



THE AGA KHAN UNIVERSITY

eCommons@AKU

Department of Radiology

Medical College, Pakistan

July 2011

# Cerebral nocardiosis

Rohana Naqi  
*Aga Khan University*

Humera Ahsan  
*Aga Khan University*

Muhammad Azeemuddin  
*Aga Khan University*

Follow this and additional works at: [http://ecommons.aku.edu/pakistan\\_fhs\\_mc\\_radiol](http://ecommons.aku.edu/pakistan_fhs_mc_radiol)

 Part of the [Infectious Disease Commons](#), and the [Radiology Commons](#)

## Recommended Citation

Naqi, R., Ahsan, H., Azeemuddin, M. (2011). Cerebral nocardiosis. *Journal of the Pakistan Medical Association*, 61(7), 697-9.  
**Available at:** [http://ecommons.aku.edu/pakistan\\_fhs\\_mc\\_radiol/20](http://ecommons.aku.edu/pakistan_fhs_mc_radiol/20)

## Case Report

### Cerebral Nocardiosis

Rohana Naqi, Humera Ahsan, Muhammad Azeemuddin  
Department of Radiology, Aga Khan University Hospital, Karachi.

#### Abstract

Localized and multisystem nocardiosis is an opportunistic disease that occurs commonly in immunocompromised patients. Rarely, it is also seen in immunocompetent individuals. The most common disease sites include lung, skin and central nervous system.

We report a case of 73 years old man who is a known case of rheumatoid arthritis for more than 15 years and was on Methotrexate and Prednisolone. Now presented with generalized tonic clonic seizures. His Magnetic Resonance Imaging (MRI) scan showed a ring enhancing lesion with mild surrounding oedema in right posterior parietal cortex. Based on the finding, the most probable diagnosis of cerebral abscess was suggested. Patient underwent right sided craniotomy with aspiration of abscess. Serum Gram staining showed branching Gram-positive rods, and serum culture showed colonies of *Nocardia Asteroides*. He was started on Sulfamethoxazole-Trimethoprim. On follow-up examination, the patient showed marked improvement clinically and was discharged in stable condition on long term antibiotic therapy.

This case highlights the importance of including nocardia on the differential diagnosis especially in patients who present with abnormal MRI scan findings that mimic tuberculoma or neoplastic disease. Clinical awareness of this condition could expedite the diagnostic process and help improve morbidity and mortality.

**Keywords:** Cerebral Nocardiosis, *Nocardia Asteroides*, Tuberculoma.

#### Introduction

Nocardiosis is an opportunistic infection caused by Gram-positive, weakly acid-fast filamentous aerobic organisms. *Nocardia asteroides* is the most common species to cause infection in humans.<sup>1</sup> Nocardiosis is a relatively uncommon bacterial infection but is strongly associated with immunosuppression. The majority of infections occur in patients with weakened cell-mediated immunity. Patients commonly include those who have received bone-marrow or solid-organ transplantation and are on immunosuppressive therapy, those with Human Immunodeficiency Virus/Acquired Immunodeficiency Syndrome (HIV/AIDS), patients on long term steroid therapy, and those with malignancies. *Nocardia asteroides* infection is acquired from the environment through

inhalation into the respiratory tract.<sup>2</sup> Involvement of the lungs (75-80%) and the skin is the most common form of presentation, but virtually any organ system may be involved.<sup>3</sup> The central nervous system is involved in approximately 44% of cases, usually in patients having pulmonary infection, but this was not the case in our patient who thus had an unusual clinical presentation.<sup>4</sup> It can spread to any part of the brain including cerebellum and even orbits.<sup>5</sup> When there is involvement of two or more noncontiguous site organs, with or without CNS involvement, the disease is said to be disseminated. The incidence of disseminated disease is 25-40%.<sup>1</sup> The imaging findings of Nocardiosis are not specific. It depends on the stage of the infectious process at the time of imaging; this may vary from cerebritis to frank abscess formation.

#### Case Report

A 73 years old male ex-smoker, known case of hypertension, rheumatoid arthritis for more than 15 years and on Methotrexate and Prednisolone came with a history of recurrent pleural effusions since last 6 years. He was on empiric Anti-tuberculous therapy (ATT) for 1 month. He suddenly developed body stiffening with jerking of all four limbs, frothing and tongue bite. This lasted for 5 minutes with post ictal confusion lasting 20-25 minutes. Post seizure his talk was irrelevant, he used abusive language and had recurrent auditory hallucinations, so was brought to emergency. One month prior to admission pleural biopsy was done which did not show any significant inflammatory infiltrate, granuloma formation or evidence of malignancy. Pleural fluid analysis showed exudative lymphocytic picture. On examination patient was vitally stable, alert, oriented to place and person but not oriented to time. No signs of meningeal irritation were noted. Cranial nerves were intact, plantar down going, reflexes +1 in all four limbs, power 3/5 in lower limbs and 4/5 in upper limbs, tone was normal. Sensory system was intact. His laboratory investigations showed raised Total leukocyte count (TLC) count. His CT scan chest showed moderate empyema on left side with adjacent partial collapse and mild ipsilateral mediastinal shift.

He underwent MRI Brain with Gadolinium for the investigation of seizures, which showed a lesion in right posterior parietal cortex. It was associated with mild

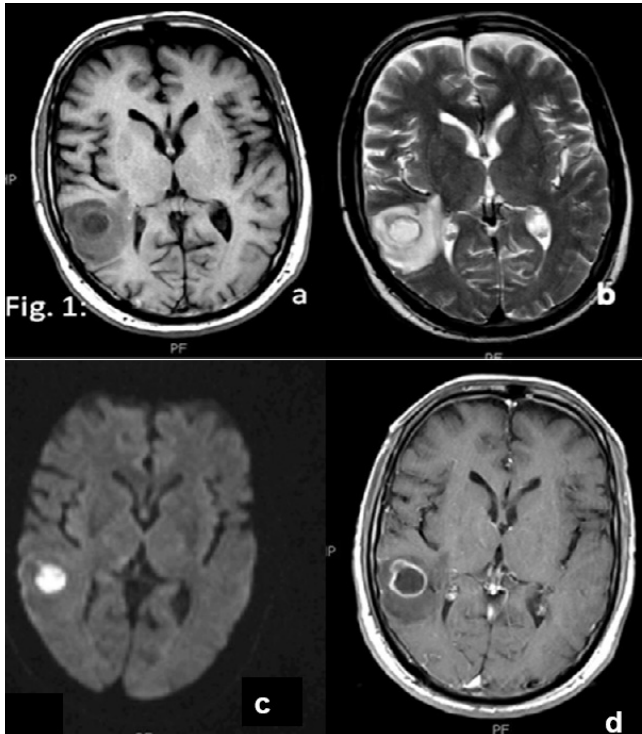


Figure-1: (a) T1-Weighted Axial image shows hypointense lesion in right parietal cortex. (b) T2- weighted axial image shows a lesion with central hyperintensity and peripheral low signal intensity rim, associated with surrounding edema. (c) Diffusion weighted axial image shows restricted diffusion. (d) Post contrast T1-weighted axial image shows a cystic mass (abscess) with rim enhancement, associated with perifocal edema with mass effect on the occipital horn of right lateral ventricle.

surrounding oedema causing effacement of adjacent cortical sulci and slight pressure effect over adjacent occipital horn of right lateral ventricle. The lesion appeared hypointense on T1-weighted and hyperintense on T2-weighted images, and showed diffusion restriction. Post contrast images showed ring enhancement. Based on these findings a most probable diagnosis of cerebral abscess was suggested. Patient underwent right sided craniotomy with aspiration of the abscess. The lesion with pus was drained and sent for culture and sensitivity, Acid fast bacilli (AFB), and histopathology. The histopathology revealed abscess formation and macrophages. With these findings clinical and microbiological correlation was advised. On microbiological examination, culture on appropriate media was done. Serum Gram stain showed branching gram positive rods, and serum culture showed colonies of *Nocardia Asteroides*. Considering all these findings, the patient was diagnosed as having cerebral abscess due to *Nocardia Asteroides*. He was started on Sulfamethoxazole-Trimethoprim. After surgery and medical therapy, the patient recovered progressively. On follow-up examination there was marked clinical improvement.

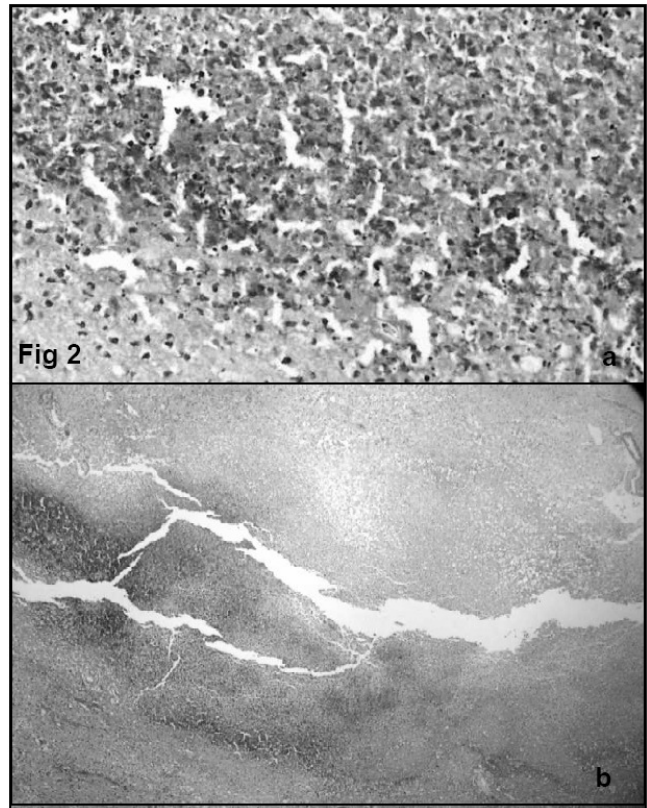


Figure-2: (a) Histopathology. High resolution. (b) Low power electron microscopy. Show brain parenchyma with extensive necrosis and acute inflammatory infiltrate.

## Discussion

*Nocardia asteroides* is the most common human pathogen. The site of infection is primarily the lungs. Brain abscess is noted to be the most common site for nocardial metastasis from the lungs. *Nocardia asteroides* accounts for 86% of systemic nocardiosis in humans, 98% of cerebral nocardial abscesses, and approximately 2% of all cerebral abscesses.<sup>2</sup> Nocardiosis can affect both immunocompromised and immunocompetent individuals.

The imaging findings of nocardiosis in the brain depends on the stage of the infectious process at the time of imaging; this may vary from cerebritis to frank abscess formation. In the abscess stage, the necrotic debris accumulates centrally, while the collagenous capsule is being formed. The proteinaceous, necrotic debris is signal intensity higher than that of the CSF on T1-weighted and turbo-inversion recovery (IR) images, with a moderate degree of brain edema. On T1-weighted images, the abscess capsule stands out against the necrotic center and surrounding edema as an isointense to slightly hyperintense ring. On T2-weighted images, the ring is consistently hypointense. This hypointense

capsule may either be due to capsular hemorrhage, the paramagnetic methemoglobin causing increased signal on T1-weighted images, or due to an abundance of free radicals in the macrophages in the abscess capsule. The activity of the macrophages is highest in the late cerebritis and early abscess phases, at which time the capsule shows marked hypointensity on T2-weighted images.<sup>6</sup> Ring enhancement is seen, which may persist for up to 8 months after treatment and therefore should not be interpreted as failure of treatment. Reliable signs of good response to treatment are shrinkage of the necrotic center and decrease in capsular hypointensity on T-2 weighted images.<sup>7</sup>

As the imaging findings are non-specific and the causative organism is difficult to isolate, diagnosis is often a problem and hence it is important to have a high index of suspicion in the appropriate clinical settings, especially in patients not responding to antituberculous treatment. When patient presents with concomitant brain and lung lesions, the differential diagnosis to be kept in mind include tuberculosis, neoplastic disease, and nocardiosis.<sup>7</sup>

Diagnosis of nocardiosis depends on the demonstration of the bacterium by direct microscopy and culture.<sup>8</sup> The predominance of polymorphonuclear leukocytes in the pus and the frequent absence of regional lymphadenopathy are characteristic.<sup>1</sup> A number of drugs have been advocated in the treatment of nocardiosis, but the drug of choice is co-trimoxazole, which can be used alone or in combination with other antimicrobials.<sup>9</sup> Surgical management for cerebral nocardia infection is often based upon the patient's clinical and immune status and the number and size of the lesions. In immunocompromised patients and those with multiple abscesses, a more aggressive surgical approach, such as craniotomy and excision, is indicated to maximize

likelihood of survival. In non-immunocompromised patients or those with a single lesion, stereotactic aspiration followed by antibiotic therapy may be sufficient.<sup>9</sup> Poor prognostic criteria include acute infection (symptoms less than three weeks), continuation of steroids, immunocompromised status, disseminated disease and the presence of brain abscess. Even with the best of medical and surgical therapy, the overall mortality in disseminated disease amounts to 40-60%.<sup>10</sup>

## Conclusion

There should be high index of suspicion for nocardiosis in the appropriate clinical setting. For disseminated disease with brain abscess, multidrug chemotherapy with surgical drainage is the management of choice.

## References

1. Wakhlu A, Agarwal V, Dabadghao S. Nocardiosis in patients of chronic idiopathic thrombocytopenic purpura on steroids. *J Assoc Phys India* 2004; 52: 591-3.
2. Fleetwood IG, Embil JM, Ross IB. Nocardia asteroides cerebral abscess in IC hosts: report of three cases and review of surgical recommendations. *Surg Neurol* 2000; 53: 605-10.
3. Urbaniak-Kujda D, Cielinska S, Kapelko-Slowik K, Mazur G, Bronowicz A. Disseminated nocardiosis as a complication of Evan's syndrome. *Ann Haematol* 1999; 78: 385-7.
4. Present CA, Wiernik PH, Serpick AA. Factors affecting survival in nocardiosis. *Am Rev Respir Dis* 1973; 108: 1444-8.
5. Borchers M, von der Mulbe B, Teikemeier F, Theegarten D. Pulmonary nocardiosis with abscesses spreading to cerebrum, cerebellum and orbits. *Dtsch Med Wocheuschr* 2006; 131: 1085-8.
6. Edelman RR, Hesselink JR, Zlatkin MB, Cruess JV. Infectious and inflammatory diseases. *Clinical Magnetic Resonance Imaging*. 3rd ed. Elsevier Health Sciences, 2005; pp 1250-1.
7. Sud S, Buxi T, Anand I, Rohatgi A. Case series: Nocardiosis of the brain and lungs. *Indian J Radiol Imaging* 2008; 18: 218-21.
8. Beaman BL, Beaman L. Nocardia species: Host-parasite relationships. *Clin Microbiol Rev* 1994; 7: 213-64.
9. Memelak AN, Obana WG, Flaherty JF. Nocardial brain abscess: treatment strategies and factors influencing outcome. *Neurosurgery* 1994; 35: 622-31.
10. Mandell GL, Benett JE, Douglas RG. Principles and practice of infectious diseases. 4th ed. Churchill Livingstone, 1995; pp 2273-80.