

Molecular imaging agents for detection of β -amyloid plaques in Alzheimer's disease

Letícia Quental¹, Goreti Ribeiro Morais¹, Isabel Santos¹, António Paulo^{1,2}

1. Grupo de Ciências Radiofarmacêuticas, Campus Tecnológico e Nuclear, Instituto Superior Técnico (CTN/IST)

2. Corresponding author: apaulo@ctn.ist.utl.pt

ABSTRACT: The formation of amyloid structures is a neuropathological feature that characterizes several neurodegenerative disorders, such as Alzheimer's and Parkinson's disease. Up to now, the definitive diagnosis of these diseases can only be accomplished by immunostaining of *post mortem* brain tissues with dyes such Thioflavin T and congo red. Aiming at early *in vivo* diagnosis of Alzheimer's disease (AD), several amyloid-avid radioprobes have been developed for β -amyloid imaging by positron emission tomography (PET) and single-photon emission computed tomography (SPECT). The aim of this paper is to present a perspective of the available amyloid imaging agents, special those that have been selected for clinical trials and are at the different stages of the US Food and Drugs Administration (FDA) approval.

Keywords: Alzheimer's disease, β -Amyloid aggregation, molecular imaging, molecular probes.

Sondas moleculares para a deteção de placas β -amilóide na doença de Alzheimer

RESUMO: A formação de estruturas amilóides é uma característica neuropatológica comum nas várias doenças neurodegenerativas, como a doença de Alzheimer e de Parkinson. Até à data, o diagnóstico destas doenças apenas é conseguido *post mortem* por estudos histoquímicos com corantes, como a Tioflavina T e o vermelho do congo. Durante os últimos anos têm sido desenvolvidos vários compostos com afinidade para agregados de β -amilóide para visualização dessas estruturas por tomografia de emissão de positrões (PET) e tomografia computadorizada de emissão de fotão único (SPECT). Neste trabalho pretendemos apresentar as principais sondas radioativas com potencial para imagiologia de estruturas amilóides, em especial aquelas que entraram em ensaios clínicos e se encontram em diferentes etapas de aprovação pela FDA.

Palavras-chave: doença de Alzheimer, agregação da β -amilóide, imagiologia molecular, sondas moleculares.

Introduction

Alzheimer's disease (AD) is a neurodegenerative disorder that affects millions of people worldwide¹. The impact in the public health is considerable, with tendency to increase as the population gets older. The most common symptoms of AD are decline in the cognitive functions, irreversible memory loss, disorientation and language impairment. AD diagnosis is based mainly on the patient's history and on neuropsychological tests. However, the overlapping of early AD symptoms with normal signs of aging difficult such diagnosis. Histopathologically, AD is characterized by the presence of senile plaques containing β -amyloid ($A\beta$) plaques and neurofibrillary tangles (NFTs) containing highly

phosphorylated tau protein. Currently, the accurate diagnosis of AD is only possible *post mortem* after confirmation of extracellular $A\beta$ deposits and NFTs, through histopathological studies using dyes such as thioflavin T (ThT) and congo red (CR)².

The molecular processes underlying the pathology are still unknown, however it is thought that the $A\beta$ deposits accumulate before the onset of the disease³. $A\beta$ is a soluble extracellular peptide composed by 40 ($A\beta_{1-40}$) or 42 ($A\beta_{1-42}$) aminoacids, which is formed from transmembrane amyloid-precursor protein (APP) by the action of β and γ secretases⁴. Thus, *in vivo* imaging agents that can specifically demonstrate the location and density of $A\beta$ deposits

in AD brain will be useful for an early and conclusive diagnosis of AD (cf. Figure 1). Moreover, these agents will help on the finding and monitorization of novel AD therapies, especially the ones based on the dissolution of the A β plaques. Positron emission tomography (PET) and single-photon emission computed tomography (SPECT) are among the best suited molecular imaging modalities to achieve such a goal.

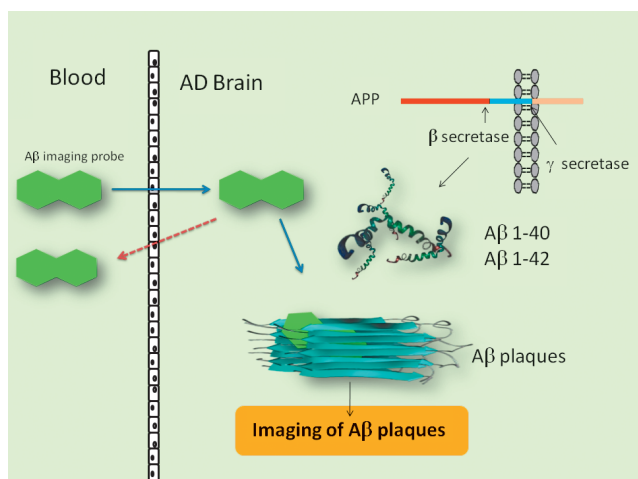


Figure 1: *In vivo* interaction of an imaging probe with cerebral A β plaques.

Design of A β imaging agents

In the past few years, several compounds have been designed to interact with the oligomeric and fibrillar forms of the A β peptide for its *in vivo* detection⁵⁻⁹. Those compounds are essentially small, aromatic and heteroaromatic molecules. Their planarity allows for the insertion into the β sheet structure of A β plaques, ensuring good binding affinity. A common requisite for these compounds is the ability to cross the blood brain barrier (BBB) to reach the intracerebral target. A good radiotracer for *in vivo* imaging of A β plaques by PET or SPECT must have a high initial brain uptake and a fast washout from the normal brain, to ensure a good target/non-target ratio. The design of these aromatic and planar compounds for the targeting of A β plaques have been based mainly on the highly conjugated system present in the structures of the ThT and CR dyes. So far, the most promising SPECT and PET radioprobes for *in vivo* imaging of A β plaques are compounds containing the gamma emitters ¹²³I/¹²⁵I and the positron emitters ¹¹C or ¹⁸F, respectively (cf. Figure 2)⁹. Although ^{99m}Tc offers several advantages for SPECT imaging, the design of ^{99m}Tc-based radiopharmaceuticals usually requires a bifunctional chelator (BFC) for the metal complexation. Conjugation of BFCs to amyloid-avid molecules produces constructs with limited BBB permeability and therefore unsuitable for *in vivo* application.

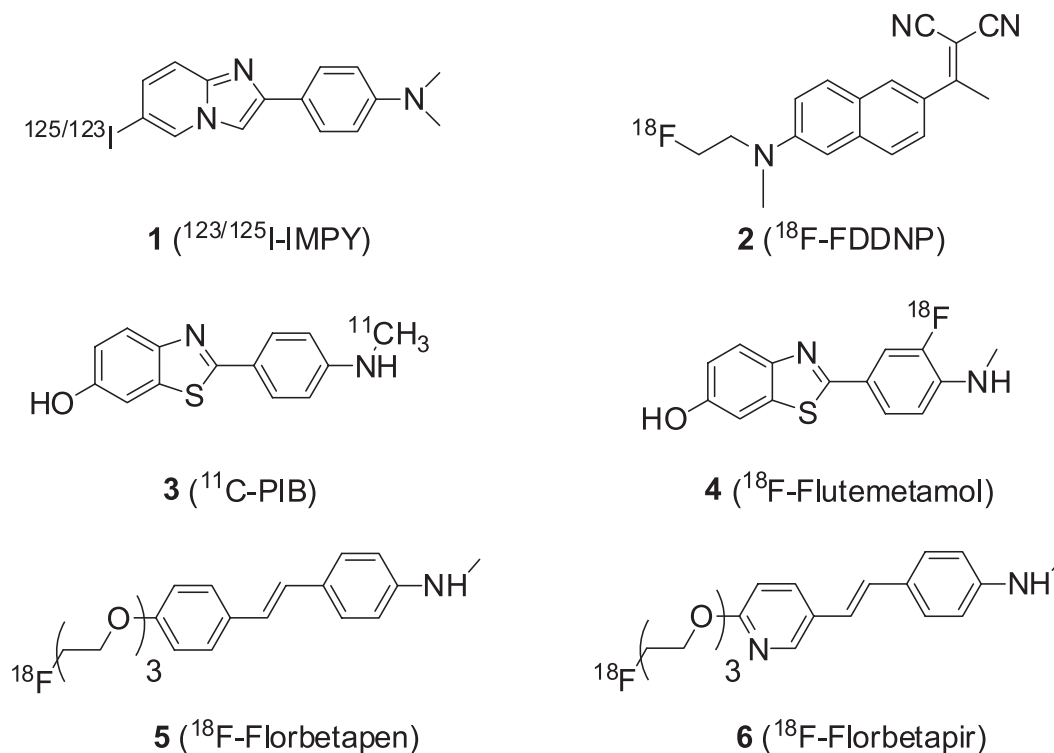


Figure 2: Chemical structures of relevant A β imaging agents.

Relevant Radiolabeled A β imaging probes

Although there are more SPECT than PET scanners, the same is not true with respect to agents for amyloid imaging. Among the SPECT amyloid imaging, the ^{123}I -IMPY (cf. Figure 2[1]) has shown up as the most promising¹⁰, while more progress has been observed in the development of PET amyloid imaging radioprobes. ^{123}I -IMPY displayed selective binding to A β plaque *ex vivo* in autoradiographic experiments using mice AD model (PSAPP)¹¹. However the signal-to-noise ratio for plaque labelling is not ideal, maybe due to the fast clearance from the brain and plasma observed in AD and normal subjects¹².

The compound ^{18}F -FDDNP (cf. Figure 2[2]) was the first PET probe successfully developed for *in vivo* molecular imaging of A β plaques¹³. However, PET imaging showed that ^{18}F -FDDNP labels both A β plaques and NFTs in the brain of AD, and thus is not selective for measuring A β deposits load in the AD brain. Also, its excessive lipophilicity ($\log P = 3.92$) contributed for high non-specific binding in normal mice brain¹⁴. The "Pittsburgh compound B" (^{11}C -PiB) (cf. Figure 2[3]) is one of the best characterized PET imaging agent for A β plaques in the brain. It showed excellent initial brain uptake and a high binding affinity to A β plaque ($K_i = 0.87 \pm 0.18 \text{ nM}$)¹⁵. In AD patients, ^{11}C -PiB retention, which was increased in the cortical areas, correlated inversely with cerebral glucose metabolism determined with ^{18}F -fluorodeoxyglucose (^{18}F -FDG) (cf. Figure 3)¹⁶. Since then, other studies in thousands of AD patients have validated the usefulness of ^{11}C -PiB as a PET A β imaging probe¹⁷⁻²⁰. However, the short half-life of ^{11}C ($t_{1/2} = 20 \text{ min}$) limits the clinical use of ^{11}C -PiB to centers with an on-site cyclotron. Such limitation prompted several authors to search for alternative amyloid-binding radiopharmaceuticals labelled with longer lived fluorine-18

($t_{1/2} = 110 \text{ min}$). ^{18}F -Flutemetamol (GE-067) (cf. Figure 2[4]) is very similar to PiB, except that it has an ^{18}F -tag instead of ^{11}C . ^3H -Flutemetamol binding reflects A β deposits load in *post mortem* brain tissue. ^{18}F -Flutemetamol is comparable to ^{11}C -PiB in its ability to detect brain A β pathology in AD living patients²¹. Biopsy and autopsy studies showed that ^{18}F -flutemetamol has a high specificity and sensitivity in the detection of A β deposits in the brain²². Final Phase III data showed a strong concordance between ^{18}F -Flutemetamol PET imaging and A β pathology (cf. Figure 4)²³. A New Drug Application (NDA) was submitted to the US Food and Drug Administration (FDA) and to European Medicine Agency (EMA) for the use of ^{18}F -flutemetamol in the visual detection of A β burden in adult patients suspected of AD²⁴.

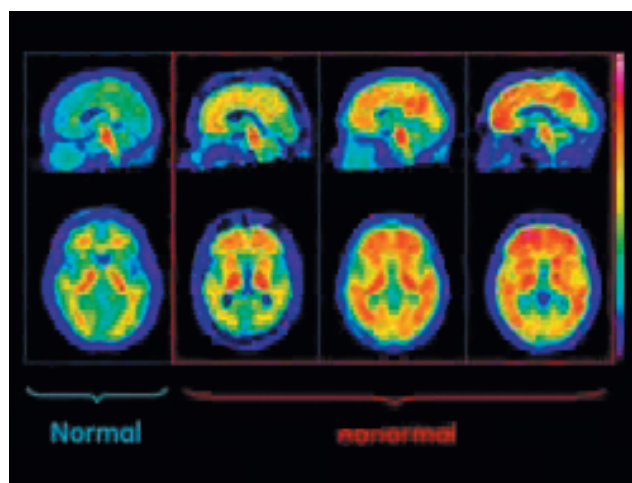


Figure 4: ^{18}F -Flutemetamol images in normal volunteers and in AD patients.

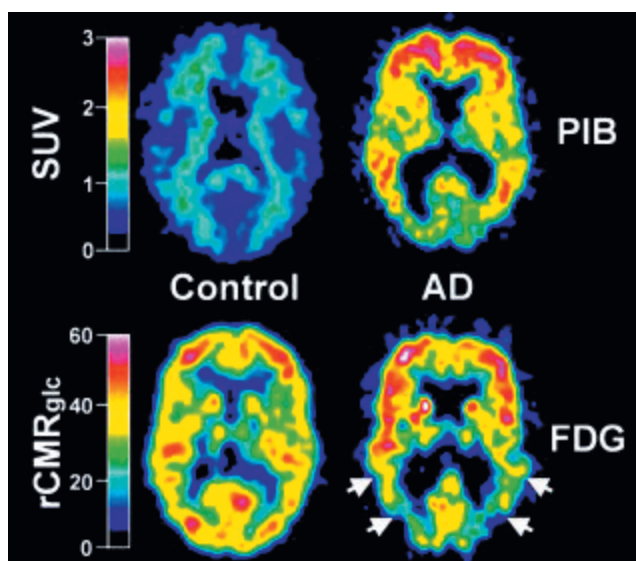


Figure 3: ^{11}C -PiB standardized uptake value (SUV) and ^{18}F -FDG $r\text{CMR}_{\text{glc}}$ images in AD patients and healthy control (HC) subjects¹³. Reproduced by permission of John Wiley and Sons.

The tracers ^{18}F -florbetapen and ^{18}F -florbetapir (cf. Figure 2[5-6]) were also found to display high-affinity binding to A β plaques with $K_i < 10 \text{ nM}$. Thanks to the pyridine ring in florbetapir, this tracer is less lipophilic than florbetapen. Nonetheless their non-specific binding in white matter is higher than that of ^{11}C -PiB²⁵⁻²⁶. Clinical studies with ^{18}F -florbetapir demonstrated a strong correlation between *in vivo* amyloid PET imaging and its *post mortem* histopathological binding²⁶. Also, ^{18}F -florbetapir-PET/MR studies correlated positively the anatomic data with the localization of ^{18}F -florbetapir retention in the white and gray matter often affected by AD. Clinical interpretation of ^{18}F -florbetapir PET relies upon assessment of gray-white differentiation, with negative studies showing higher activity in the white matter than in the cerebral cortex (cf. Figure 5A) and positive studies showing loss of gray-white contrast due to the tracer binding to beta-amyloid plaques in the cerebral cortex (cf. Figure 5B)²⁷. ^{18}F -Florbetapir has recently been approved by the FDA for clinical use²⁸. Nonetheless, other amyloid PET tracers are in late phase clinical trials and may soon become clinically available.

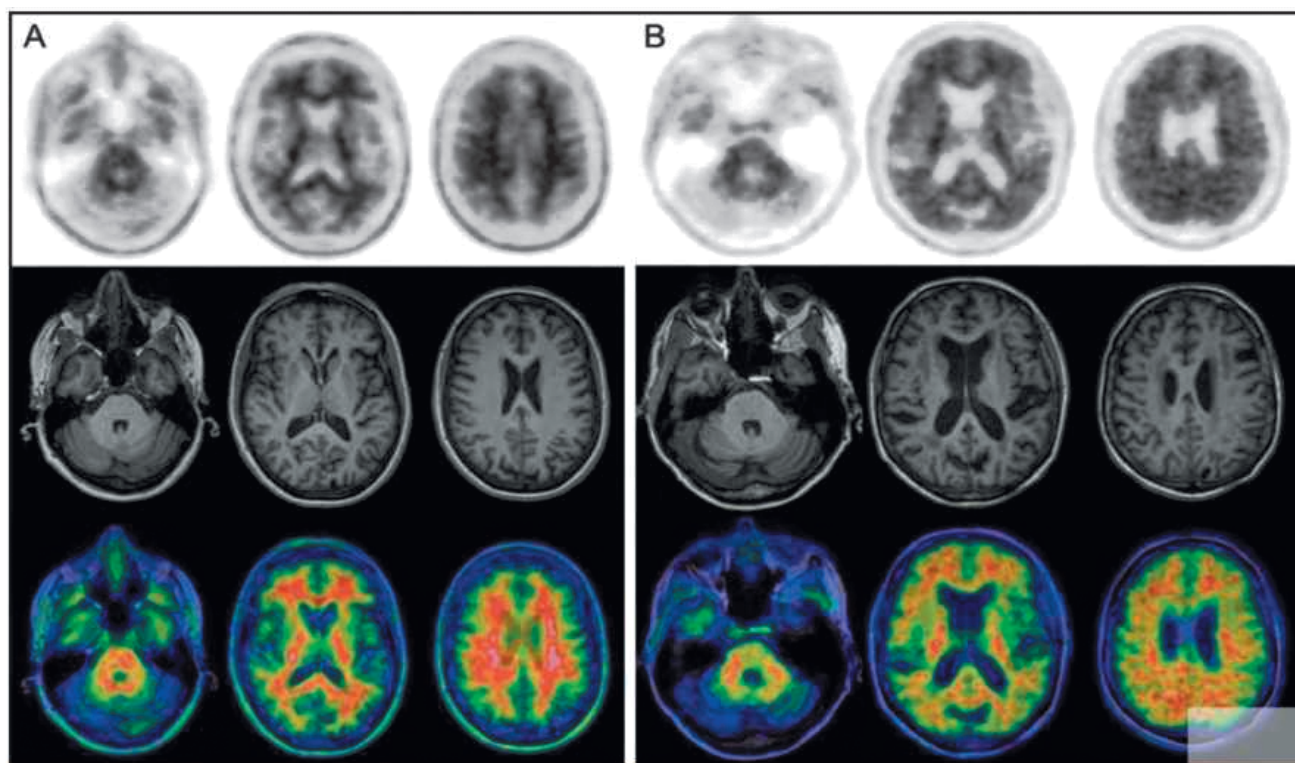


Figure 5: Amyloid imaging with ^{18}F -florbetapir. **A)** Normal control subject with no-to-sparse $\text{A}\beta$ plaques. **B)** Positive PET/MRI study, consistent with moderate to frequent $\text{A}\beta$ plaques²⁰.

Conclusions

The ^{11}C -PIB, ^{18}F -flutemetamol, ^{18}F -florbetapen, and ^{18}F -florbetapir have been well studied in humans as amyloid imaging agents. The imaging performance of these four PET tracers is comparable with high retention in cortical regions, providing all of them good contrast with non-target regions. Despite being the best studied, ^{11}C -PIB has not been yet approved by the FDA, while ^{18}F -flutemetamol is pending FDA and EMA approval. So far, the only amyloid PET tracer authorized by the FDA is the ^{18}F -florbetapir (Amyvid) for brain imaging of cognitively impaired adults undergoing evaluation of AD²⁸.

Acknowledgments

We thank the Fundação para a Ciência e Tecnologia (FCT) – PTDC/QUI/102049/2008 and "Ciência 2008" program – for financial support.

References

1. Alzheimer Association. 2012 Alzheimer's disease facts and figures. *Alzheimers Dement.* 2012;8(2):131-68.
2. Bacskai BJ, Hickey GA, Skoch J, Kajdasz ST, Wang Y, Huang GF, et al. Four-dimensional multiphoton imaging of brain entry, amyloid binding, and clearance of an amyloid-beta ligand in transgenic mice. *Proc Natl Acad Sci U S A.* 2003;100 (21):12462-7.
3. Irvine GB, El-Agnaf OM, Shankar GM, Walsh DM. Protein aggregation in the brain: the molecular basis for Alzheimer's and Parkinson's diseases. *Mol Med.* 2008;14 (7-8): 451-64.
4. Vassar R, Bennett BD, Babu-Khan S, Kahn S, Mendiaz EA, Denis P, et al. Beta-secretase cleavage of Alzheimer's amyloid precursor protein by the transmembrane aspartic protease BACE. *Science.* 1999;286(5440):735-41.
5. Ono M. Development of positron-emission tomography/single-photon emission computed tomography imaging probes for *in vivo* detection of beta-amyloid plaques in Alzheimer's brains. *Chem Pharm Bull.* 2009;57(10):1029-39.
6. Mathis CA, Lopresti BJ, Klunk WE. Impact of amyloid imaging on drug development in Alzheimer's disease. *Nucl Med Biol.* 2007;34(7):809-22.
7. Kung HF, Choi SR, Qu W, Zhang W, Skovronsky D. 18F stilbenes and styrylpyridines for PET imaging of A beta plaques in Alzheimer's disease: a miniperspective. *J Med Chem.* 2010;53(3):933-41.
8. Ribeiro Morais G, Vicente Miranda H, Santos IC, Santos I, Outeiro TF, Paulo A. Synthesis and *in vitro* evaluation of fluorinated styryl benzazoles as amyloid-probes. *Bioorg Med Chem.* 2011;19(24):7698-710.
9. Ribeiro Morais G, Paulo A, Santos I. A synthetic overview of radiolabeled compounds for β -amyloid targeting. *Eur J Org Chem.* 2012;2012 (7):1279-93.
10. Zhuang ZP, Kung MP, Wilson A, Lee CW, Plössl K, Hou C, et al. Structure-activity relationship of imidazo[1,2- α]

- pyridines as ligands for detecting beta-amyloid plaques in the brain. *J Med Chem.* 2003;46(2):237-43.
11. Kung MP, Hou C, Zhuang ZP, Cross AJ, Maier DL, Kung HF. Characterization of IMPY as a potential imaging agent for beta-amyloid plaques in double transgenic PSAPP mice. *Eur J Nucl Med Mol Imaging.* 2004;31(8):1136-45.
 12. Newberg AB, Wintering NA, Plössl K, Hochold J, Stabin MG, Watson M, et al. Safety, biodistribution, and dosimetry of 123I-IMPY: a novel amyloid plaque-imaging agent for the diagnosis of Alzheimer's disease. *J Nucl Med.* 2006;47(5):748-54.
 13. Barrio J, Huang S, Cole G, Satyamurthy N. PET imaging of tangles and plaques in Alzheimer's disease with a highly hydrophobic probes. *J Labelled Comp Radiopharm.* 1999; 42(Suppl 11):S194-S5.
 14. Agdeppa ED, Kepe V, Liu J, Flores-Torres S, Satyamurthy N, Petric A, et al. Binding characteristics of radiofluorinated 6-dialkylamino-2-naphthylethylidene derivatives as positron emission tomography imaging probes for beta-amyloid plaques in Alzheimer's disease. *J Neurosci.* 2001;21(24):RC189.
 15. Mathis CA, Wang YM, Holt DP, Huang GF, Debnath ML, Klunk WE. Synthesis and evaluation of C-11-labeled 6-substituted 2-arylbenzothiazoles as amyloid imaging agents. *J Med Chem.* 2003;46(13):2740-54.
 16. Klunk WE, Engler H, Nordberg A, Wang Y, Blomqvist G, Holt DP, et al. Imaging brain amyloid in Alzheimer's disease with Pittsburgh Compound-B. *Ann Neurol.* 2004;55(3):306-19.
 17. Rowe CC, Ng S, Ackermann U, Gong SJ, Pike K, Savage G, et al. Imaging beta-amyloid burden in aging and dementia. *Neurology.* 2007;68(20):1718-25.
 18. Raji CA, Becker JT, Tsopelas ND, Price JC, Mathis CA, Saxton JA, et al. Characterizing regional correlation, laterality and symmetry of amyloid deposition in mild cognitive impairment and Alzheimer's disease with Pittsburgh Compound B. *J Neurosci Methods.* 2008;172(2):277-82.
 19. Butters MA, Klunk WE, Mathis CA, Price JC, Ziolkowski SK, Hoge JA, et al. Imaging Alzheimer pathology in late-life depression with PET and Pittsburgh compound-B. *Alzheimer Dis Assoc Disord.* 2008;22(3):261-8.
 20. Archer HA, Edison P, Brooks DJ, Barnes J, Frost C, Yeatman T, et al. Amyloid load and cerebral atrophy in Alzheimer's disease: an C-11-PIB positron emission tomography study. *Ann Neurol.* 2006;60(1):145-7.
 21. Ikonomic M, Price J, Abrahamson E, Mathis C, Paljug W, Debnath M, et al. Direct correlations of [H-3]flutemetamol binding with [H-3]PIB binding and amyloid-beta concentration and plaque load in [C-11]PIB imaged brains. *Neurology.* 2012;78(Meeting Abstracts 1):S34.002.
 22. Vandenberghe R, Van Laere K, Ivanoiu A, Salmon E, Bastin C, Triau E, et al. 18F-flutemetamol amyloid imaging in Alzheimer disease and mild cognitive impairment: a phase 2 trial. *Ann Neurol.* 2010;68(3):319-29.
 23. Wolk D, Gomez J, Sadowsky C, Singh U, Rinne J, Wong D, et al. Brain autopsy and in-vivo cortical brain biopsy trials show a strong concordance between [F-18]flutemetamol PET and amyloid-beta pathology. *Neurology.* 2012; 79(11):E88.
 24. Express Healthcare. US FDA, EMEA accept GE healthcare's review applications for [18F] flutemetamol [Internet]. Express Healthcare; 2013 Jan 9. Available from: <http://healthcare.financialexpress.com/latest-updates/1166-us-fda-emea-accept-ge-healthcare-s-review-applications-for-18f-flutemetamol>
 25. Barthel H, Gertz HJ, Dresel S, Peters O, Bartenstein P, Buerger K, et al. Cerebral amyloid-beta PET with florbetaben (18F) in patients with Alzheimer's disease and healthy controls: a multicentre phase 2 diagnostic study. *Lancet Neurol.* 2011;10(5):424-35.
 26. Clark CM, Schneider JA, Bedell BJ, Beach TG, Bilker WB, Mintun MA, et al. Use of florbetapir-PET for imaging beta-amyloid pathology. *JAMA.* 2011;305(3):275-83.
 27. Fowler K, McConathy J, Khanna G, Dehdashti F, Benzinger TL, Miller-Thomas M, et al. Simultaneous PET/MRI acquisition: clinical potential in anatomically focused and whole-body examinations. *Appl Radiol.* 2013;42(6):9-14.
 28. Yang L, Rieves D, Ganley C. Brain amyloid imaging – FDA approval of Florbetapir F18 Injection. *New Engl J Med.* 2012;367(10):885-7.

Artigo recebido em 07.08.2013