



Asymptomatic *Giardia Intestinalis* infection and Roux-Y-Gastric Bypass

Laurent Genser, Christine Poitou, Edith Brot-Laroche

► To cite this version:

Laurent Genser, Christine Poitou, Edith Brot-Laroche. Asymptomatic *Giardia Intestinalis* infection and Roux-Y-Gastric Bypass. *Surgery for Obesity and Related Diseases*, Elsevier, 2015, in press. <10.1016/j.soard.2015.06.002>. <hal-01176995>

HAL Id: hal-01176995

<http://hal.upmc.fr/hal-01176995>

Submitted on 16 Jul 2015

HAL is a multi-disciplinary open access archive for the deposit and dissemination of scientific research documents, whether they are published or not. The documents may come from teaching and research institutions in France or abroad, or from public or private research centers.

L'archive ouverte pluridisciplinaire **HAL**, est destinée au dépôt et à la diffusion de documents scientifiques de niveau recherche, publiés ou non, émanant des établissements d'enseignement et de recherche français ou étrangers, des laboratoires publics ou privés.

Title Page

Asymptomatic *Giardia Intestinalis* infection and Roux-Y-Gastric Bypass

5 **L. Genser**^{1,2,4,5} M.D; **Christine Poitou**^{2,3,4} M.D PhD; **Edith Brot-Laroche**^{2,5} PhD

¹ Assistance Publique-Hôpitaux de Paris (AP-HP), Department of Digestive and Hepato-Pancreato-Biliary Surgery, Pitié-Salpêtrière University Hospital, Pierre & Marie Curie University, 47-83 Boulevard de l'Hôpital, 75013, Paris, France.

10 ² Institute of Cardiometabolism and Nutrition, ICAN, Pitié-Salpêtrière Hospital, Paris, F-7513, France.

³ Assistance Publique-Hôpitaux de Paris (AP-HP), Department of Nutrition, Assistance Publique-Hôpitaux de Paris (AP-HP), Pitié-Salpêtrière University Hospital, Pierre & Marie Curie University, 47-83 Boulevard de l'Hôpital, 75013, Paris, France.

⁴ Inserm UMR_S 1166, Nutriomics Team 6, Pitié-Salpêtrière Hospital, Paris, Sorbonne universités,
15 UPMC Université Paris 06; Sorbonne Cités; INSERM; F-75013, Paris, France ;

⁵ Inserm UMR_S 1138, Team 4, Centre de Recherche des Cordeliers, Sorbonne universités, UPMC Université Paris 06; Sorbonne Cités; INSERM; F-75006, Paris, France ;

20 **Contributions:** LG collected data and contributed to discussion; LG, CP and EBL contributed to case conceptualization, participated in writing and reviewing of the manuscript. **Correspondence:** Laurent Genser; laurent.genser@gmail.com

Shortened title: Giardiasis and gastric bypass

25 **Grants and Fundings:** LG has benefited from a French government grant managed by the National Agency for Research “Investments for the Future ANR-10-IAHU ICAN; The project was funded by APPERT institute (UPPIA); Benjamin Delessert Institute; Lipid and Nutrition group.

30 **Acknowledgements:** The authors thank patient in the clinical investigation program for their participation. F. Marchelli and V. Lemoine, Nutrition Department, Pitié-Salpêtrière Hospital, Paris, France, were in charge of patient data base management. Daniele Chateau UMRS1138 team Leturque and Kevin Garbin CICC imaging core facility of UMRS 1138 performed the electron microscopy of patient jejunum.

35 **Manuscript:**

Giardiasis is one of the most common parasitic infections of the human intestine worldwide, and ranges from 3-7% in western countries to 100% in some populations [1]. *Giardia Intestinalis* (i.e *Duodenalis* or *Lambli*a) is a flagellated, binucleated protozoan parasite that
40 infects the upper intestinal tract in many mammalian hosts. Giardiasis can present with a broad range of clinical manifestations, from being asymptomatic to acute or chronic nonspecific gastro-intestinal symptoms associated with malnutrition [2]. However little is known regarding Giardiasis in human obesity.

A 41 year-old obese woman (BMI: 53.2 kg/m², weight: 159 kg) with a normal clinical
45 examination and preoperative investigations underwent an uneventful Roux-en-Y gastric bypass. A jejunal sample of surgical waste was systematically collected and analyzed in the context of a clinical trial (NCT02292121). During the morphological inspection of the jejunal epithelium by electron microscopy, an infection by *Giardia Lambli*a was detected (Figure 1) [3]. Once the diagnosis was confirmed by fecal parasitological examination, infestation was
50 successfully eradicated.

Giardiasis is responsible for long-term post-infectious gastrointestinal and extra-intestinal (1:3) complications, including persistent malnutrition [4], even when successfully eradicated. This case report and the known manifestations of giardiasis may warrant the search of this infection in patients showing unexpected nutritional complications, and would also justify a
55 reinforced follow-up in patients with a history of Giardiasis.

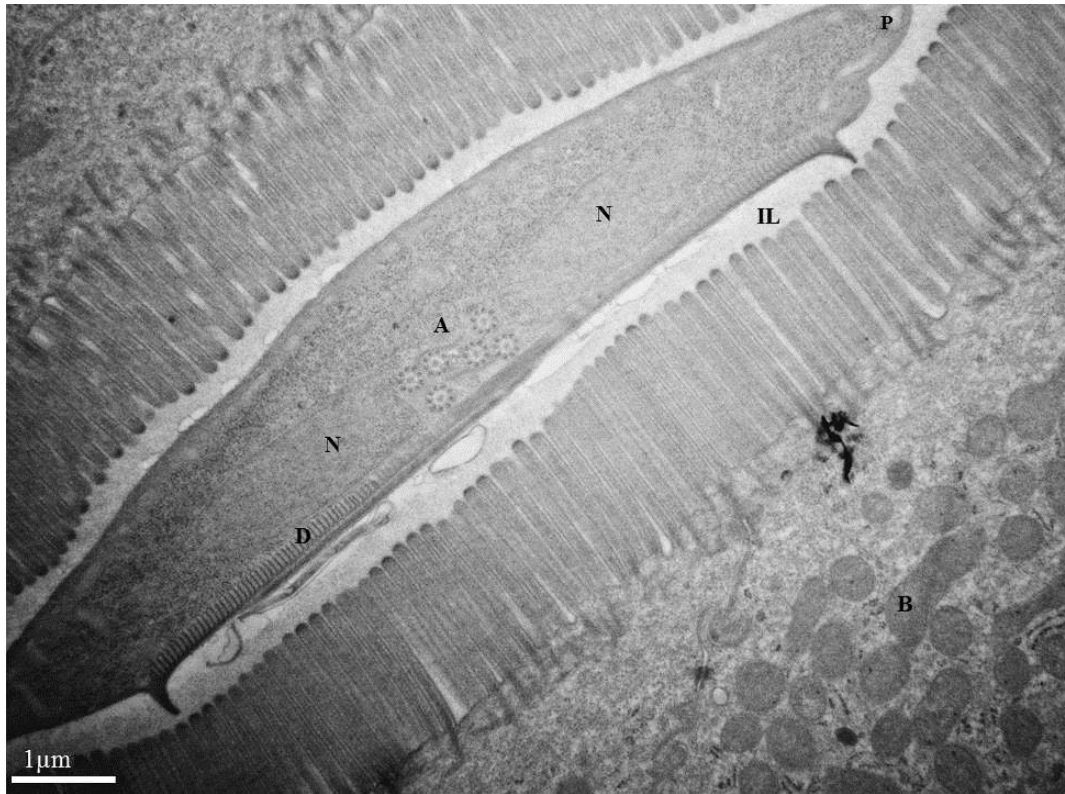


Figure Legends:

Figure 1: Transmission Electron microscopy image showing detail of a *Giardia Intestinalis* surrounding an epithelial cell of the jejunal mucosa within the intestinal lumen (IL): The ventral disk (D); the two nuclei (N), Peripheral vesicles (P) and flagellar axonemes (A). Jejunal cell shows an increased number of intra-cytoplasmic multi-vesicular and dense bodies (B)

Keywords: Giardia intestinalis; gastric bypass; symptom

References:

- 70 [1] Thompson RCA. Echinococcus, Giardia and Cryptosporidium: observational studies
challenging accepted dogma. *Parasitology* 2009;136:1529–35.
doi:10.1017/S0031182009005897.
- [2] Muhsen K, Levine MM. A systematic review and meta-analysis of the association
between Giardia lamblia and endemic pediatric diarrhea in developing countries. *Clin*
75 *Infect Dis Off Publ Infect Dis Soc Am* 2012;55 Suppl 4:S271–93. doi:10.1093/cid/cis762.
- [3] Barbieri D, De Brito T, Hoshino S, Nascimento OB, Martins Campos JV, Quarentei G, et
al. Giardiasis in childhood. Absorption tests and biochemistry, histochemistry, light and
electron microscopy of jejunal mucosa. *Arch Dis Child* 1970;45:466–72.
- 80 [4] Halliez MCM, Buret AG. Extra-intestinal and long term consequences of Giardia
duodenalis infections. *World J Gastroenterol WJG* 2013;19:8974–85.
doi:10.3748/wjg.v19.i47.8974.