

2015

# MCM2 and chromogranin are markers of serrated polyp progression

Danielle Fortuna, MD

*Department of Surgery, Thomas Jefferson University, danielle.fortuna@jefferson.edu*


Bruce M. Boman, MD, PhD

*Thomas Jefferson University, Bruce.Boman@jefferson.edu*

Juan P. Palazzo, MD

*Thomas Jefferson University, Juan.Palazzo@jefferson.edu*

## [Let us know how access to this document benefits you](#)

Follow this and additional works at: <http://jdc.jefferson.edu/pacbresidentposters> Part of the [Medical Anatomy Commons](#), [Medical Cell Biology Commons](#), and the [Medical Pathology Commons](#)

### Recommended Citation

Fortuna, MD, Danielle; Boman, MD, PhD, Bruce M.; and Palazzo, MD, Juan P., "MCM2 and chromogranin are markers of serrated polyp progression" (2015). *Pathology, Anatomy and Cell Biology Resident's Posters*. Paper 21.<http://jdc.jefferson.edu/pacbresidentposters/21>

## Background

Serrated polyp (SP) pathophysiology is of great interest, and examination of colonic stem cell (SC) differentiation and crypt cell proliferation can provide insight into the natural progression of SPs. In normal colonic mucosa, SCs can differentiate into neuroendocrine cells (NEC) that reside in the crypt-base stem cell niche. SCs also produce rapidly proliferating cells located in the proliferative compartment in the lower half of the crypt.

Staining for **minichromosome maintenance 2 (MCM2)** protein, a component of the DNA helicase involved in the initiation of DNA replication, is a marker of cellular proliferation in all cell cycle phases. **Chromogranin (CGA)** is a marker of differentiated NECs. Using MCM2 and CGA, we examined these cell types in SPs: hyperplastic polyps (HP) and sessile serrated adenomas (SSA) with and without cytologic dysplasia.

## Objectives

Using immunohistochemistry for MCM2 and CGA:

- Examine the proliferative compartment of SPs
- Assess neuroendocrine cell population in SPs

Goal: Identify potential trends in the proliferative and the neuroendocrine cell compartments in SP progression compared to the background normal mucosa

## Methods

Immunohistochemistry was performed on 46 paraffin-embedded SPs (11 HPs, 31 SSAs, 4 SSAs with dysplasia) and sections of normal colon using anti-MCM2 antibody (Santa-Cruz, Dallas, TX; 1:200 dilution) and CGA (Dako, Carpinteria, CA; 1:10 dilution). Staining positivity and distribution in both SP and adjacent normal colonic mucosa was assessed.

*Expected proliferation/differentiation patterns in normal colon:*

- positive nuclear MCM2 staining of the lower portion of the colonic crypt
- positive cytoplasmic CGA staining of scattered cells in the lower portion of the colonic crypt

**MCM2** demonstrated 3 major categories of staining:

- *expected/normal*: staining limited to lower portion of crypt or slightly expanded
- *focal*: non-continuous full crypt staining
- *diffuse*: continuous full crypt staining

**CGA** demonstrated the following staining patterns:

- present (individual scattered cells)
- absent (non-continuous or continuous)

## Results

**Patterns of MCM2 staining in SPs:** 100% of HPs, SSAs, and SSAs with dysplasia showed some degree of positive MCM2 staining throughout the entire crypt (focal/diffuse full crypt staining). Diffuse full crypt proliferation was seen in 100% of SSAs with dysplasia, 81% of SSAs, and 64% of HPs. Surface staining was focal/absent in all polyps.

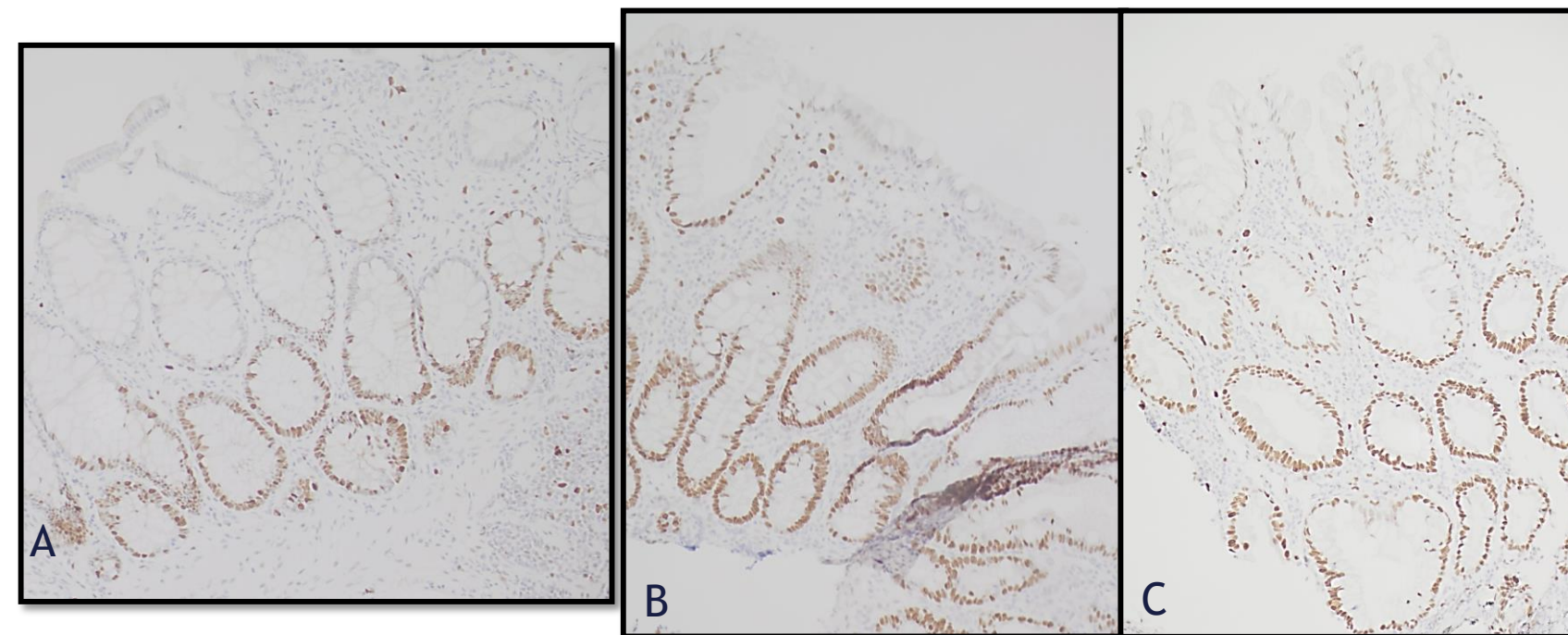


Figure 1A-C, MCM2. Normal colonic mucosa (A) compared to full crypt staining in HP (B) and SSA (C).

**Patterns of MCM2 staining in background normal mucosa:** When present, areas of histologically normal mucosa adjacent to SPs showed aberrant, full crypt staining of MCM2 in 100% of SSAs with dysplasia and 58% of SSAs. Adjacent normal mucosa of HPs showed the expected/normal pattern.

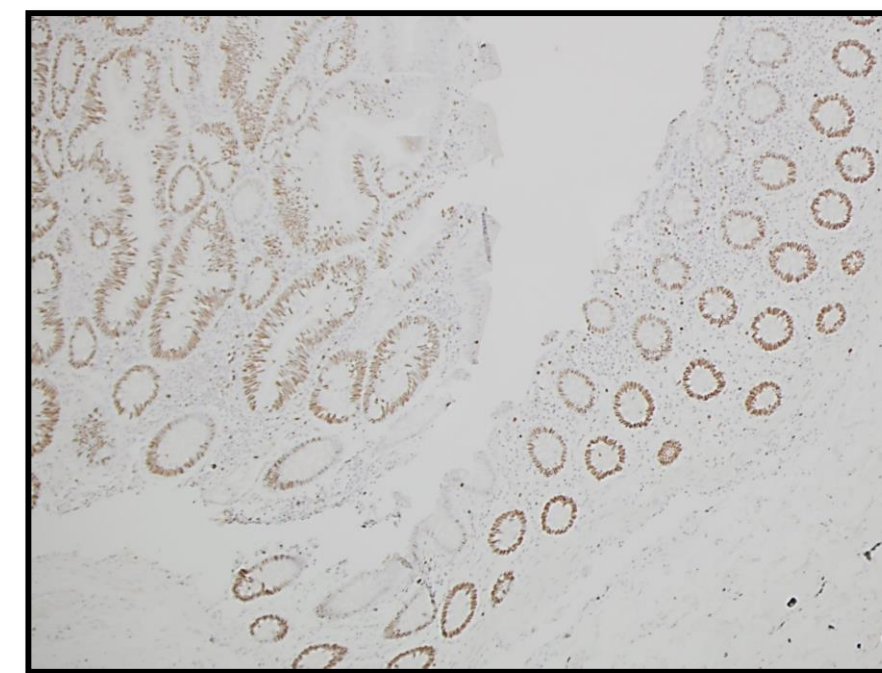


Figure 2, MCM2. SSA with dysplasia (left) and adjacent normal mucosa (right) showing diffuse MCM2 staining.

**Patterns of CGA staining in SPs:** HPs and SSAs showed scattered CGA-positive cells in the lower crypt (>5 cells per crypt base). 100% of SSAs with dysplasia and a small subset of SSAs (30%), showed rare to absent CGA positive cells.

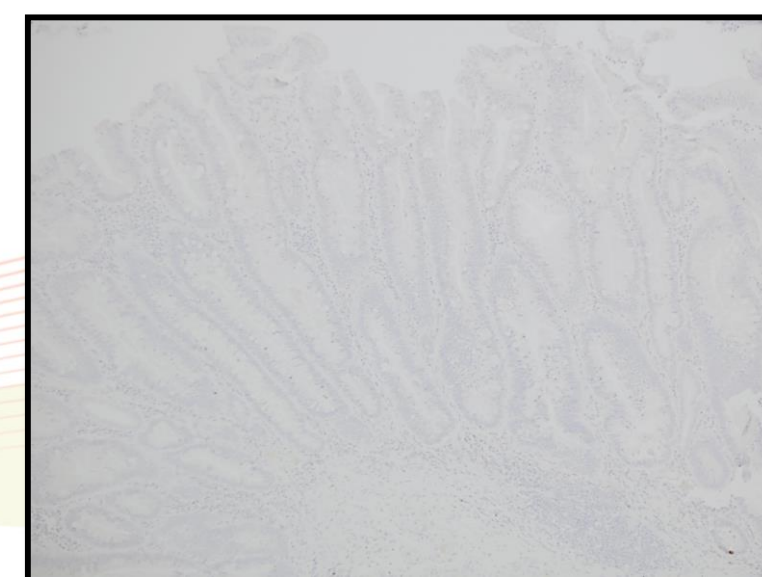


Figure 3. CGA, SSA with dysplasia shows rare to absent CGA positive cells.

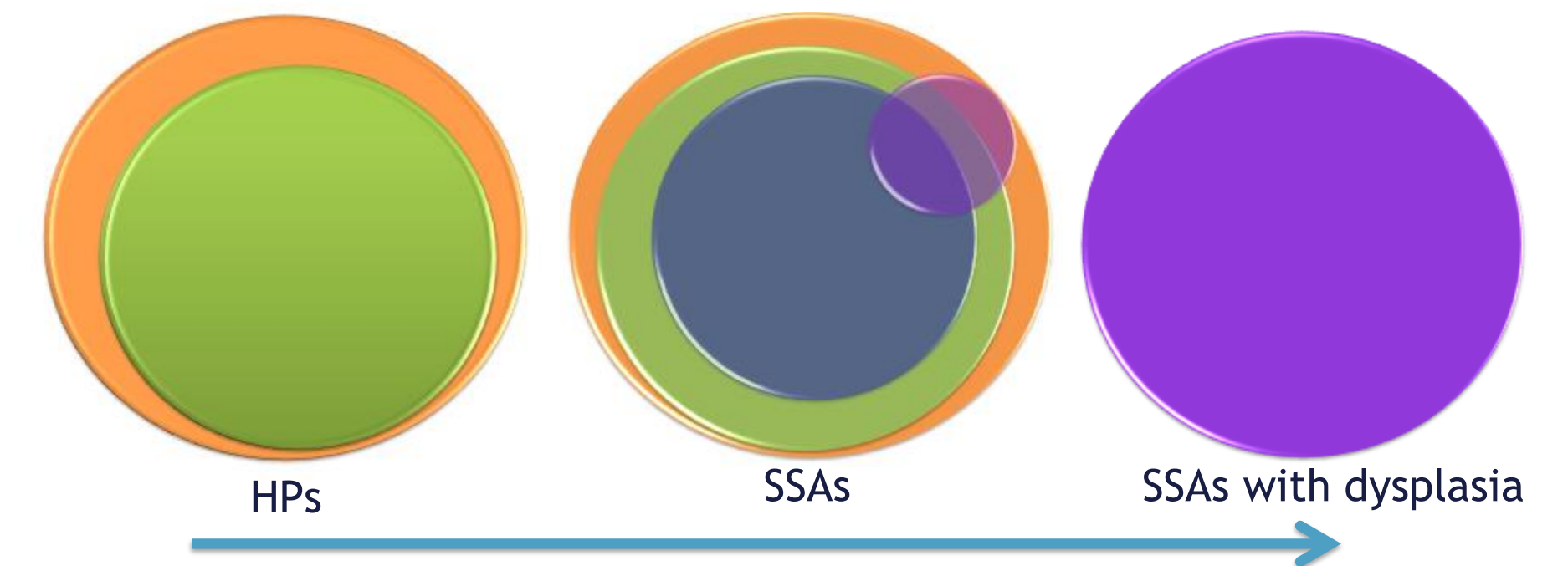
## Results

Graphic and tabular representation of MCM2 and CGA staining patterns in SPs

Table 1. Observed MCM2, CGA staining patterns

MCM2 and CGA staining patterns	HP	SSA	SSA with dysplasia
☑full crypt proliferation (focal or diffuse)	11	31	4
☑diffuse full crypt proliferation	7	25	4
☑diffuse full crypt proliferation of both polyp and background normal colon	0	13	4
☑absence of CGA (focal or diffuse)	0	10	4
☑diffuse full crypt proliferation of both polyp and background normal colon	0	4	4
☑absence of CGA	0	4	4
Total number of polyps in group	11	31	4

Diagram 1. Observed MCM2 and CGA staining patterns. (Colors correspond to categories in Table 1; circle size approximates relative proportion within given group.)



**Interpretation:** SP progression may include extension of the proliferative compartment (orange and green), expansion of proliferative changes to surrounding normal mucosa (blue), and loss of NECs (purple).

## Conclusions

- Expansion of the proliferation compartment and neuroendocrine cell loss are components of SP development and progression.
- HPs and SSAs show a similar proliferative profile.
- Aberrant cell proliferation cell staining patterns in the normal colonic mucosa adjacent to SSAs with dysplasia (and a subset of SSAs) suggest that the colonic microenvironment may play a significant role in SP progression.
- Continued exposure/stimulation from a particular microenvironment may promote SP formation and predisposition to malignancy.