

9-1-2016

# Bone mineral density in mucopolysaccharidosis IVB

Francyne Kubaski

*Nemours/Alfred I. duPont Hospital for Children; University of Delaware*

Heidi H. Kecskemethy

*Nemours/Alfred I. duPont Hospital for Children*

Howard T. Harcke

*Thomas Jefferson University; Nemours/Alfred I. duPont Hospital for Children, howard.harcke@jefferson.edu*

Shunji Tomatsu

*Nemours/Alfred I. duPont Hospital for Children; University of Delaware*

## [Let us know how access to this document benefits you](#)

Follow this and additional works at: <http://jdc.jefferson.edu/radiologyfp>Part of the [Radiology Commons](#)

### Recommended Citation

Kubaski, Francyne; Kecskemethy, Heidi H.; Harcke, Howard T.; and Tomatsu, Shunji, "Bone mineral density in mucopolysaccharidosis IVB" (2016). *Department of Radiology Faculty Papers*. Paper 43. <http://jdc.jefferson.edu/radiologyfp/43>

This Article is brought to you for free and open access by the Jefferson Digital Commons. The Jefferson Digital Commons is a service of Thomas Jefferson University's [Center for Teaching and Learning \(CTL\)](#). The Commons is a showcase for Jefferson books and journals, peer-reviewed scholarly publications, unique historical collections from the University archives, and teaching tools. The Jefferson Digital Commons allows researchers and interested readers anywhere in the world to learn about and keep up to date with Jefferson scholarship. This article has been accepted for inclusion in Department of Radiology Faculty Papers by an authorized administrator of the Jefferson Digital Commons. For more information, please contact: [JeffersonDigitalCommons@jefferson.edu](mailto:JeffersonDigitalCommons@jefferson.edu).



## Bone mineral density in mucopolysaccharidosis IVB



Francyne Kubaski <sup>a,c,1</sup>, Heidi H. Kecskemethy <sup>a,b,\*</sup>, H. Theodore Harcke <sup>a,d</sup>, Shunji Tomatsu <sup>a,c</sup>

<sup>a</sup> Department of Biomedical Research, Nemours/Alfred I. duPont Hospital for Children, 1600 Rockland Road, Wilmington, DE 19803, USA

<sup>b</sup> Department of Medical Imaging, Nemours/Alfred I. duPont Hospital for Children, 1600 Rockland Road, Wilmington, DE 19803, USA

<sup>c</sup> Department of Biological Sciences, University of Delaware, 118 Wolf Hall, Newark, DE 19716, USA

<sup>d</sup> Department of Radiology and Pediatrics, Jefferson Medical College, Thomas Jefferson University, 901 Walnut St, Philadelphia, PA 19107, USA

### ARTICLE INFO

#### Article history:

Received 1 August 2016

Accepted 1 August 2016

Available online 8 August 2016

#### Keywords:

Mucopolysaccharidosis type B

Bone mineral density

Dual-energy X-ray absorptiometry

Lateral distal femur dual-energy X-ray absorptiometry

### ABSTRACT

To date, the only published reports of bone mineral density (BMD) in MPS IV involve patients with MPS IVA; no reports exist describing BMD for MPS IVB. In this prospective study of BMD in three patients with MPS IVB, BMD was acquired by dual-energy X-ray absorptiometry (DXA) at whole body (WB), lumbar spine (LS), and lateral distal femur (LDF). Functional abilities, ambulatory status, medical history, and height z-score were evaluated. Three patients with MPS IVB (two females), aged 17.7, 31.4 and 31.7 years, were evaluated. Every patient was ambulatory and one sustained two fractures caused by trauma. Whole body and hip DXA scans were technically invalid in every patient due to the presence of prosthetic hip hardware. Lumbar spine was valid in only 1 patient due skeletal abnormalities, and was normal (Z-score of  $-0.8$ ). The LDF was valid in every patient and was low at all three regions of interest: average LDF z-scores were  $-3.1$  (range,  $-2.9$  to  $-3.6$ ),  $-2.3$  (range,  $-2.0$  to  $-2.5$ ), and  $-2.1$  (range,  $-2.0$  to  $-2.3$ ) for region 1–region 3, respectively. Patients with MPS IVB have low BMD of the lower extremities even with full-time ambulation. Routine body sites to measure by DXA were problematic; hip and WB were invalid due to artifact, and LS had limited utility. The LDF was the only body site consistently available on all patients. Patients did not experience low-energy fractures despite low BMD.

© 2016 Published by Elsevier Inc. This is an open access article under the CC BY-NC-ND license (<http://creativecommons.org/licenses/by-nc-nd/4.0/>).

### 1. Introduction

Mucopolysaccharidosis IVB (MPS IVB, Morquio syndrome type B) (OMIM#253010) is an autosomal recessive inherited metabolic disorder caused by deficiency of  $\beta$ -galactosidase (GLB1) [1]. This hydrolase is responsible for the catabolism of terminal  $\beta$ -galactose residues as keratan sulfate (KS) and GM1 ganglioside [2,3]. Keratan sulfate accumulation in patients with MPS IVB causes skeletal dysplasia, growth retardation, keratansulfaturia, corneal clouding, and impaired cardiac function [2,4]. The incidence of MPS IV is variable among different populations (1 per 75,000 in Northern Ireland to 1 per 640,000 in Western Australia) [5,6]. To date more than 180 mutations have been described on GLB1 (HGMD) [7], but fewer mutations are associated with the clinical phenotype of MPS IVB [2,4,8,9]. There is no cure or established treatment for MPS IVB.

**Abbreviations:** BMD, bone mineral density; DXA, dual energy X-ray absorptiometry; GAGs, glycosaminoglycans; GLB1,  $\beta$ -galactosidase; HAZ, height-adjusted Z-score; HGMD, The Human Gene Mutation Database; KS, keratan sulfate; LDF, lateral distal femur; LS, lumbar spine; MPS IVB, mucopolysaccharidosis type IV B; NHANES, National Health and Nutrition Survey; WB, whole body.

\* Corresponding author at: Nemours Biomedical Research, Nemours/Alfred I. duPont Hospital for Children, 1600 Rockland Rd., Wilmington, DE 19899-0269, USA.

E-mail address: [Heidi.Kecskemethy@nemours.org](mailto:Heidi.Kecskemethy@nemours.org) (H.H. Kecskemethy).

<sup>1</sup> The first two authors should be regarded as joint first authors.

Bone and cartilage are the main tissues affected in patients with MPS IVB, resulting in skeletal dysplasia. However, skeletal and cartilage involvement are not only caused by the primary GAG accumulation but also by disruption of several secondary mechanisms and pathways as: signaling transduction pathways, regulation of humoral factors (chemokines and cytokines), endocytosis, autophagy, apoptosis, oxidative stress, innate and adaptive immune responses [10].

The growth deficits and bone deformities seen in MPS IVB are less severe than those observed in MPS IVA, resulting in a milder phenotype with greater functional abilities. Lack of ambulation is known to negatively impact BMD of the lateral distal femur (LDF) in patients with other medical conditions including cerebral palsy, Duchenne muscular dystrophy, and spina bifida [11–15]. A strong association was demonstrated between low BMD at the LDF and fracture history in children with cerebral palsy and Duchenne muscular dystrophy [16]. Several reports have demonstrated low BMD in MPS IVA [17–20]. One of those reports [17] employed a height adjustment methodology to the DXA results, the HAZ method described by Zemel [21]. The appropriateness of using the HAZ method for children with skeletal dysplasia and who have severe height deficits is questionable [20,22]. Kecskemethy and colleagues reported low BMD of the lower extremities (LDF DXA) in patients with MPS IVA, indicating that the LDF, due to the presence of metallic hardware, intolerance of required position for scan acquisition,

and spine abnormalities, is the most accurate and feasible site to measure BMD in MPS IVA [20].

To date, no reports exist describing BMD for MPS IVB; this is the first report of BMD in MPS IVB. We describe BMD measured by DXA at standard body sites and the LDF [23,24], and examine clinical correlates (anthropometric measures, medical and fracture history, and ambulation). Investigation of bone mineral density (BMD) in patients with MPS IVB contributes to understanding of disease pathology.

## 2. Methods

### 2.1. Subjects

This cross-sectional study prospectively evaluated three patients with MPS IVB (two females) ranging in age from 17.7 to 31.7 years (mean age 26.9 years) who were enrolled in this study at the Nemours/Alfred I. duPont Hospital for Children (AIDHC). Patients were diagnosed biochemically by enzyme assay. Functional abilities, medical history, Tanner score, and height Z-score were reviewed. Radiographs of the lateral spine were used to aid in correct region of interest placement on the lumbar spine (LS) DXA. Age and gender-matched norms were used to calculate Z-scores. Height and weight measures were obtained and height Z-scores were calculated using National Health and Nutrition Survey (NHANES) LMS tables (CDC 2000, accessed 9/5/15) [25]. The maximum age available (19.9 years) was used for patients over this age. Informed consent was applied and the study was approved by the Institutional Review Board of the Institution (338578).

### 2.2. BMD assessments

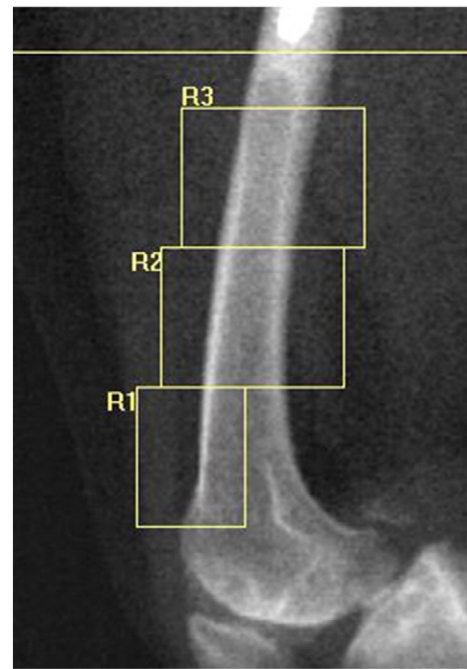
Bone mineral density was assessed by DXA at the whole body (WB), lumbar spine LS, and LDF using a Hologic Discovery A model bone densitometer (Hologic, Bedford, MA, USA) located in the AIDHC Medical Imaging Department. All scans were acquired and analyzed by the same DXA technologist. The DXA Z-scores were calculated based on age and gender-matched manufacturer-provided norms and published normative values for the LDF [21]. The oldest normative LDF values available (18 years) were used for the two patients older than 18 years.

The LDF scans were analyzed for three distinct regions of interest, described by Henderson et al., to assess bone density in different types of bone [24]. Region 1 (R1), the most distal region, is predominantly trabecular bone; region 2 (R2) is a mix of trabecular and cortical bone; and region 3 (R3), the most proximal region, is primarily cortical bone (Fig. 1). The LDF BMD was assessed bilaterally, left and right femur BMD values were averaged, and Z-scores were calculated. Abnormal DXA results were defined as more than two standard deviations (SD) below the normal mean, expressed as Z-score  $< -2$  [26]. Radiographs of the LS, including inter-vertebral assessment by DXA, were reviewed by a radiologist and were used to aid in correct region of interest placement on the LS DXA.

## 3. Results

Three Caucasian patients (two females) with MPS IVB were evaluated; aged 17.7, 31.4 and 31.7 years. Mean height was 131.2 cm (average Z-score  $-5.4$ ), and mean weight was 39.9 kg (average Z-score  $-4.0$ ) (Table 1). All patients were ambulatory: two walked independently without any aids and one used a walker and occasionally (once per month) used a wheelchair. One patient sustained two fractures (arm and femur) due to trauma (fall and motor vehicle accident, respectively). All three subjects were post-pubescent.

The presence of metallic artifact from prosthetic hips on every WB scan precluded valid assessment of the results (Fig. 2). Metal is interpreted as bone on DXA and therefore the presence of metal artificially elevates BMD. Two of the three patients had vertebral overlap at T12 and L1, invalidating LS scan results. The one technically valid LS



**Fig. 1.** The LDF DXA scan is analyzed for three regions of interest: Region 1 (anterior distal metaphysis) is essentially trabecular bone, region 2 (metadiaphysis) is composed of both trabecular and cortical bone, region 3 (diaphysis) is composed primarily of cortical bone. There has been proximal femoral surgery with the distal end of the metal prosthesis visible above region 3. LDF DXA, lateral distal femur dual-energy X-ray absorptiometry; R1, region 1; R2, region 2; R3, region 3.

scan resulted in a normal BMD Z-score of  $-0.8$ , but wedging of L3, which can elevate LS BMD DXA results, was noted [27] (Fig. 3). The LDF yielded technically valid results for all patients, and Z-scores were low at all three regions of interest with average Z-scores of  $-3.1$ ,  $-2.3$ , and  $-2.1$  at R1–R3, respectively (Fig. 4). Every region of interest for all measurements (both femurs) was consistently below normal.

## 4. Discussion

In this study, we evaluated and reported the BMD of three patients with MPS IVB. The skeletal abnormalities seen in patients with MPS IVB are primarily caused by the accumulation of KS. The exact mechanism of low BMD in MPS IVB is still unknown, although as undegraded substrate accumulates, normal bone and cartilage formation is disrupted leading to impaired homeostasis which could affect BMD [10,28]. Low BMD has also been reported in other lysosomal disorders [28] (e.g. Gaucher's) and skeletal dysplasias [29] (e.g. achondroplasia and hypochondroplasia).

In general, patients with MPS IVB exhibit a less severe phenotype than those with MPS IVA. This fact is evidenced by greater functional ability (all patients were ambulatory) and less severe growth deficits in height resulting in an average height Z-score of  $-5.4$ , compared with a group of patients with MPS IVA where nine of 18 patients were fully ambulatory and had an average height Z-score of  $-7.4$  [20].

Ambulation is preservative of bone density as demonstrated by studies examining DXA of the lower extremities in patients with cerebral palsy, Duchenne muscular dystrophy, and spina bifida [11–16]. Henderson et al. described a strong association between fracture and LDF BMD in children with Duchenne muscular dystrophy and cerebral palsy [16]. All of our patients were essentially full-time ambulators (one used a walker and a wheelchair once per month). Despite this ambulation, the LDF BMD was uniformly below normal in all three patients. There was no history of non-traumatic fracture, often seen in patients with low BMD of the lower extremities. It is impossible to examine

**Table 1**  
Clinical data for MPS IVB patients.

Patient ID	1	2	3
Age (years)	17.7	31.4	31.7
Gender	F	M	F
Height (cm)	129.5	137.2	127
Height Z-score	-5.2	-5.4	-5.5
Weight (kg)	33.2	50	36.4
Weight Z-score	-5.3	-2.5	-4.2
LS BMD (gm/cm <sup>2</sup> )	0.915	Invalid	Invalid
LS BMD Z-score	-0.8	n/a	n/a
Technical note	Wedging L3	L1–T12 overlap	L1–T12 overlap
LDF R1 BMD (gm/cm <sup>2</sup> )	0.605	0.738	0.6775
LDF R1 Z-score	-3.6	-2.9	-2.9
LDF R2 BMD (gm/cm <sup>2</sup> )	0.886	0.986	0.883
LDF R2 Z-score	-2.4	-2.0	-2.5
LDF R3 BMD (gm/cm <sup>2</sup> )	0.990	1.024	0.961
LDF R3 Z-score	-2.0	-2.1	-2.3
Fracture history? Y/N	N	Y × 2 (trauma)	N
Fracture details	n/a	L arm from fall; L femur from car accident	n/a
Ambulation details	Uses walker; manual WC 1×/month	Independent walker - no assistive devices	Independent walker - no assistive devices

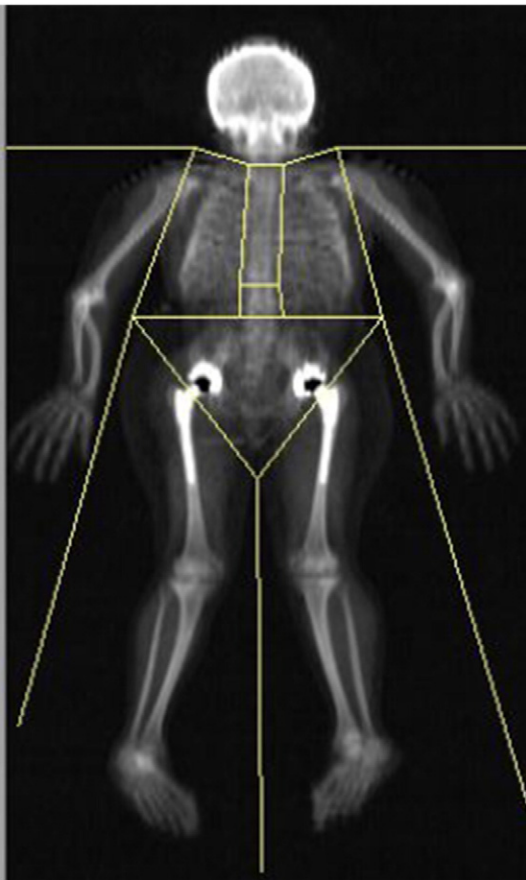
LS, lumbar spine; BMD, bone mineral density; LDF, lateral distal femur; R1, region 1; R2, region 2; R3, region 3; F, female; WC, wheelchair; M, male; L, left; MVA, motor vehicle accident.

the relationship between BMD and fracture in this limited number of patients.

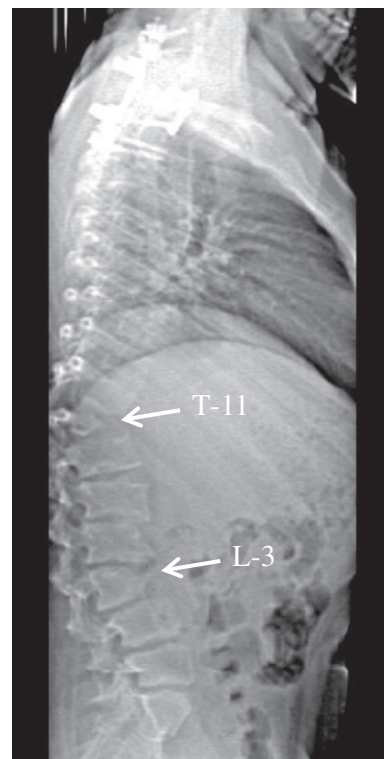
While DXA is the most commonly used and clinically available technology to assess BMD, there are known limitations with a two-dimensional assessment of a three-dimensional object, like bone. Dual-energy X-ray absorptiometry is an areal measurement that uses values for area and bone mineral content, taken from a two-dimensional image to determine BMD in gm/cm<sup>2</sup>—this is frequently designated areal BMD (aBMD). Abnormally-shaped vertebrae that are

wedge-shaped or beaked are common in MPS IVB (Fig. 3). Utilizing DXA to measure atypically shaped vertebrae can yield variable aBMD results [27]. This is a limitation of using the LS DXA to assess BMD in patients with MPS IV(A and B). Careful review of LS radiographs should be made to determine both the technical validity and correct identification of vertebrae on the LS DXA scan when assessing BMD in MPS IVB. Only one of three LS DXA scans in this study was valid, and still an elevation in overall LS BMD from wedging noted at L-3 may have resulted.

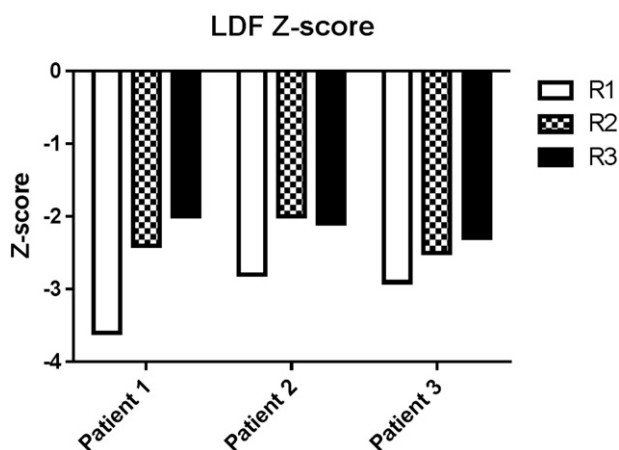
While WB DXA scans could reliably be acquired, their validity was compromised by the presence of metallic artifact present with hip replacements (Fig. 4). The LDF measurement was established as an



**Fig. 2.** Metallic prostheses used in bilateral hip replacements artificially elevate BMD on WB DXA. Every patient had artificial hips, invalidating WB DXA results. BMD, bone mineral density; WB DXA, whole body dual-energy X-ray absorptiometry.



**Fig. 3.** Lateral spine radiograph used for correct identification of lumbar vertebrae for LS DXA. Note the dysmorphic vertebral bodies with anterior wedging of L-3 and a hypoplastic, wedge-shaped body at T-11. These result in focal areas of kyphosis. There has been spinal fusion in the cervico-thoracic region using metallic fixation. LS DXA, lateral spine dual-energy X-ray absorptiometry.



**Fig. 4.** Lateral distal femur DXA BMD Z-scores in three patients with MPS IVB. LDF, lateral distal femur; DXA, dual energy X-ray absorptiometry; BMD, bone mineral density; MPS, mucopolysaccharidosis; R1, region 1; R2, region 2; R3, region 3.

alternative measurement site for patients with joint contractures, hip dislocation, positioning limitations, or metallic hardware [24]. Only the LDF DXA consistently offered technically valid DXA results. This scan was easily obtained and well-tolerated by patients with MPS IVB.

Patient height and bone size are known to affect DXA results and for that reason adjustments are sometimes recommended to DXA BMD results [26]. The Height-Adjusted Z-score (HAZ) method described by Zemel et al. [21], has been applied to BMD results of patients with different types of MPS, resulting in normalization of the LS and WB results [17,30]. We do not adjust our one valid LS result by using the HAZ method because of the large height deficits seen in our patients with MPS IVB (Table 1). The HAZ method of correcting for height deficit has not been validated for the LDF DXA.

The HAZ method was developed for children with height deficits, aged 6–18 years, who have normal skeletal morphometry. In the 2010 paper describing the HAZ method, the shortest height used was  $-2.6$  SD below the age-matched controls [31]. Polgreen and colleagues [22] describe the use of the HAZ method in a group of 24 children with MPS I ( $n = 11$ ), II ( $n = 9$ ) or VI ( $n = 4$ ); they reported that the HAZ method was valid for the LS, but overestimated WB results, likely due to overall atypical bone geometry seen in MPS. While the HAZ method was valid at the LS in this group of patients, it is important to note that patients with MPS I and II have fewer spinal skeletal deformities than are seen in MPS IV(A or B). The skeletal abnormalities and height deficits seen in MPS VI are more similar to MPS IV, but the average height Z-score in the MPS VI subjects was  $-4.3 (\pm 0.6)$ , whereas the average height Z-score in our study was  $-5.4 (\pm 0.2)$ . The HAZ method applied to the one technically valid LS in this study resulted in a possible overcorrection: the unadjusted Z-score was  $-0.8$  and after adjustment, became  $+2.1$ . It would appear that using the HAZ adjustment might have resulted in an overcorrection of results. The maximum height deficit acceptable for the HAZ method is unknown. For patients with severe skeletal conditions affecting bone morphometry and severe height deficits, height-based adjustments of DXA results should be used with caution.

This study has several limitations including a limited sample size of three patients. MPS IVB is a rare condition and BMD in MPS IVB has not been described in the literature. Another limitation of this study is that our evaluation of bone density was limited to DXA, which is an areal measure. The oldest age available for the LDF DXA normative values is 18 years. The mean age of our study population was 26.9 years (range, 17.7–31.7 years). However, peak bone mass in the typical population is thought to be acquired between 20 and 30 years of age depending on gender and body site [32]. We know neither the

age of peak bone mass accrual in MPS IVB, nor the age at which peak bone is acquired at the distal femur.

In conclusion, despite these limitations, we have presented novel findings about BMD in patients with MPS IVB. We evaluate the technical validity of the DXA scans acquired at different body sites and present BMD findings at an alternative DXA site – the LDF. Images were evaluated and interpreted by a pediatric radiologist ensuring the accuracy of our findings in the presence of potentially confusing skeletal anatomy.

### Competing interests

The authors declare that they have no competing interests.

### Contributions to the project

Heidi Kecskemethy was responsible for the planning, conduct, data acquisition and analysis, and reporting of the work described in this article.

Francyne Kubaski was responsible for the data analysis and reporting of the work described in this article.

Shunji Tomatsu was involved with the planning, conduct, and reporting of the work described in this article.

Theodore Harcke was involved with planning, conduct, and reporting of work described in this article.

### Acknowledgments

This work was supported by the Department of Medical Imaging at the Nemours/Alfred I. duPont Hospital for Children. Francyne Kubaski was supported by Conselho Nacional de Desenvolvimento Científico e Tecnológico from Brazil (CNPq). Work by Shunji Tomatsu was supported in part by grants from the Austrian MPS Society grant number 3212482005, The Bennett Foundation grant number 4399, and International Morquio Organization (Carol Ann Foundation) grant number 3212482001, as well as by an Institutional Development Award (IDeA) from the National Institute of General Medical Sciences of NIH grant numbers RO1 HD065767 and RO3 HD064749. The content of the article is solely the responsibility of the authors and does not necessarily represent the official views of the National Institutes of Health or other sponsors. We also wish to thank the patients and families involved in the study.

### References

- [1] J.S. O'Brien, E. Gugler, A. Giedion, U. Wiessmann, N. Herschkowitz, C. Meier, J. Leroy, Spondyloepiphyseal dysplasia, corneal clouding, normal intelligence and acid beta-galactosidase deficiency, *Clin. Genet.* 9 (1976) 495–504.
- [2] Y. Suzuki, A. Oshima, E. Namba,  $\beta$ -Galactosidase deficiency ( $\beta$ -galactosidosis) GM1 gangliosidosis and Morquio B disease, in: C.R. Scriver, A.L. Beaudet, W.S. Sly, D. Valle (Eds.), *The Metabolic and Molecular Bases of Inherited Disease*, McGraw Hill, New York 2001, pp. 3775–3809.
- [3] A. Caciotti, M.A. Donati, T. Bardelli, A. d'Azzo, G. Massai, L. Luciani, E. Zammarchi, A. Morrone, Primary and secondary elastin-binding protein defects leads to impaired elastogenesis in fibroblasts from GM1-gangliosidosis patients, *Am. J. Pathol.* 165 (2005) 1689–1698.
- [4] A. Caciotti, S.C. Garman, Y. Rivera-Cólon, E. Procopio, S. Catarzi, L. Ferri, C. Guido, P. Martell, R. Parini, D. Antuzzi, R. Battini, M. Sibilio, A. Simonati, E. Fontana, A. Salviati, G. Akinci, C. Cereda, C. Dionisi-Vici, F. Deodato, A. d'Amico, A. d'Azzo, E. Bertini, M. Filocamo, M. Scarpa, M. di Rocco, C.J. Tiff, F. Ciani, S. Gasperini, E. Pasquini, R. Guerrini, M.A. Donati, A. Morrone, GM1 gangliosidosis and Morquio B disease: an update on genetic alterations and clinical findings, *Biochim. Biophys. Acta* 1812 (2011) 782–790.
- [5] J. Nelson, Incidence of mucopolysaccharidoses in Northern Ireland, *Hum. Genet.* 101 (1997) 355–358.
- [6] J. Nelson, J. Crowhurst, B. Carey, L. Greed, Incidence of mucopolysaccharidoses in Western Australia, *Am. J. Med. Genet. A* 123A (2003) 310–313.
- [7] HGMD-The Human Gene Mutation Database Available at: <http://www.hgmd.cf.ac.uk/ac/index.php> Accessed on: January 8, 2016.
- [8] A. Oshima, K. Yoshida, M. Shimamoto, Y. Fukuhura, H. Sakuraba, Y. Suzuki, Human beta-galactosidase gene mutations in morquio B disease, *Am. J. Hum. Genet.* 49 (1991) 1091–1093.
- [9] R. Santamaria, A. Chabás, M.J. Coll, C.S. Miranda, L. Vilageliu, D. Grinberg, Twenty-one novel mutations in the GLB1 gene identified in a large group of GM1-

- gangliosidosis and Morquio B patients: possible common origin for the prevalent p.R59H mutation among gypsies, *Hum. Mutat.* 27 (2006) 1060.
- [10] L.A. Clarke, Pathogenesis of skeletal and connective tissue involvement in the mucopolysaccharidoses: glycosaminoglycan storage is merely the instigator, *Rheumatology* 50 (2011) v13–v18.
- [11] R.E. Haas, H.H. Kecsckemethy, M.A. Lopiccolo, J. Hossain, R.T. Dy, S.J. Bachrach, Lower extremity bone mineral density in children with congenital spinal dysfunction, *Dev. Med. Child Neurol.* 54 (2012) 1133–1137.
- [12] H.T. Harcke, H.H. Kecsckemethy, D. Conklin, C.P. McKay, Assessment of bone mineral density in Duchenne muscular dystrophy using the lateral distal femur, *J. Clin. Neuromuscul. Dis.* 8 (2006) 1–6.
- [13] R.C. Henderson, R.K. Lark, M.J. Gurka, G. Worley, E.B. Fung, M. Conaway, V.A. Stallings, R.D. Stevenson, Bone density and metabolism in children and adolescents with moderate to severe cerebral palsy, *Pediatrics* 110 (1Pt 1) (2002) e5.12.
- [14] E.A. Szalay, A. Cheema, Children with spina bifida are at risk for low bone density, *Clin. Orthop. Relat. Res.* 469 (2002) 2153–2157.
- [15] R. Grossberg, M.G. Blackford, H.H. Kecsckemethy, R. Henderson, M.D. Reed, Longitudinal assessment of bone growth and development in a facility-based population of young adults with cerebral palsy, *Dev. Med. Child Neurol.* 57 (11) (Nov 2015) 1064–1069, <http://dx.doi.org/10.1111/dmcn.12790> (Epub 2015 May 6. PMID: 25951240).
- [16] R.C. Henderson, L.M. Berglund, R. May, B.S. Zemel, R.J. Grossberg, J. Johnson, K. Plotkin, R.D. Stevenson, E. Szalay, B. Wong, H.H. Kecsckemethy, H.T. Harcke, The relationship between fractures and DXA measures of BMD in the distal femur of children and adolescents with cerebral palsy or muscular dystrophy, *J. Bone Miner. Res.* 25 (2010) 520–526.
- [17] H.Y. Lin, S.C. Shih, C.K. Chuang, M.R. Chen, D.M. Niu, S.P. Lin, Assessment of bone mineral density by dual energy x-ray absorptiometry in patients with mucopolysaccharidoses, *Orphanet. J. Rare Dis.* 8 (2013) 71.
- [18] C. Adam, A. Rakei, L.G. Ste-Marie, Full description of bone metabolism in a case of Morquio-Brailsford syndrome, *The Endocrine Society's 94th Annual Meeting and Expo.* June 23–26. Houston, TX. Presentation Number: SUN-351, 2012.
- [19] H.M. Koura, A. El-Katoury, N.I. Abdallah, H. El-Bassyouni, D.F. Ayoub, R.I. Bassiouni, Bone mineral density in Egyptian children with mucopolysaccharidoses, *Res. J. Med. Med. Sci.* 4 (2009) 100–106.
- [20] H.H. Kecsckemethy, F. Kubaski, H.T. Harcke, S. Tomatsu, Bone mineral density in MPS IV A (Morquio syndrome type A), *Mol. Genet. Metab.* 117 (2016) 144–149.
- [21] B.S. Zemel, V.A. Stallings, M.B. Leonard, D.R. Paulhamus, H.H. Kecsckemethy, H.T. Harcke, R.C. Henderson, Revised pediatric reference data for the lateral distal femur measured by Hologic Discovery/Delphi dual energy X-Ray absorptiometry, *J. Clin. Densitom.* 12 (2009) 207–218.
- [22] L.E. Polgreen, W. Thomas, E. Fung, D. Viskochil, D.A. Stevenson, J. Steinberger, P. Orchard, C.B. Whitley, K.E. Ensrud, Low bone mineral content and challenges in interpretation of dual-energy x-ray absorptiometry in children with mucopolysaccharidosis types I, II, and VI, *J. Clin. Densitom.* 17 (2014) 200–206.
- [23] H.T. Harcke, A. Taylor, S. Bachrach, F. Miller, R.C. Henderson, Lateral femoral scan: an alternative method for assessing bone mineral density in children with cerebral palsy, *Pediatr. Radiol.* 28 (1998) 241–246.
- [24] R.C. Henderson, R.K. Lark, J.E. Newman, H. Kecsckemethy, E.B. Fung, J.B. Renner, H.T. Harcke, Pediatric reference data for dual X-ray absorptiometric measures of normal bone density in the distal femur, *AJR Am. J. Roentgenol.* 178 (2002) 439–443.
- [25] Centers for Disease Control and Prevention, National Center for Health Statistics LMS Parameters for Girls & Boys: Height for Age, National Health and Nutrition Survey (NHANES), Atlanta, 2000 <http://www.cdc.gov/growthcharts/zscore.htm> Accessed 15 Sept 2015.
- [26] N.J. Crabtree, A. Arabi, L.K. Bachrach, M. Fewtrell, G.E. Fuleihan, H.H. Kecsckemethy, N. Jaworski, C.M. Gordon, Dual-energy X-ray absorptiometry interpretation and reporting in children and adolescents: the revised 2013 ISCD pediatric official positions, *J. Clin. Densitom.* 17 (2014) 225–242.
- [27] S.L. Bonnick, A.L. Lewis, *Skeletal anatomy in densitometry*, Bone Densitometry for Technologists, third ed. Springer, New York 2003, p. 70.
- [28] L.A. Clarke, C.E. Hollak, The clinical spectrum and pathophysiology of skeletal complications in lysosomal storage disorders, *Best Pract. Res. Clin. Endocrinol. Metab.* 29 (2014) 219–235.
- [29] M. Matsushita, H. Kitoh, K. Mishima, I. Kadono, H. Sugiura, S. Hasegawa, Y. Nishida, N. Ishiguro, Low bone mineral density in achondroplasia and hypochondroplasia, *Pediatr. Int.* (2015) 1–4.
- [30] E.B. Fung, J.A. Johnson, J. Madden, T. Kim, P. Harmatz, Bone density assessment in patients with mucopolysaccharidosis: a preliminary report from patients with MPS II and VI, *J. Pediatr. Rehabil. Med.* 3 (2010) 13–23.
- [31] B.S. Zemel, M.B. Leonard, A. Kelly, J.M. Lappe, V. Gilsanz, S. Oberfield, S. Mahboubi, J.A. Shepherd, T.N. Hangartner, M.M. Frederick, K.K. Winer, H.J. Kallwarf, Height adjustment in assessing dual energy x-ray absorptiometry measurements of bone mass and density in children, *J. Clin. Endocrinol. Metab.* 95 (2010) 1265–1273.
- [32] R.P. Heaney, S. Abrams, B. Dawson-Hughes, A. Looker, R. Marcus, V. Matkovic, C. Weaver, Peak bone mass, *Osteoporos. Int.* 11 (2000) 985–1009.