

Original Article

# Radiotherapy for iris metastasis from esophageal carcinoma: A series of three cases

Chandana Das, Carol L. Shields

The Ocular Oncology Service, Wills Eye Hospital, Thomas Jefferson University, Philadelphia, PA, USA

**Background:** Description of three cases of metastatic esophageal carcinoma to the iris and focus on management strategies.

**Methods:** A 48-year-old man (Case 1) with previously treated stage IV esophageal carcinoma presented with blurred vision in the left eye (OS) for 3 weeks. Initial fine needle aspiration biopsy (FNAB) was negative for malignant cells, so incisional biopsy was performed and confirmed metastatic carcinoma. A 53-year-old man (Case 2) with previously treated stage III esophageal cancer experienced 2 months of pain and 1 month of blurred vision OS. Documented tumor growth suggested esophageal carcinoma metastasis. A 65-year-old man (Case 3) with previously treated stage IV esophageal carcinoma developed hyphema in the right eye (OD), and FNAB confirmed metastatic carcinoma.

**Results:** Case 1 was treated with external beam radiotherapy (EBRT), delivered over 16 days which resulted in complete tumor regression. Case 2 received stereotactic body radiotherapy (SBRT) over 21 days leading to complete tumor regression. Case 3 was treated with plaque radiotherapy over 4 days, resulting in complete tumor regression.

**Conclusions:** In all three cases, radiotherapy was employed, and enucleation was avoided. Plaque radiotherapy achieved tumor control in a shorter period of time (4 days) compared to EBRT (16 days) or SBRT (21 days). Knowing the short life expectancy of these patients, plaque radiotherapy appears most favorable.

**Keywords:** Esophageal carcinoma, eye, iris, metastasis, plaque radiotherapy, radiotherapy

## Introduction

Metastatic cancer to the eye can arise from several systemic sites and is typically found within the uvea. Shields *et al.* evaluated 520 eyes with uveal metastatic foci and found the most common primary sites to include cancer of the breast (47%), lung (21%), and gastrointestinal (GI) tract (4%).<sup>[1]</sup> Less commonly, uveal metastases originated from primary cancers of the kidney, skin, and prostate at 2% each.<sup>[1]</sup> Esophageal metastasis represented only 0.2% of the entire group (1 patient of the 420 patient

sample).<sup>[1]</sup> However, the incidence of esophageal and gastric cardia adenocarcinoma has been rising at an average rate of 1.7% per year between 1999 and 2008, representing cancer that should be recognized.<sup>[2]</sup>

Metastatic tumors to the eye classically present in the choroid (88%) and less often in the iris (9%) or ciliary body (2%).<sup>[1]</sup> Management of uveal metastasis involves systemic chemotherapy, external radiotherapy, or focal plaque radiotherapy. Plaque radiotherapy is a form of brachytherapy in which a localized radiotherapy dose can be achieved over a select portion of the eye using a curvilinear applicator over a short period of time. It has been shown to be effective in the treatment of choroidal melanoma,

## Correspondence:

Dr. Carol L. Shields, Ocular Oncology Service, Suite 1440, Wills Eye Hospital, 840 Walnut Street, Philadelphia, PA 19107, USA.  
E-mail: [carolshields@gmail.com](mailto:carolshields@gmail.com)

### Access this article online

#### Quick Response Code:



Website:  
[www.ojonline.org](http://www.ojonline.org)

DOI:  
10.4103/0974-620X.184526

This is an open access article distributed under the terms of the Creative Commons Attribution-NonCommercial-ShareAlike 3.0 License, which allows others to remix, tweak, and build upon the work non-commercially, as long as the author is credited and the new creations are licensed under the identical terms.

For reprints contact: [reprints@medknow.com](mailto:reprints@medknow.com)

Cite this article as: Das C, Shields CL. Radiotherapy for iris metastasis from esophageal carcinoma: A series of three cases. *Oman J Ophthalmol* 2016;9:93-6.

choroidal metastases, iris melanoma, and other tumors. Herein, we illustrate three patients with esophageal carcinoma metastatic to the iris treated with external beam radiotherapy (EBRT), stereotactic body radiotherapy (SBRT), and plaque radiotherapy. One of the benefits of plaque radiotherapy is the rapid delivery of focal radiotherapy to a select site in the eye. The three patients described survived a mean of 10 months from the time of iris metastasis detection and plaque radiotherapy achieved tumor control with 4 days of treatment (1% of the remaining lifetime), whereas EBRT (16 days) and SBRT (21 days), occupied 5% and 7% of their remaining days, respectively.

## Case Reports

### Case 1

A 48-year-old white man presented with 3 weeks of blurred vision in the left eye (OS) and history of biopsy proven stage IV esophageal adenocarcinoma with metastases to the left cervical lymph nodes, treated with EBRT and chemotherapy. On examination, visual acuity was 20/20 in the right eye (OD) and 20/30 OS. Intraocular pressure (IOP) was normal. His left eye had an iris stromal mass from 11:00 to 4:00 with ill-defined margins measuring 6 mm × 4 mm × 1 mm [Figure 1a and b]. The fundus was normal in both eyes (OU). There were no active systemic metastases at this point. A fine needle aspiration biopsy (FNAB) of the lesion was negative for malignant cells. The patient was

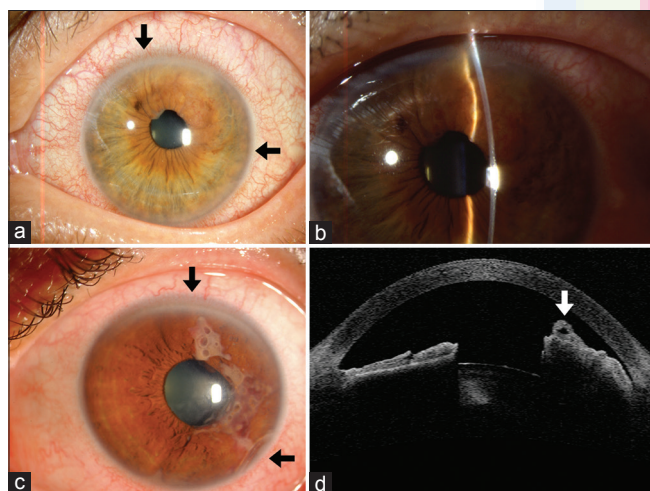
followed with observation and returned 3 months later with tumor growth, now encompassing the iris from 8:00 to 4:30, with 20/200 vision OS and IOP of 52 mm Hg OS. An incisional biopsy revealed mucous secreting adenocarcinoma metastatic to the iris. This eye was treated with an EBRT dose of 3000 cGy over 16 days. Following treatment, visual acuity was 20/20 OD and 20/25 OS, and his IOP had improved to 13 mm Hg OD and 16 mm Hg OS. He later developed cataract with visual acuity of 20/400 OS and died 13 months after his first visit [Table 1].

### Case 2

A 53-year-old white man presented with 2 months of pain and blurred vision. It was suspected elsewhere to be uveitis, but later, a tumor was discovered. He gave a history of stage III esophageal carcinoma with regional lymph node involvement, treated with total esophagectomy and chemotherapy. On examination, visual acuity was 20/20 OD and 20/100 OS with normal IOP of 10 mmHg OD and 15 mmHg OS. The right eye was normal. In the left eye, there was diffuse iris infiltration from 12:00 to 6:00 measuring 12 mm × 5 mm × 2.7 mm, with angle involvement at 5:00 and 7:00 and infiltration of the anterior lens capsule [Figure 1c and d]. In addition, there was cystoid macular edema OS. Following 2 weeks with documented growth, treatment with SBRT using a dose of 3500 centigray in 14 fractions over 21 days was provided.<sup>[3]</sup> Following treatment, tumor regression was documented.<sup>[3]</sup> The patient died 12 months later [Table 1].

### Case 3

A 65-year-old white man was found to have hyphema and a tumor OD. His history was significant for biopsy-proven stage IV adenocarcinoma with metastases to the left supraclavicular lymph node and bone, treated with chemotherapy. On examination, visual acuity was 20/40 OD and 20/20 OS. IOP was 31 mmHg OD and 18 mmHg OS. The left eye was normal. The right eye had a multinodular iris mass measuring 4 mm × 3 mm × 2 mm [Figure 2a] with intrinsic vessels and gonioscopic evidence of hyphema with tumor seeds, confirmed on anterior segment optical coherence tomography [Figure 2b]. FNAB revealed poorly differentiated metastatic carcinoma. A radioactive plaque using Iodine-125 was placed over the tumor, delivering 3500 centigray to the apex of the tumor over 4 days and achieving complete tumor regression [Figure 2c and d]. The patient died 5 months after his first visit [Table 1].



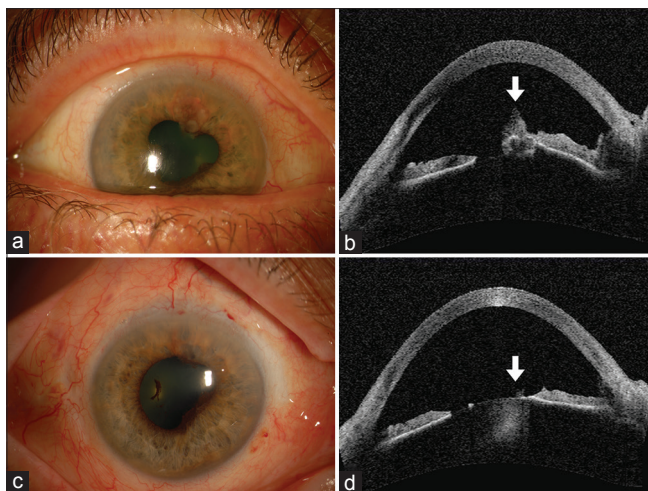
**Figure 1:** Iris metastasis from esophageal carcinoma. (a) (Case 1) Ill-defined iris metastasis within the iris stroma (arrows) causing iris thickening from 11:00 to 3:00. (b) (Case 1) Slit beam highlights the region of iris thickening and irregular surface. (c) (Case 2) Ill-defined iris metastasis (arrows) with a foamy appearance on the iris surface from 12:00 to 4:00. (d) (Case 2) Anterior segment optical coherence tomography shows the mass (arrow) on the iris surface

## Discussion

The incidence of esophageal and gastric cardia adenocarcinoma has increased sevenfold from 1973 to 2006, from 3.6 to 25.6 cases

**Table 1: Summary of clinical features in each case of esophageal carcinoma metastasis to the iris and managed with radiotherapy**

Case	Age	Gender	Race	Systemic cancer	Interval cancer to iris metastasis (months)	Treatment of iris metastasis	Interval iris metastasis to death (months)
Number 1	48	Male	Caucasian	Esophageal	12	External beam radiotherapy	13
Number 2	53	Male	Caucasian	Esophageal	14	Stereotactic radiotherapy	12
Number 3	65	Male	Caucasian	Esophageal	9	Plaque radiotherapy	5



**Figure 2:** Iris metastasis from esophageal carcinoma treated with plaque radiotherapy. (a) (Case 3) Ill-defined iris metastasis extending from 12:00 to 8:00 with posterior synechia at the site of a nodule at the 1:00 meridian. (b) (Case 3) Anterior segment optical coherence tomography shows the mass as a nodule at the pupillary margin (arrow). (c) (Case 3) Following plaque radiotherapy, the tumor has regressed to a flat scar with persistent posterior synechia. (d) (Case 3) Following plaque radiotherapy, anterior segment optical coherence tomography demonstrates flattened iris without a mass (arrow)

per million according to Carr *et al.*<sup>[2]</sup> There are several reasons for this alarming rise, including gastroesophageal reflux disease (GERD), obesity, tobacco use, and low dietary intake of fruits and vegetables.<sup>[4]</sup> Chronic inflammation (esophagitis) resulting from GERD leads to the development of Barrett's esophagus, which is metaplasia of native squamous epithelium to intestinal-like columnar epithelium following chronic exposure to gastric acid. This can culminate in cellular dysplasia and invasive esophageal adenocarcinoma.<sup>[4]</sup> Obesity contributes by increasing intra-abdominal pressure, intensifying already existing GERD, and increasing levels of adiponectin and insulin-like growth factors which modulate cellular proliferation and apoptosis.<sup>[2]</sup> Obesity also contributes to the increased levels of proinflammatory adipocytokines.<sup>[4]</sup> Multiple studies have linked current or past tobacco use to the development of esophageal adenocarcinoma.<sup>[2]</sup> Finally, diets high in carbohydrates and saturated fats with a concurrent decrease in fruits and vegetables may lead to increased insulin resistance and higher levels of insulin-like growth factors, contributing to carcinogenesis.<sup>[2]</sup>

The treatment of esophageal carcinoma depends on tumor invasion and includes adjuvant chemoradiotherapy following surgical resection through the transhiatal, transthoracic, or endoscopy routes.<sup>[4]</sup> Prognosis depends on tumor stage with 5-year survival at 82% for stage 0 (high-grade dysplasia, G1); 64–77% for stage I (T1-2, N0, M0, G1-3); 40–50% for stage II (T1-3, N0-1, M0, G3-any); and 15–25% for stage III (T1-4b, N0-any, M0, G any).<sup>[5]</sup> Five-year survival can be assumed to be <15% in patients with stage IV (T any, N any, M1, G any) esophageal adenocarcinoma.

Esophageal carcinoma rarely metastasizes to the eye, and generally to the choroid when it does. In a large analysis of 520 eyes with metastatic disease, cancers of the GI tract were the

source of metastasis in 19 (4%) eyes.<sup>[11]</sup> In an analysis of 40 cases of iris metastasis, only one case was from esophageal carcinoma, highlighting the rarity of this finding.<sup>[6]</sup> However, there have been case reports of esophageal adenocarcinoma metastasis to the iris as the presenting manifestation of esophageal adenocarcinoma.<sup>[7]</sup>

Plaque radiotherapy is a form of brachytherapy using an applicator with radioactive material lined by protective, radiation-safe gold. This technology has been used for several decades to treat choroidal melanoma and more recently to treat choroidal metastasis.<sup>[8]</sup> Plaque radiotherapy was also adapted to treat iris melanoma, particularly those that are nonresectable.<sup>[9]</sup>

In 1995, Shields *et al.* reported the use of plaque radiotherapy for iris metastasis in four cases.<sup>[10]</sup> All four cases demonstrated complete regression without recurrence.<sup>[10]</sup> Subsequent reports on the use of plaque radiotherapy for iris malignancy, particularly melanoma, have disclosed the safety and efficacy of this approach.<sup>[11]</sup>

In our series of three cases of iris metastasis from esophageal carcinoma, each patient received radiotherapy in different forms. Case 1 was treated with EBRT over 16 days, and Case 2 received SBRT over 21 days, both with complete tumor regression. The therapy occupied 5% (Case 1) and 7% (Case 2) of the patient's remaining days. In Case 3, plaque radiotherapy was applied and took only 4 days of treatment, representing 1% of the patient's mean remaining days. Including all three cases, systemic metastases led to death at a mean of 10 months. Each form of radiotherapy was successful in tumor control, avoiding pain, glaucoma, and blindness, but this goal was most efficiently achieved with plaque radiotherapy. Given the short life prognosis in such patients, we advocate plaque radiotherapy for most rapid tumor control with least time commitment.

### Financial support and sponsorship

The support provided by the Eye Tumor Research Foundation, Philadelphia, PA (CLS), USA.

### Conflicts of interest

There are no conflicts of interest.

### Precis

Plaque radiotherapy is a safe and effective treatment for iris metastasis from esophageal carcinoma, with tumor control achieved over 4 days of radiation exposure.

### References

- Shields CL, Shields JA, Gross NE, Schwartz GP, Lally SE. Survey of 520 eyes with uveal metastases. *Ophthalmology* 1997;104:1265-76.
- Carr JS, Zafar SF, Saba N, Khuri FR, El-Rayes BF. Risk factors for rising incidence of esophageal and gastric cardia adenocarcinoma. *J Gastrointest Cancer* 2013;44:143-51.
- Dhakal S, Lema GM, Diloreto DA Jr, Katz AW. Esophageal metastasis to the iris effectively palliated using stereotactic body radiation therapy and adjuvant intravitreal chemotherapy: Case report and literature review. *Case Rep Oncol* 2012;5:639-43.

Das and Shields: Radiotherapy for iris metastasis from esophageal carcinoma

4. Lagergren J, Lagergren P. Recent developments in esophageal adenocarcinoma. *CA Cancer J Clin* 2013;63:232-48.
5. Rice TW, Blackstone EH, Rusch VW. 7<sup>th</sup> edition of the AJCC cancer staging manual: Esophagus and esophagogastric junction. *Ann Surg Oncol* 2010;17:1721-4.
6. Shields JA, Shields CL, Kiratli H, de Potter P. Metastatic tumors to the iris in 40 patients. *Am J Ophthalmol* 1995;119:422-30.
7. Lee WB, Sy HM, Filip DJ, Grossniklaus HE. Metastatic esophageal adenocarcinoma presenting in the iris. *Am J Ophthalmol* 2007;144:477-9.
8. Shields CL, Shields JA, De Potter P, Quaranta M, Freire J, Brady LW, *et al.* Plaque radiotherapy for the management of uveal metastasis. *Arch Ophthalmol* 1997;115:203-9.
9. Shields CL, Naseripour M, Shields JA, Freire J, Cater J. Custom-designed plaque radiotherapy for nonresectable iris melanoma in 38 patients: Tumor control and ocular complications. *Am J Ophthalmol* 2003;135:648-56.
10. Shields CL, Shields JA, De Potter P, Singh AD, Hernandez C, Brady LW. Treatment of non-resectable malignant iris tumours with custom designed plaque radiotherapy. *Br J Ophthalmol* 1995;79:306-12.
11. Fernandes BF, Krema H, Fulda E, Pavlin CJ, Payne DG, McGowan HD, *et al.* Management of iris melanomas with <sup>125</sup>Iodine plaque radiotherapy. *Am J Ophthalmol* 2010;149:70-6.

