



Kikuchi Disease: Recognizing a Common Presentation of an Uncommon Condition

Ramya Punati, MD

Thomas Jefferson University, ramya.punati@jefferson.edu

Follow this and additional works at: <http://jdc.jefferson.edu/tmf>

 Part of the [Internal Medicine Commons](#)

[Let us know how access to this document benefits you](#)

Recommended Citation

Punati, MD, Ramya () "Kikuchi Disease: Recognizing a Common Presentation of an Uncommon Condition," *The Medicine Forum*: Vol. 17, Article 17.

Available at: <http://jdc.jefferson.edu/tmf/vol17/iss1/17>

This Article is brought to you for free and open access by the Jefferson Digital Commons. The Jefferson Digital Commons is a service of Thomas Jefferson University's [Center for Teaching and Learning \(CTL\)](#). The Commons is a showcase for Jefferson books and journals, peer-reviewed scholarly publications, unique historical collections from the University archives, and teaching tools. The Jefferson Digital Commons allows researchers and interested readers anywhere in the world to learn about and keep up to date with Jefferson scholarship. This article has been accepted for inclusion in The Medicine Forum by an authorized administrator of the Jefferson Digital Commons. For more information, please contact: JeffersonDigitalCommons@jefferson.edu.

Kikuchi Disease: Recognizing a Common Presentation of an Uncommon Condition

Ramya Punati, MD

INTRODUCTION

Kikuchi disease, also known as histiocytic necrotizing lymphadenitis or Kikuchi-Fujimoto disease, is a rare condition that typically presents with fever and cervical lymphadenopathy in previously healthy young women. First described by Dr. Kikuchi and independently by Dr. Fujimoto in Japan in 1972, the disease is benign and usually self-limited. However, because it can present dramatically and mimic more serious conditions such as lymphoma and tuberculous adenitis, recognizing Kikuchi disease is crucial to avoid misdiagnosis and inappropriate treatment. This case describes a patient who presented with severe manifestations of Kikuchi disease that generated an extensive workup and differential diagnosis prior to its identification.

CASE PRESENTATION

A 24-year-old African-American female with no past medical history presented with fever of 104°F and painful cervical lymphadenopathy of several weeks duration. The patient had recently been hospitalized at two other hospitals with these symptoms and was treated empirically with amoxicillin and then doxycycline for presumed acute bacterial infections without improvement in her symptoms. At the time of admission to Jefferson, the patient reported persistent fevers, nausea, diffuse abdominal pain, twenty pound weight loss, frequent loose, nonbloody stools, and worsening lymphadenopathy which began in the cervical region and more recently involved the axillary and inguinal nodes. She had no rash, urinary symptoms, or cardiopulmonary symptoms. She denied recent travel, sexual contact, or pertinent family history. On exam, she was ill-appearing but hemodynamically stable. Exam was notable for significant tender, firm lymphadenopathy in the cervical, submandibular, axillary, and inguinal regions bilaterally. Abdomen was diffusely tender but soft and nondistended without hepatosplenomegaly.

Laboratory studies on admission showed pancytopenia (white blood cell [WBC] count 1.6 B/L with 35% bands, hemoglobin 9.8 g/dL, platelets 120 B/L), normal basic metabolic panel, and mild elevation of transaminases (aspartate aminotransferase [AST] 80 IU/L, alanine aminotransferase [ALT] 95 IU/L). She was empirically started on broad-spectrum antibiotics for sepsis, though these were discontinued after all cultures remained negative. CT of the chest, abdomen, and pelvis showed no lymphadenopathy or evidence of infection. Her transaminases rose to 2045 IU/L (AST) and 1068 IU/L

(ALT) within one week. Abdominal ultrasound showed increased echogenicity of the portal triads consistent with hepatitis. Her ferritin level was initially elevated at 1379 ng/mL and peaked at 16394 ng/mL one week after admission. Her triglyceride level was normal.

Inflammatory markers, namely erythrocyte sedimentation rate and C-reactive protein levels were moderately elevated. Complete autoimmune workup was negative except for anti-smooth-muscle antibody which was positive at a low titer (1:40) and anti-Smith/RNP antibody which was positive at 309 U/mL. Infectious workup for bacterial, viral, and parasitic etiologies was negative except for an indeterminate interferon- γ release assay (QuantiFERON-TB Gold) result and Hepatitis B serologies consistent with prior immunization.

In terms of hematologic and oncologic workup, labs were not consistent with tumor lysis syndrome. Lactate dehydrogenase was elevated at 1348 IU/L. Blood smear showed pancytopenia with left-shifted granulocytes. Peripheral blood flow cytometry showed a CD4:CD8 T lymphocyte ratio of 2.3. A bone marrow biopsy was performed and flow cytometry of the aspirate showed no phenotypically abnormal population. Molecular genetics confirmed normal female karyotype (46 XX). Pathology showed a hypocellular bone marrow (10%) with markedly hypoplastic trilineage hematopoiesis. There was also dyserythropoiesis and left-shifted myelopoiesis but no suggestion of malignancy or hemophagocytosis.

As the above workup was carried out, the patient's intermittent fevers and painful lymphadenopathy persisted.

DIFFERENTIAL DIAGNOSIS

The differential diagnosis was initially broad and included lymphoma, autoimmune conditions such as systemic lupus erythematosus (SLE) and hemophagocytic lymphohistiocytosis, and obscure infectious etiologies. As none of the workup was conclusive or diagnostic, an excisional biopsy of a right cervical lymph node was performed. The pathology of this lymph node showed extensive apoptosis and necrosis with histiocytic infiltrate and immunoblast proliferation, consistent with Kikuchi lymphadenitis.

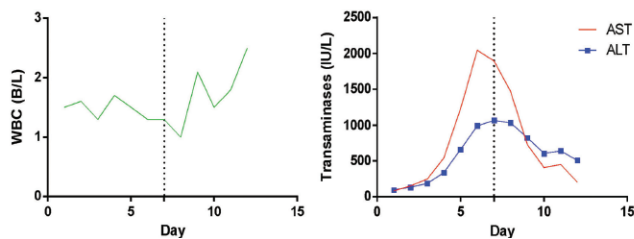


Figure 1. Trend of white blood cell count (WBC), transaminases and ferritin during patient's hospital stay. Dotted line indicates initiation of steroids on hospital day 7. (AST - aspartate aminotransferase; ALT - alanine aminotransferase)

OUTCOME AND FOLLOW-UP

The patient began treatment with high-dose intravenous steroids on hospital day 7. Following steroid administration, she became afebrile and had a decrease in her painful lymphadenopathy with improving transaminases, ferritin and WBC count (**Figure 1**). She was discharged on a slow steroid taper with rheumatology and hematology follow-up.

DISCUSSION

Kikuchi disease is a rare, benign condition that usually presents with fever and cervical lymphadenopathy and is defined by its classic lymph node histopathology. Although originally described in Japan, the disease has since been found in all racial groups and various countries. It is more common in females than males and the mean age at presentation is 30 years.¹ The pathogenesis is unknown, but evidence suggests an immune response of T cells and histiocytes to an infectious agent such as a herpesvirus.²

Clinically, patients with Kikuchi disease typically present with lymphadenopathy and fever lasting one week to one month, as the patient in this case did. In the majority of cases, only the cervical lymph nodes are involved, and they are moderately enlarged (1-2 cm), firm, smooth, mobile, and painful.³ Rarely, patients may present with fever of unknown origin and have only mediastinal or retroperitoneal lymphadenopathy. Other common findings include leukopenia (43%), anemia (23%), rash (10%), arthritis (7%), and hepatosplenomegaly (3%).^{4,5} Rashes seen in Kikuchi disease can be highly variable, mimicking drug eruptions or the malar rash of SLE. Common constitutional symptoms include night sweats, weight loss, myalgias, nausea, vomiting, and diarrhea. In addition, inflammatory conditions of various organs have been reported in association with Kikuchi disease, including aseptic meningitis, autoimmune hepatitis, thyroiditis, polymyositis, uveitis, and neuritis.

The diagnosis of Kikuchi disease is made by lymph node biopsy, which on microscopy shows paracortical foci with necrosis and a histiocytic cellular infiltrate.^{1,6} In the earlier, proliferative phase of the disease, the presence

of T and B cell blasts can raise the possibility of lymphoma, but preservation of nodal architecture and the polyclonal infiltrate exclude this. Later, biopsies in the necrotizing phase show necrosis with progressive predominance of histiocytes. The lack of neutrophils in this phase helps distinguish it from SLE and drug-induced lymphadenopathy.

Management of Kikuchi disease consists primarily of supportive care, as there is no proven effective treatment. However, patients with severe or persisting symptoms have been treated with glucocorticoids or intravenous immunoglobulin with apparent benefit.⁷ In most patients, the disease is self-limited and symptoms resolve within one to four months. However, patients should be followed for several years for late recurrences or development of SLE.⁸

KEY POINTS

- Kikuchi disease is rare but should be considered in the differential diagnosis of young females presenting with fever and cervical lymphadenopathy.
- Although Kikuchi disease is self-limited and benign, lymph node biopsy should always be performed when the diagnosis is suspected to rule out more serious mimicking conditions that require specific, aggressive therapy such as lymphoma or tuberculous adenitis.
- No effective treatment has been established for Kikuchi disease, although steroids have been helpful in many cases.

REFERENCES

1. Dorfman RF, Berry GJ. Kikuchi's histiocytic necrotizing lymphadenitis: an analysis of 108 cases with emphasis on differential diagnosis. *Seminars Diagn Pathol* 1988; 5(4): 329-45.
2. Hudnall SD, Chen T, Amr S, Young KH, Henry K. Detection of human herpesvirus DNA in Kikuchi-Fujimoto disease and reactive lymphoid hyperplasia. *Int J Clin Exp Pathol* 2008; 1(4): 362.
3. Kuo TT. A Clinicopathologic Study of 79 Cases with an Analysis of Histologic Subtypes, Immunohistology, and DNA Ploidy. *Am J Surg Pathol* 1995; 19(7): 798-809.
4. Kucukardali Y, Solmazgul E, Kunter E, Oncul O, Yildirim S, Kaplan M. Kikuchi-Fujimoto Disease: Analysis of 244 Cases. *Clin Rheumatol* 2006; 26(1): 50-4.
5. Asano S, Akaike Y, Jinnouchi H, Muramatsu T, Wakasa H. Necrotizing lymphadenitis: a review of clinicopathological, immunohistochemical and ultrastructural studies. *Hematol Oncol* 1990; 8(5): 251-60.
6. Atwater AR, Longley BJ, Aughenbaugh WD. Kikuchi's disease: case report and systematic review of cutaneous and histopathologic presentations. *J Am Acad Dermatol* 2008; 59(1): 130-6.
7. Jang YJ, Park KH, Seok HJ. Management of Kikuchi's disease using glucocorticoid. *J Laryngol Otol* 2000; 114(09): 709-11.
8. Song JY, Lee J, Park DW, et al. Clinical outcome and predictive factors of recurrence among patients with Kikuchi's disease. *Int J Infect Dis* 2009; 13(3): 322-6.