



# Allergic Inflammatory Mediated Coronary Artery Vasospasm: A Case Report of Kounis Syndrome

Jonathan Hullman, MS4

Thomas Jefferson University, [jonathan.hullman@jefferson.edu](mailto:jonathan.hullman@jefferson.edu)


Jaehee Kim, MD

Thomas Jefferson University, [jaehee.kim@jefferson.edu](mailto:jaehee.kim@jefferson.edu)

Gregary D. Marhefka, MD, FACC, FACP

Thomas Jefferson University, [Gregary.Marhefka@jefferson.edu](mailto:Gregary.Marhefka@jefferson.edu)

Follow this and additional works at: <http://jdc.jefferson.edu/tmf>

 Part of the [Cardiology Commons](#), and the [Internal Medicine Commons](#)

[Let us know how access to this document benefits you](#)

## Recommended Citation

Hullman, MS4, Jonathan; Kim, MD, Jaehee; and Marhefka, MD, FACC, FACP, Gregary D. () "Allergic Inflammatory Mediated Coronary Artery Vasospasm: A Case Report of Kounis Syndrome," *The Medicine Forum*: Vol. 17, Article 4.

Available at: <http://jdc.jefferson.edu/tmf/vol17/iss1/4>

This Article is brought to you for free and open access by the Jefferson Digital Commons. The Jefferson Digital Commons is a service of Thomas Jefferson University's [Center for Teaching and Learning \(CTL\)](#). The Commons is a showcase for Jefferson books and journals, peer-reviewed scholarly publications, unique historical collections from the University archives, and teaching tools. The Jefferson Digital Commons allows researchers and interested readers anywhere in the world to learn about and keep up to date with Jefferson scholarship. This article has been accepted for inclusion in The Medicine Forum by an authorized administrator of the Jefferson Digital Commons. For more information, please contact: [JeffersonDigitalCommons@jefferson.edu](mailto:JeffersonDigitalCommons@jefferson.edu).

# Allergic Inflammatory Mediated Coronary Artery Vasospasm: A Case Report of Kounis Syndrome

Jonathan Hullman, MS4, Jaehee Kim, MD, Gregory Marhefka, MD, FACC, FACP

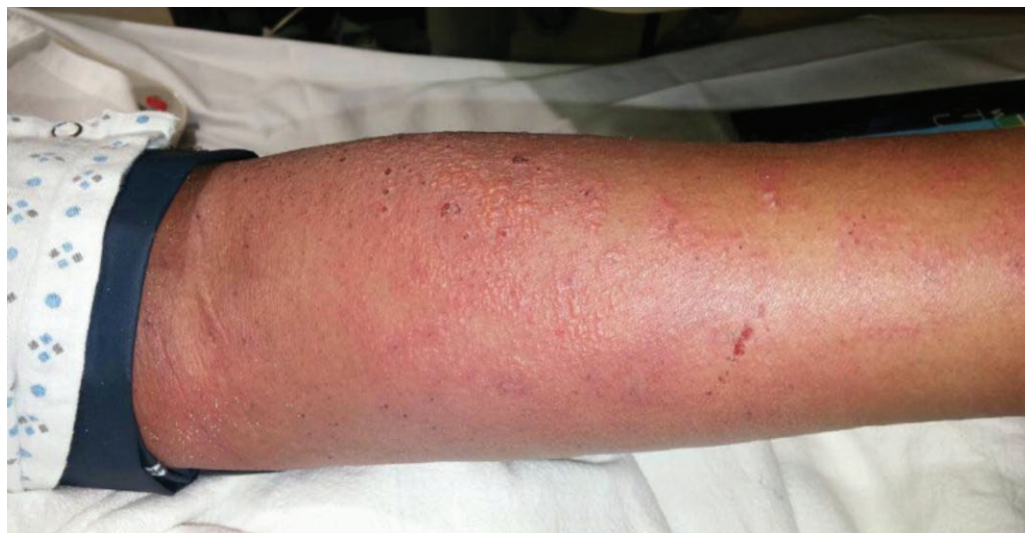

Figure 1. Picture of the patient's arm on day of admission demonstrating a diffuse erythematous, non-blanching, maculopapular rash.

## INTRODUCTION

Kounis syndrome is an acute coronary syndrome occurring secondary to an anaphylactic reaction. A wide variety of triggers such as drugs and environmental exposures have been described for the so-called allergic myocardial infarction. The pathophysiology of Kounis syndrome is thought to be due to the release of inflammatory mediators such as histamine and cytokines by mast cells and eosinophils resulting in either coronary vasospasm, myocardial infarction or stent thrombosis<sup>1</sup>.

## CASE PRESENTATION

A 57 year-old African American woman was brought in by ambulance from home with acute onset of chest tightness that awoke her from sleep that morning. The pain was associated with nausea, shortness of breath, and numbness with paresthesias in her extremities. Upon presentation, her physical exam was notable for a diffuse erythematous, non-blanching, maculopapular rash on the trunk as well as the extremities (Figure 1). Laboratory results were significant for an elevated white blood cell count of  $19.4 \times 10^9/L$  with 2.4% eosinophils (normal 1-6%), and troponin T < 0.01. An EKG demonstrated 2mm ST segment elevations in leads II, III and aVF concerning for inferior wall ischemia (Figure 2A).

The patient underwent an urgent cardiac catheterization due to concern for acute coronary syndrome. However, cardiac catheterization did not show any occlusion or

significant stenosis of the coronary arteries (Figure 3). A repeat EKG was performed following catheterization, which demonstrated resolution of the ST segment elevations (Figure 2B). The absence of coronary artery disease suggested that these transient ST segment elevations seen in the inferior leads of the EKG were due to coronary artery vasospasm rather than coronary plaque rupture or thrombus. A transthoracic echocardiogram obtained following cardiac catheterization showed no wall motion abnormalities with normal ejection fraction.

## DIFFERENTIAL DIAGNOSIS

The patient underwent an extensive work-up to determine the cause of her rash. Her infectious and autoimmune workups were unremarkable. Later during her hospitalization, the patient developed an eosinophilia with a white blood cell differential containing 20% eosinophils. A punch biopsy of the skin was performed, which showed superficial perivascular dermatitis with eosinophils and neutrophils pointing to a hypersensitivity reaction. Upon further questioning, it was revealed that the patient was started on mirtazapine by her primary care physician for treatment of insomnia three days prior to admission. Because there was no other identified etiology from her work-up, mirtazapine was suspected to be the culprit of her allergic reaction. Subsequently, mirtazapine was stopped and the patient was given a course of oral glucocorticoids which led to resolution of the rash.

Figure 2A

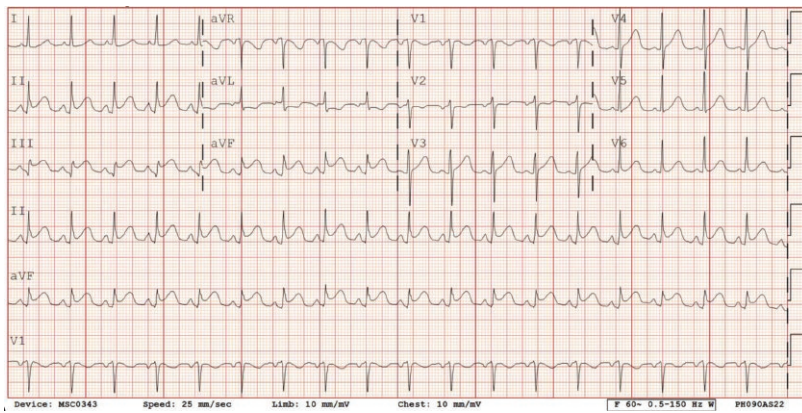


Figure 2B

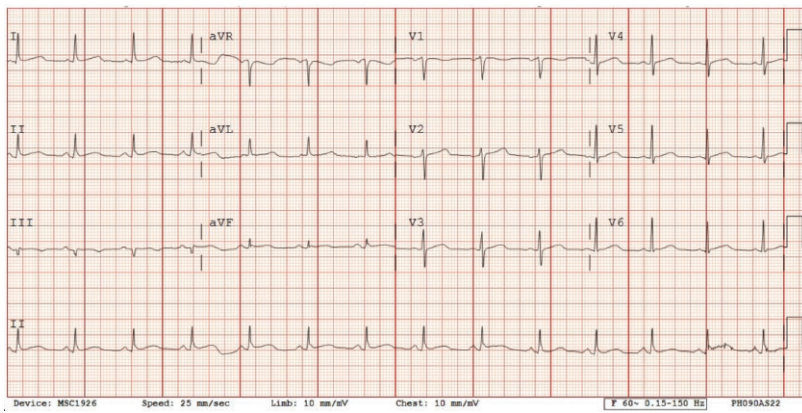


Figure 2. EKG tracing from admission (A) demonstrating ST segment elevation in leads II, III and aVF and following cardiac catheterization (B) showing resolution of ST segment elevation.

Figure 3A

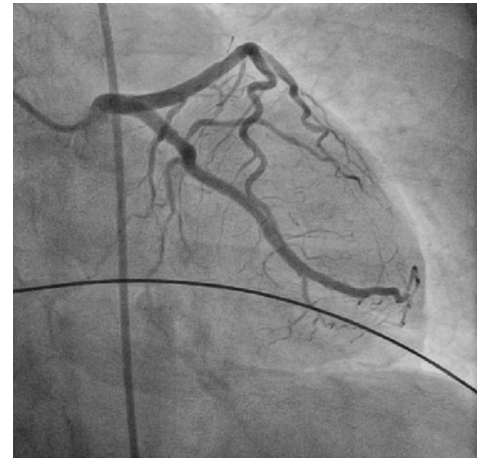


Figure 3B

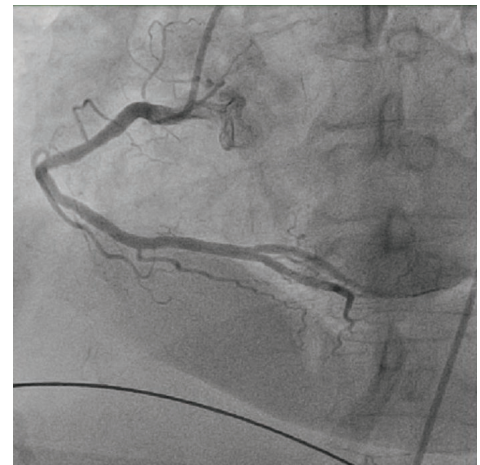


Figure 3. Images from cardiac catheterization demonstrating no occlusion or stenosis in the (A) left or (B) right coronary arteries.

## DISCUSSION

Kounis syndrome was originally described in 1991; however, this phenomenon is not widely known in clinical practice<sup>2</sup>. Above we have described a case of Kounis syndrome in which coronary artery vasospasm occurs due to inflammatory mediators in the absence of underlying coronary artery disease. It is clear from her diffuse rash, eosinophilia, and skin biopsy that she was undergoing an allergic inflammatory reaction which ultimately led to her coronary artery vasospasm. Recognizing Kounis syndrome as a differential diagnosis for acute coronary syndrome is important as treatment with steroids and antihistamines may be of benefit in addition to vasodilators such as calcium-channel blockers and nitrates<sup>3</sup>.

## REFERENCES

1. Kounis NG. Coronary hypersensitivity disorder: the kounis syndrome. *Clinical Therapeutics*. 2013; 35:564-71.
2. Kounis NG, Zavras GM. Histamine-induced coronary artery spasm: the concept of allergic angina. *British Journal of Clinical Practice*. 1991;45:121-128.
3. Cevik C, Nugent K, Shome GP, Kounis NG. Treatment of kounis syndrome. *International Journal of Cardiology*. 2010;143:223-226.