

1840

On the anatomy of the breast - Plate I: This plate is intended to show the external appearance of the nipple in the male at different ages, the internal appearance of the gland as covered by its fascia at different periods of life, the glands and the ducts of the male gland injected, and the gland and ducts of the foetus

Sir Astley Paston Cooper , Bart.

[Let us know how access to this document benefits you](#)

Follow this and additional works at: <http://jdc.jefferson.edu/cooper> Part of the [History of Science, Technology, and Medicine Commons](#)

Recommended Citation

Cooper, Sir Astley Paston , Bart., "On the anatomy of the breast - Plate I: This plate is intended to show the external appearance of the nipple in the male at different ages, the internal appearance of the gland as covered by its fascia at different periods of life, the glands and the ducts of the male gland injected, and the gland and ducts of the foetus" (1840). *On the anatomy of the breast, by Sir Astley Paston Cooper, 1840*. Paper 45.

<http://jdc.jefferson.edu/cooper/45>

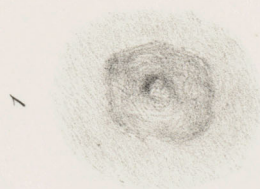
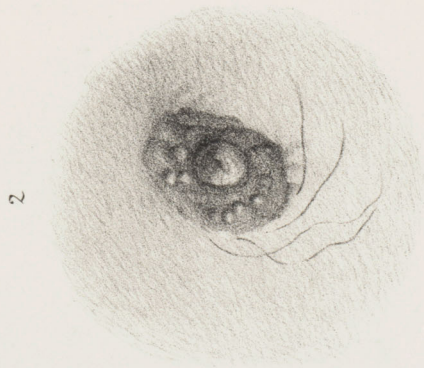
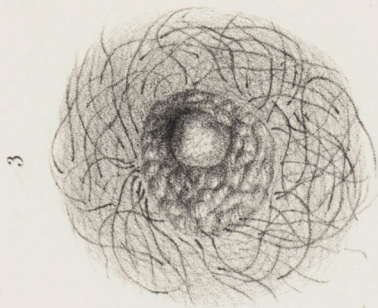
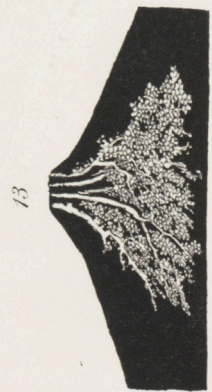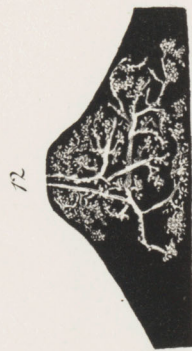
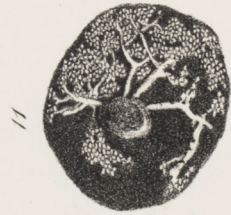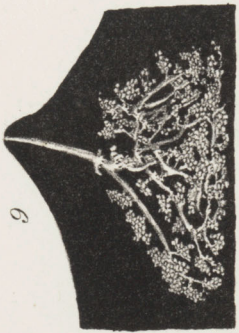
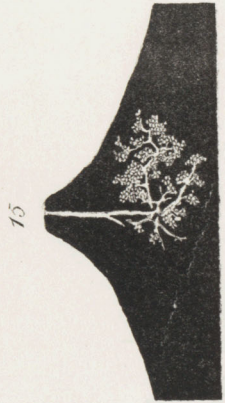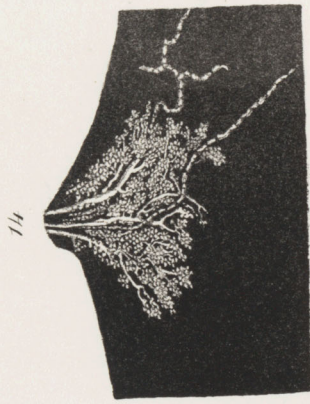
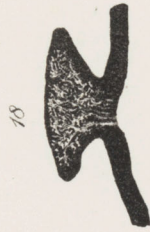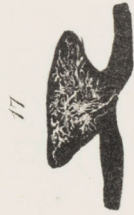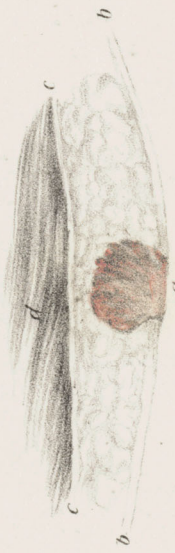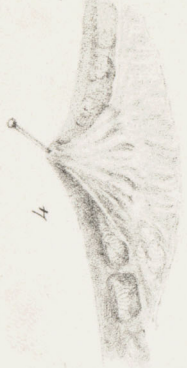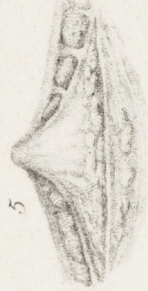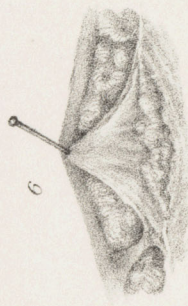
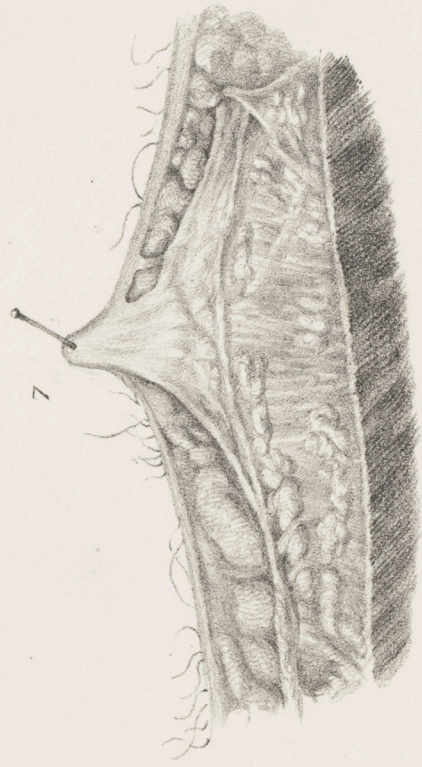
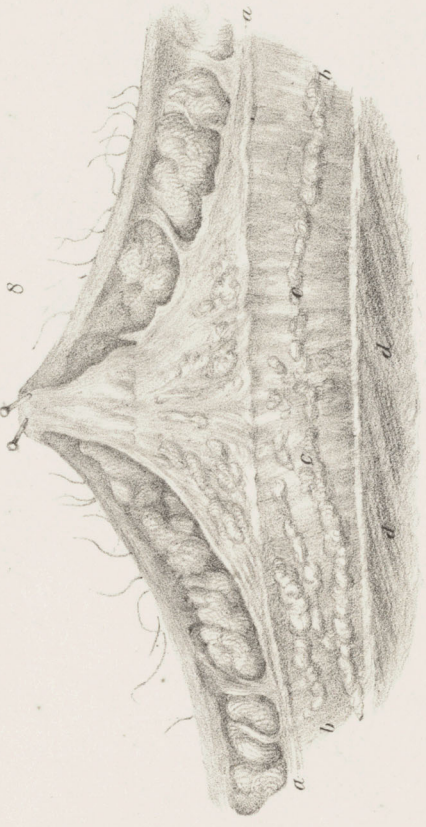


PLATE I.

This Plate is intended to show the external Appearance of the Nipple in the Male at different Ages; the internal Appearance of the Gland as covered by its Fascia at different periods of life; the Glands and the Ducts of the Male Gland injected, and the Gland and Ducts of the Fœtus.

- Fig. 1. The nipple and areola at six years of age.
- Fig. 2. The nipple, areola, and tubercles, with a few hairs, in a man aged forty-three.
- Fig. 3. The nipple, tubercles, and hairs, of a man at seventy-three.
- Fig. 4. Age, three years. Section of the male breast, showing the radiated disposition of the gland, its ligamenta suspensoria, and anterior and posterior fascia.
- Fig. 5. Age, seven years. The gland, the anterior and posterior fascia, and the ligamenta suspensoria, with fat between them.
- Fig. 6. Age, thirteen years. Section of the gland, ligamenta suspensoria, and fat.
- Fig. 7. Age twenty-nine years. A section of the gland; the skin covered with hairs; fat and ligamenta suspensoria placed beneath it; the anterior and posterior fascia with the gland between them; fibrous and cellular tissue, with fat between the posterior fascia and the pectoral muscle; the latter appearing at the lower part of the figure.
- Fig. 8. Age, thirty-eight. Its upper part shows the skin with hairs growing from it; under it, lobes of fat between ligamenta suspensoria; the nipple and gland of the breast enclosed in their fasciæ.
- a, a*, The posterior fascia passing behind the breast.
- Between the posterior fascia and the pectoral muscle, cellular and fibrous tissue, *b, b*.

c, c, Some fat seen deposited in the fascia of the gland, and in the cellular and fibrous tissue, *b, b*.
d, d, The pectoral muscle.

- Fig. 9. Duct of the male gland injected with quicksilver, exhibiting its ramifications and cells. The ducts divide in much the same manner as those of the female.
- Fig. 10. Posterior view of the male gland, showing four ducts injected with quicksilver.
- Fig. 11. Anterior view of fig. 10; four ducts seen passing to the nipple; the cells shown.
- Fig. 12. Ducts injected in the male, with several ramifications.
- Fig. 13. Five ducts injected with quicksilver, proceeding to small but distinct cells.
- Fig. 14. Three ducts injected with quicksilver; their cells are filled, and absorbent vessels are seen arising from them.
- Fig. 15. A single duct with its branches, partially injected with quicksilver.

Fœtal Gland.

- Fig. 16. The gland of the fœtus at nine months, or full growth.
a, The gland.
b, The skin.
c, The cellular and adipose tissue.
d, The pectoral muscle.
- Fig. 17. One of the ducts and its branches injected with quicksilver.
- Fig. 18. Several ducts and their ramifications injected.
- Figs. 16, 17, and 18, are placed in the opposite direction to the other drawings.