

1903

Modern Surgery - Chapter 7. Ulceration and Fistula

John Chalmers Da Costa
Jefferson Medical College

Let us know how access to this document benefits you

Follow this and additional works at: http://jdc.jefferson.edu/dacosta_modernsurgery

 Part of the [History of Science, Technology, and Medicine Commons](#)

Recommended Citation

Da Costa, John Chalmers, "Modern Surgery - Chapter 7. Ulceration and Fistula" (1903). *Modern Surgery, 4th edition, by John Chalmers Da Costa*. Paper 52.

http://jdc.jefferson.edu/dacosta_modernsurgery/52

This Article is brought to you for free and open access by the Jefferson Digital Commons. The Jefferson Digital Commons is a service of Thomas Jefferson University's [Center for Teaching and Learning \(CTL\)](#). The Commons is a showcase for Jefferson books and journals, peer-reviewed scholarly publications, unique historical collections from the University archives, and teaching tools. The Jefferson Digital Commons allows researchers and interested readers anywhere in the world to learn about and keep up to date with Jefferson scholarship. This article has been accepted for inclusion in *Modern Surgery, 4th edition, by John Chalmers Da Costa* by an authorized administrator of the Jefferson Digital Commons. For more information, please contact: JeffersonDigitalCommons@jefferson.edu.

VII. ULCERATION AND FISTULA.

An **ulcer** is a loss of substance due to molecular death of a superficial structure. The molecular death is brought about by bacteria. Ordinary ulcers are caused by pus organisms. The action of the pus organisms is the same as in an abscess. A broken abscess becomes an ulcer, and an ulcer is in structure a half-section of an abscess. The floor of an ulcer consists of granulation tissue and corresponds with the abscess-wall. An abscess arises from molecular death within the tissues; an ulcer, from molecular death of a free surface. An ulcer may increase in size by molecular death of adjacent structures or by sloughing, that is to say, by death of visible masses of tissue. A wound healing by granulation is often wrongly called an ulcer. An ulcer must not be confounded with an excoriation. In an ulcer the corium is always, and the subcutaneous tissue is generally, destroyed, and a scar is left after healing. In an excoriation the mucous layer of epithelium is exposed, or this is destroyed and the corium is exposed. In an excoriation the corium is never destroyed, and no scar remains after healing. An ulcer heals by granulation (page 95). Embryonic tissue by vascularization becomes granulation tissue, granulation tissue is converted into fibrous tissue, the fibrous tissue contracts, and by pulling the edges of the ulcer toward each other lessens the size of the cavity. When the granulations reach the level of the skin the epithelium at the edges of the ulcer proliferates and the sore is soon covered over with new epithelium.

Necrosis of a superficial part may arise from—(1) Inflammation. The pressure of the exudate can cut off the circulation, or bacteria may directly destroy tissue. Suppuration occurs. (2) The action of pus bacteria, causing primary cell-necrosis. (3) Bacteria of putrefaction and organisms of suppuration acting upon a wound. (4) Traumatism or irritants, producing at once stasis, which is added to by secondary inflammation, the exudate undergoing purulent liquefaction. (5) Prolonged pressure. (6) Deficient blood-supply. (7) Faulty venous return. (8) Degeneration of a neoplastic infiltration (gummatous, malignant, or tuberculous). (9) Trophic disturbance. (10) Nutritional disturbances (as scurvy). Most ulcers are due to pus organisms, and even areas of necrosis that arise from something else (as gummatous degeneration) are likely to suppurate.

Classification.—Ulcers are classified into groups according to the condition of the ulcer and the associated constitutional state. In the first group we find the varicose, hemorrhagic, acute, chronic, irritable, neuralgic, etc. In the second group are placed the tuberculous, syphilitic, senile, scorbutic, etc. All ulcers, whatever their origin, are either *acute* or *chronic*, and such conditions as great pain, hemorrhage, edema, exuberant granulations, phagedena, sloughing, eczema, gout, syphilis, scurvy, etc., are to be looked upon as complications. The leg is so common a site of ulcers as to warrant a special description of ulcers of this part. In describing an ulcer state the patient's previous history; the supposed cause; the situation; the outline; the duration; and the mode of onset of the ulcer. State if the ulcer is single or if multiple sores exist, and if there is or is not pain. Whether or not any healing has ever occurred, and the patient's constitutional condition. Set forth the

complications; the state of anatomically related glands; the condition of the edge, the floor, and the parts about the ulcer, and the nature and quantity of the discharge.

Acute or inflamed ulcer of the leg may follow an acute inflammation and may be acute from the start, or may be first chronic and then become acute. It is especially common in drunkards, and among those of dilapidated constitutions. It is characterized by rapid progress and intense inflammation. There is rarely more than one ulcer. In outline these ulcers are usually oval, but may be irregular. The floor of an acute ulcer contains no granulations, but is composed of the raw and inflamed tissues, or is covered with a mass of gray aplastic lymph, or it may have upon it large greenish sloughs. The edges are thin and undermined. The discharge is very profuse and ichorous, excoriating the surrounding parts. The adjacent cutaneous surface is inflamed and edematous, and there is much burning pain. In some cases the glands in the groin enlarge. Constitutionally, there is gastro-intestinal derangement, but rarely fever. When the ulcer spreads with great rapidity and becomes deeper as well as larger in surface area, it is called "phagedenic." The formation of sloughs indicates that tissue death is going on so rapidly that the dead portions have not time to break down and be cast off. Limited stasis produces molecular death; more extensive stasis, a slough. If a chronic ulcer becomes acute, the granulations are destroyed.

Treatment.—In treating an acute ulcer of the leg, give a dose of blue mass or calomel, followed in eight or ten hours by a saline (ʒij each of Rochelle and Epsom salts), and order light diet. Deny stimulants except in a case of diphtheritic ulcer. Administer opium if pain is severe. Spray the ulcer with hydrogen peroxid, use the scissors and forceps to get rid of sloughs, and after sloughs are removed wash the ulcer with corrosive sublimate solution (1 : 1000), or paint it with pure carbolic acid. Paint the skin adjacent to the ulcer with equal parts of tincture of iodine and alcohol. Dress with hot antiseptic fomentations. Apply a bandage from the toes to well above the ulcer. Insist on the patient remaining in bed with the leg slightly elevated. Change the dressings before they become cool and always as soon as they are saturated with discharge. Every day paint the parts about the ulcer with equal parts of iodine and alcohol.

Many cases do very well after antiseptization, and dusting the ulcer with iodoform, lead-water and laudanum being applied to the inflamed parts around the ulcer; but in a bad case hot antiseptic fomentations, compression, and elevation are more useful until sloughs separate. If the discharge is offensive, apply acetanilid, aristol, or iodoform, or use gr. iij of chloral to ʒj of water, before applying hot fomentations or ordinary antiseptic dressings. A 25 per cent. ointment of ichthyol is very useful when applied to parts around the ulcer. If sloughs continue to form, touch the sloughing area with a 1 : 8 solution of acid nitrate of mercury or with a solution of pure carbolic acid, and reapply antiseptic fomentations. If an ulcer continues to spread, clean with peroxid of hydrogen, dry with absorbent cotton, touch with nitrate of mercury solution (1 : 8), and apply an antiseptic fomentation. Repeat application of nitrate of mercury every day until the ulcer ceases to extend and granulations begin to form. When granulations begin to form moist hot dressings are no longer necessary, and dry aseptic or antiseptic dressings can be used.

If an ulcer is covered with a great mass of aplastic lymph, touch daily with a solution of silver nitrate (gr. xl to $\bar{3}j$) or with acid nitrate of mercury (1 : 15), and dress with iodoform and antiseptic fomentations. Give internally tonics, stimulants, and nutritious liquid food. In any case, when granulations form, dress antiseptically with dry dressings, or employ a non-irritant ointment, such as cosmolin. If granulations form slowly, touch them every day with a solution of silver nitrate (gr. x to $\bar{3}j$) and dress antiseptically, or apply a stimulating ointment (resin cerate or $\bar{3}j$ of ung. hydrarg. nitratis to $\bar{3}vij$ of ung. petrolii, or an ointment of copper sulphate, gr. iij to $\bar{3}j$), or dress with gauze soaked in a solution of 3 drops of nitric acid to $\bar{3}j$ of gum Arabic.

Chronic ulcer of the leg is characterized by low action and slow progress. It may be chronic from the start, or it may result from acute ulcer. Usually it is found as a solitary ulcer two inches above the internal malleolus. *Syphilitic ulcers* often occur in a group, are usually crescentic, and are frequent upon the front of knee. A *tuberculous ulcer* may have no granulations, but is usually covered with pale edematous granulations, which signify the existence of a tendency to venous stasis. The edges of the tuberculous ulcer are undermined and irregular, the parts about it are livid and tender, and the discharge is thin and scanty (page 181). An ordinary chronic ulcer is circular or oval, and is surrounded by congested, discolored, and indurated skin, this induration being due to fibrous tissue, and there is often eczema or a brown pigmentation of the neighboring skin. The floor of the ulcer is uneven, and usually is covered with granulations, each of which is red and the size of a pin-point, but which may be exuberant or edematous. If granulations are absent, the ulcer has the appearance of a piece of liver, or is smooth and glazed. The edges are thick, turned out, and not sensitive to the touch. Occasionally, but rarely, they are thin and undermined. Some ulcers are indurated and adherent; this adhesion to the deeper structures prevents healing by antagonizing contraction. An ulcer may fail to heal because of severe infection; because of want of rest; because of absence of granulations resulting from deficient blood-supply; because of edematous granulations; because of exuberant granulations; because of adhesion to deep structures, and because of some constitutional disease.

Treatment.—In treating a chronic ulcer, give a saline cathartic every day or so. Treat any existing diathesis. Insist on rest and, if possible, elevation. Asepticize the ulcer. Draw blood by shallow scarifications of the bottom and edges of the ulcer and the skin about it. If the ulcer is adherent to deeper structures, make incisions like those shown in Fig. 50, each cut going through the deep fascia. These incisions, besides permitting contraction, allow granulations to sprout in the cuts and absorb exudate. After incision keep the part elevated and dressed antiseptically for two days. In two

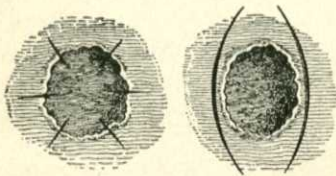


Fig. 50.—Incisions for adherent ulcer.

days after scarification or incision scrape the ulcer with a curet until sound tissue is reached. Use hot antiseptic fomentations for two days more, then paint the parts adjacent to the ulcer with tincture of iodine and alcohol (1 : 3), dress the parts about the ulcer with ichthyol ointment, and dress the ulcer

antiseptically or with sterile gauze. In a day or so the use of ichthyol can be discontinued and the ulcer can be dressed antiseptically with sterile gauze, normal salt solution, boric acid, bichlorid of palladium, chlorin-water, a solution of permanganate of potassium, sulphur, glutol, protonuclein, or bovinin. Glutol (formalin-gelatin) is very useful in some cases and so is protonuclein. When healing begins, treat as outlined for healing acute ulcer (page 129).

Unna's dressing is satisfactory in many cases. It is applied as a fluid, painted on when hot. It solidifies on cooling and resembles rubber. The paint is made as follows: Dissolve 4 parts of the best gelatin in 10 parts of water by means of a hot-water bath. While the fluid is hot add 10 parts of glycerin, and then 4 parts of powdered white oxid of zinc and stir energetically until the mixture is cold. Melt the paint by setting the receptacle in a hot-water bath. The extremity must be clean and thoroughly dry. Apply the paint from just above the roots of the toes to just below the knee. Cover the layer of paint with a gauze bandage; put over this another layer of paint, then another bandage, and so on until three, four, or five bandages have been applied. To prevent wrinkling, put the bandages on in pieces. The outer layer of the dressing is a coat of the paint. This dressing is worn from four to eight weeks unless it loosens sooner. When it loosens, it is changed. If the ulcer discharges freely and stains the dressing, cut a trap-door in the dressing and through this cleanse the ulcer and apply dressings and a bandage as often as necessary (Michel, in "Chicago Clinic," No. 8, 1900).

An excellent treatment if the patient must walk about is camphor, first recommended by Schulze ("Münchener medicinische Wochenschrift," March 19, 1901). It is most conveniently used, as Walbaum shows, as spirits of camphor ("Münchener medicinische Wochenschrift," June 25, 1901). He applies the dressing in the following manner: Clean the ulcer with green soap, and dress it daily with dressings wet with acetate of aluminium. In about three days the discharge will become scanty and free from odor. It is at this period that camphor should be used. A small piece of gauze wet with spirits of camphor is applied directly and only to the ulcer. Over this is applied a large piece of dry sterile gauze, a rubber dam, a large piece of absorbent cotton, and a bandage from the toes up. Every other day the dressings are removed, the ulcer is washed with a 2 per cent. solution of carbolic acid, and the dressings are reapplied. Usually the ulcer is healed in three weeks.

Complications.—Remove by scissors and forceps any badly damaged tissue. Take out dead bone; slit sinuses; trim overhanging edges. Treat **eczema** locally by washing with ethereal soap and applying powdered oxid of zinc or borated talcum, the leg then being wrapped in cotton. Unna's paint is very useful in chronic eczema. If the part is crusted, the crusts should be removed by applying some oily materials and washing with ethereal soap and water. Ordinary soap should not be used. In an acute case soap and water always do harm and the part is to be cleaned by "gently wiping with cold cream or petrolatum" (Stelwagon, on "Diseases of the Skin"). If crusting is very marked it may be necessary to remove it by means of an ordinary poultice, or, better, a starch poultice made with a 2 per cent. solution of boracic acid. When scales or crusts are slight or absent or when they have been removed, the remedial agent should be applied. The remedies for eczema are legion. Among them are a solution of lead acetate; lead-water

and laudanum; a powder composed of 30 grains of powdered boracic acid and $\frac{1}{2}$ ounce each of talc and zinc oxid; ung. picis liquidæ, \mathfrak{z} j, with sufficient ung. zinci oxidi to make \mathfrak{z} j; $\frac{1}{2}$ ounce of liquor carbonis detergens to 1 pint of water. In every case of eczema place the patient upon a plain and nutritious diet; order him to avoid wines and liquors; give an occasional saline laxative; keep the skin and kidneys active, and if the patient is gouty or rheumatic, give appropriate remedies. The value of arsenic in eczema has been much overrated.

Varicose veins demand either ligation at several points, excision, circumcision by Schede's method (page 329), or the continued use of a flannel roller or a Martin rubber bandage. Never operate on varicose veins if phlebitis exists, unless a clot has formed, in which case apply a ligature above the clot. *Inflammation* is met by rest, elevation, painting the neighboring parts with dilute tincture of iodine, and applying about the ulcer ichthyol ointment. For *calloused edges*, blister, employ radiating incisions, or cut the edges away. Ordinary *thick edges* should be strapped. In strapping use adhesive plaster and do not completely encircle the limb (Fig. 51). When

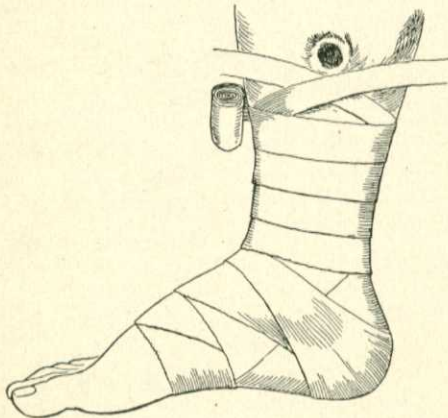

Fig. 51.—Strapping of ulcer of leg (after Liston).

the parts are *adherent* the ulcer is immovable, being firmly anchored to structures beneath it. In such a condition completely or partly surround the sore with a cut through the deep fascia (Fig. 50). This cut sets the ulcer free from its anchorage and permits it to contract. *Edematous granulations* require dry dressings and pressure by a flannel bandage, a rubber bandage, or adhesive plaster. If the bottom of the ulcer is *joul*, dry it and touch with a solution of acid nitrate of mercury (1:8) or with crystals of pure carbolic acid. Repeat this every third day and dress with hot antiseptic fomentations until granulations appear. *Superfluous granulations* (proud flesh) should be cut away with scissors, scraped away, or burned down with a strong solution of silver nitrate or with the solid stick of lunar caustic. *Absence of granulations* or scantiness of granulations means deficiency of blood-supply. The surgeon endeavors to bring more blood to the part, and to do this induces inflammation. The usual method of procedure is to apply daily to the sore a solution of nitrate of silver (10 to 15 grains to the ounce). Argyrol of a strength of 25 per cent. is not painful and is as efficient. In obstinate cases blister the ulcer or scrape it, or paint it with tincture of iodine, or apply pure carbolic acid, or touch it with the actual cautery.

Irritable ulcer is due to exposure of a nerve and destruction of its sheath (page 133). Find with a probe the painful granulation and divide it with a tenotome, or curet the ulcer or burn it with the solid stick of silver nitrate.

If healing entirely fails, *skin-graft*. Among the methods of skin-graft-

ing are—(1) Reverdin's, (2) Thiersch's, and (3) Wolfe's. (See Plastic Surgery.)

When a man having an ulcer must go out and about, the camphor treatment can be employed (page 131), Unna's dressing may be applied (page 131), or the patient can use a firmly applied roller, or, better still, a Martin bandage. Martin's bandage, which is made of red rubber, limits the amount of arterial blood going to the ulcer and favors venous flow from the sore and its neighborhood. The bandage should be used as follows: Before getting out of bed spray the sore with hydrogen peroxid by means of an atomizer, remove the froth with absorbent cotton, wash the leg with soap and water, dry it with a towel, dust the skin with borated talcum powder, and apply the bandage. All of these things should be done before putting the foot to the floor. At night, after getting on the bed, remove the bandage, wash it with soap and water, dry it with a towel, hang it unrolled over the back of a chair to air, and again cleanse the leg and ulcer. If these rules are not strictly observed, the Martin bandage will produce pain, suppuration, and eczema of the leg.

Tuberculous Ulcers (see pages 180, 181).

Syphilitic Ulcers (see page 233).

A **healthy ulcer** is covered with small, bright-red granulations which do not bleed on touching, are painless, and grow rapidly. The edges are soft and show the opalescent blue line of proliferating epithelium. The sore is movable, the discharge is purulent and yellow, and the parts about are not inflamed.

Various Ulcers.—The **fungous** or **exuberant ulcer** is produced by interference with the return of venous blood from the part, and it is specially common after burns and other injuries when cicatricial contraction causes venous obstruction. The granulations are large, deep red in color, bleed when touched, form rapidly, and mount above the level of the skin. The discharge from a fungous ulcer is profuse, thin, and bloody. In the treatment of such an ulcer venous return must be favored by bandaging and by elevation of the part. If the edges are very thick, divide them in a number of places. The superfluous granulations should be burnt down with lunar caustic or should be cut off. Strapping with adhesive plaster or the use of a rubber bandage does good. The sore can be dressed with euophen, aristol, or dry aseptic gauze.

A **varicose ulcer** is an ulcer complicated by varicose veins. It is usually single, is oval, round, or irregular in outline, and is most often seen above the inner malleolus. Its edges are thick, everted, and swollen. The swelling is largely due to edema, and is found to pit on pressure. The edges are not undermined, but slope gently to the floor of the ulcer. The floor is usually covered with rather large granulations which bleed freely on touching. In a varicose ulcer the destruction of tissue often begins at the margin of a congested area and advances toward the center. Such an ulcer is usually surrounded by eczema. To aid the healing of a varicose ulcer it is first of all necessary to favor the return of venous blood from the part by position and bandaging. Martin's bandage is very useful. It may be necessary to operate on the veins.

Erethistic, irritable, or painful ulcers are very sensitive, a condition due to the exposure of nerve-filaments and destruction of nerve-sheaths.

Irritable ulcers are especially found near the ankle, over the tibia, in the anus (fissure), or in the matrix of the nail (ingrowing nail). Curet an erethistic ulcer, and touch with pure carbolic acid or with the solid stick of silver nitrate. Chloral, gr. xx to the ounce, allays the pain; so do cocain and eucaïn for a time. In some cases the painful granulation can be located with a probe and the nerve-filament divided with a tenotome.

The **indolent ulcer** shows no tendency to heal. In such an ulcer there is usually venous congestion from varicose veins or from cardiac weakness. A great mass of scar-tissue forms at the base and edges, which fastens the ulcer to bone or fascia, so that the edges cannot contract. Healthy granulations cease to form. The edges of such an ulcer are thick, smooth, immovable, and free from tenderness. Granulations are entirely absent or there are seen here and there a few unhealthy granulations. The discharge is thin, seropurulent, and offensive. The parts about the ulcer are congested and pigmented. The pigmentation is due to the fact that in an area of chronic congestion numbers of red blood-cells have been disintegrated. Such an ulcer is treated by making incisions to loosen the base and edges, so that contraction can take place, correcting the venous congestion by means of position, the use of compression, in some cases the administration of cardiac stimulants, and in all cases the employment of stimulating applications to the ulcer in order to increase the supply of arterial blood.

The **callous ulcer** is the most chronic form of indolent ulcer and is sunken deeply below the level of the skin. Its border is hard and knobby. Its floor shows no granulations, and is either smooth and glistening or foul and liver-colored. The discharge is thin and scanty, and the ulcer varies little in appearance from week to week or even from month to month. The treatment consists in scraping and cauterizing the ulcer; making radiating incisions through the margins and floor or elliptical incisions about the ulcer; applying antiseptic dressings and a firm bandage. In some cases the ulcer should be strapped. In severe cases it is necessary to extirpate the ulcer and apply skin-grafts.

Hemorrhagic ulcers bleed easily and profusely. Pressure must be applied; it is sometimes necessary to cut or burn away the granulations.

Phagedenic Ulcer.—The phagedenic ulcer results from the profound microbic infection of tissues debilitated by local or constitutional disease, and is commonly venereal. This ulcer has no granulations and is covered with sloughs; its edges are thin and undermined, and it spreads rapidly in all directions. Such an ulcer should be touched with strong caustics or Paque-lin's cautery, and dressed with iodoform gauze and antiseptic fomentations. Tonics and stimulants should always be administered.

The **edematous ulcer** may result from impediment to the venous return or, as Nancrede points out, may be produced by the persistent use of poultices or wet dressings upon any ulcer.* It is most often met with in tuberculous processes and is occasionally seen when varicose veins exist. The granulations are large and pale, and are apt to bend over like unsupported vines. The discharge is profuse and seropurulent. The edges are softened and desquamating. An edematous ulcer requires dry dressings, stimulation, and compression.

* "Principles of Surgery."

A **rodent** or **Jacob's ulcer**, *Noli me tangere*, or **cancroid ulcer** is a superficial epithelioma developing usually from sebaceous glands, sweat-glands, or hair follicles. It requires scraping and cauterization, or, what is better, excision (page 273).

Marjolin's ulcer is an epithelioma arising from a chronic ulcer or an old cicatrix. The malignant change begins at some point of the edge of the ulcer, and its first evidence is induration. The induration spreads slowly and comes to involve a considerable part of or even the entire ulcer. Marjolin's ulcer is the seat of scalding, darting pain; the discharge is profuse, ichorous, and foul, and the floor of the ulcer is uneven, warty, or cauliflower-like. The anatomically related lymph-glands eventually become involved. This involvement is rarely early because induration has blocked lymph-channels. In order to confirm the diagnosis a bit of tissue should be removed and the removed piece must include a portion of the edge of the ulcer and of some

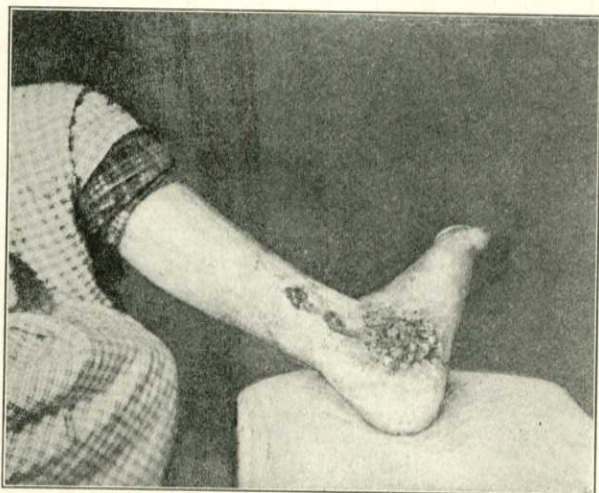

Fig. 52.—Marjolin's ulcer.

apparently sound tissue beyond it. If a microscopical examination shows epithelial infiltration of the apparently sound tissue, a diagnosis of malignant disease must be made. In an early stage of such an ulcer free extirpation and removal of the anatomically related glands may cure the patient. In a more advanced case, if an extremity is involved, amputate and clear out the related lymphatic area. In a very advanced case use the x-rays.

Decubitus, or **bed-sore**, is due to pressure upon an area of feeble circulation (page 151). It is in most instances a condition of gangrene.

Neuroparalytic or **trophic ulcer** is due to impairment of the trophic nerve-fibers or of the trophic centers in the cord.

The **perforating ulcer**, as it was named by Vesigne, commonly affects the plantar surface of the metatarsophalangeal joint or the pulp of the great toe or little toe about a callosity or corn. Very rarely it affects the palm of the hand. The parts about the corn inflame, and pus forms and reaches into the bone. A sinus evacuates the pus by the side of the

corn. A portion of the callous mass is cast off and a shallow ulcer is often exposed. After a time the bone is laid bare or the joint opened. The margins of the ulcer or sinus are surrounded by sprouting granulations and these are encircled by an area of markedly thickened epidermis. In very rare cases more than one ulcer is present. The discharge from a perforating ulcer is thin and scanty and the ulcer, which slowly advances, is very chronic. It is not painful and is slightly, if at all, tender. The foot is cold and often edematous and the parts about the ulcer may be anesthetic. The ulcer may heal when the patient is kept in bed, to open again when he gets about. The disease is far more common among males than among females and is most often met with in the fourth or fifth decades of life. As this ulcer may be present in anesthetic leprosy, in diabetes, peripheral neuritis, syphilis, in a paralyzed limb, and tabes dorsalis, and as the part on which it occurs is apt to be sweaty, cold, and more or less anesthetic, and as the sore may be hereditary, it is usually set down as trophic in origin. Treatment of a perforating ulcer consists, according to Treves, in going to bed and poulticing. Every time a poultice is removed the raised epithelium around the ulcer is cut away and then the poultice is reapplied. In about two weeks an ulcer remains surrounded by healthy tissue. Treves treats this sore with glycerin made to a creamy consistency with salicylic acid, to each ounce of which $\frac{1}{2}$ x of carbolic acid have been added. He directs the patient to wear during the rest of his life some form of bunion-plaster to keep off pressure. Nerve-stretching has been recommended as the proper treatment for perforating ulcer. If in a perforating ulcer the bone is diseased, it must be removed. No matter what treatment is employed, the sore is apt to reappear in the old situation or an adjacent region, when the part is subjected to pressure. Some advise the use of an artificial leg, the knee being kept bent. It may be necessary to amputate the toe or the foot.

The **scorbutic ulcer** is covered with a dark-brown crust, beneath which are pale and bleeding granulations. The parts adjacent are of a violet color.

Epheliomatous, sarcomatous, tuberculous, and syphilitic ulcers and ulcers of the stomach and duodenum are considered under these respective diseases.

Fistula.—A fistula is an abnormal communication between the surface and an internal part of the body, or between two natural cavities or canals. The first form is seen in a rectal fistula, a urethral fistula, or a biliary fistula; and the second form is seen in a vesicovaginal fistula. *Fistulæ* may result from congenital defect, as when there is failure in the closure of the branchial clefts, and can arise from sloughing, traumatism, and suppuration. *Fistulæ* are named from their situation and communications. For instance, a pleural fistula, an intestinal or fecal fistula, a rectal fistula, an anal fistula, a gastric fistula, a bronchial fistula, a vesical fistula, a biliary fistula, etc. Many *fistulæ* are tuberculous and lead to some deeply placed tuberculous focus. A fistula in communication with an internal organ may be maintained by an obstruction the removal of which cures the fistula.

A **sinus** is a tortuous track opening usually upon a free surface and leading down into the cavity of an imperfectly healed abscess. A sinus may be an unhealed portion of a wound. Many sinuses are due to pus burrowing subcutaneously. A sinus fails to heal because of the presence of some irritant fluid, as saliva, urine, or bile; because of the existence of a foreign-body, as

dead bone, a bit of wood, a bullet, a septic ligature, etc.; or because of rigidity of the sinus-walls, which rigidity will not permit collapse. Sinuses may be maintained by want of rest (muscular movements) and general ill health. The walls of a tuberculous sinus are lined with a material identical with the pyogenic membrane of a cold abscess.

Treatment.—In treating a fistula or a sinus, remove any causative obstruction and any foreign body, lay the channel open, curet, brush with pure carbolic acid, and pack with iodoform gauze. In obstinate cases entirely extirpate the fibrous walls, sew the deeper parts of the wound with buried catgut sutures, and approximate the skin surfaces with interrupted sutures of silkworm-gut. To stimulate a sinus to granulation it is sometimes necessary to touch it throughout with the actual cautery, nitric acid, pure carbolic acid, nitrate of silver fused on a metallic probe, in a solution of a strength of gr. xl to the ounce, or argyrol of a strength of 50 per cent. Fresh air is a necessity to the patient, and nutritious food and tonics must be ordered.