

2015

Hemorrhagic Bullous Dermatitis

Bhuvanesh Govind, MD

Thomas Jefferson University, bhuvanesh.govind@jefferson.edu

Luis Eraso, MD

Thomas Jefferson University, luis.eraso@jefferson.edu

Esteban Gnass, MD

Thomas Jefferson University, esteban.gnass@jefferson.edu

Geno Merli, MD

*Thomas Jefferson University, Geno.Merli@jefferson.edu*Follow this and additional works at: <http://jdc.jefferson.edu/tmf> Part of the [Medicine and Health Sciences Commons](#)[Let us know how access to this document benefits you](#)

Recommended Citation

Govind, MD, Bhuvanesh; Eraso, MD, Luis; Gnass, MD, Esteban; and Merli, MD, Geno (2015) "Hemorrhagic Bullous Dermatitis," *The Medicine Forum*: Vol. 16, Article 19.Available at: <http://jdc.jefferson.edu/tmf/vol16/iss1/19>

This Article is brought to you for free and open access by the Jefferson Digital Commons. The Jefferson Digital Commons is a service of Thomas Jefferson University's [Center for Teaching and Learning \(CTL\)](#). The Commons is a showcase for Jefferson books and journals, peer-reviewed scholarly publications, unique historical collections from the University archives, and teaching tools. The Jefferson Digital Commons allows researchers and interested readers anywhere in the world to learn about and keep up to date with Jefferson scholarship. This article has been accepted for inclusion in *The Medicine Forum* by an authorized administrator of the Jefferson Digital Commons. For more information, please contact: JeffersonDigitalCommons@jefferson.edu.

Hemorrhagic Bullous Dermatitis

Bhuvanesh Govind, MD, Luis Eraso, MD, Esteban Gnass, MD, Geno Merli, MD

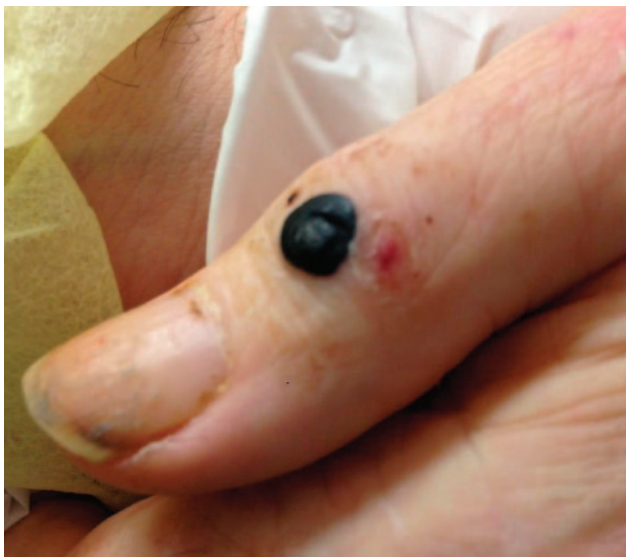

Figure 1. Hemorrhagic Bullous Dermatitis. Well-circumscribed, tense, nontender bullae with no significant surrounding erythema.

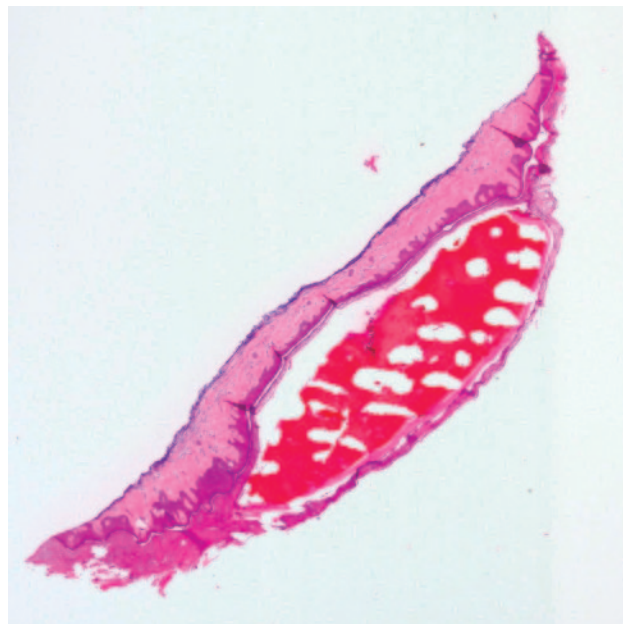


Figure 2. Intraepidermal collection of red blood cells, beneath the keratin layer. (4x power)

The patient is a 64 year old man with active primary central nervous system B-cell lymphoma who was hospitalized for management of a right lower extremity traumatic injury complicated by a calf hematoma. During the hospital stay, the patient was diagnosed with a provoked left lower extremity deep vein thrombosis (DVT) and treated initially with therapeutic dosing of enoxaparin. Five days after low molecular weight heparin (LMWH) initiation, gradual development of tense, well-circumscribed bullae were noted to appear on his arms and hands bilaterally, ranging from 0.5 cm to 1.5 cm in diameter. These lesions were both nonpruritic and nontender with no significant surrounding erythema (Figure 1). Bullae were located distal to the site of enoxaparin injections. Aside from a normocytic normochromic anemia related to chronic medical conditions, results of platelet counts, creatinine levels, and coagulation profiles remained unremarkable. A shave biopsy of one of the lesions revealed an intraepidermal collection of red blood cells without evidence of thrombotic or vasculitic changes (Figures 2 & 3). enoxaparin dose was reduced several days after lesion onset due to increasing calf hematoma size, in an effort to balance anticoagulation benefit for the DVT with risk

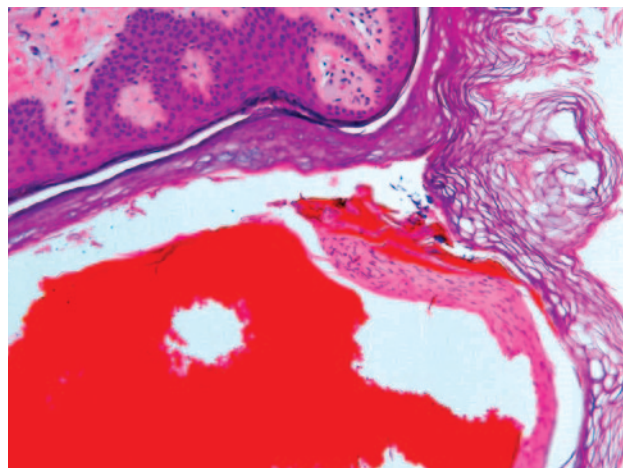


Figure 3. No evidence of thrombotic or vasculitic changes. Hemorrhagic collection with occasional neutrophils. (210x power)

of continued bleeding into the hematoma. The bullae started to regress approximately two weeks after onset, eventually crusting over. The patient was eventually discharged home.

We present a case of hemorrhagic bullous dermatosis, which is a rare type of cutaneous reaction to heparins with only a handful of cases reported in the literature. Delayed-type (type IV) hypersensitivity and immune-mediated (heparin-induced thrombocytopenia) mechanisms are the most common causes of cutaneous complications attributed to heparin products.¹ Type IV cutaneous hypersensitivity reactions are non-antibody mediated and typically occur several days to weeks following drug exposure. They may manifest as isolated or multiple erythematous plaques with papulovesicles or scaling. Heparin-induced thrombocytopenia, on the other hand, can induce skin erythema that progresses to hemorrhage and subsequent tissue necrosis.¹ Several unusual and rare dermatologic manifestations have been reported in the literature with a broad differential diagnosis including pustulosis, toxic epidermal necrolysis, arthus reaction, baboon syndrome, hypereosinophilia, and calcinosis cutis.^{1,3}

There have only been ten cases reported in the literature regarding the clinical setting and course of hemorrhagic bullous. Mechanisms underlying the pathogenesis of these lesions have not been clearly elucidated, although a hypersensitivity reaction has been suspected.^{1,4,5} The histopathology of the bullae reveal intraepidermal collections of red blood cells without any thrombotic or vasculitic changes. Direct immunofluorescence and heparin platelet factor 4 have all been negative in prior case reports.⁴⁻⁷ Only one of the ten cases has reported unfractionated heparin as an inciting agent for hemorrhagic bullous,⁸ while the remaining have been from LMWH. The age range of affected patients in case reports were 50-90 years old with several having a history of malignancy.⁴⁻⁸

Hemorrhagic bullous seems to take a clinically benign course with no patient report of pain or pruritis. The onset of bullae in our case is consistent with the reported 5 to 21 day window of lesion development reported in the literature. The association between lesion regression and discontinuation of heparin treatment seems to be unclear given that about half of the patients' bullae reported thus far regress despite continuation of

heparin therapy with no changes in dosing. Although the resolution of bullae in our patient occurred several days after enoxaparin dose reduction, it is hard to differentiate whether lesion regression occurred directly due to medication management or the natural history of these seemingly benign, self-limiting, bullae.

REFERENCES

1. Schindewolf M, Lindhoff-Last E, Ludwig RJ, Boehncke WH. Heparin-induced skin lesions. *Lancet*. 2012; 380: 1867-79.
2. Ludwig, RJ, et al. Management of Cutaneous Type IV Hypersensitivity Reactions Induced by Heparin. *Journal of Thrombosis and Haemostasis*. 2006; 96: 611-617.
3. Hirsh, J., et al. Heparin and low-molecular-weight heparin mechanisms of action, pharmacokinetics, dosing, monitoring, efficacy, and safety. *Chest*. 2001: 64S-94S.
4. Villanueva CA, Najera L, Espinosa P, Borbujo J. Bullous hemorrhagic dermatosis at distant sites: a report of 2 new cases due to enoxaparin injection and a review of the literature. *Actas Dermosifiliograficas*. 2012; 103(9): 816-819.
5. Maldonado Cid, Paola, et al. Bullous hemorrhagic dermatosis at sites distant from subcutaneous injections of heparin: A report of 5 cases. *Journal of the American Academy of Dermatology*. 2012: e220-e222.
6. Pena ZG, Suszko JW, Morrison LH. Hemorrhagic Bullae in a 73-year old man. *JAMA Dermatology*. 2013; 149(7): 871-872.
7. Perrinaud A, Jacobi D, Machet MC, et al. Bullous hemorrhagic dermatosis occurring at sites distant from subcutaneous injections of heparin: three cases. *J Am Acad Dermatol*. 2006; 54: S5-7.
8. Choudry S., Fishman PM, Hernandez C. Heparin-induced bullous hemorrhagic dermatosis. *Cutis*. 2013; 91(2): 93-98.