

2-19-2015

# Bilayer Button Graft for Endoscopic Repair of High-Flow Cranial Base Defects

Chris Luminais

*Thomas Jefferson University, [chrisluminais@gmail.com](mailto:chrisluminais@gmail.com)*

M. L. Otten

*Thomas Jefferson University*

A. A. Farag

*Thomas Jefferson University*

P. Soni

*Thomas Jefferson University*

W. Mohiuddin

*Thomas Jefferson University*

*See next page for additional authors*

## [Let us know how access to this document benefits you](#)

Follow this and additional works at: <http://jdc.jefferson.edu/otograndrounds>

 Part of the [Otolaryngology Commons](#)

---

### Recommended Citation

Luminais, Chris; Otten, M. L.; Farag, A. A.; Soni, P.; Mohiuddin, W.; Ziegler, N.; Nyquist, G. G.; Farrell, C.; Rosen, M. R.; and Evans, J. J., "Bilayer Button Graft for Endoscopic Repair of High-Flow Cranial Base Defects" (2015). *Department of Otolaryngology - Head and Neck Surgery Faculty, Presentations and Grand Rounds*. Presentation 38.  
<http://jdc.jefferson.edu/otograndrounds/38>

---

**Authors**

Chris Luminais, M. L. Otten, A. A. Farag, P. Soni, W. Mohiuddin, N. Ziegler, G. G. Nyquist, C. Farrell, M. R. Rosen, and J. J. Evans

# Bilayer Button Graft for Endoscopic Repair of High-Flow Cranial Base Defects

Otten ML, Farag AA, Illoreta AM, Soni P, Luminais C, Mohiuddin W, Ziegler N, Nyquist GG, Farrell C, Rosen MR, Evans JJ

## Introduction

Closure of dural defects in trans-nasal, extended, endoscopic techniques remains a challenge, and published cerebrospinal fluid (CSF) leak rates are higher than rates for trans-cranial approaches. Development of a technique that used a vascularized, nasoseptal flap (NSF) significantly reduced the rate of CSF leak, and several groups have developed ways to buttress the NSF. A closure technique developed at our institution uses a bilayer "button" of fascia lata. The initial series of twenty patients repaired with this method from 2007 to July 1, 2009 were presented, with a CSF leak rate of 10% (Luginbuhl et al 2010).

## Methods

We reviewed cases between July 1<sup>st</sup>, 2009 through January 31<sup>st</sup>, 2014. These patients had high flow leaks, which involved openings into a cistern or ventricle. The included patients had a primary "button" graft, which was constructed from a fresh piece of fascia lata. The inlay portion was 25-30% larger than the defect, and the onlay portion was 5-10% larger than the defect. The two pieces were sutured together with two to four, 4-0 Neuroilon sutures (Ethicon, Bridgewater, NJ). They were then inserted in the subdural and epidural spaces, forming a water-tight seal.

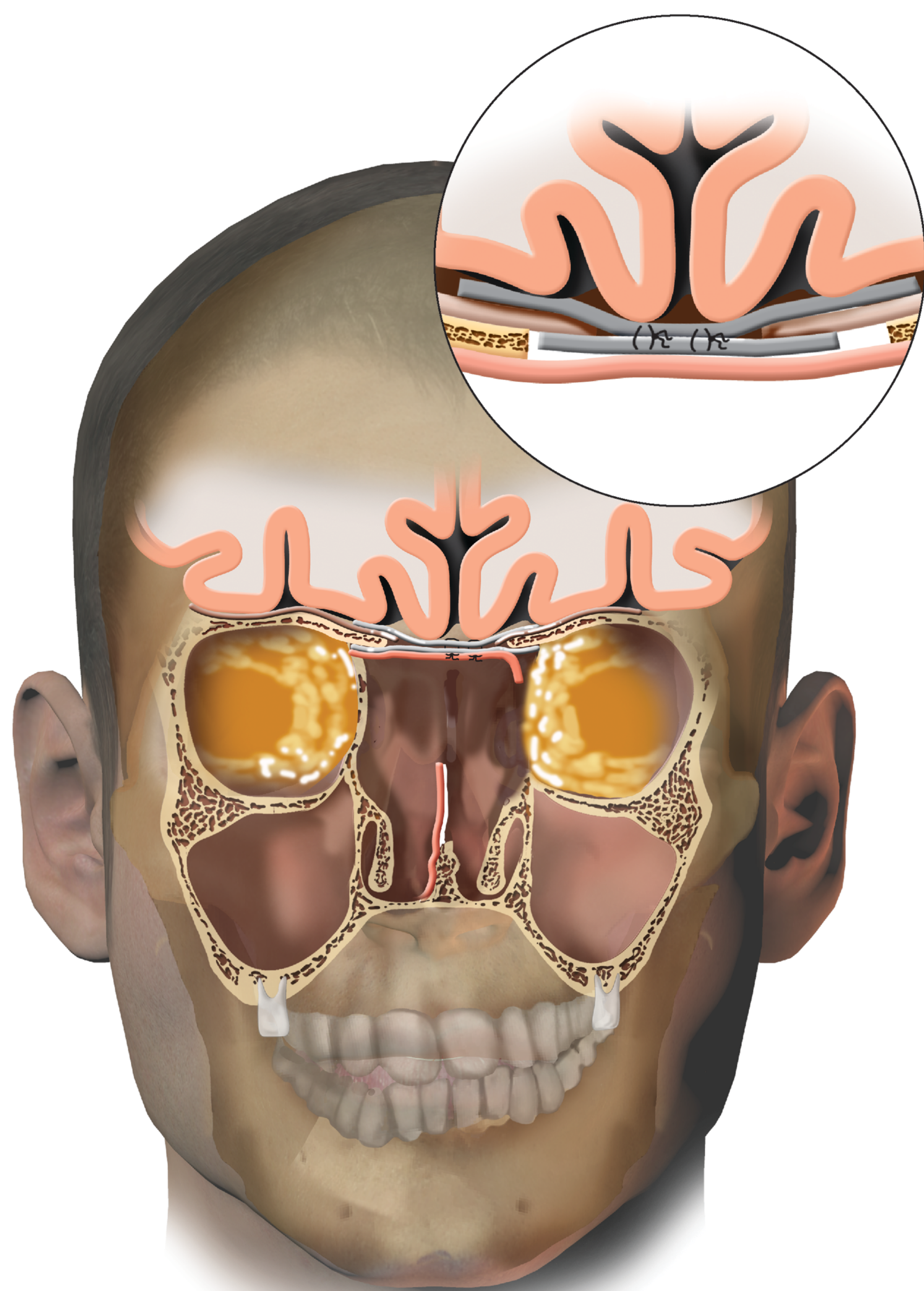


Figure 1: Bilayer button graft closure of the anterior cranial base with a nasoseptal flap

## Results

Of the sixty-six cases that had button graft placement, seven (11%) did not have a NSF, and none of these leaked. There were two (3%) patients who had post-operative leaks. The population characteristics included an average age of 54 years and an average Body Mass Index of 30. In 59/66 (89.4%) of cases, a nasoseptal flap was placed. Anterior skull base meningiomas represented 29% of the pathology, craniopharyngiomas were 27%, macroadenomas were 15%, esthesioneuroblastomas were 6%, and Rathke's cleft cysts were also 6%. Lumbar drains were placed at surgery in only 9/66 (13.6%) cases, and average length of stay was six days.

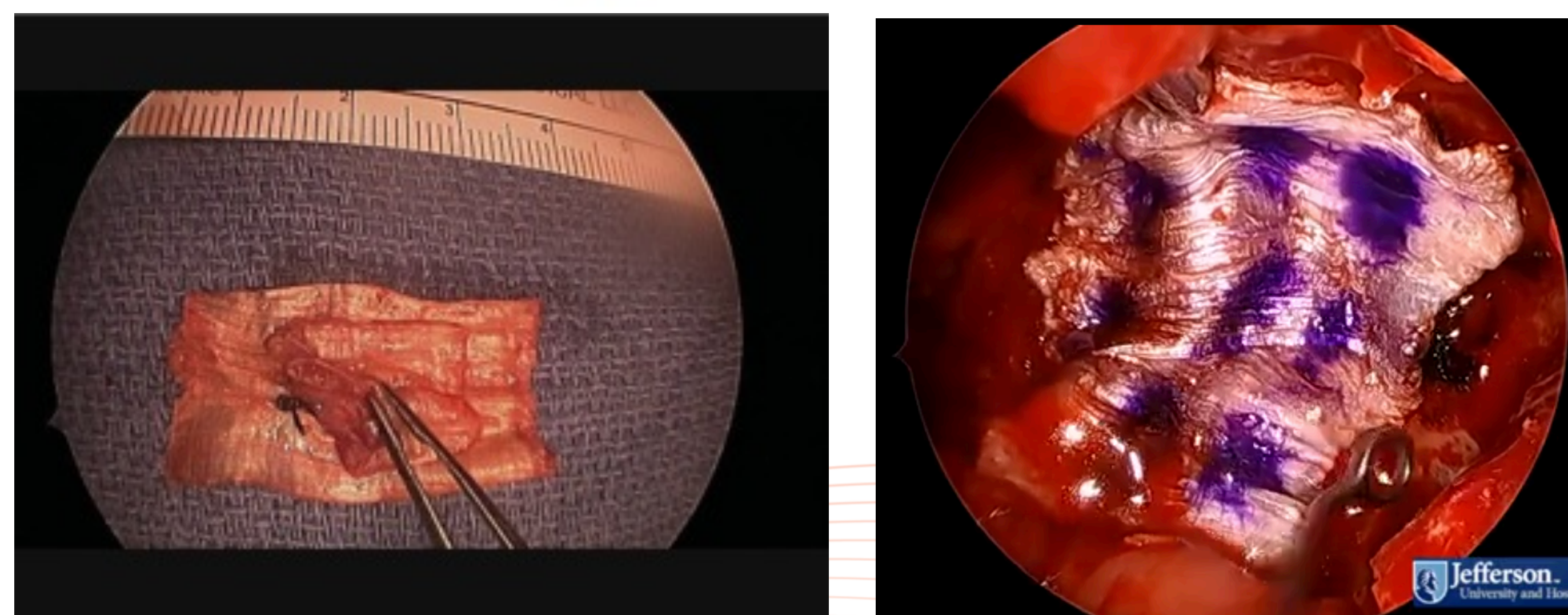
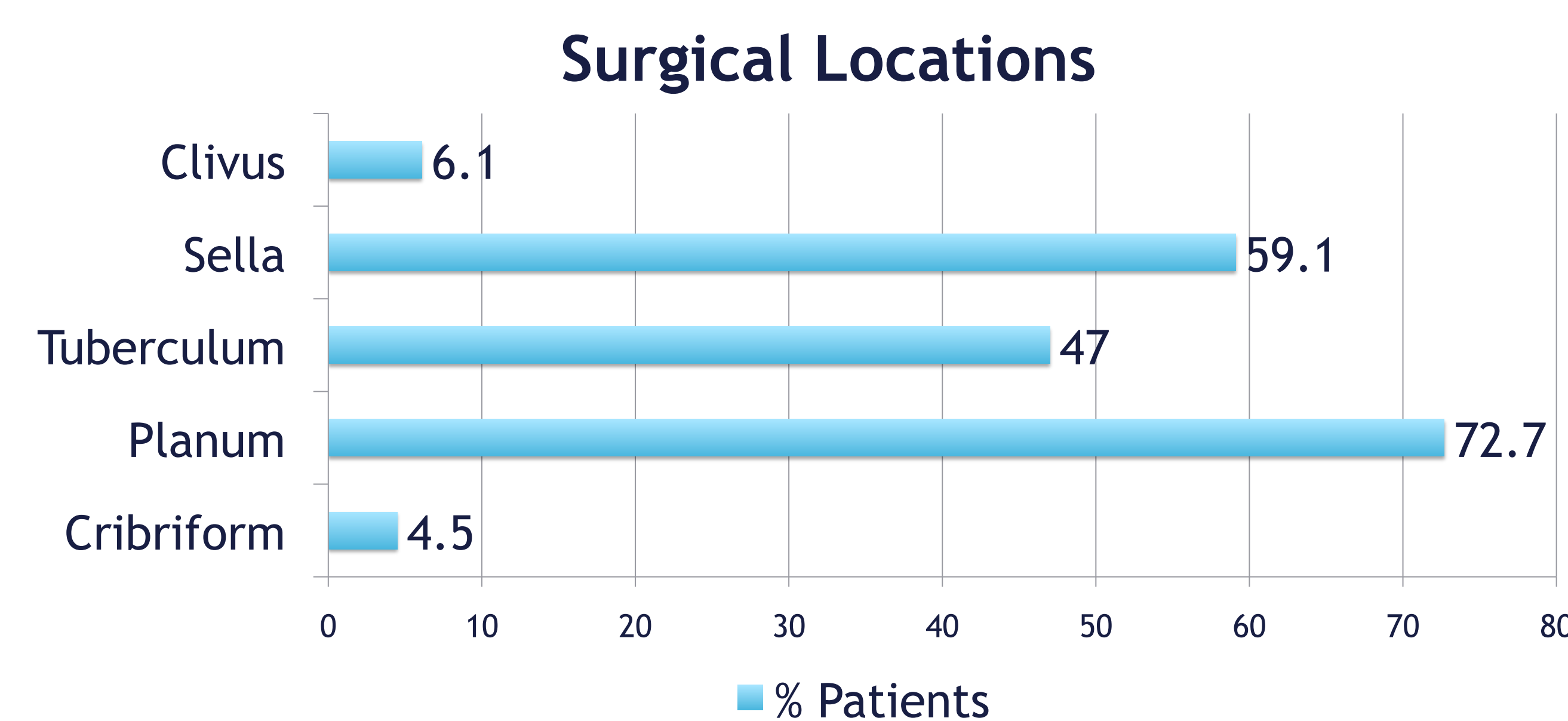
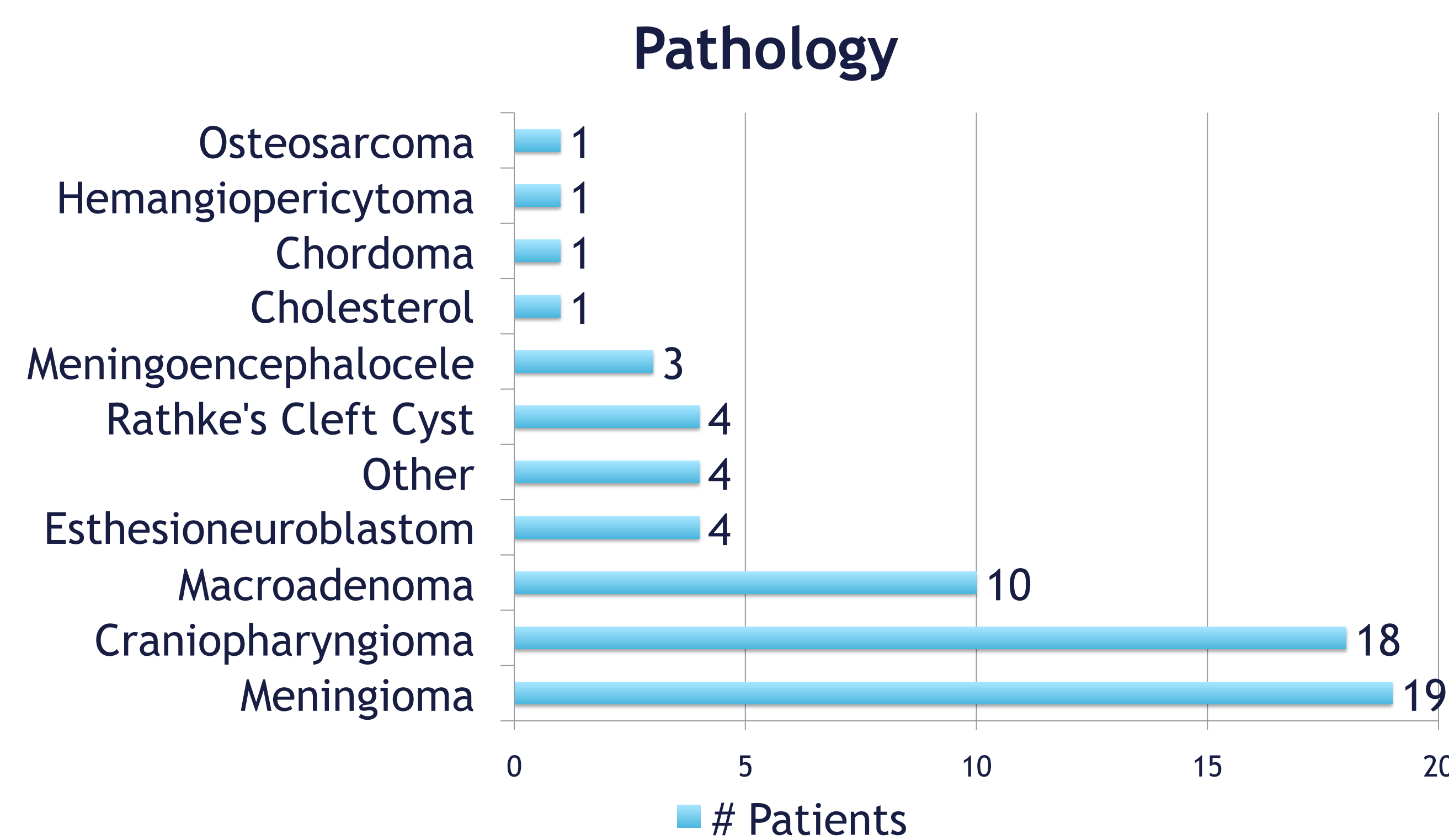



Figure 2: Illustration (top) and intraoperative pictures (bottom) of the bilayer button graft

## Discussion

The bilayer button graft was used successfully to repair large skull base defects with high-flow CSF leaks. The button graft has a low (3%) rate of postoperative CSF leak, which is comparable to leak rates reported for other techniques, such as the gasket seal (Garcia-Navarro et al 2011). Of the two cases that had postoperative leaks, one was a revision of a Rathke's cleft cyst and the other was a meningioma; both cases involved the tuberculum. Notably, 47% of cases involved the tuberculum, a region that can be difficult to close. This area remains challenging, but it is our belief that the flexible composition of the bilayer button graft allows it to be placed more easily and successfully in the angle of the tuberculum.



## Conclusions

The bilayer button graft is a useful supplement to the nasoseptal flap in trans-nasal, endoscopic, skull base surgery. It can be used to close large defects that involve high-flow leaks. Furthermore, our CSF leak rate is comparable to that reported for trans-cranial approaches.

## References

- Luginbuhl, A. J., Campbell, P. G., Evans, J., & Rosen, M. (2010). Endoscopic repair of high-flow cranial base defects using a bilayer button. *The Laryngoscope*, 120(5), 876-880.
- Garcia-Navarro, V., Anand, V. K., & Schwartz, T. H. (2011). Gasket seal closure for extended endonasal endoscopic skull base surgery: efficacy in a large case series. *World neurosurgery*.

## Contact Information

Dr. Marc R. Rosen: Marc.Rosen@jefferson.edu  
Dr. James Evans: James.Evans@jefferson.edu