



Thomas Jefferson University  
Jefferson Digital Commons

Department of Emergency Medicine Faculty Papers

Department of Emergency Medicine

1-1-2013

# Rewarming for accidental hypothermia in an urban medical center using extracorporeal membrane oxygenation.

David Morley

*Thomas Jefferson University, David.Morley@jefferson.edu*

Kentaro Yamane

*Thomas Jefferson University*

Rika O'Malley

*Thomas Jefferson University*

Nicholas Cavarocchi

*Thomas Jefferson University, Nicholas.Cavarocchi@jeffesron.edu*

Hitoshi Hirose

*Thomas Jefferson University, Hitoshi.Hirose@Jefferson.edu*

## [Let us know how access to this document benefits you](#)

Follow this and additional works at: <http://jdc.jefferson.edu/emfp>

 Part of the [Emergency Medicine Commons](#)

### Recommended Citation

Morley, David; Yamane, Kentaro; O'Malley, Rika; Cavarocchi, Nicholas; and Hirose, Hitoshi, "Rewarming for accidental hypothermia in an urban medical center using extracorporeal membrane oxygenation." (2013). *Department of Emergency Medicine Faculty Papers*. Paper 19.  
<http://jdc.jefferson.edu/emfp/19>

This Article is brought to you for free and open access by the Jefferson Digital Commons. The Jefferson Digital Commons is a service of Thomas Jefferson University's [Center for Teaching and Learning \(CTL\)](#). The Commons is a showcase for Jefferson books and journals, peer-reviewed scholarly publications, unique historical collections from the University archives, and teaching tools. The Jefferson Digital Commons allows researchers and interested readers anywhere in the world to learn about and keep up to date with Jefferson scholarship. This article has been accepted for inclusion in Department of Emergency Medicine Faculty Papers by an authorized administrator of the Jefferson Digital Commons. For more information, please contact: [JeffersonDigitalCommons@jefferson.edu](mailto:JeffersonDigitalCommons@jefferson.edu).

**Received:** 2012.11.03  
**Accepted:** 2012.12.21  
**Published:** 2013.01.08

**Authors' Contribution:**

- A** Study Design
- B** Data Collection
- C** Statistical Analysis
- D** Data Interpretation
- E** Manuscript Preparation
- F** Literature Search
- G** Funds Collection

## Rewarming for accidental hypothermia in an urban medical center using extracorporeal membrane oxygenation

**David Morley<sup>1</sup>, Kentaro Yamane<sup>2</sup>, Rika O'Malley<sup>1</sup>, Nicholas C. Cavarocchi<sup>2</sup>, Hitoshi Hirose<sup>2</sup>**

<sup>1</sup> Department of Emergency Medicine, Thomas Jefferson University, Philadelphia, PA, U.S.A.

<sup>2</sup> Division of Cardiothoracic Surgery, Department of Surgery, Thomas Jefferson University, Philadelphia, PA, U.S.A.

### Summary

**Background:**

Accidental hypothermia complicated by cardiac arrest carries a high mortality rate in urban areas. For moderate hypothermia cases conventional rewarming methods are usually adequate, however in severe cases extracorporeal membrane oxygenation (ECMO) is known to provide the most efficient rewarming with complete cardiopulmonary support. We report a case of severe hypothermia complicated by prolonged cardiac arrest successfully resuscitated using ECMO.

**Case Report:**

A 45 year old female was brought to our emergency department with a core body temperature <25°C. Shortly after arrival she had witnessed cardiac arrest in the department. Resuscitative efforts were started immediately including conventional rewarming techniques, followed by ECMO support. ECMO was used successfully in this case to resuscitate this patient from prolonged arrest (3.5 hours) when conventional techniques likely would have failed. After a prolonged hospital course this patient was discharged with her baseline mental and physical capacities intact.

**Conclusions:**

This case demonstrates the advantages of advanced internal rewarming techniques, such as ECMO, for quick and efficient rewarming of severely hypothermic patients. This case supports the use of ECMO in severely hypothermic patients as the standard of care.

**key words:**

**hypothermia • cardiac arrest • extracorporeal membrane oxygenation • rewarming**

**Full-text PDF:**

<http://www.amjcaserep.com/fulltxt.php?ICID=883728>

**Word count:**

1816

**Tables:**

–

**Figures:**

1

**References:**

12

**Author's address:**

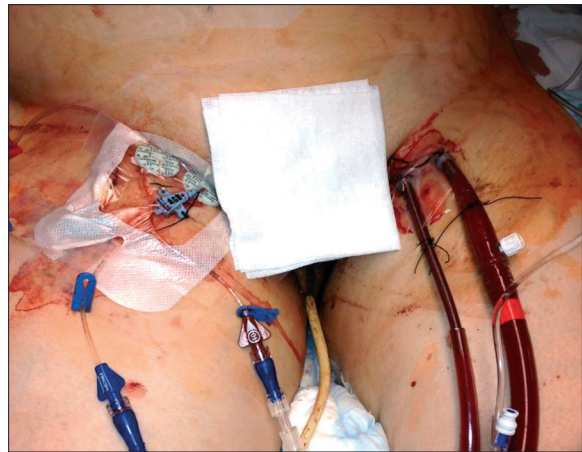
Hitoshi Hirose, Thomas Jefferson University, 1025 Walnut Street Room 605, Philadelphia, PA 19107, U.S.A.,  
 e-mail: Hitoshi.Hirose@jefferson.edu

## BACKGROUND

Accidental hypothermia associated with cardiac arrest is difficult to manage. Conventional rewarming techniques such as using a warming blanket, warm intravenous saline, nasogastric lavage, continuous bladder irrigation and thoracic lavage via chest tubes may not be effective if the patient's core body temperature is below 28°C. Extracorporeal membranous oxygenation (ECMO) is the most effective rewarming method for patients who suffer from severe accidental hypothermia, and also is effective cardiopulmonary support for patients in cardiac arrest. Successful ECMO rewarming for accidental hypothermia has been reported mostly from Northern Europe or Canada with survival rates between 30–47% [1–3]. Here we report a case of successful resuscitation with full neurological recovery using ECMO for accidental hypothermic cardiac arrest observed at an urban medical center in the Northeastern United States.

## CASE REPORT

A 45 year old female was brought in by her caregiver concerned for lethargy. The patient has history of Down syndrome, microcephaly, severe mental retardation and self-abusive behavior. She lives in a group home under 24 hour supervision. The caregiver was unable to provide the details of the patient's activity that day, including the possibility of her being left outside. On the day of presentation there was mild precipitation with an outside temperature ranging from -10°C to -6°C. Upon arrival to our triage area at 5:48 pm, she was lethargic with a Glasgow coma scale of 8 (open eyes to stimuli, incomprehensible speech, and flexing extremities to stimuli). The patient was brought to a resuscitation room and was seen by the emergency physician immediately. Her blood pressure was 94/47 with a heart rate of 30, respiratory rate of 10 and pulse ox of 94% on room air. On palpation, she was "icy cold" and temperature was not obtainable (the rectal thermometer in our facility will not register temperature measurements below 25°C). The patient was minimally responsive, had a weak gag reflex, palpable femoral pulse and clear bilateral breath sounds. Multiple attempts at peripheral access were attempted, but unsuccessful. A warming blanket was placed immediately and warm intravenous fluid was started at 6:40 pm through a triple lumen central line placed in the right femoral vein. Twelve lead EKG showed a junctional rhythm, rate 30 s. Atropine was given for symptomatic bradycardia with no effect. Due to declining mental status and gurgling upper airway sounds, endotracheal intubation was performed for airway protection. At 7:12 pm, no pulse was palpable and blood pressure was not obtainable. Telemetry monitor showed a junctional rhythm, rate 30 s. Advanced cardiac life support (ACLS) protocol for pulseless electrical activity (PEA) was initiated by emergency department personnel. Humidified heated oxygen via the endotracheal tube, in and out warm saline lavage via an orogastric tube and via a three-way foley catheter were started for rewarming. However, the body temperature remained below 25°C despite these conventional rewarming methods. Catecholamines including dopamine, epinephrine, and norepinephrine were started. At 7:50 pm, the patient had no gag reflex, corneal reflex and her pupils were dilated without light reflex.



**Figure 1.** Arterio-venous extracorporeal membrane oxygenation cannulas are placed in the left groin.

Due to limitations of conventional rewarming, cardiothoracic surgery was consulted for ECMO rewarming at 8:00 pm. Cardiopulmonary resuscitation (CPR) with chest compression was continued until initiation of ECMO. Access to the femoral vessels was challenging due to truncal obesity. Finally, an 18 French arterial and a 20 French venous cannula were inserted to the left groin using Seldinger technique, after giving 5000 units of heparin. Veno-arterial ECMO was initiated at 8:40 pm with a flow of 4 liter/min (Figure 1). CPR and catecholamine drips were stopped and rewarming via ECMO heat exchanger was started with control setting at 37°C. Upon initiation of ECMO, rectal temperature was 26.8°C, the patient was pulseless, telemetry monitoring showed agonal rhythm, blood pressure was not obtainable, and her neurologic exam remained unchanged. After 20 minutes of ECMO support, EKG returned to a junctional rhythm with heart rate of 30 s, the arterial pressure was 65 mm Hg without pulsation, the patient started making urine, and body temperature increased to 30°C. The patient's mean arterial pressure was maintained above 60 mm Hg on ECMO without pulsatility. At 10:40 pm, arterial wave form started showing pulsatility despite ECMO flow of 4 liter/min. The patient's temperature gradually increased to a goal temperature of 36.5°C by 11:50 pm. At that time, cardiac motion was visible on bedside echocardiography, a strong carotid pulse was palpated and she began moving extremities to verbal commands. A total of 2 packed red cells were transfused to maintain hemoglobin 10 g/dl and 20 mg of furosemide was given intravenously to facilitate diuresis.

At midnight, an ECMO weaning trial was performed and ECMO flow was decreased to 0.5 L/min. During the weaning trial, the hemodynamics of the patient were maintained with blood pressure 100/58 mm Hg and heart rate 100 in sinus rhythm (without inotropes or pressor support), oxygen saturation 99% and body temperature 36.9°C. Minimum ECMO flow 1.5 L/min was maintained until the surgery team was available for decannulation. ECMO was successfully removed and the access site was repaired at 01:25 am without cardiopulmonary compromise. Total ECMO time was 3 hours 45 minutes.

Subsequent head CT and echocardiography were normal and she was transferred to the intensive care unit for further monitoring. The patient was extubated on hospital day 3,

but remained in the hospital for nearly three months. The patient's lengthy hospital course was complicated by PEG tube placement and subsequent removal, self-abusive behavior and an in-hospital fall. No other complications were observed. The patient's neurologic status, although depressed initially post-intubation, returned to her baseline after approximately one week. No cause was ever found for this patient's hypothermia. An investigation into the patient's social situation by hospital social workers revealed no wrong doing by the patient's living facility. The patient returned to the same assisted living facility upon hospital discharge.

## DISCUSSION

From 1979–2002 there were, on average, 689 deaths each year in the United States attributable to hypothermia [4]. In Philadelphia, the location of our medical center, there were no recent reported deaths attributed to hypothermia [5,6]. Accidental hypothermia is considered a completely preventable form of death. Risk factors for accidental hypothermia in an urban center include alcohol/drug abuse, homelessness and mental illness [1]. Moderate hypothermia (28–32°C) carries a mortality rate around 21% and the mortality rate for severe hypothermia (<28°C) increases to around 40% [3].

Severe hypothermia complicated by cardiac arrest carries even higher mortality rates (53–80%) [1]. Electrolyte abnormalities ( $K^+ > 9$ ), severe acidosis ( $pH < 6.5$ ) and coagulopathy ( $ACT > 400$  s) are extremely poor prognostic factors and prolonged resuscitative efforts may not be indicated if these laboratory values are seen [7]. Even in cases of severe hypothermia with an extremely poor prognosis, declaring brain death in severely hypothermic patients is problematic. A core body temperature  $> 36^\circ\text{C}$  should be maintained before initiating brain death evaluations. Severe hypothermia can cause neurologic depression that can mimic brain death [8]. Metabolism is slowed in hypothermic patients preventing equilibration of  $\text{PaCO}_2$  and complicating apnea testing necessary for assessing brain function [8]. For severely hypothermic patients in cardiac arrest, achieving a core body temperature  $> 36^\circ\text{C}$  may be impossible using conventional warming techniques. If advanced internal rewarming is not available, it may take long time to rewarm the patient to  $33\text{--}35^\circ\text{C}$ , of which temperature allow emergency department physicians to reassess for signs of life [9]. However, as this case demonstrates, ECMO can be used to achieve a target core body temperature quickly.

Compared to conventional rewarming methods, ECMO has several advantages. First, ECMO can provide complete hemodynamic support [10]. ECMO flow is adequate to circulate the entire vascular volume and end-organ damage developed during cardiac arrest can be quickly resolved. CPR can be safely discontinued as soon as ECMO reaches optimal flow. Additionally, inotropic agents can be discontinued decreasing the risk of ventricular tachyarrhythmia. Second, ECMO provides oxygenated blood; allowing ventilator support to be minimized, and therefore reducing the risks of barotrauma and oxygen related pulmonary injury [1–3]. Finally, ECMO rewarms central organs rather than peripheral organs, while conventional methods rewarm peripheral tissue prior to central organs. The degree of the peripheral vasodilation in ECMO is less than conventional

rewarming methods. This allows the heart and brain to be warmed first. Quickly rewarming the myocardium minimizes potential irritation of the 'cold heart' which is prone to ventricular tachyarrhythmia [1].

ECMO requires peripheral cannulation, which can be performed quickly in the emergency department or intensive care unit. The only contraindications to ECMO use are: irreversible brain injury, difficult vascular access, severe aortic regurgitation, and aortic dissection [10]. The requirement of heparin for cannulation is minimal and usually tolerated well by the patients. Our ECMO protocol is a 5000 unit bolus of heparin at the time of cannulation and no further heparin during the first 24 hours minimizing the risk of bleeding associated with anticoagulation needed for ECMO use. Decannulation of ECMO cannula can be done in the emergency department under local anesthesia and mild intravenous sedatives.

Although hypothermia usually acts in a neuro-protective manner [11], many survivors from hypothermic cardiac arrest developed neurological complications, most likely related to cerebral edema due to micro vascular fluid extravasation [2]. ECMO increases third spacing of fluid. Large fluid volumes given during resuscitation further aggravates fluid status contributing to marked cerebral swelling and poor neurologic outcomes if volume status is not followed closely [10]. Due to similar mechanisms, reperfusion pulmonary edema is another major cause of death after rewarming from hypothermic arrest [11,12]. Maintaining appropriate hemoglobin level and aggressive diuresis are key elements in the management of patients undergoing ECMO rewarming.

This successful resuscitation can be attributed to several factors; the patient arrived in our emergency room hypothermic, but still responsive. PEA arrest was witnessed in the emergency department where all medical personal and equipment were available. ACLS protocols were started immediately and chest compressions continued without interruption until the initiation of ECMO. ECMO provided complete hemodynamic support while the patient remained pulseless. The ECMO flow and rewarming processes were steady, monitored closely, and the heart rhythm returned spontaneously.

## CONCLUSIONS

The presented case demonstrates a dramatic survival and neurologic recovery after prolonged hypothermic cardiac arrest (3.5 hours) after rewarming with ECMO. At our urban academic medical center, cardiothoracic surgery service is available 24/7 to initiate ECMO in the appropriate clinical settings. In this case, cardiac arrest occurred on a weekday, after hours when the attending surgeon and perfusionist were not on site. Despite this, ECMO was still started quickly (45 minutes after consultation) while ACLS protocol continued over 90 minutes by emergency department personnel leading to ECMO cannulation in a timely fashion. Traditional rewarming likely would have failed in this case of profound hypothermia and only the immediate availability of ECMO allowed for a positive outcome in this patient. We believe that placing severely hypothermic patients on ECMO in the emergency department provides

the best chance for full recovery and could be the option for the standard of care.

## REFERENCES:

1. Walpoth BH, Walpoth-Aslan BN, Mattle HP et al: Outcome of survivors of accidental deep hypothermia and circulatory arrest treated with extracorporeal blood warming. *N Engl J Med*, 1997; 337: 1500–5
2. Farstad M, Andersen KS, Koller ME et al: Rewarming from accidental hypothermia by extracorporeal circulation. A retrospective study. *Eur J Cardiothorac Surg*, 2001; 20: 58–64
3. Vretnar DF, Urschel JD, Parrott JC, Unruh HW: Cardiopulmonary bypass resuscitation for accidental hypothermia. *Ann Thorac Surg*, 1994; 58: 895–98
4. Hypothermia-related deaths – United States, 2003–2004. Morbidity and mortality weekly report; Reported on February 25, 2005 / 54(07); 173–75. Available from CDC web site: [www.cdc.gov/mmwr/preview/mmwrhtml/mm5407a4.htm](http://www.cdc.gov/mmwr/preview/mmwrhtml/mm5407a4.htm)
5. Mallya G, Herr L, Mehta N: City of Philadelphia Department of Public Health. Vital Statistics Report. 2009. Table M6A, 102–107. Available from Philadelphia Department of Public Health Website: <http://www.phila.gov/health/pdfs/2009%20Vitals%20Report.pdf>
6. Mallya G, Herr L, Mehta N: City of Philadelphia Department of Public Health. Vital Statistics Report. 2008. Table M6A, 91–96. Available from Philadelphia Department of Public Health Website: <http://www.phila.gov/health/pdfs/2008%20Vital%20Statistics%20Report.pdf>
7. Mair P, Kornberger E, Furtwaengler W et al: Prognostic Markers in patients with severe accidental hypothermia and cardiocirculatory arrest. *Resuscitation*, 1994; 27: 47–54
8. Wijdicks EF, Varelas PN, Gronseth GS, Greer DM: American Academy of Neurology. Evidence-based guideline update: determining brain death in adults: report of the Quality Standards Subcommittee of the American Academy of Neurology. *Neurology*, 2011; 74: 1911–18
9. Sawamoto K, Tanno K, Takeyama Y, Asai Y: Successful treatment of severe accidental hypothermia with cardiac arrest for a long time using cardiopulmonary bypass – report of a case. *Int J Emerg Med*, 2012; 5: 9
10. Sidebotham D, McGeorge A, McGuinness S et al: Extracorporeal membrane oxygenation for treating severe cardiac and respiratory disease in adults: Part I-overview of extracorporeal membrane oxygenation. *J Cardiothorac Vasc Anesth*, 2009; 23: 886–92
11. Ruttman E, Weissenbacher A, Ulmer H et al: Prolonged extracorporeal membrane oxygenation-assisted support provides improved survival in hypothermic patients with cardiocirculatory arrest. *J Thorac Cardiovasc Surg*, 2007; 134: 594–600
12. Oberhammer R, Beikircher W, Hörmann C et al: Full recovery of an avalanche victim with profound hypothermia and prolonged cardiac arrest treated by extracorporeal re-warming. *Resuscitation*, 2008; 76: 474–80