



2013

# A 73-Year-Old Female With Palpitations

Kevin M. Curl, MD

*Thomas Jefferson University Hospitals, [Kevin.Curl@jefferson.edu](mailto:Kevin.Curl@jefferson.edu)*

Jacqueline V. Kraft, MD

*Thomas Jefferson University Hospitals, [Jacqueline.Kraft@jefferson.edu](mailto:Jacqueline.Kraft@jefferson.edu)*

Malinda Wu, MSIII

*Thomas Jefferson University*

Carlos Fernandez-Ortega, MSIII

*Thomas Jefferson University*

Follow this and additional works at: <http://jdc.jefferson.edu/tmf>

 Part of the [Medicine and Health Sciences Commons](#)

[Let us know how access to this document benefits you](#)

### Recommended Citation

Curl, MD, Kevin M.; Kraft, MD, Jacqueline V.; Wu, MSIII, Malinda; and Fernandez-Ortega, MSIII, Carlos (2013) "A 73-Year-Old Female With Palpitations," *The Medicine Forum*: Vol. 14, Article 18.

Available at: <http://jdc.jefferson.edu/tmf/vol14/iss1/18>

This Article is brought to you for free and open access by the Jefferson Digital Commons. The Jefferson Digital Commons is a service of Thomas Jefferson University's [Center for Teaching and Learning \(CTL\)](#). The Commons is a showcase for Jefferson books and journals, peer-reviewed scholarly publications, unique historical collections from the University archives, and teaching tools. The Jefferson Digital Commons allows researchers and interested readers anywhere in the world to learn about and keep up to date with Jefferson scholarship. This article has been accepted for inclusion in *The Medicine Forum* by an authorized administrator of the Jefferson Digital Commons. For more information, please contact: [JeffersonDigitalCommons@jefferson.edu](mailto:JeffersonDigitalCommons@jefferson.edu).

## A 73-YEAR-OLD FEMALE WITH PALPITATIONS

Kevin Curl, MD, Jacqueline Kraft, MD, Malinda Wu, MSIII, Carlos Fernandez-Ortega, MSIII

### Background

Atrial fibrillation is a commonly encountered clinical problem. Although a large percentage of patients have no clearly identifiable precipitant, secondary atrial fibrillation is a well-documented clinical entity.<sup>1</sup>

### Case presentation

A 73-year-old female with a history of obstructive sleep apnea, hypertension, and chronic obstructive pulmonary disease presents with complaints of intermittent palpitations, substernal squeezing chest pressure, and shortness of breath for two weeks. Her most recent episode occurred on the bus, prompting her to come to the emergency room for evaluation. Further questioning revealed mild weight loss and diarrhea over the prior few weeks. Home medications included amlodipine, baby aspirin, albuterol as needed, and ciprofloxacin for a recently diagnosed URI.

### Investigation

Vital signs were temperature 99.4°F, blood pressure 140/70, heart rate 154, respiratory rate 14, with oxygen saturation of 95% on room air. Physical exam revealed scattered bilateral rhonchi, irregularly irregular tachycardia, and mild lower extremity edema. Electrocardiogram (ECG) showed atrial fibrillation with a ventricular rate of 137 bpm and non-specific ST/T wave changes. Initial laboratory studies showed negative cardiac markers, normal blood counts, and normal basic metabolic panel. Transthoracic echocardiogram on hospital day 1 was remarkable for a normal ejection fraction (65%) without segmental wall motion abnormalities, severely dilated left atrium (left atrial volume Index 43 cc/m<sup>2</sup>), mild left ventricular hypertrophy, and no significant valvular abnormalities.

Further lab studies revealed a thyroid-stimulating hormone (TSH) less than 0.01mIU/mL and free thyroxine (fT<sub>4</sub>) of 4.1 ng/dL (0.7-1.7 ng/dL). Endocrinology was consulted and recommended empirically starting methimazole 10 mg three times a day along with further thyroid laboratory investigation, and a thyroid ultrasound. Total triiodothyronine (T<sub>3</sub>) was 325ng/dL (90-180ng/dL), free T<sub>3</sub> was 15.3pg/dL (2-4.4 pg/dL), and thyroid ultrasound revealed a rounded homogeneous thyroid without any dominant nodules greater than 1cm. A thyroid uptake scan (Figure 1) exhibited rapid iodine turnover consistent with Graves' disease. Eventually, thyroid stimulating immunoglobulin returned at a level of 620% (normal <140%)

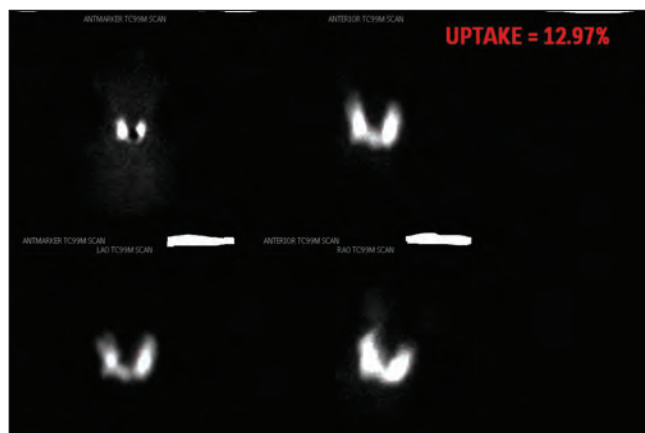
and anti-thyroid peroxidase antibody level was 530.5 units (0-100 units).

### Treatment

The patient's heart rate was initially controlled with intravenous beta-blockers. She was fully anticoagulated for her new-onset atrial fibrillation. The patient's rate control improved with oral metoprolol in addition to methimazole. She spontaneously converted to sinus rhythm on treatment day 3 of this regimen. Her heart rhythm remained in sinus throughout the rest of her hospitalization, and she was discharged with a enoxaparin to warfarin. She was asked to follow-up with endocrinology as an outpatient to discuss further treatment options for her hyperthyroidism, including possible radioactive ablation.

### Outcome and follow-up

The patient has been seen in follow-up in the cardiology clinic. Office exam and ECG revealed frequent atrial ectopy and it is possible that this patient has subclinical paroxysmal atrial fibrillation episodes. She is rate controlled with metoprolol and is anticoagulated with warfarin, which she is to continue for three months. After three months, a one week outpatient telemetry will be ordered to assess her burden of atrial fibrillation. Should she be free of atrial fibrillation, the possibility of discontinuing her warfarin and maintaining her on aspirin mono-therapy will be discussed with the patient.



**Figure 1.** Thyroid uptake scan showing diffuse thyroid uptake without a dominant “hot” nodule. These findings are consistent with Graves’ disease.

## Discussion

Atrial fibrillation is the most common arrhythmia in patients with thyrotoxicosis. Prevalence of atrial fibrillation in hyperthyroidism ranges between less than 2% to 20%.<sup>1,2</sup> Increasing age, male sex and structural heart disease, such as ischemic heart disease, congestive heart failure and valvular disorders (especially mitral valve prolapse), are associated with increased risk of atrial fibrillation in patients with hyperthyroidism.<sup>3</sup> While it is common for hyperthyroid patients to develop atrial fibrillation, less than 1% of all atrial fibrillation patients have hyperthyroidism.<sup>4</sup>

The mechanism by which hyperthyroidism predisposes to atrial fibrillation has not been clearly identified.<sup>1</sup> Thyroid hormone shortens cardiomyocyte refractory period by upregulating the transcription of  $\beta$ -adrenergic receptors, resulting in an increased cAMP that subsequently accelerates diastolic depolarization and increases heart rate. Thyroid hormone shortens the action potential duration of isolated rabbit pulmonary vein cardiomyocytes, which decreases refractoriness and facilitates the genesis of reentrant circuits, thereby increasing the arrhythmogenic activity of pulmonary vein cardiomyocytes.<sup>5</sup>

The cardiovascular manifestations of hyperthyroidism are best corrected by treating the underlying thyrotoxicosis with either antithyroid drug therapy or radioactive iodine thyroid ablation.<sup>1</sup> Pharmacotherapy with methimazole or propylthiouracil can provide a more rapid reduction in serum T4 and T3 than radioactive iodine ablation and is often utilized to prevent the potential thyrotoxicosis exacerbation that can occur with therapeutic doses of radioiodine.<sup>6</sup> Methimazole is typically preferred to propylthiouracil, except during the first trimester of pregnancy, because it can more rapidly reverse thyrotoxicosis and has fewer side effects. Both serum T4 and T3 should be monitored in the treatment of thyrotoxicosis because serum T3 concentrations may remain elevated even with normalization of serum T4.<sup>7</sup> In comparison with the importance of serum T3 and T4 values, serum TSH values may be misleading during the initial period of treatment.<sup>8</sup>

Patients under 60 years of age without preexisting heart disease and short duration thyrotoxicosis typically spontaneously convert to normal sinus rhythm within 6 weeks; the frequency of conversion decreases in older patient populations, who

frequently require interventions.<sup>9</sup> The treatment of atrial fibrillation in thyrotoxicosis should be limited to rate control, as cardioversion and normal sinus rhythm cannot be reliably maintained while thyrotoxicosis persists.<sup>1</sup> Patients who experience atrial fibrillation as a complication of thyrotoxicosis are at increased risk of thromboembolism, and should be anticoagulated according to non-valvular atrial fibrillation guidelines. Because thyrotoxicosis is associated with increased plasma clearance of vitamin K-dependent coagulation factors, the dose of warfarin required to achieve full anticoagulation in these patients is lower.<sup>10</sup>

## Key Points

Patients presenting with arrhythmias should be screened for thyroid dysfunction. These arrhythmias are best corrected with treatment of underlying thyroid disease. Atrial fibrillation secondary to thyrotoxicosis should be treated with rate control, as cardioversion cannot reliably maintain sinus rhythm.

## References

1. Klein I, Danzi S. Thyroid disease and the heart. *Circulation*. 2007;116:1725-1735.
2. Klein I, Ojamaa K. Thyroid hormone and the cardiovascular system. *N Eng J Med*. 2001;344:501-509.
3. Frost L, Vestergaard P, Mosekilde L. Hyperthyroidism and risk of atrial fibrillation or flutter: a population-based study. *Arch Intern Med*. 2004;164:1675-1678.
4. Sawin CT, et al. Low serum thyrotropin concentrations as a risk factor for atrial fibrillation in older persons. *N Eng J Med*. 1994;331:1249-1252.
5. Chen YC, Chen SA, Chen YJ, Chang MS, Chan P, Lin CI. 2002. Effects of thyroid hormone on the arrhythmogenic activity of pulmonary vein cardiomyocytes. *J Am Coll Cardiol*. 2002;39:366-372.
6. Woeber, KA. Current Concept: Thyrotoxicosis and the Heart. *N Eng J Med*. 1992 Jul 9;327(2):94-8.
7. Takamatsu J, Hosoya T, Naito N, et al. Enhanced thyroid iodine metabolism in patients with triiodothyronine-predominant Graves' disease. *J Clin Endocrinol Metab*. 1988;66:147.
8. Ross DS, Daniels GH, Gouveia D. The use and limitations of a chemiluminescent thyrotropin assay as a single thyroid function test in an out-patient endocrine clinic. *J Clin Endocrinol Metab*. 1990;71:764.
9. Petersen P, Hanen JM. Stroke in thyrotoxicosis with atrial fibrillation. *Stroke*. 1988;19:15-8.
10. Shenfield GM. Influence of thyroid dysfunction on drug pharmacokinetics. *Clin Pharmacokinet*. 1981;6:275-97.