



2013

# Paraneoplastic Acral Vascular Syndrome

Daniel M. Kopolovich, MSIII  
*Thomas Jefferson University*

Dean D. Lagonosky, MSIII  
*Thomas Jefferson University*

Allison A. Greco, MSIV  
*Thomas Jefferson University*

Emma Weaver, MD  
*Thomas Jefferson University Hospital, Emma.Weaver@jefferson.edu*

Rahul Malhotra, MD  
*Thomas Jefferson University Hospital, Rahul.Malhotra@jefferson.edu*

*See next page for additional authors*

Follow this and additional works at: <http://jdc.jefferson.edu/tmf>

 Part of the [Medicine and Health Sciences Commons](#)

[Let us know how access to this document benefits you](#)

## Recommended Citation

Kopolovich, MSIII, Daniel M.; Lagonosky, MSIII, Dean D.; Greco, MSIV, Allison A.; Weaver, MD, Emma; Malhotra, MD, Rahul; Holmes, MD, Phoebe; and Stewart, MD, John R. (2013) "Paraneoplastic Acral Vascular Syndrome," *The Medicine Forum*: Vol. 14, Article 14.

Available at: <http://jdc.jefferson.edu/tmf/vol14/iss1/14>

This Article is brought to you for free and open access by the Jefferson Digital Commons. The Jefferson Digital Commons is a service of Thomas Jefferson University's [Center for Teaching and Learning \(CTL\)](#). The Commons is a showcase for Jefferson books and journals, peer-reviewed scholarly publications, unique historical collections from the University archives, and teaching tools. The Jefferson Digital Commons allows researchers and interested readers anywhere in the world to learn about and keep up to date with Jefferson scholarship. This article has been accepted for inclusion in *The Medicine Forum* by an authorized administrator of the Jefferson Digital Commons. For more information, please contact: [JeffersonDigitalCommons@jefferson.edu](mailto:JeffersonDigitalCommons@jefferson.edu).

---

# Paraneoplastic Acral Vascular Syndrome

## **Authors**

Daniel M. Kopolovich, MSIII; Dean D. Lagonosky, MSIII; Allison A. Greco, MSIV; Emma Weaver, MD; Rahul Malhotra, MD; Phoebe Holmes, MD; and John R. Stewart, MD

## PARANEOPLASTIC ACRAL VASCULAR SYNDROME

Daniel M. Kopolovich, MSIII, Dean D. Laganosky, MSIII, Allison A. Greco, MSIV,  
Emma Weaver, MD, Rahul Malhotra, MD, Phoebe Holmes, MD, John Stewart, MD

### Introduction

Cases of rheumatologic phenomena coinciding with malignancy have been well-documented in the medical literature. These syndromes may be associated with common autoimmune markers, potentially masking the underlying diagnosis of malignancy. The association between malignancy and its coinciding rheumatologic manifestations is poorly understood. These paraneoplastic symptoms are more prevalent in high-stage adenocarcinomas of the lung, breast, and ovary. Possible mechanisms may include cytokine derangements, blood hyperviscosity, and circulatory disruption. While some evidence suggests that control of the primary tumor alleviates its associated paraneoplastic symptoms, other proposed therapies include heparin, prednisone, aspirin, and vasodilatory agents. Efficacy is limited due to association of these syndromes with high-grade malignancy. We describe the case of a patient presenting with paraneoplastic acral vascular syndrome (PAVS) in association with primary ovarian carcinoma.<sup>1,2</sup>

### Case

The patient is a 57-year-old female with a history of Hashimoto's thyroiditis and migraines, who presents with an ulcerating rash of the fingertips and a tender discoloration of the plantar aspect of both feet. The rash began four weeks prior to presentation as a purple discoloration of the fingertips, progressing to a desquamating, palmar rash with distal phalangeal ulceration and necrosis of the fingertips. Almost simultaneously, the patient experienced purple discoloration of the soles of her feet bilaterally and described a sensation of "standing on marbles." She denies similar episodes in the past as well as sick contacts. She reports experiencing excessive stress in preparing for her daughter's wedding, exposure to a new type of dryer sheet, and a recent manicure/pedicure. The patient was recently treated with two medrol dose packs, minocycline, nitroglycerin paste (which had to be discontinued due to hypotension), and aspirin. Following treatment, the patient had no relief of symptoms.

Review of systems was remarkable for bilateral knee pain, painful mouth ulcers, a non-tender, erythematous scaling rash on the elbows, back, and right thigh. She denied fever, weight loss, fatigue, night sweats, change in appetite, or abdominal swelling. She reported allergies to DEET (rash and trouble breathing) and Demerol. Recent skin testing suggested sensitivity to wheat, corn, and soy. Family history was significant for a mother with giant cell arteritis, father who passed away from melanoma and a sister with breast cancer. The patient also had two daughters, one with Raynaud's syndrome and celiac disease, and another with Sjogren's syndrome. The patient was a middle school math

teacher and had no occupational exposures. Social history was unremarkable.

### Physical Exam

Physical exam revealed unremarkable vital signs. The patient's right hand was notable for purple discoloration of the distal 2nd through 5th digits and necrotic ulcerations of the distal 2nd and 3rd digits (Figure 1). The left hand had purple discoloration of the distal 1st through 5th digits. Both hands had slight peeling of the palmar surface, not extending past the wrist. There was mild swelling of the metacarpal-phalangeal joints as well as proximal inter-phalangeal joints bilaterally. Purple discoloration of the anterior plantar surfaces of bilateral feet was also noted. Neurologic exam was intact. Patient had 2+ radial, posterior tibial and dorsalis pedis pulses bilaterally, and no leg edema. Faint crackles were auscultated posteriorly in bilateral lower lobes of the lungs. No cervical, supraclavicular, axillary or inguinal lymphadenopathy was palpated.

Lab values revealed the following: C-Reactive Proteins 10.9 (H), Rheumatoid Factor: 16.9 (H), ANA (homogenous 1:160, speckled 1:160), Anti-Ro 8.0 (H), Anti-cardiolipin IgM 76 (H), Aldolase 11.7 (H). CA-125 118 (H) CA 15.3 (CA 27.29) 46 (H). Blood

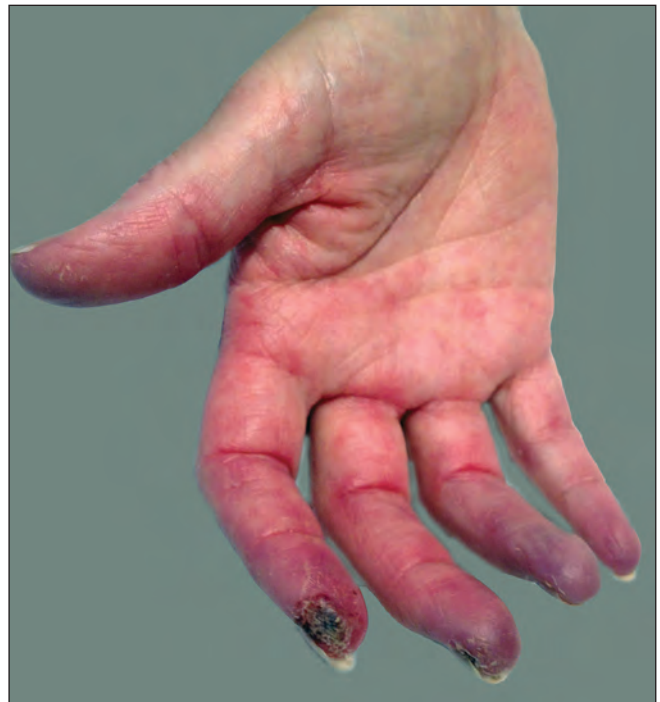

Figure 1. Right Hand Rash

count, coagulation profile, chemistry profile, liver function tests, lipid profile and urinalysis were unremarkable. Additionally, ESR, Anti-double stranded DNA, Anti Scl-70, c-ANCA, p-ANCA, atypical p-ANCA, anti-MPO, Antiproteinase-3, Jo-1 antibody, Lyme panel, viral hepatitis panel, EBV/CMV PCR, cold agglutinins, SPEP/UPEP, beta-2 glycoprotein, Celiac panel, Lupus anticoagulant, RNP, CPK, heavy metals, CEA, and CA 19.9 were also normal. Chest radiograph showed a pulmonary interstitial prominence with predilection for the lung bases.

CT chest/abdomen/pelvis showed patchy ground glass opacities bilateral lower lobes, likely airspace filling process, of uncertain significance. No interstitial lung disease. Diffuse retroperitoneal adenopathy, extending from the diaphragm down through the common iliac and external iliac territories and a cystic area in the left adnexa. Another lymph node in the right supraclavicular region was also seen and a fine needle biopsy of this node was performed. Cytology was consistent with an adenocarcinoma of ovarian origin. (Figures 2 & 3)

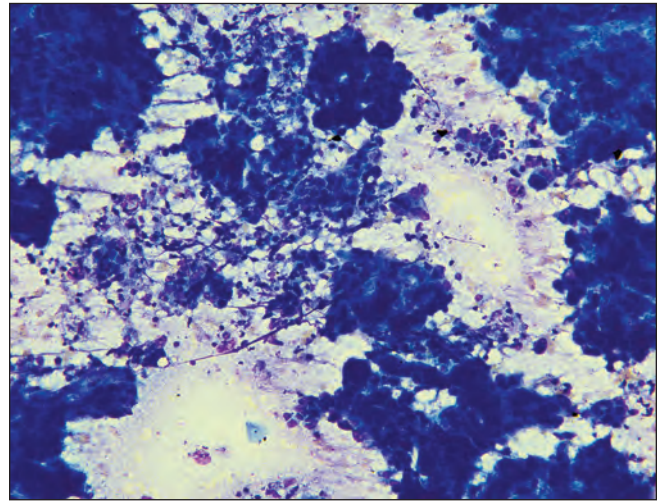
MRI of the abdomen and pelvis revealed a 5.0 cm solid and cystic left adnexal mass, lesions of the left ileum consistent with bony metastases, and extensive peritoneal carcinomatosis.

## Discussion

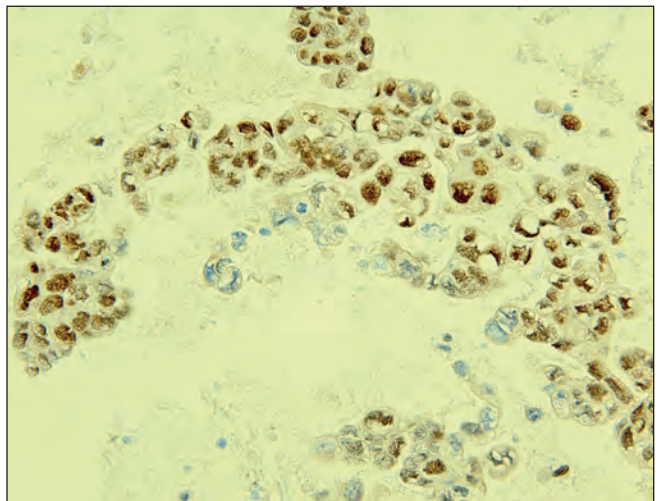
This patient was diagnosed with paraneoplastic acral vascular syndrome (PAVS) in association with primary ovarian carcinoma. PAVS is an infrequently described phenomenon characterized by acrocyanosis and subsequent necrosis of the distal extremities secondary to malignancy. Most common associations are adenocarcinoma of gastrointestinal and pulmonary origin; however, ovarian cancer has been implicated in a number of cases.<sup>1,3-5</sup> Of these, the majority are found to be metastatic at the time of diagnosis.<sup>5,6</sup> In one literature review it was shown that PAVS affects the hands in 94% of patients and the feet in only 30%.<sup>1</sup> The mean age of onset is 54.4 years old and vasculitis precedes the diagnosis of malignancy by an interval of 1-38 months with a mean of 10 months.<sup>3,7</sup>

A number of authors have previously described atypical features that may raise suspicion for an underlying neoplastic versus primary rheumatologic pathology. Age greater than 50 years at presentation, atypical involvement of the digits, as well as poor response to steroids and vasodilating agents may indicate an underlying malignancy. In contrast to primary rheumatologic disorders, which occur more frequently in young women, these conditions occur with equal frequency in men and women.<sup>1,2</sup>

Several proposed mechanisms for PAVS include: (i) ischemia from tumor antigen immune complex deposition in the small vessels of the digits, (ii) tumor infiltration into the cervical plexus resulting in the release of vasoconstrictor substances, (iii) direct endothelium invasion by the tumor cells, and (iv) hypersensitivity reaction.<sup>4,7</sup> However, these mechanisms are not



**Figure 2.** Diff quick stain of fine needle aspiration of lymph node showing large malignant cells consistent with adenocarcinoma.



**Figure 3.** Wilms immunohistochemical stain of the cell block—the stain is positive, confirming an ovarian origin, ruling out lung.

consistent between patients. In one study, the pathology of the digits showed leukocytoclastic small vessels, which was histologically different from the vascular involvement normally seen in other diseases such as Rheumatoid arthritis, SLE, and Takayasu vasculitis.<sup>7</sup> Fibrinoid necrosis and intimal proliferation were also noted.<sup>8</sup> Other findings included disruption of the endothelium and invasion of the vessels by neutrophils.<sup>7</sup>

Treatment options for addressing the symptoms of PAVS include steroids, IV prostacyclin, lower molecular weight Heparin, aspirin, topical nitroglycerin, and calcium channel blockers. More definitively, PAVS was found to resolve with cancer treatment.<sup>1</sup> In another study of 22 patients, clinical remission of malignancy corresponded with the disappearance of PAVS.<sup>6</sup> In



summary, small vessel disease refractory to traditional therapies warrants increased clinical suspicion for metastatic malignancy so as not to delay definitive treatment.

## References

1. Poszepczynska-Guigné, Ewa, Manuelle Viguier, Olivier Chosidow, Brigitte Orcel, Joseph Emmerich, Louis Dubertret, Paraneoplastic acral vascular syndrome: Epidemiologic features, clinical manifestations, and disease sequelae, *Journal of the American Academy of Dermatology*, Volume 47, Issue 1, July 2002, Pages 47-52.
2. Racanelli V, Prete M, Minoia C, Favoino E, Perosa F. Rheumatic disorders as paraneoplastic syndromes. *Autoimmun Rev.* 2008 May;7(5):352-8. Epub 2008 Feb 22. Review. PubMed PMID: 18486921.
3. Smith RA, Propper DJ, Harvey AR. Ovarian Carcinoma and Raynaud's phenomenon. *BJ Dermatol* 1995; 132: 152-3.
4. Maurice PDL. Ovarian carcinoma and digital ischemia. *Clin Exp Dermatol* 1996; 21: 381-2.
5. Legrain S, Raguin G, Piette JC. Digital Necrosis revealing ovarian cancer. *Dermatology* 1999; 199: 183-4.
6. Chow SF, McKenna CH. Ovarian cancer and gangrene of the digits: case report and review of the literature. *Mayo Clin Proc* 1996; 71: 253-8.
7. Greer JM, Longley S, Edwards L, Elfenbein GJ, Panush RS. Vasculitis associated with malignancy: Experience with 13 patients and literature review. *Medicine (Baltimore)* 1988; 67:220-30.
8. Friedman SA. Malignancy and arteriopathy. A report of two cases. *Angiology* 20:136 (1969).

"Vernal Falls 3"

photograph by Soham Vakil

