

1-24-2013

# Endoscopic Ultrasonic Dacryocystorhinostomy for Recurrent Dacryocystitis Following Rhinoplasty

Nadia Mostovych, MD

*Thomas Jefferson University, Nadia.Mostovych@jefferson.edu*

Mindy R. Rabinowitz, MD

*Thomas Jefferson University, Mindy.Rabinowitz@jefferson.edu*

Edmund A. Pribitkin, MD

*Thomas Jefferson University, edmund.pribitkin@jefferson.edu*

Jurij R. Bilyk, MD

*Wills Eye Institute, jbilyk@aol.com*

## [Let us know how access to this document benefits you](#)

Follow this and additional works at: <http://jdc.jefferson.edu/otograndrounds>

 Part of the [Otolaryngology Commons](#)

### Recommended Citation

Mostovych, MD, Nadia; Rabinowitz, MD, Mindy R.; Pribitkin, MD, Edmund A.; and Bilyk, MD, Jurij R., "Endoscopic Ultrasonic Dacryocystorhinostomy for Recurrent Dacryocystitis Following Rhinoplasty" (2013). *Department of Otolaryngology - Head and Neck Surgery Faculty, Presentations and Grand Rounds*. Presentation 8.

<http://jdc.jefferson.edu/otograndrounds/8>



Nadia Mostovych, MD<sup>1</sup>, Mindy R. Rabinowitz, MD<sup>1</sup>, Edmund A. Pribitkin, MD<sup>1</sup>, Jurij R. Bilyk, MD<sup>2</sup>

<sup>1</sup>Thomas Jefferson University Hospital, Department of Otolaryngology-Head and Neck Surgery,

<sup>2</sup>Wills Eye Institute, Oculoplastic and Orbital Surgery Service, Philadelphia, PA

## ABSTRACT

The lacrimal sac is the structure most vulnerable to injury when performing osteotomies for rhinoplasty. When performed in a low lateral position or along the frontal process of the frontal-maxillary suture, osteotomies have the potential to tear the medial canthal ligament and injure the underlying lacrimal sac resulting in dacryocystitis. We report a case of dacryocystitis in a 19 year old male who presented with recurrent episodes of pain, tearing, and discharge from his left eye following primary rhinoplasty. He was found to have obstruction of the lacrimal system secondary to a low lateral osteotomy with an impinging bone fragment on imaging. Endoscopic dacryocystorhinostomy was performed using a Sonopet<sup>®</sup> ultrasonic bone aspirator under image guidance to remove the bone fragments posing risk to further injury to the lacrimal sac and orbit. Patency of the nasolacrimal duct was achieved and the patient remained symptom free at 6 month follow up. We describe the first case of recurrent dacryocystitis following rhinoplasty requiring treatment by an endoscopic dacryocystorhinostomy (DCR). Endoscopic DCR with the use of the ultrasonic bone aspirator provides several advantages over open DCR, including the lack of an external incision and decreased risk of injury to the adjacent orbital soft tissue anatomy including the lacrimal system.

## INTRODUCTION

Epiphora following rhinoplasty is usually secondary to soft tissue edema causing compression of the lacrimal system and resolves within 1-2 weeks. However, epiphora that persists, especially longer than 2-3 months, and/or is complicated by dacryocystitis raises concern for damage to the lacrimal drainage system (LDS).

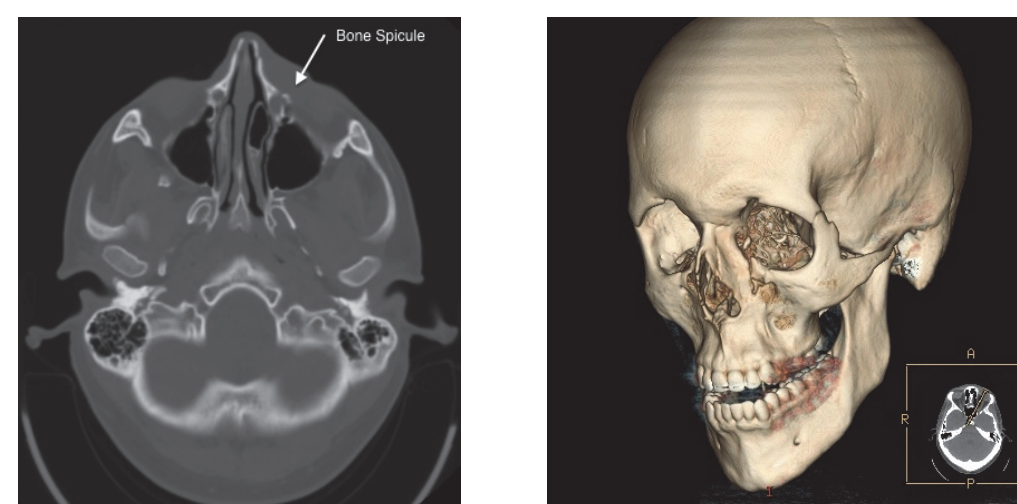
The LDS contains lacrimal canaliculi, the lacrimal sac, and the nasolacrimal duct—connecting the LDS to the nasal cavity. The lacrimal sac lies in the lacrimal fossa of the lacrimal bone and is protected posteriorly by the posterior lacrimal crest and anteriorly by the anterior lacrimal crest, which is formed by the junction of the lacrimal bone and the frontal process of the maxilla.<sup>1</sup> The medial canthal tendon provides further protection for the sac by passing anteriorly over the lacrimal sac and attaching to the frontal process of the maxilla.<sup>1</sup>

The anterior wall of the lacrimal sac is closely associated to the posterior aspect of the medial canthal tendon by an aponeurotic lamina that attaches to the posterior lacrimal crest.<sup>2</sup> However, the lacrimal sac remains vulnerable to injury as it lacks bony covering for 10-11 mm and is not fully protected by the medial canthal tendon.<sup>3</sup> It is most vulnerable to injury from lateral osteotomy. An osteotomy along the frontal process of the frontal maxillary suture may disrupt the medial canthal tendon<sup>3</sup> and in turn injure the underlying lacrimal sac. A subperiosteal tunnel deep to the protective medial canthal tendon may also predispose the lacrimal sac to shearing injury.<sup>2</sup> We describe the first case of recurrent dacryocystitis following rhinoplasty to be treated successfully by an endoscopic dacryocystorhinostomy.

## CASE PRESENTATION

A 19 year-old male presented with recurrent episodes of pain, tearing and discharge from the left eye that began five weeks after primary rhinoplasty. Ophthalmologic evaluation revealed a mild stricture of the left inferior canaliculus and partial left nasolacrimal duct obstruction (20% patency). Physical examination revealed a deep osteotomy with considerable nasal bone infraction. Computed tomography (CT) demonstrated evidence of dacryocystitis and a relatively lateral osteotomy which disrupted the LDS causing obstruction (Figure 1). Conservative treatment with oral and topical anti-staphylococcal antibiotics resulted in only transient resolution of his dacryocystitis.

**Figure 1**

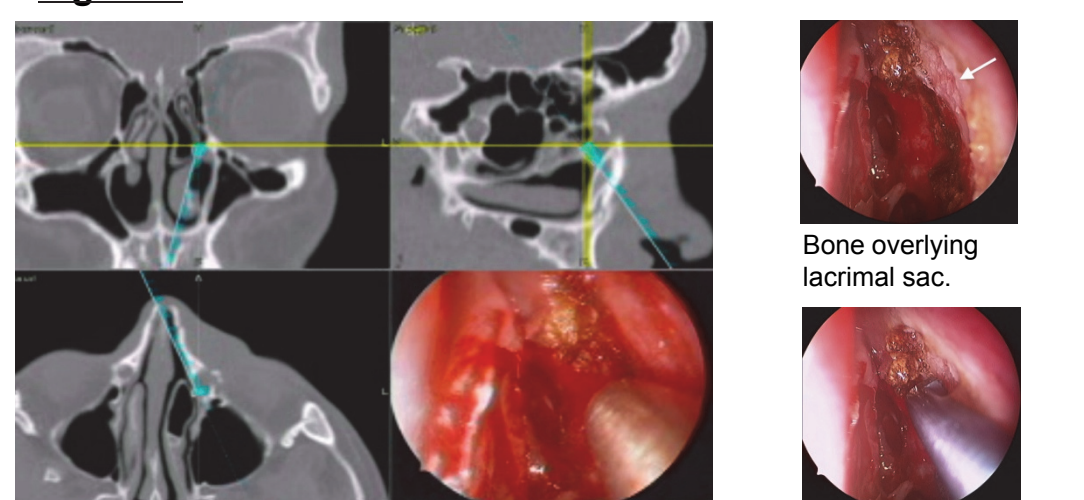


Left: Computed tomography (CT) and Right: Three dimensional CT reconstruction images showing multiple fractures involving the left inferomedial orbital rim with extension into the anterior medial wall of the maxillary sinus. Fractures and a displaced bony fragment can be seen involving the region of the left lacrimal sac with extension down along the lacrimal duct.

## METHODS

The patient underwent a successful endoscopic dacryocystorhinostomy. In order to avoid comminution of the fractured lacrimal fossa and canal and potential injury to the orbit, the Sonopet<sup>®</sup> ultrasonic bone aspirator (Stryker, Inc., Kalamazoo, MI) was employed to remove the bone overlying the lacrimal sac under image guidance (Figure 2). The lacrimal sac was opened widely to evacuate mucopurulent discharge. Additionally, a bone spicule lying within the lacrimal sac was removed endoscopically (Figure 3) without complication. A Crawford tube was placed in the nasolacrimal duct to retain patency. Post-operatively, cultures grew *Staphylococcus aureus* and he was treated with a six week course of clarithromycin after which the Crawford tube was removed.

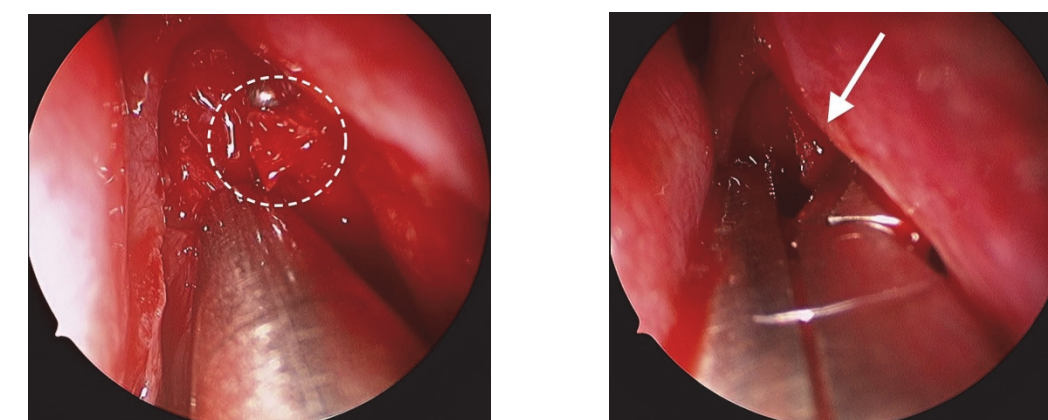
**Figure 2**



Left: Intraoperative navigation image guidance showing bone spicule in the left lacrimal sac – well visualized in axial plane.

Sonopet<sup>®</sup> removing bone overlying lacrimal sac.

**Figure 3**



Bone spicule exposed after opening the lacrimal sac.

Removal of bone spicule from the lacrimal sac.

## RESULTS

At six months follow-up the patient had no evidence of epiphora, infection, pain or discomfort from the left eye.

## CONCLUSION

Care must be taken to avoid LDS injury during the performance of lateral osteotomies. Low curved osteotomies using sharp osteotomes, following the nasomaxillary groove, remaining inferior to the frontal suture line, and without prior subperiosteal tunnels may reduce the risk of LDS injury. Epiphora and dacryocystitis may be successfully managed through endoscopic DCR without potentially disfiguring external DCR incisions. Finally, use of the ultrasonic bone aspirator should be considered in cases where bone fragmentation is suspected to help minimize risk to adjacent orbital soft tissue anatomy and to prevent injury to the lacrimal system.

## REFERENCES

1. Sachs, ME. Lacrimal system injury secondary to cosmetic rhinoplasty. *Advanced Ophthalmic Plastic & Reconstructive Surgery* 1984; 3:301-305.
2. Thomas, JR and Griner, N. The relationship of lateral osteotomies in rhinoplasty to the lacrimal drainage system. *Otol-Head and Neck Surg* 1986; 94:362-367.
3. Cies, WA and Baylis, HI. Epiphora following rhinoplasty and Caldwell-Luc Procedures. *Ophthalmic Surgery* 1976; 7:77-81.
4. Lawson W, Kessler S, and Biller HF. Unusual and Fatal complications of Rhinoplasty. *Arch Otolaryngol* 1983; 109:164-169.
5. Flowers RS and Anderson R. Injury to the lacrimal apparatus during rhinoplasty. *Plast Reconstr Surg* 1968; 42:577-581.
6. Flanagan JC. Epiphora following rhinoplasty. *Ann Ophthalmology* 1978; 10:1239-1242.
7. Osguthorpe JD and Calcaterra TC. Nasolacrimal Obstruction after Maxillary Sinus and Rhinoplastic Surgery. *Arch Otolaryngol* 1979; 105: 264 – 266.
8. Yigit O, Ugur c, Berna UC et al. The evaluation of the effects of lateral osteotomies on the lacrimal drainage system after rhinoplasty using active transport dacryocystography. *Rhinology* 2004; 42, 19-22.
9. Meyers Ad and Hawes MJ. Nasolacrimal obstruction after inferior meatus nasal antrostomy. *Arch Otolaryngol Head Neck Surg* 1991; 117: 208-211.
10. Goldan O, Georgiou I, Haik J et al. Lacrimal fistula 10 years after closed cosmetic rhinoplasty: case report. *Aesth Plastic Surg* 2008; 32: 153 – 154.
11. Pilanci O, Ucar C, Kuvat SV, et al. An uncommon complication of septorhinoplasty, acute dacryocystitis. *Aesth Plast Surg* 2010; 34: 392 – 393.
12. Antisdell JL, Kadze MS, and Sindwani R. Application of ultrasonic aspirators to endoscopic dacryocystorhinostomy. *Otolaryngol Head Neck Surg* 2008; 139: 586-588.