



January 2007

Hemicrania continua-like headache associated with carotid dissection may respond to indomethacin

Avi Ashkenazi

Thomas Jefferson University, avi.ashkenazi@jefferson.edu

Muhammad A. Abbas

Thomas Jefferson University

Dinesh K. Sharma

Thomas Jefferson University

Stephen D. Silberstein

Thomas Jefferson University

[Let us know how access to this document benefits you](#)

Follow this and additional works at: <http://jdc.jefferson.edu/neurologyfp>

 Part of the [Neurology Commons](#)

Recommended Citation

Ashkenazi, Avi; Abbas, Muhammad A.; Sharma, Dinesh K.; and Silberstein, Stephen D., "Hemicrania continua-like headache associated with carotid dissection may respond to indomethacin" (2007).

Department of Neurology Faculty Papers. Paper 13.

<http://jdc.jefferson.edu/neurologyfp/13>

This Article is brought to you for free and open access by the Jefferson Digital Commons. The Jefferson Digital Commons is a service of Thomas Jefferson University's [Center for Teaching and Learning \(CTL\)](#). The Commons is a showcase for Jefferson books and journals, peer-reviewed scholarly publications, unique historical collections from the University archives, and teaching tools. The Jefferson Digital Commons allows researchers and interested readers anywhere in the world to learn about and keep up to date with Jefferson scholarship. This article has been accepted for inclusion in Department of Neurology Faculty Papers by an authorized administrator of the Jefferson Digital Commons. For more information, please contact: JeffersonDigitalCommons@jefferson.edu.

**Hemicrania Continua - Like Headache Associated with Internal Carotid Artery
Dissection may Respond to Indomethacin**

Avi Ashkenazi, M.D.¹, Muhammad A. Abbas, M.D.¹, Dinesh K. Sharma, M.D.², Stephen
D. Silberstein, M.D., F.A.C.P.¹

Departments of Neurology¹ and Radiology², Thomas Jefferson University Hospital
Philadelphia, PA

Abstract

Hemicrania continua (HC) is an idiopathic, chronic disorder characterized by a continuous, strictly unilateral headache associated with ipsilateral cranial autonomic symptoms. The symptoms of HC typically respond dramatically to indomethacin therapy. We describe a patient with traumatic internal carotid artery (ICA) dissection, who presented with a clinical picture mimicking HC that initially responded to indomethacin. Patients with a clinical picture similar to HC should be managed with a high index of suspicion for a possible cervical arterial dissection.

Hemicrania continua (HC) is a chronic, indomethacin-responsive headache disorder characterized by a continuous, strictly unilateral head pain that fluctuates in intensity and is associated with ipsilateral cranial autonomic symptoms^{1,2}. HC was first described by Medina and Diamond in 1981 as a “cluster headache variant” responding to indomethacin³. Sjaastad and Spierings described two more cases and coined the term HC⁴. Initially considered a rare disorder, HC has been increasingly recognized over the past two decades⁵. The International Headache Society (IHS) has recently published specific diagnostic criteria for HC⁶. The rapid and dramatic response to indomethacin is a hallmark of HC, and indeed is one of the IHS diagnostic criteria for this disorder^{2,6}. However, the mechanism of the beneficial effect of indomethacin on HC, which far exceeds the effect of other NSAIDs on this disorder, remains unknown. Moreover, the specificity of indomethacin responsiveness for this disorder has been debated⁷. The etiology and pathogenesis of HC are currently unknown.

We describe a patient with traumatic internal carotid artery (ICA) dissection, who presented with a clinical picture that mimicked HC, with a transient response to indomethacin.

Case report

The patient is a 51-year-old, right-handed woman who presented to our clinic in December 2004 with a chief complaint of severe, continuous, right-sided headache. In May 2003, while riding a bus that was involved in a motor vehicle accident, the patient had right-sided neck and shoulder trauma. She remained fully conscious and had no symptoms immediately after the trauma. The headache appeared three weeks later. One month after the onset of headache she noticed drooping of her right eyelid. She was admitted to a local hospital, where a magnetic resonance angiography (MRA) of the neck revealed a dissection of the right ICA (figure A). A brain MRI was normal. She was started on anticoagulant therapy, which was stopped after a year. Her headache was

continuous from the onset until she was seen at our clinic. At presentation, she complained of a continuous, strictly right-sided headache that was moderate to severe in intensity, with superimposed paroxysms of short-lasting (duration of up to 30 seconds), shooting pain in the same area. She reported on occasional right-sided tearing and rhinorrhea, as well as nausea. She was severely disabled by her headache, unable to work or attend family or social activities. Her sleep was disrupted by the pain and she was taking morphine tablets daily.

Her past medical history included arterial hypertension and depression. Prior to her neck trauma, she only had occasional episodes of tension type headache. On examination, she was in obvious distress from pain. Her mood was depressed. Miosis and eyelid ptosis were present on the right. A repeat MRA of the neck showed no healing of the right ICA dissection (figure B).

The patient was started on oral indomethacin 75 mg/day, and was instructed to stop all other pain medications. Twenty-four hours after the initiation of indomethacin treatment, she experienced significant headache relief. The indomethacin dose was increased gradually to 225 mg/day and pantoprazole 40 mg/day was added for gastrointestinal protection. At that point, she became headache-free and had no adverse effects from her medications.

Six months later, her headache recurred and gradually increased in severity, despite continued indomethacin use. Verapamil, at a dose of 240 mg/day, was added to her treatment regimen, with a very good response. At the most recent follow-up in January 2006, the patient was doing well, with only mild headaches.

Discussion

This patient presented with the clinical picture that resembled HC, i.e. a strictly unilateral, continuous headache of moderate to severe intensity for >3 months, associated with ipsilateral cranial autonomic symptoms⁶. Her headache also responded initially to indomethacin. However, that response was transient.

Few patients, who presented with a clinical phenotype resembling HC associated with a specific disease, have been described in the literature⁸. The etiologies of these

"secondary HC" cases include head trauma, a sphenoid bone tumor, lung cancer, and sphenoid sinusitis⁹⁻¹². Lay and Newman described four patients (three of whom were women) who presented with a clinical picture of HC that started in temporal relation to head trauma⁹. All four patients had headache resolution or significant headache improvement with indomethacin treatment, while other analgesics, including NSAIDs other than indomethacin, were ineffective. Antonaci and Sjaastad reported on a 28-year-old woman with HC secondary to a mesenchymal tumor in the sphenoid bone¹⁰. Her headache abated with indomethacin treatment, but the effect of indomethacin faded after two months of treatment. Successful treatment of the tumor resulted in elimination of the headache. In another case report, a 61-year-old man presented with continuous hemicranial pain associated with lung cancer¹¹. There were no associated cranial autonomic symptoms. The patient's headache was entirely responsive to indomethacin. Another report was of a 53-year-old woman presented with continuous unilateral headache associated with autonomic symptoms¹². Indomethacin provided significant headache relief. On evaluation, sphenoid and posterior ethmoid sinusitis was found ipsilateral to her head pain. Treatment of the sinusitis with antibiotic enabled the indomethacin therapy to be discontinued.

ICA dissection has been well recognized in association with unilateral headache and incomplete Horner syndrome^{13,14 15}. However, in all but one of these cases, the headaches were not evaluated using the new IHS criteria for HC, and indomethacin was not given as a treatment trial. Silbert et al studied 135 patients with symptomatic ICA dissection, 47% of whom presented with headache¹⁵. The head pain was typically ipsilateral to the dissection. In a recent case report, a man presented with IHS-defined HC that responded to indomethacin at a dose of 150 mg/day¹⁴. He was found to have a dissection of the ICA ipsilateral to the pain, with secondary occlusion of the vessel. Eight weeks after the initiation of anticoagulant therapy, the indomethacin could be tapered off without recurrence of his headache. Repeat imaging showed resolution of the vascular occlusion.

Our case, along with the above recently reported one, shows that an ICA dissection may present with HC-like headache that may respond initially to indomethacin. It has been suggested that patients with HC who require a high dose of indomethacin, or who experience fading of the indomethacin effect, may have an underlying pathology¹⁶. Our case, where the response to indomethacin faded six months after initiation of treatment, supports this theory. The persistence of the carotid dissection in our patient probably played a role in the persistence of her headache. She had multiple neck MRAs after the neck trauma, and all showed no healing of the dissection. Carotid dissections usually heal within several months, and by that time the symptoms associated with the dissection abate, as described by Rogalewski et al¹⁴.

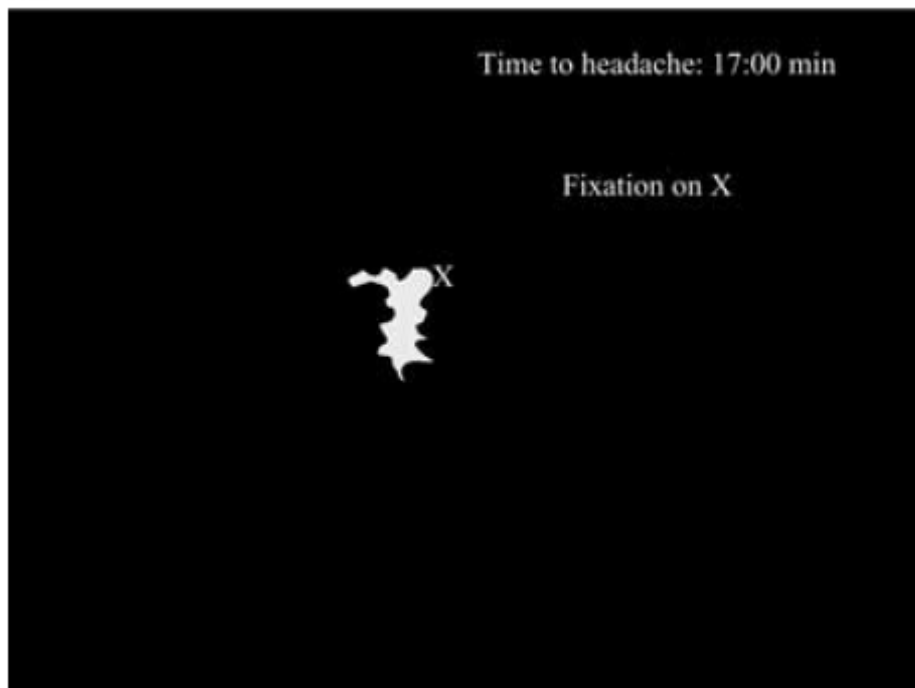The occurrence of headache in association with carotid dissection is consistent with the observation that stimulation of the carotid artery results in pain referred ipsilaterally to the head¹⁵. The cranial autonomic symptoms seen in ICA dissection may result from damage to the sympathetic fibers that travel along the carotid artery wall.



Patients who present with a clinical picture resembling HC should be managed with a high index of suspicion for a possible cervical arterial dissection, even when the headache responds initially to indomethacin.

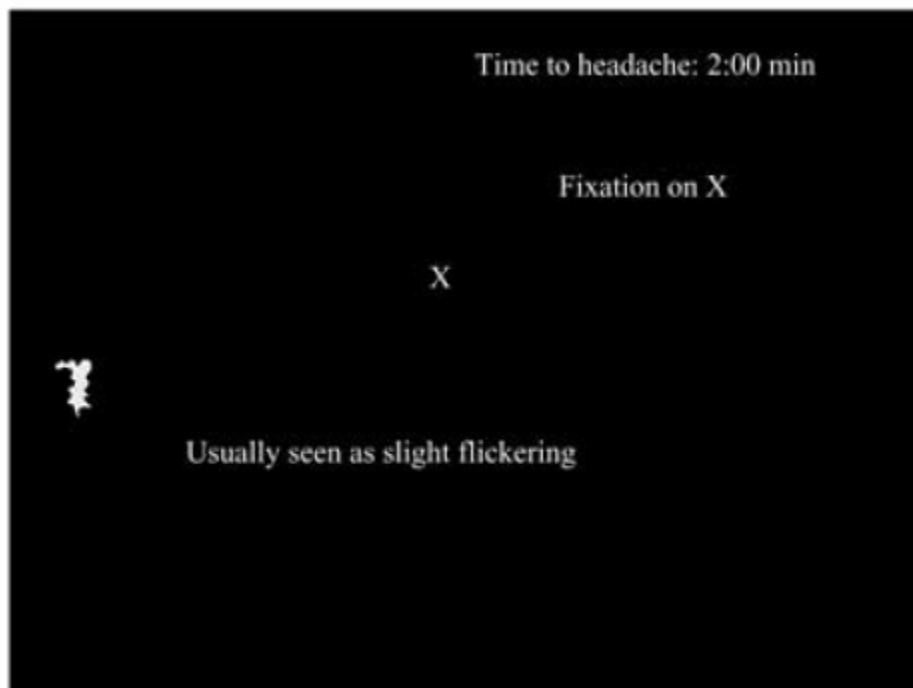Figure legend

Neck MRA showing a dissection of the right internal carotid artery (A); the dissection failed to heal 13 months later (B).

ICA – internal carotid artery; ECA- external carotid artery;
CCA – common carotid artery; VA- vertebral artery

A

B**C**

D

REFERENCES

1. Pareja JA, Antonaci F, Vincent M. The hemicrania continua diagnosis. *Cephalalgia* 2001;21:940-946.
2. Matharu MS, Boes CJ, Goadsby PJ. Management of trigeminal autonomic cephalgias and hemicrania continua. *Drugs* 2003;63:1637-1677.
3. Medina JL, Diamond S. Cluster headache variant, spectrum of a new headache syndrome. *Arch Neurol* 1981;38:705-709.
4. Sjaastad O, Spierings EL. Hemicrania continua: another headache absolutely responsive to indomethacin. *Cephalalgia* 1984;4:65-70.
5. Peres MF, Silberstein SD, Nahmias A, et al. Hemicrania continua is not that rare. *Neurology* 2001;57:948-951.
6. Headache Classification Committee. The International Classification of Headache Disorders, 2nd Edition. *Cephalalgia* 2004;24:1-160.
7. Dodick D. Hemicrania continua: diagnostic criteria and nosologic status. *Cephalalgia* 2001;21:869-872.
8. Trucco M, Mainardi F, Maggioni F, Badino R, Zanchin G. Chronic paroxysmal hemicrania, hemicrania continua and SUNCT syndrome in association with other pathologies: a review. *Cephalalgia* 2004;24:173-184.
9. Lay CL, Newman LC. Posttraumatic hemicrania continua. *Headache* 1999;39:275-279.
10. Antonaci F, Sjaastad O. Hemicrania continua: a possible symptomatic case, due to mesenchymal tumor. *Funct Neurology* 1992;7:471-474.
11. Eross EJ, Swanson JW, Dodick DW. Hemicrania continua: an indomethacin-responsive case with an underlying malignant etiology. *Headache* 2002;42:527-529.
12. Meckling SK, Becker WJ. Sphenoid sinusitis presenting as indomethacin-responsive "hemicrania continua": a case report. *Cephalalgia* 1997;17:303(Abstract)
13. Mokri B, Sundt T, Houser W. Spontaneous internal carotid dissection, hemicrania, and Horner's syndrome. *Arch Neurol* 1979;36:677-680.

14. Rogalewski A, Evers S. Symptomatic hemicrania continua after internal carotid artery dissection. *Headache* 2005;45:167-169.
15. Silbert PL, Mokri B, Schievink WI. Headache and neck pain in spontaneous internal carotid and vertebral artery dissections. *Neurology* 1995;45:1517-1522.
16. Sjaastad O, Stovner LJ, Stolt-Nielsen A, Antonaci F, Fredriksen TA. CPH and hemicrania continua: requirements of high dose indomethacin dosages- an ominous sign? *Headache* 1995;35:363-367.