

November 2012

Successful liver failure management using molecular adsorbents recirculating system during complicated veno-arterial extracorporeal membrane oxygenation as a bridge to a left ventricular assist device placement

Hitoshi Hirose

Thomas Jefferson University, Hitoshi.Hirose@Jefferson.edu

Shigeki Tabata

Thomas Jefferson University, Shigeki.Tabata@jeffersonhospital.org

Nicholas Cavarocchi

Thomas Jefferson University, nicholas.cavarocchi@jefferson.edu

[Let us know how access to this document benefits you](#)

Follow this and additional works at: <http://jdc.jefferson.edu/surgeryfp>



Part of the [Surgery Commons](#)

Recommended Citation

129. Tabata S, Cavarocchi N, Hirose H. Successful liver failure management using molecular adsorbents recirculating system during complicated veno-arterial extracorporeal membrane oxygenation as a bridge to a left ventricular assist device placement. Presented at Cardiovascular Thoracic Critical Care 2012, Washington DC, October 4-6, 2012.

This Article is brought to you for free and open access by the Jefferson Digital Commons. The Jefferson Digital Commons is a service of Thomas Jefferson University's [Center for Teaching and Learning \(CTL\)](#). The Commons is a showcase for Jefferson books and journals, peer-reviewed scholarly publications, unique historical collections from the University archives, and teaching tools. The Jefferson Digital Commons allows researchers and interested readers anywhere in the world to learn about and keep up to date with Jefferson scholarship. This article has been accepted for inclusion in Department of Surgery Faculty Papers by an authorized administrator of the Jefferson Digital Commons. For more information, please contact: JeffersonDigitalCommons@jefferson.edu.

Successful liver failure management using molecular adsorbents recirculating system during complicated veno-arterial extracorporeal membrane oxygenation as a bridge to a left ventricular assist device placement

Shigeki Tabata, MD, Nicholas Cavarocchi, MD, Hitoshi Hirose, MD.

From Thomas Jefferson University Hospital, Philadelphia, PA, USA.

Objective

ECMO is a well-established therapy for the patients with cardiogenic shock.

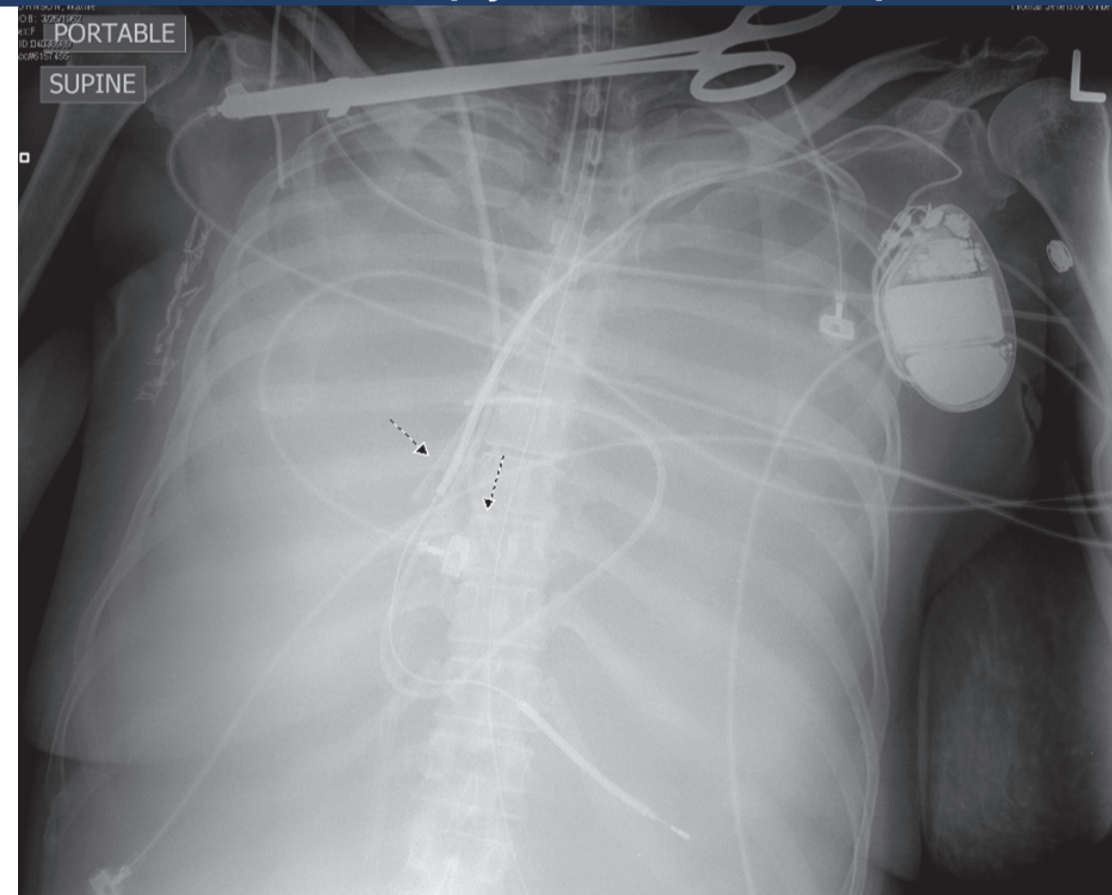
We present a patient who developed severe complications while on ECMO.

Case presentation-1

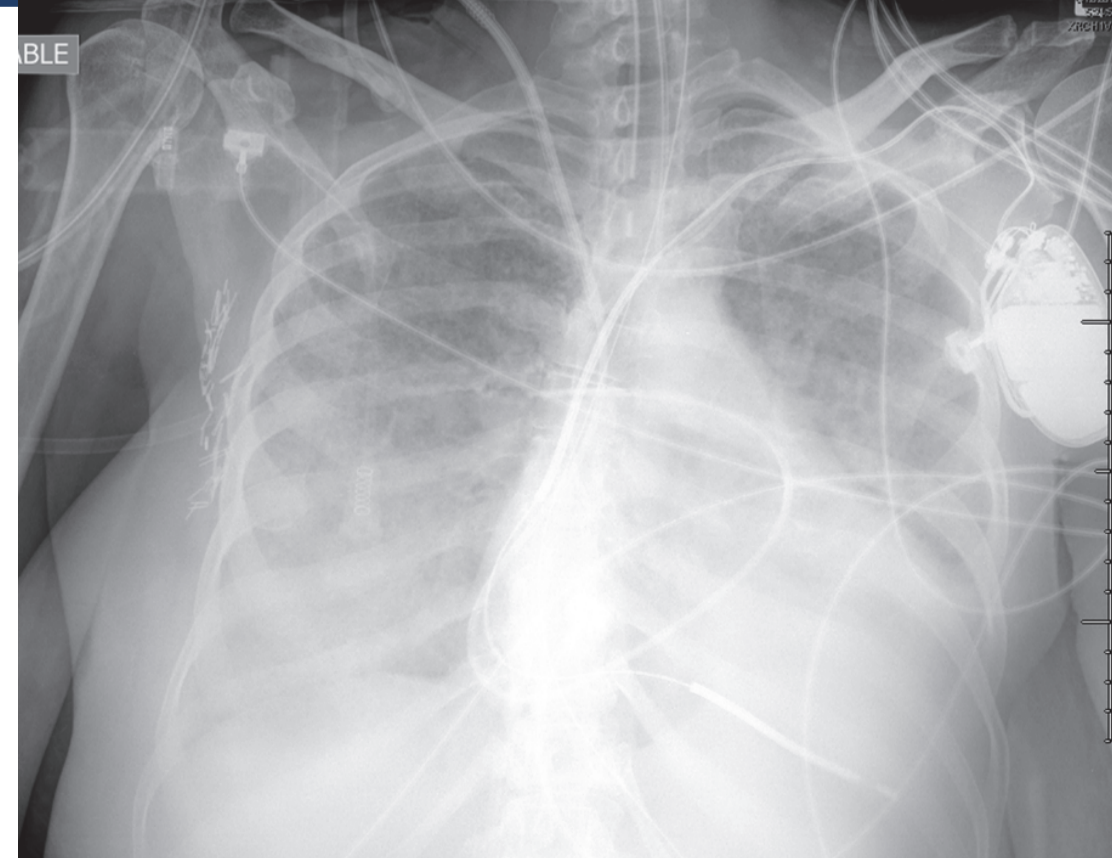A 49 year old female presented with severe heart failure and was placed on V-A ECMO for bridge to decision.

While on ECMO, the patient developed massive hemoptysis after Swan-Ganz catheter manipulation. After the endotracheal tube was clamped and the patient relied on full ECMO support for 36 hours, the hemoptysis resolved.

Massive hemoptysis & ET tube clamped



ET tube unclamped 36 h after hemoptysis



Case presentation-2

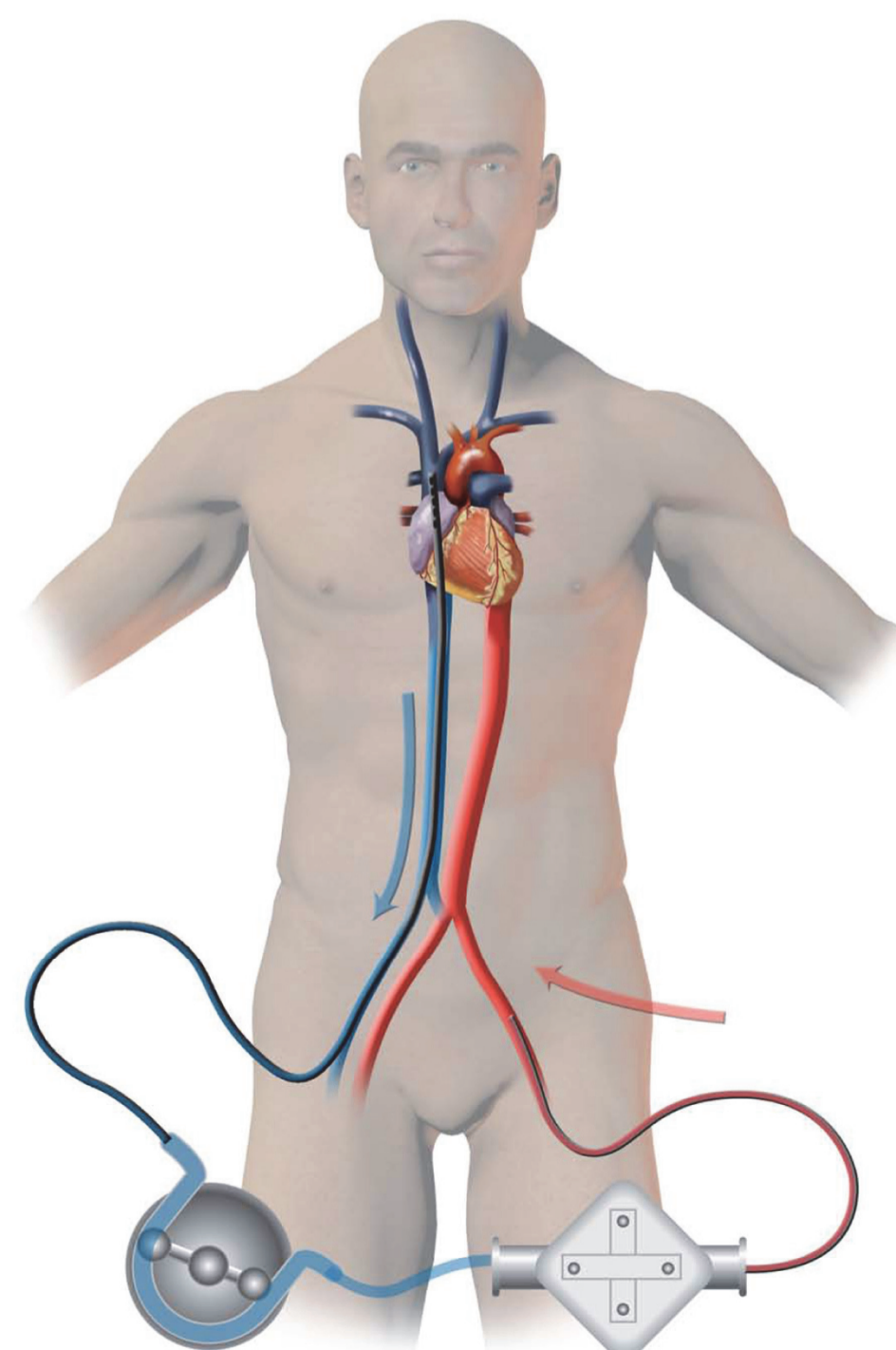
The patient also developed liver failure with peak total bilirubin of 56 mg/dl. The molecular adsorbents recirculating system (MARS) device was performed from ECMO day 9 to ECMO day 14. Liver function improved and the value of total bilirubin decreased to 9.9 mg/dl on ECMO day 19.

On ECMO day 20, the patient underwent a Heart Mate II LVAD placement and successful ECMO wean.

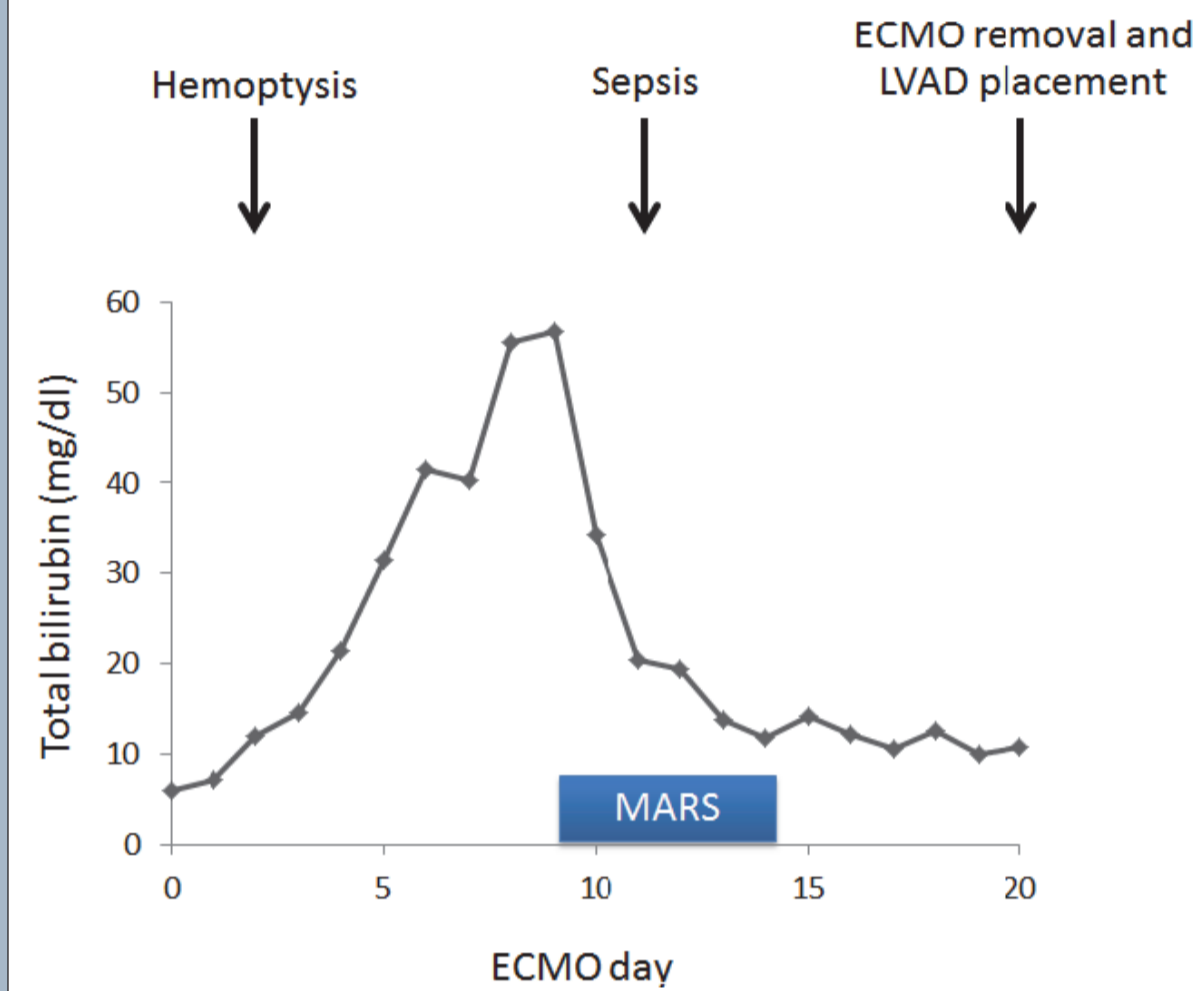
During the course of surgical recovery, the patient had two episodes of sepsis and VAD pocket infection, which was finally controlled with antibiotic beads placement into the pocket.

The patient was transferred to an acute rehabilitation facility on ECMO day 77.

ECMO



Total bilirubin improved after MARS



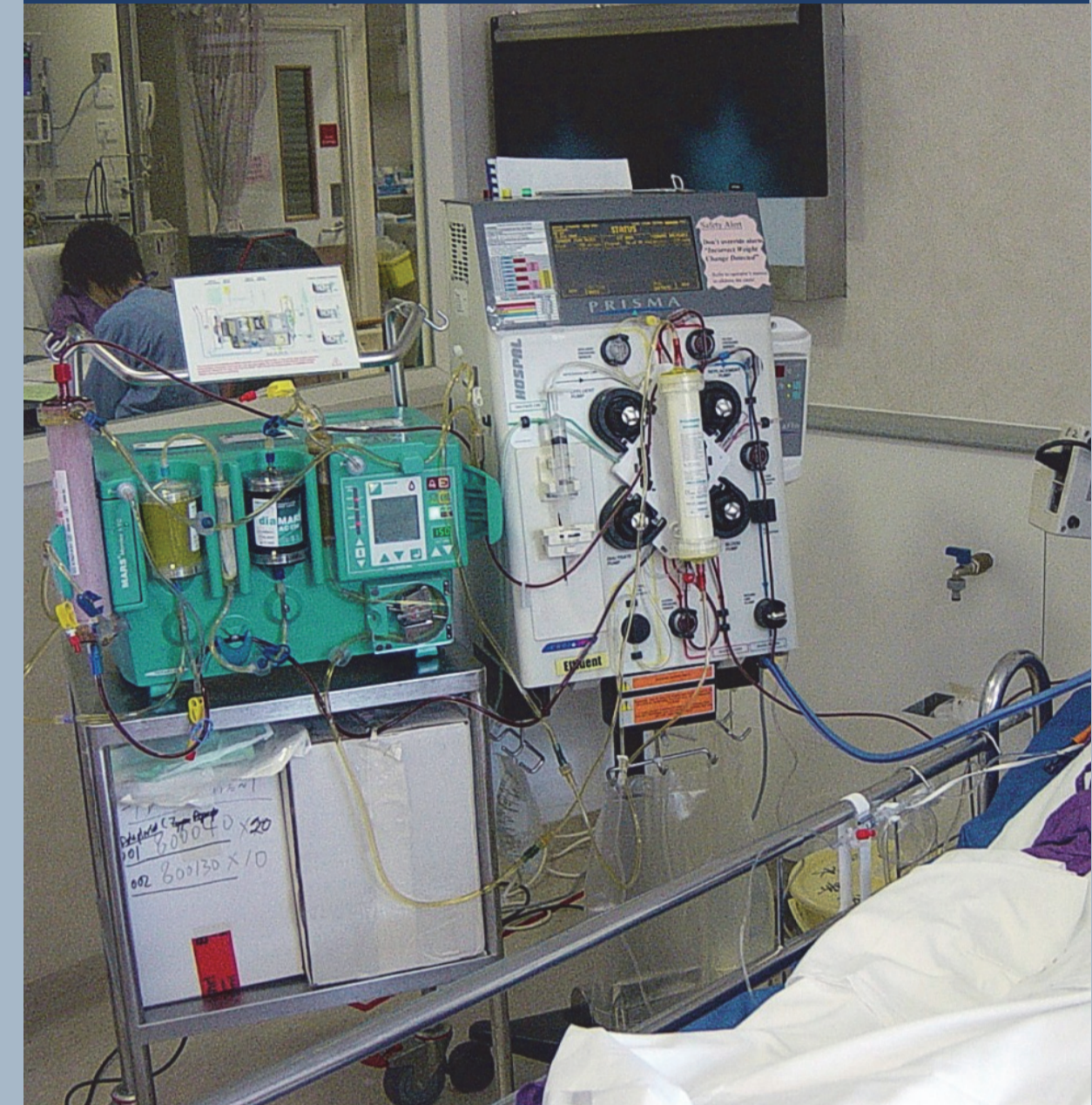
Discussion

Among the many possible hematologic complications, hemoptysis is often difficult to control. In our patient, the hemoptysis was not controllable by conventional treatment, thus the endotracheal tube was clamped to allow the entire airway to tamponade using the advantage of ECMO.

Liver function is most important risk factors to determine patient survival. The MARS is a cell-free extracorporeal liver support device which eliminates albumin-bound substances, such as bilirubin. Using MARS, the patient recovered liver function to allow to perform LVAD placement safely.

While these mechanical circulatory support, control of sepsis isolating the source of infection was essential for patient survival.

MARS



Conclusions

To our knowledge, this is the first report of a patient on ECMO complicated by massive hemoptysis and severe acute hepatic failure successfully managed and bridged to LVAD.

Patients can be successfully transitioned from ECMO to VAD despite major complications if these complications are successfully treated.

Contact information

Hitoshi Hirose, MD, Ph D.
genex@nifty.com

Associate Professor of Surgery
Division of Cardiothoracic Surgery
Thomas Jefferson University