



November 2012

An old problem with a new therapy: GI bleeding in VAD patients and deep bowel enteroscopy (Double balloon. Spiral enteroscopy).

Hitoshi Hirose

Thomas Jefferson University, Hitoshi.Hirose@jefferson.edu

Konrad Sarosiek

Thomas Jefferson University, Konrad.Sarosiek@jefferson.edu

Linda Bogar

Thomas Jefferson University, Linda.Bogar@jefferson.edu

Pitcher Harrison

Thomas Jefferson University

Barbara Ebert

Thomas Jefferson University

See next page for additional authors

[Let us know how access to this document benefits you](#)

Follow this and additional works at: <http://jdc.jefferson.edu/surgeryfp>

 Part of the [Surgery Commons](#)

Recommended Citation

Sarosiek K, Bogar L, Hirose H, Harrison P, Ebert B, Cavarocchi N. An old problem with a new therapy: GI bleeding in VAD patients and deep bowel enteroscopy (Double balloon. Spiral enteroscopy). Presented at the 32nd International Society of Heart and Lung Transplantation Annual Meeting and Scientific Section. Prague, Czech Republic. April 18-21, 2012.

This Article is brought to you for free and open access by the Jefferson Digital Commons. The Jefferson Digital Commons is a service of Thomas Jefferson University's [Center for Teaching and Learning \(CTL\)](#). The Commons is a showcase for Jefferson books and journals, peer-reviewed scholarly publications, unique historical collections from the University archives, and teaching tools. The Jefferson Digital Commons allows researchers and interested readers anywhere in the world to learn about and keep up to date with Jefferson scholarship. This article has been accepted for inclusion in Department of Surgery Faculty Papers by an authorized administrator of the Jefferson Digital Commons. For more information, please contact: JeffersonDigitalCommons@jefferson.edu.

Authors

Hitoshi Hirose, Konrad Sarosiek, Linda Bogar, Pitcher Harrison, Barbara Ebert, and Nicholas Cavarocchi

An Old Problem with a New Therapy: Gastrointestinal Bleeding in VAD Patients and Deep Bowel Enteroscopy

Konrad Sarosiek MD, Linda Bogar MD, Hitoshi Hirose MD, Pitcher Harrison MD,
Barbara Ebert CRNP, Nicholas Cavarocchi MD



CARDIOTHORACIC SURGERY, THOMAS JEFFERSON UNIVERSITY HOSPITAL, PHILADELPHIA, PA



Purpose

To propose a new approach to diagnosis and treatment of gastrointestinal bleeding (GIB) in patients with ventricular assist devices (VAD) utilizing the new technology of Deep Bowel Enteroscopy (DBE).

Background

There has long existed a connection between non-pulsatile flow devices and AVM formation leading to GIB yet the diagnostic and treatment algorithms have remained undefined. As technology changes, our approach must also change. Traditional approach utilizes:

- nasogastric lavage
- radioactive bleeding scans/angiography
- upper endoscopy
- colonoscopy
- capsule endoscopy

This multitude of tests can lead to delays in diagnosis and treatment resulting in increased transfusions and antibody production. With the advent of Deep Bowel Enteroscopy (Single balloon, Double balloon, and Spiral Enteroscopy), areas of the small intestine which were off limits are now easily accessible without surgery.

Materials and Methods


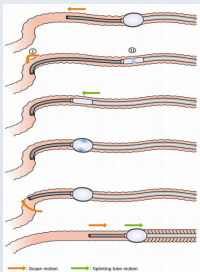
Retrospective review of 62 patients with non-pulsatile VAD's over a 7 year period for episodes of GIB.

→GIB was defined as: heme positive stool and drop in Hgb \geq 2g.

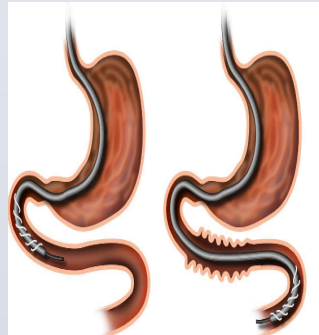
→All patients were anticoagulated on either aspirin, Plavix, Coumadin or a combination of these medications and had no bleeding history prior to the initial bleed.

→End points measured were number of packed red blood cells received and the number of tests performed per episode of GIB.

Single Balloon and Double Balloon Enteroscope



Spiral Enteroscopy



Contact Information

Dr. Nicholas Cavarocchi
Email: nicholas.cavarocchi@jefferson.edu

Results

There were 41 individual episodes of GIB in 14 patients. The sentinel bleed occurred within the first year of VAD implant in 13 of 14 (93%) patients. Ten of the fourteen patients (71%) developed a second bleed and all of these subsequent bleeding episodes (100%) were seen within 1 year of the sentinel bleed. Of the 41 episodes, 33 individual sites were identified using a spectrum of imaging modalities.

The most common locations were the duodenum (36%) followed by the jejunum (25%) and the source pathology was AVM in 30 of 33 (91%) with the remaining being diverticuli and a polyp.

Thus, the proximal GI tract accounted for over 78% of the lesions that we were able to identify.

Episodes were separated into two groups; Group A consisted of episodes where the diagnosis and treatment was performed within 48 hours, and Group B where it took greater than 48 hours. Our results showed that patients in group A received half the units of blood (3.53 v. 7.33; p<0.05) and underwent fewer procedures (2.14 v. 3.22; p=0.109).

Most Common Sites Identified As Source of GIB

Stomach	4
Duodenum	12 (36%)
Jejunum	9 (25%)
Ileum	1
Colon	7
Total	33

Outcomes of Group Comparison

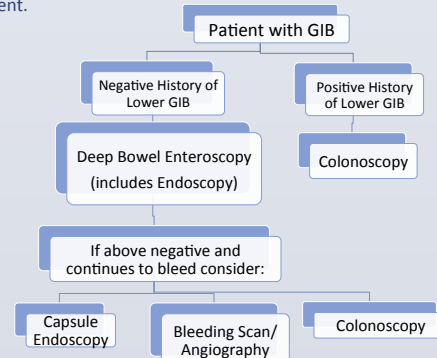
	Group A (Dx/Tx <48hrs)	Group B (Dx/Tx >48hrs)	P value
# of Episodes (n)	14	9	
PRBC / Episode	2.285	7.33	0.0168
# of Tests / Episode	2.14	3.11	0.1095

Recognizing our preliminary data, we investigated the number of episodes which were treated with DBE on initial presentation and found that seven episodes of GIB were managed with initial DBE for AVM's and 100% were successfully treated on the same day.

Thus, this led to the development of our algorithm for the diagnosis and treatment of GIB in VAD patients using DBE.

Discussion and Conclusion

Traditional GIB algorithms were designed for medical patients with little emphasis on speedy diagnosis and are aimed at most common sites of bleeding seen in the general population. Non-pulsatile VAD patients with GIB are different; they require modern modalities aiming at the most common locations of bleeding specific to this population. Our study shows the upper GI tract as the most common site with AVM's being the predominant pathology. Utilizing our algorithm, DBE can be performed upon presentation thus eliminating the need for further tests and limiting the number of PRBC's given to the patient.



With most AVM's located in the duodenum and jejunum, diagnostic attention should be placed on the proximal small bowel. This algorithm utilizing initial DBE will decrease transfusions, decrease the number of procedures performed and potentially decrease antibody formation while lowering hospital costs and providing a rapid therapy for our patients.