

Case Report

Erosive Eosinophilic Esophagitis in Rumination Syndrome

†Shawn S Sidhu, ‡James R Rick

† *Northwestern McGaw/NMH/VA-IL* ‡ *Pediatric Gastroenterology Division of Wright Patterson Air Force Base of Dayton, OH;*

INTRODUCTION

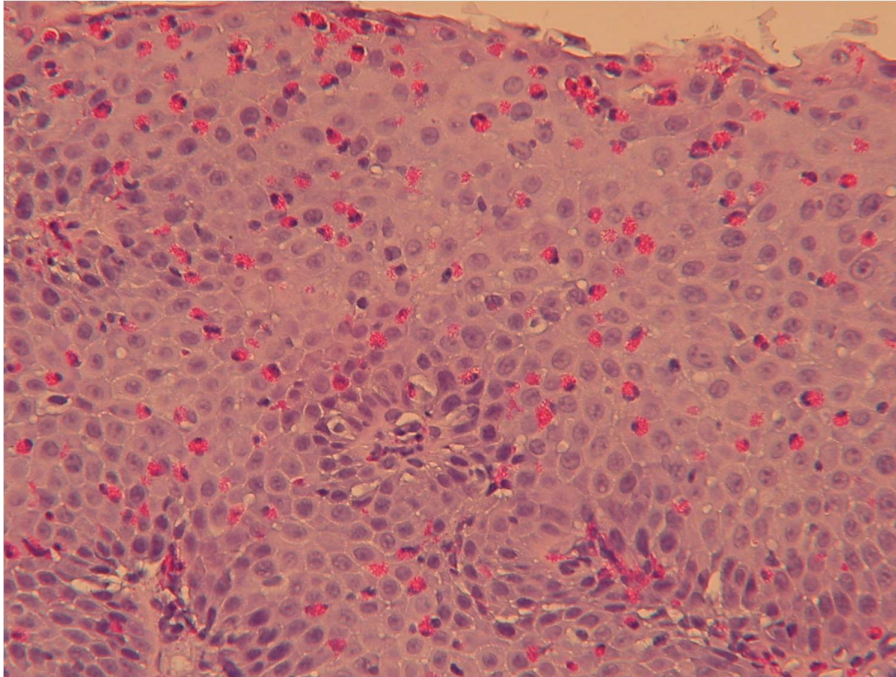
Rumination syndrome involves bringing up partially digested food into the pharynx voluntarily, followed by reswallowing or expelling.¹ It was discovered in the 17th century²; however, knowledge of the disorder has remained sparse until recently. Indeed, the first case of adult rumination in Japan was reported as recently as 2006.³ Due to this recent increase in awareness, notions about the disease have remained in a state of constant fluctuation. While first believed to be a disease of neurologically-impaired⁴ children between 3 and 8 months of age⁵, it is now widely recognized as occurring in men and women of all ages and cognitive abilities.^{6,7,8} Originally rumination was labeled benign⁹; however, it is now known to cause such complications as weight loss, malnutrition, dental erosions, halitosis, electrolyte abnormalities,¹⁰ abdominal discomfort, weight loss,⁶ choking, aspiration, and pneumonia.¹¹ Similarly, while the absence of gastroesophageal reflux disease was an original criterion for the syndrome,¹² it has been found that many of these patients have evidence of “pathologic gastroesophageal reflux.”¹³ Some suggest that thorough upper gastrointestinal workup, such as upper esophageal barium studies and EGD, not be done on children presenting with rumination, despite the presence of abdominal pain or other accompanying gastrointestinal symptoms.⁶ We performed a thorough upper gastrointestinal workup on a patient with concurrent rumination syndrome and heartburn, and were intrigued by the findings.

CASE REPORT

A 10 year old boy in the fifth grade with anxiety disorder, obsessive-compulsive disorder, and allergic rhinitis was referred to the Department of Pediatric Gastroenterology to evaluate suspected esophageal reflux. History revealed a chronic pattern of post-prandial regurgitation, rechewing, and reswallowing of food and liquids consistent with rumination syndrome of two year duration. He did experience heartburn and noted an “acid-like” sensation in his pharynx even in the absence of food. Remarkably, he was able to willfully suppress and/or aggravate his regurgitation and it occurred up to 20-40 times a day. He denied any dysphagia, retching, nausea, chest or abdominal pain. Ranitidine had been started by his Pediatrician with a reduction in the heartburn, but no change in the rumination. His anxiety and obsessive-compulsive disorders were managed by psychotherapy and prozac 20 mg qd. The only other medication was zyrtec 10 mg qd. His general development was normal and academic performance in public school excellent. Family history was significant for maternal history of esophageal reflux and hiatal hernia with subsequent fundoplication. His vital signs were normal and height, weight and body mass index were noted to be at the 20th percentile, 35th percentile and 60th percentile for his age, respectively. Physical exam was normal, though very prominent circumvallate papillae on the posterior aspect of the tongue were noted.

He was started on lansoprazole 15 mg po qd and an upper gastrointestinal series was found to be normal. Because of persistent heartburn and regurgitation, an upper gastrointestinal endoscopy was performed. Interestingly, distal erosive esophagitis and an antral predominant nodular gastritis were found. A mild active gastritis was seen on biopsy with *Helicobacter pylori* identified by special stains. *Campylobacter pylori*-like organism (CLO test) rapid urea test was positive. The distal esophageal biopsy showed dense intraepithelial eosinophilic infiltration and basilar hyperplasia (Image 1). The middle and

upper esophagus were not biopsied secondary to normal endoscopic appearance. He was treated with lansoprazole 15 mg BID and a ten day course of amoxicillin and clarithromycin. Six weeks after the endoscopy, *H. pylori* fecal antigen test was negative. He was continued on acid suppression, anti-depressants, and psychotherapy.



Despite these therapies, breakthrough heartburn, regurgitation and rumination persisted. Four months later, a follow up upper endoscopy was performed. This time his esophagus and gastric mucosa appeared completely normal, with gross resolution of the previous findings. While the middle esophageal biopsy was negative, the distal esophageal biopsy showed squamous epithelium with scattered (2-4/hpf) intraepithelial eosinophils, a reduction from the prior biopsy. There was no evidence of *H. pylori*. Acid suppression was increased sequentially increased to 30 mg of lansoprazole BID with resolution of his heartburn and acid sensation. His rumination has continued and he is currently being instructed on diaphragmatic breathing with partial success.

DISCUSSION

Eosinophilic esophagitis is thought to be either reflux-induced or allergic in nature.¹⁴ Our patient's case was most likely reflux-induced because "gross and histologic esophageal abnormalities normalized following treatment with a PPI, implicating acid reflux as the underlying cause."¹⁴ Yet, the central issue at hand isn't our patient's diagnosis. The novel issue being discussed here is the standard of care in a child presenting with both rumination syndrome and heartburn. The current standard of care in rumination is reassurance and behavioral therapy as a treatment modality.^{3,13,15,16,17,18,19,20,21,22,23} As stated above, upper gastrointestinal barium series and EGD have been deemed noncontributory in patients with rumination syndrome.⁶ Some doubt esophagitis occurs at all patients with rumination, claiming "vomitus contains mainly food, and acid, if present, does not have prolonged contact with the esophageal mucosa."¹⁸ Clearly, our patient was a ruminator with pathologic erosive esophagitis. Had we adhered to these guidelines, we would've missed a major finding in our patient. Eosinophils in the esophageal mucosa, to any degree, is considered pathologic.²⁴ Our effective treatment of his reflux esophagitis could've prevented potentially serious complications of esophagitis, such as ulcers, laryngeal disease, chronic cough, Barrett's esophagus, and esophageal adenocarcinoma.²⁵ By no means do we feel that every child with rumination syndrome should receive a thorough upper gastrointestinal workup. Our suggestion is that those with accompanying heartburn be evaluated for their reflux.

REFERENCES

- 1) American Psychiatric Association. Diagnostic and statistical manual of mental disorders. 3rd ed, revised. Washington (DC): American Psychiatric Association; 1987.
- 2) Kanner L. Historical notes on rumination in man. *Med Life* 1936;43:27-60.
- 3) Sugawa T, Fujiwara Y, Okuyama M, et al. Rumination syndrome in an adult with normal intelligence. *Nippon Shokakibyō Gakkai Zasshi*. 2006 Jun;103(6):631-5.
- 4) Sullivan PB. Gastrointestinal problems in the neurologically impaired child. *Baillieres Clin Gastroenterol*. 1997;11(3):529-46.
- 5) Rasquin-Weber A, Hyman PE, Cucchiara S, et al. Childhood functional gastrointestinal disorders. *Gut* 1999;45:60-68.
- 6) Chial HJ, Camilleri M, Willieams DE, et al. Rumination syndrome in children and adolescents: diagnosis, treatment, and prognosis. *Pediatrics* 2003;111:158-162.
- 7) Malcolm A, Thumshirn MB, Camilleri M, et al. Rumination Syndrome. *Mayo Clin Proc* 1997;72:646-652
- 8) Olden KW. Rumination Syndrome. *Curr Treat Options Gastroenterol* 2001;4:351-358.
- 9) Levine DF, Wingate DL, Pfeffer JM, Butcher P. Habitual rumination: A benign disorder. *BMJ* 1983;287:255-6.
- 10) O'Brien MD, Bruce BK, Camilleri M. The rumination syndrome: clinical features rather than manometric diagnosis. *Gastroenterology* 1995; 108:1024-1029.
- 11) Konarski EA, Favell JE. Manual for the Assessment and Treatment of Behavior Disorders of People With Mental Retardation. North Carolina: Western Carolina Center Foundation, 1992.
- 12) Clouse RE, Richter JE, Heading RC, Janssens J, Wilson JA. Functional esophageal disorders. *Gut* 1999;45(suppl 2):1131-1136.
- 13) Tack J, Talley NJ, Camilleri M, et al. Functional Gastrointestinal Disorders. *Gastroenterology* 2006;130:1466-1479.
- 14) Ngo P, Furuta GT, Antonioli DA, et al. Eosinophils in the esophagus-peptic or allergic eosinophilic esophagitis? Case series of three patients with esophageal eosinophilia. *Am J Gastroenterol* 2006;101:1666-1670.
- 15) Amamath RP, Abell TL, Malagelada JR. The rumination syndrome in adults. A characteristic manometric pattern. *Ann Intern Med* 1986;105:513-8.
- 16) Chitkara DK, Tilburg MV, Whitehead WE, et al. Teaching Diaphragmatic Breathing for Rumination Syndrome. *Am J Gastroenterol* 2006;101:2449-2452.
- 17) Johnson WG, Corrigan SA, Crusco AH, Jarell MP. Behavioral assessment and treatment of post-prandial regurgitation. *J Clin Gastroenterol* 1987;9:679-84.
- 18) Khan S, Hyman PE, Cocjin J, et al. Rumination syndrome in adolescents. *J Pediatr* 2000;136:528-31.
- 19) Oelschlager BK, Chan MM, Eubanks TR, et al. Effective treatment of rumination with nissen fundoplication. *J Gastrointest Surg* 2002;6:638-644.
- 20) Parther CM, Litzinger KL, Camilleri M, Thumshirn M, Williams DE. An open trial of cognitive behavioral intervention in the treatment of rumination syndrome [abstract]. *Gastroenterology* 1997;112:A808.
- 21) Shay SS, Johnson LF, Wong RK, et al. Rumination, heartburn, and daytime gastroesophageal reflux. A case study with mechanisms defined and successfully treated with biofeedback therapy. *J Clin Gastroenterol* 1986;8:115-126.
- 22) Smout AJ, Breumelhof R. Voluntary induction of transient lower esophageal sphincter relaxation in an adult patient with rumination syndrome. *Am J Gastroenterol* 1990;85:1621-5.
- 23) Sokel BS, Devane SP, Bentovim A, Milla PJ. Self hypnotherapeutic treatment of habitual reflex vomiting. *Ach Dis Child* 1990;65:626-7.
- 24) Winter HS, Madara JL, Stafford RJ, et al. Intraepithelial eosinophils: a new diagnostic criterion for reflux esophagitis. *Gastroenterology* 1982;83:818-23.
- 25) Featherstone EA. Severe GERD: effective treatment prevents potentially serious complications. *JAAPA*. 2005 Apr;18(4):25-9;quiz31-2