

6-2007

# Massive Retroperitoneal Hematoma Caused by Retroperitoneal Ectopic Pregnancy

Jay Goldberg

*Thomas Jefferson University, Jay.Goldberg@jefferson.edu*

Michael Weinstein

*Thomas Jefferson University, Michael.Weinstein@jefferson.edu*

Kris Kaulback

*Thomas Jefferson University, Kris.Kaulback@jefferson.edu*

Aileen Gariepy

*Thomas Jefferson University*

George Bega

*Thomas Jefferson University, Gjergji.Bega@jefferson.edu*

## [Let us know how access to this document benefits you](#)

Follow this and additional works at: <http://jdc.jefferson.edu/surgeryfp> Part of the [Obstetrics and Gynecology Commons](#), and the [Surgery Commons](#)

### Recommended Citation

Goldberg, Jay; Weinstein, Michael; Kaulback, Kris; Gariepy, Aileen; and Bega, George, "Massive Retroperitoneal Hematoma Caused by Retroperitoneal Ectopic Pregnancy" (2007). *Department of Surgery Faculty Papers*. Paper 61.

<http://jdc.jefferson.edu/surgeryfp/61>

## CASE REPORT

# Massive Retroperitoneal Hematoma Caused by Retroperitoneal Ectopic Pregnancy

Jay Goldberg, MD, MSCP; Michael Weinstein, MD; Kris Kaulback, MD; Aileen Garipey, MD; George Bega, MD

**A** massive retroperitoneal hematoma caused by a retroperitoneal ectopic pregnancy is managed successfully utilizing multidisciplinary cooperation and transfusion of blood products.

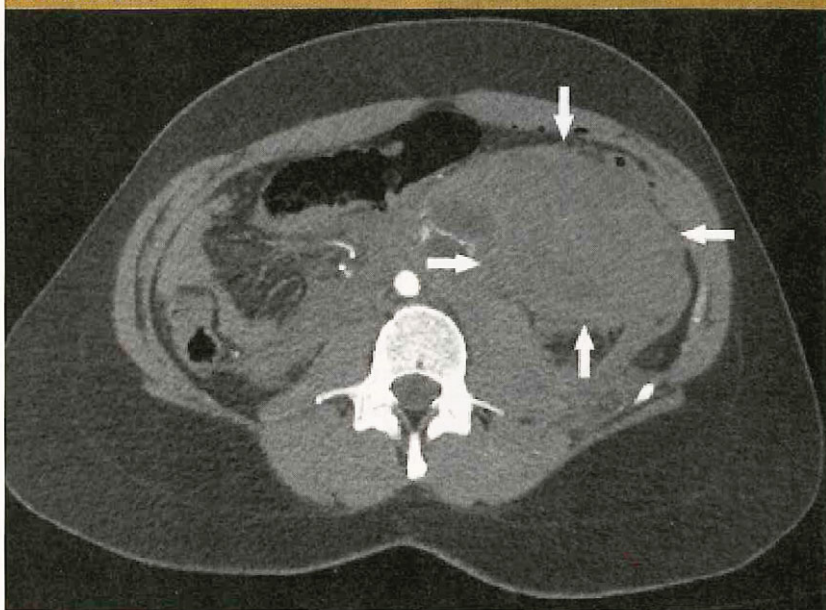
An ectopic pregnancy is defined as a gestation implanted in a location other than within the uterine cavity. While these most commonly occur in the fallopian tube, ectopic pregnancies may rarely occur in the cervix, ovary, or abdominal cavity. The authors report an unusual case of a retroperitoneal ectopic pregnancy presenting as a massive retroperitoneal hematoma in a hemodynamically unstable patient.

### CASE REPORT

A 24-year-old woman (gravida 4, para 1021) presented to the emergency department at 8 weeks' gestation by last menstrual period. She complained of

Jay Goldberg, MD, MSCP, is director, Division of General Obstetrics and Gynecology; Michael Weinstein, MD, is assistant professor of surgery; Kris Kaulback, MD, is associate professor of surgery; Aileen Garipey, MD, is instructor of obstetrics and gynecology; and George Bega, MD, is director, 3D/4D Ultrasound Imaging Program. All are at Jefferson Medical College, Philadelphia, Penn.

FIGURE 1.



Axial computed tomographic arteriogram showing a 20-x-15-cm hemorrhagic retroperitoneal mass below the left anterior perirenal space extending down into the upper pelvis.

Courtesy of Jay Goldberg, MD, MSCP.

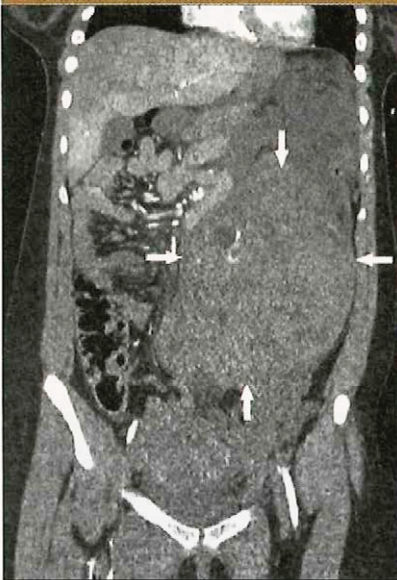increasing abdominal pain of 1 day's duration. She was unaware that she was pregnant. She had no history of prior surgeries or sexually transmitted infections, and denied any recent trauma.

On presentation, the patient's vital signs were initially stable. She was noted on examination to have significant abdominal pain with rebound and guarding but no palpable masses. Pelvic exami-

nation revealed a nongravid-sized uterus with no adnexal tenderness, adnexal enlargement, or cervical motion tenderness.

The patient's serum human chorionic gonadotropin (hCG) level was 24,872 mIU/mL, and the hemoglobin value was 11.4 g/dL. Transabdominal and transvaginal ultrasonography showed a nongravid-sized uterus, with no evidence of an intrauterine gestation.

FIGURE 2.



Frontal computed tomographic arteriogram showing a 20-x-15-cm hemorrhagic retroperitoneal mass below the left anterior perirenal space extending down into the upper pelvis.

Courtesy of Jay Goldberg, MD, MSCP.

No adnexal mass was identified, but there was a moderate amount of fluid in the cul-de-sac.

Approximately 2 hours after presentation, the patient became hypotensive and tachycardic. She was taken to the operating room for exploratory surgery, with a presumptive diagnosis of a ruptured tubal ectopic pregnancy.

In the operating room, exploratory laparotomy was performed through a low transverse incision. Approximately 100 mL of blood was suctioned from the pelvis. The uterus, fallopian tubes, ovaries, and broad ligaments appeared normal. Exploration of the upper abdomen revealed a massive, left-sided, retroperitoneal hematoma behind the left colonic mesentery. It was nonpulsatile and nonexpanding,

and not bleeding into the peritoneal cavity. Due to continued hypotension and an intraoperative hemoglobin level of 5.5 g/dL, 4 units of packed red blood cells (RBCs) and 3 units of fresh frozen plasma (FFP) were transfused. At that point, it was decided that further exploration of the hematoma was neither necessary nor advisable, and the patient's abdomen was closed.

Immediate postoperative computed tomographic arteriography of the abdomen and pelvis was performed, demonstrating a 20-x-15-cm hemorrhagic retroperitoneal mass below the left anterior perirenal space extending down into the upper pelvis (Figures 1 and 2). There was no evidence of pseudoaneurysm or active bleeding. An interventional radiologist was consulted, but the hematoma was not amenable to embolization.

Given the suspicion of an ectopic pregnancy, possibly retroperitoneal in location, a 90-mg intramuscular dose of methotrexate was administered based on her calculated body surface area. The plan was to closely monitor the patient, transfuse additional blood products as needed, and return to the operating room if she became unstable.

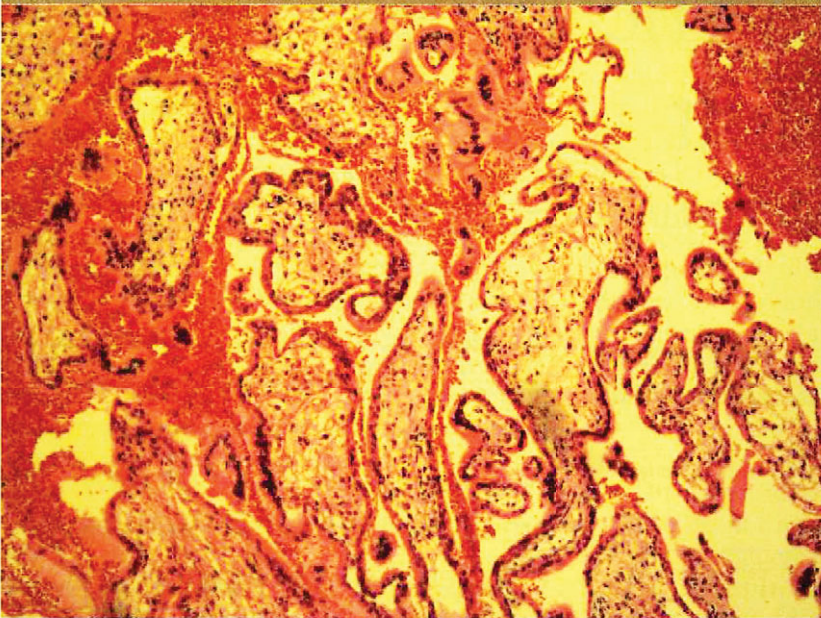
Approximately 20 hours later, the patient's hemoglobin values had dropped from 9.6 to 6.8 g/dL and she again became hypotensive, so she was returned to the operating room for exploration of the retroperitoneal hematoma. A midline skin incision was made extending above the umbilicus. There was a significant amount of intra-abdominal blood arising from a small hole in the very tense retroperitoneal hematoma. The hematoma was opened with cautery, and approximately 2 L

of clotted blood were removed. Bright red blood was oozing from a quarter-sized vascular area in the most superior portion of the hematoma cavity. Clips were applied to the vascular structures, resulting in hemostasis. No products of conception were grossly visible at the time of surgery. In total, from admission to completion of the second surgery, the patient received 12 units of packed RBCs and 8 units of FFP. Pathologic evaluation of the evacuated clotted blood revealed chorionic villi (Figure 3), confirming the suspected diagnosis of retroperitoneal ectopic pregnancy leading to a hematoma.

**Pathologic evaluation of the evacuated clotted blood revealed chorionic villi (Figure 3), confirming the suspected diagnosis of retroperitoneal ectopic pregnancy leading to a hematoma.**

Two days after evacuation of the retroperitoneal hematoma, the patient's serum hCG level had decreased from 24,872 to 6,000 mIU/mL. Two days later, it had declined to 3,200 mIU/mL. Her postoperative course was complicated by intermittent fever and a mild ileus. These resolved without specific interventions. The patient was discharged 8 days after her initial

FIGURE 3.



Microscopic image (200 $\times$ ) of degenerating chorionic villi identified in the evacuated retroperitoneal blood clot.

Courtesy of Jay Goldberg, MD, MSCP.

presentation, without further complication. Her hCG level was followed serially as an outpatient until it fell to less than 10 mIU/mL 3 weeks later.

## DISCUSSION

The management of retroperitoneal hemorrhage is based on hemodynamic parameters and secondary clinical findings. The majority of retroperitoneal hemorrhage is from venous sources and thus can be managed with expeditious correction of coagulopathy, volume replacement, and close monitoring. Patients who continue to bleed despite these efforts often have an arterial etiology and may benefit from angiography with embolization or stenting. Surgery to control bleeding in the retroperitoneum can be quite challenging, and is usually reserved for patients who do not respond

to initial volume replacement or who have failed angiography. Rarely, a decompressive operation may be indicated when retroperitoneal bleeding causes femoral or lumbar plexus neuropathies or abdominal compartment syndrome.

Spontaneous retroperitoneal hematomas are uncommon. The majority of retroperitoneal hematomas are secondary to anticoagulation therapy. Other etiologies include neoplasm, arterial aneurysm, pseudoaneurysm rupture, and trauma.

Very few cases of retroperitoneal ectopic pregnancy have been reported.<sup>1-3</sup> Following in vitro fertilization-embryo transfer (IVF-ET), a retroperitoneal ectopic pregnancy was hypothesized to have occurred via uterine perforation, with retroperitoneal placement of the transferred embryo.<sup>1</sup> Reports in the absence of IVF-ET

have theorized that retroperitoneal implantation may have occurred via vascular routes, lymphatic channels, or transperitoneal trophoblastic invasion.<sup>2,3</sup>

## CONCLUSION

This case is of interest because of the unusual presentation and successful management of a hemodynamically unstable patient with a massive retroperitoneal hematoma

*Surgery to control bleeding in the retroperitoneum can be quite challenging, and is usually reserved for patients who do not respond to initial volume replacement or who have failed angiography.*

due to retroperitoneal implantation of an ectopic pregnancy. While rare, successful outcome of this life-threatening condition is predicated on multidisciplinary cooperation, clinical vigilance, and potentially massive transfusion of blood products.

## REFERENCES

1. Ferland RJ, Chadwick DA, O'Brien JA, Granai CO 3rd. An ectopic pregnancy in the upper retroperitoneum following in vitro fertilization and embryo transfer. *Obstet Gynecol.* 1991;78(3 pt 2):544-546.
2. Lee JW, Sohn KM, Jung HS. Retroperitoneal ectopic pregnancy. *AJR Am J Roentgenol.* 2005;184(5):1600-1601.
3. Sotus PC. Retroperitoneal ectopic pregnancy: a case report. *JAMA.* 1977;238(13):1363-1364.