



2012

Hematemesis, a Distended Abdomen, and Pulseless Electrical Activity – An Unusual Presentation of Boerhaave’s Syndrome

Andrew Garrett, MD
Thomas Jefferson University

Marie Nguyen, MD
Thomas Jefferson University

Lindsay Wilde, MD
Thomas Jefferson University

Andrew Toscano, MD
Thomas Jefferson University

Philip Pancari, MD
Thomas Jefferson University

See next page for additional authors

Follow this and additional works at: <http://jdc.jefferson.edu/tmf>

 Part of the [Medicine and Health Sciences Commons](#)

[Let us know how access to this document benefits you](#)

Recommended Citation

Garrett, MD, Andrew; Nguyen, MD, Marie; Wilde, MD, Lindsay; Toscano, MD, Andrew; Pancari, MD, Philip; and Lerner, MD, Andrew (2012) "Hematemesis, a Distended Abdomen, and Pulseless Electrical Activity – An Unusual Presentation of Boerhaave’s Syndrome," *The Medicine Forum*: Vol. 13, Article 7.

Available at: <http://jdc.jefferson.edu/tmf/vol13/iss1/7>

This Article is brought to you for free and open access by the Jefferson Digital Commons. The Jefferson Digital Commons is a service of Thomas Jefferson University's [Center for Teaching and Learning \(CTL\)](#). The Commons is a showcase for Jefferson books and journals, peer-reviewed scholarly publications, unique historical collections from the University archives, and teaching tools. The Jefferson Digital Commons allows researchers and interested readers anywhere in the world to learn about and keep up to date with Jefferson scholarship. This article has been accepted for inclusion in *The Medicine Forum* by an authorized administrator of the Jefferson Digital Commons. For more information, please contact: JeffersonDigitalCommons@jefferson.edu.

Hematemesis, a Distended Abdomen, and Pulseless Electrical Activity – An Unusual Presentation of Boerhaave’s Syndrome

Authors

Andrew Garrett, MD; Marie Nguyen, MD; Lindsay Wilde, MD; Andrew Toscano, MD; Philip Pancari, MD;
and Andrew Lerner, MD

HEMATEMESIS, A DISTENDED ABDOMEN, AND PULSELESS ELECTRICAL ACTIVITY – AN UNUSUAL PRESENTATION OF BOERHAAVE'S SYNDROME

Andrew Garrett, MD, Marie Nguyen, MD, Lindsay Wilde, MD, Andrew Toscano, MD, Philip Pancari, MD, and Andrew Lerner, MD

Case Presentation

An 82-year-old male with a past medical history significant for coronary artery disease with three stents placed over the last 15 months, diastolic heart failure with preserved EF, atrial fibrillation on warfarin, colon cancer status-post sigmoid resection and prostate cancer status-post prostatectomy who presented with three episodes of melena, hematemesis, and weakness. The patient was in his usual state of health prior to these symptoms. He had no history of gastrointestinal (GI) bleeding or other GI pathology and was a non-drinker and non-smoker. He denied frequent use of non-steroidal anti-inflammatory medications.

Hospital Course

The patient initially presented to an outside hospital where he had a hemoglobin of 9.6 g/dL (baseline of approximately 11 g/dL) and had an International Normalized Ratio (INR) of 3.5. The patient was given subcutaneous vitamin K and transfused with packed red blood cells and fresh frozen plasma. Given the persistence of melanic stools and blood via nasogastric lavage, he was transferred to the intensive care unit (ICU). The patient was stabilized and transferred to Thomas Jefferson University Hospital (TJUH) for further care. No procedures were performed prior to transfer.

At the time of presentation to the TJUH ICU, the patient's vital signs were as follows: temperature 96.3° F, blood pressure 135/56, pulse of 77 and irregularly irregular, respiratory rate 16, and oxygen saturation 96% on room air. His hemoglobin was 8.0 g/dL, platelets were 142,000 cells/mcL, and INR was 1.71. His physical exam was remarkable for slight epigastric tenderness and red blood return from the nasogastric tube that did not clear with lavage.

The decision was made to take the patient for esophagogastroduodenoscopy (EGD) and he was intubated prior to the procedure for airway protection due to persistent hematemesis. EGD showed no active signs of bleeding. However, it was remarkable for suspected Barrett's esophagus, a gastric ulceration covered by eschar and a gastroesophageal (GE) junction ulceration that was likely the original bleeding source. Biopsies were obtained from the distal esophagus and stomach. The patient was extubated without incident and remained stable over the next several hours.

After the patient's first oral intake post-EGD, he became nauseated and began to vomit large quantities of bright red

blood. The patient was emergently intubated and underwent a repeat EGD, which revealed a perforation at the gastroesophageal junction. Subsequently, his abdomen became progressively more distended and tympanitic. The following upright x-ray was taken (Figure 1).

A STAT surgery consult was called for acute esophageal perforation. Meanwhile, the patient became hypotensive requiring aggressive fluid resuscitation, massive transfusion protocol and vasopressors. As the surgeons arrived at bedside, the patient lost his pulse. Telemetry and exam revealed pulseless electrical activity and a Code Blue was called. Advanced cardiac life support was performed by a multidisciplinary team. Approximately 5 minutes into the Code, the patient's abdomen was emergently decompressed with a midline abdominal incision. The patient regained a pulse approximately fifteen minutes after resuscitation began. The patient remained intubated and unresponsive to any stimulus. Blood work revealed a severe metabolic acidemia with a pH of 6.8. After discussion with the family, life support was discontinued and the patient expired. Pneumomediastinum causing cardiac tamponade physiology and abdominal compartment syndrome causing lack of venous return and output was thought to be the cause of the rapid demise in the setting of subdiaphragmatic Boerhaave's syndrome.

Discussion

Cardiac function and a perfusing pulse returned shortly after abdominal decompression. Unfortunately, despite the delivery of high quality chest compressions, the lack of preload meant that there was likely little to no cardiac output. This phenomenon has been described in two previous case reports, one of which described cardiac arrest due to tension pneumomediastinum from supradiaphragmatic Boerhaave's.^{1,2}

Boerhaave's syndrome is a rare condition first described in 1724 by Dr. Herman Boerhaave after the post-mortem examination of Baron de Wassenauer.³ The pathophysiology of this syndrome is a rapid increase in intraluminal esophageal pressure (classically from retching or vomiting) combined with negative intrathoracic pressure leading to a spontaneous transmural esophageal rupture. As the esophagus is the only part of the digestive tract that lacks a serosal layer, it is most susceptible to perforation. The tear occurs in the left postero-lateral aspect of the distal esophagus in 90% of cases, approximately 2-4 cm longitudinally in an area thought to be an anatomical weak spot.⁴

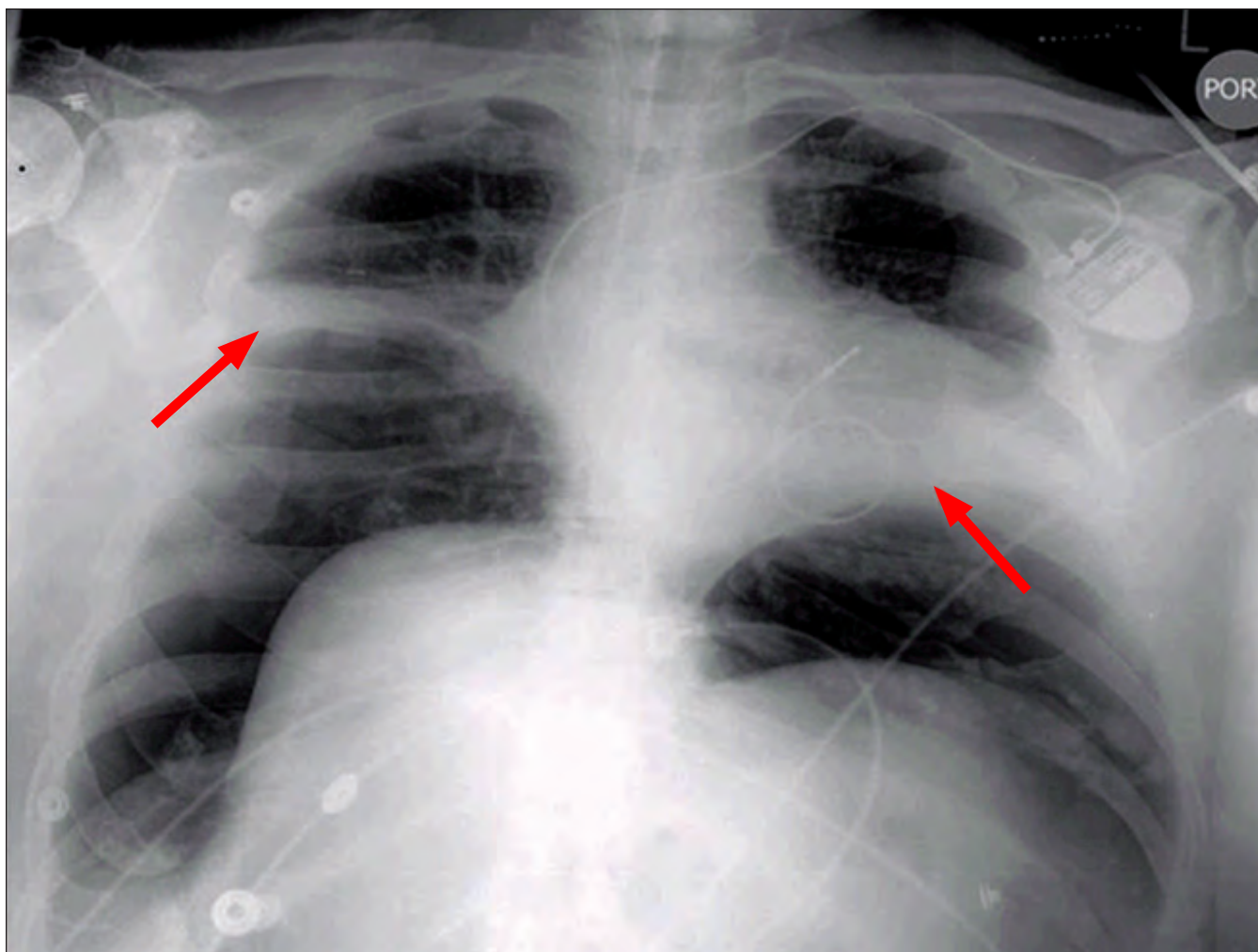


Figure 1. Upright chest x-ray with arrows indicating the diaphragm

The incidence of Boerhaave's syndrome is estimated to be 3 in 50,000-100,000 hospital admissions, but true figures are difficult to determine due to the rarity of the syndrome.⁵ The male to female ratio has been reported as high as 5 to 1 and no racial predilection has been identified.⁴ Expulsion of oral and gastric contents into the mediastinum and pleural space leads to local inflammation and systemic sepsis with an initial associated mortality of 30% which, if left untreated, nears 100%.⁶ Diagnostic delays are common as the initial presentation is often nonspecific, which is historically related to an increase in morbidity and mortality.⁷

Spontaneous esophageal ruptures account for 15-30% of all esophageal ruptures, whereas iatrogenic causes account for 50-60%, and traumatic ruptures another 10-15%.⁷⁻¹¹ Spontaneous rupture is most closely associated with chronic alcohol use (40%), a history of gastric or duodenal ulcers (41%), anorexia nervosa, and bulimia nervosa.¹² Most patients present with chest or epigastric pain (85-90%) and vomiting (71%).^{8,13}

The classic Mackler's triad is the constellation of vomiting, lower chest pain, and subcutaneous emphysema. One series of 127 patients found that subcutaneous emphysema was present in 47% of the cases.⁸ In our patient, the rupture occurred below the diaphragm, which led to his abdominal distention and ultimate deterioration. By location, the most common site of rupture is the thoracic esophagus.⁴ In another series of 119 patients, ruptures by esophageal location were 13% cervical, 80% thoracic, and 7% abdominal.¹¹

Routine imaging remains critical in diagnosis. Left-sided pleural effusion and corresponding pneumothorax 80-90% of cases will have with or without a widened mediastinum on upright chest x-ray.¹³ Most importantly in our case, subdiaphragmatic free air was the critical imaging finding. The "V sign of Naclerio" may also be present, which is a v-shaped radiolucency encompassing pleural and mediastinal structures.⁵ However, plain radiographs can be normal in 12-33% of cases of esophageal perforations.¹⁴ Computed tomography is most sensitive for this syndrome,

which may demonstrate an esophageal communication and mediastinal free air. Due to the emergent nature of this syndrome, a CT of the chest is not always feasible.

Laboratory testing provides little in terms of diagnosis, as there is no one result that may be suggestive of the diagnosis. If pleural effusion is present a pleural fluid analysis may demonstrate undigested food, a low pH and a high amylase level. In pleural fluid concerning for esophageal rupture, a water-soluble (Gastrografin) contrast esophagram should be performed to confirm the diagnosis.^{15,16} However, there is a 10% false negative rate associated with contrast esophagrams.⁸ In those instances, if the clinical suspicion is still high, a barium swallow study or CT of the chest are an appropriate next step in management. Although barium is known to cause inflammation and subsequently fibrosis when in contact with the mediastinum, it is superior in demonstrating small perforations.

The insufflation necessary for EGD could pose the risk of evolution of perforation and further free air into thoracic or abdominal spaces. EGD itself carries approximately a 0.4% overall risk of perforation, with diagnostic accounting for 0.03%, dilation 0.25% and notably dilation for achalasia 4%.¹⁷ As most endoscopic procedures are to explore pathology related to strictures, the diseased portions of esophagus are often the weakest points and the areas of iatrogenic rupture.¹⁷ Per GI reports, our patient's rupture was not at the site of previous biopsy but more likely at the site of previously noted GE-junction ulceration. Although inadvertent, the insufflation during the second EGD that demonstrated the perforation led to an increase in amount of subdiaphragmatic free air and an acceleration of our patient's disease.

References

- Witz, M et al. Spontaneous rupture of distal esophagus (Boerhaave's syndrome) with unusual clinical presentation of pneumoperitoneum. *Postgrad Med J*. 1984 January; 60(699): 60–61.
- Paluszkiwicz, P et al. Cardiac Arrest Caused by Tension Pneumomediastinum in a Boerhaave Syndrome Patient. *The Annals of Thoracic Surgery*. Volume 87, Issue 4, April 2009, Pages 1257-1258
- Derbes VJ and Mitchell RE Jr. Hermann Boerhaave's atrocis, nec Descripti priu, morbi Historia; the first translation of the classic case report of rupture of the esophagus, with annotations. *Bull Med Libr Assoc*. 1955 Apr; 43(2):217-240.
- Callaghan J. The Boerhaave Syndrome. *Brit J Surg* 1972 Jan; 59(1):41-44.
- Korczynski P, et al. Acute respiratory failure in a patient with spontaneous esophageal rupture (Boerhaave syndrome). *Respir Care*. 2011 Mar;56(3):347-50.
- Vial CM and Whyte RI. Boerhaave's syndrome: diagnosis and treatment. *Surg Clin North Am*. 2005 Jun; 85(3):515-524.
- Gupta NM, Kaman L. Personal management of 57 consecutive patients with esophageal perforation. *Am J Surg* 2004; 187:58.
- Bladergroen MR et al. Diagnosis and recommended management of esophageal perforation and rupture. *Ann Thorac Surg*. 1986 Sept; 42(3):235-239.
- Brinster CJ, et al. Evolving options in the management of esophageal perforation. *Ann Thorac Surg* 2004;77(4):1475–1483.
- Vallböhmer D, et al. Options in the management of esophageal perforation: analysis over a 12-year period. *Dis Esophagus* April 2010; 23(3):185–190.
- Bhatia, P et al. Current Concepts in the Management of Esophageal Perforations: A Twenty-Seven Year Canadian Experience. *The Annals of Thoracic Surgery*. Volume 92, Issue 1, July 2011, Pages 209-215
- Brauer RB et al. Boerhaave's syndrome: analysis of the literature and report of 18 new cases. *Dis Esophagus*. 1997 Jan; 10(1):64-68.
- Pate JW et al. Spontaneous rupture of the esophagus: a 30-year experience. *Ann Thorac Surg*. 1989 May; 47(5):689-92.
- Jones WG and Ginsberg RJ. Esophageal perforation: a continuing challenge. *Ann Thorac Surg*. 1992 Mar; 53(3):534-543.
- Payne WS, Brown W Jr, Fontana RS. Esophageal perforation, Mallory Weiss syndrome, and acquired esophageal fistulas. In: Payne WS, Olsen AM, eds. *The esophagus*. Philadelphia: Lea & Febiger, 1974:171-189.
- Drury M, Anderson W, Heffner JE. Diagnostic value of pleural fluid cytology in occult Boerhaave's syndrome. *Chest* 1992;102(3):976–978.
- Michel, L et al. Esophageal Perforation. *Annals of Thoracic Surgery*. Feb 1982;33(2):203-210
- Barrett NR. Report of a case of spontaneous perforation of the esophagus successfully treated by operation. *Br J Surg*. 1947 Oct; 35(138):216-218.
- Brinster CJ et al. Evolving options in the management of esophageal perforation. *Ann Thorac Surg* 2004 Apr; 77(4):1475-1483.
- Petruzzello et al. Successful early treatment of Boerhaave's syndrome by endoscopic placement of a temporary self-expandable plastic stent without fluoroscopy. *Gastrointest Endosc*. 2003 Oct; 58(4):608-12.
- de Schipper JP, et al. Spontaneous rupture of the esophagus: Boerhaave's syndrome in 2008: literature review and treatment algorithm. *Dig Surg* 2009;26(1):1–6.
- Ghassemi KF, et al. Endoscopic treatment of Boerhaave syndrome using a removable self-expandable plastic stent. *J Clin Gastroenterol* 2007;41(9):863–864.
- Fischer A, et al. Nonoperative treatment of 15 benign esophageal perforations with self-expandable covered metal stents. *Ann Thorac Surg*. Feb 2006;81(2):467-72.
- Kiev, J et al. A Management Algorithm for Esophageal Perforation. *The American Journal of Surgery*. 194 (2007):103-106.



“The Grand Canyon”
Photography by Niluk Peiris, MD