



Thomas Jefferson University
Jefferson Digital Commons

Department of Obstetrics and Gynecology Faculty
Papers

Department of Obstetrics and Gynecology

2-1-2009

Cryptococcosis of the upper genital tract.

Manish Gopal

Department of Obstetrics and Gynecology, University of Pennsylvania

Stacy McCrosson

Department of Obstetrics and Gynecology, West Jersey Hospital

Pamela Edmonds

Department of Pathology, Abington Hospital

Thomas Klein

Department of Obstetrics and Gynecology, Thomas Jefferson University Hospital, Thomas.Klein@jefferson.edu

[Let us know how access to this document benefits you](#)

Follow this and additional works at: <http://jdc.jefferson.edu/obgynfp>

 Part of the [Obstetrics and Gynecology Commons](#)

Recommended Citation

Gopal, Manish; McCrosson, Stacy; Edmonds, Pamela; and Klein, Thomas, "Cryptococcosis of the upper genital tract." (2009). *Department of Obstetrics and Gynecology Faculty Papers*. Paper 20.
<http://jdc.jefferson.edu/obgynfp/20>

This Article is brought to you for free and open access by the Jefferson Digital Commons. The Jefferson Digital Commons is a service of Thomas Jefferson University's [Center for Teaching and Learning \(CTL\)](#). The Commons is a showcase for Jefferson books and journals, peer-reviewed scholarly publications, unique historical collections from the University archives, and teaching tools. The Jefferson Digital Commons allows researchers and interested readers anywhere in the world to learn about and keep up to date with Jefferson scholarship. This article has been accepted for inclusion in Department of Obstetrics and Gynecology Faculty Papers by an authorized administrator of the Jefferson Digital Commons. For more information, please contact: JeffersonDigitalCommons@jefferson.edu.

Case Report

Cryptococcosis of the Upper Genital Tract

Manish Gopal, M.D.,¹ Stacy McCrosson, M.D.,² Pamela Edmonds,³ and Thomas Klein, M.D.⁴

Abstract

Upper genital tract infection by *Cryptococcus neoformans* has not previously been reported. We describe such a case, in order to alert clinicians to the existence of this rare infection. A 34-year-old woman with AIDS presented with chronic menorrhagia, fever, anemia, and thrombocytopenia. Despite blood transfusions and hormonal therapy, her vaginal bleeding could not be controlled and she became hemodynamically unstable. Total abdominal hysterectomy and bilateral salpingo-oophorectomy were performed, at which time granulomatous peritonitis and prominent myometrial blood vessels were found. Histologic examination revealed cryptococcal infection of all upper genital organs. This case demonstrates that disseminated cryptococcosis may involve the upper genital tract in women, and may be associated with profuse vaginal bleeding.

Introduction

INFECTION OF the upper genital tract with *Cryptococcus neoformans* has not previously been reported in humans. We describe the clinical features of such an infection in a patient with AIDS. Awareness of the existence of this opportunistic infection and its association with abnormal uterine bleeding may permit earlier diagnosis and more successful medical therapy.

Case Report

A 34-year-old woman gravida 3 para 3003 presented to the emergency department following a syncopal episode. She described profuse vaginal bleeding, weakness, and lightheadedness. She gave a history of menorrhagia for several years with anemia recently requiring blood transfusions at another institution, where serologic tests for hepatitis C and HIV were positive. Transabdominal ultrasound was reported as showing "tortuous, ectatic myometrial vessels suggestive of varices." The patient had left the hospital against medical advice. She had been noncompliant with antiretroviral regimens, and had abused alcohol, tobacco, and crack cocaine. She denied any personal or family history of bleeding disorders, but an aunt had undergone hysterectomy because of abnormal bleeding.

On physical examination the oral temperature was 100.8°F, pulse 128 beats per minute and blood pressure 70/44 mm Hg. The lungs were clear to percussion and auscultation. The abdomen was soft and nontender, without masses. On vaginal speculum examination, dark blood was present, but there was no active bleeding. The uterus was slightly enlarged and tender and no adnexal masses were palpable. Chest x-ray showed no pulmonary disease. Initial laboratory data included: serum β hCG negative, hemoglobin 4 g/dL, white blood cell count (WBC) 2200 per microliter, platelets 120,000 per microliter, partial thromboplastin time 35 seconds (normal, 25–37 seconds.), International normalized ratio (INR) 1.22 (normal, 0.91–1.09), total bilirubin 0.7 mg/dL, direct bilirubin 0.4 mg/dL, alkaline phosphatase 60 IU/L, AST (GOT) 27 IU/L, ALT (GPT) 10 IU/L. All liver function test values are within normal limits for our laboratory.

The patient was admitted for observation and transfusion of 6 units of packed red blood cells. Intravenous conjugated estrogens were administered. An endometrial biopsy was nondiagnostic because of insufficient endometrial tissue. The CD4 count was 4 cells per microliter and the viral load was 12,000 HIV-I RNA copies per milliliter. On the second hospital day she remained febrile and began bleeding profusely, with hypotension and tachycardia. Because of her clinical instability, hysterectomy was recommended. After counseling and

¹Department of Obstetrics & Gynecology, University of Pennsylvania, Philadelphia, Pennsylvania.

²Department of Obstetrics & Gynecology, West Jersey Hospital, Voorhees, New Jersey.

³Department of Pathology, Abington Hospital, Abington, Pennsylvania.

⁴Department of Obstetrics & Gynecology, Thomas Jefferson University Hospital, Philadelphia, Pennsylvania.

informed consent, the patient was taken to the operating room.

She was given intravenous fluid resuscitation, further transfusions, and pressors. At laparotomy, ascites was noted, and all pelvic and abdominal serosal surfaces were studded with white milium nodules approximately 1 mm in diameter, suggestive of tuberculosis. A total abdominal hysterectomy and bilateral salpingo-oophorectomy were carried out. The uterus was 10 cm in length, soft, and on cut section revealed numerous large myometrial blood vessels. There was no evidence of a uterine arteriovenous malformation or any other pelvic vascular abnormality. The tubes and ovaries were without gross abnormality except for the serosal lesions. Intraoperatively, her platelet count fell to 50,000 per microliter, her INR rose to 1.36, and her partial thromboplastin time was 40 seconds. The surgery was uncomplicated, without excessive blood loss.

Postoperatively, the patient initially remained febrile. She denied any history of tuberculosis or exposure to tuberculosis, and smears of peritoneal fluid were negative for acid-fast bacilli. However, cytologic examination of peritoneal fluid revealed organisms consistent with yeast, and *Cryptococcus neoformans* was identified in cultures of blood and peritoneal fluid. Intravenous amphotericin B (60 mg/24 hours) was given, as well as trimethoprim-sulfamethoxazole (two double-strength tablets three times daily, 3 days per week) for prophylaxis against *Pneumocystis jiroveci* pneumonia. The final histologic report confirmed cryptococcal infiltration of the cervix, endometrium, myometrium, uterine serosa, tubes, and ovaries (Fig. 1). Confirmed as well was the presence of large tortuous arteries throughout the myometrium. Although the patient responded well to amphotericin B, she experienced fever, chills, and nausea. Therefore, the amphotericin B was discontinued after 48 hours of therapy and replaced with oral fluconazole 400 mg daily. She was eventually discharged, to be followed by gynecology and infectious disease specialists, for future long-term antifungal and antiretroviral therapy. However, the patient did not return

for follow-up visits and her current whereabouts and status are unknown.

Discussion

The patient described here appears to represent the first reported case of *Cryptococcus neoformans* infection involving the uterus, ovaries, and fallopian tubes. Cryptococcosis has been well characterized.¹ It may occur in a disseminated form, or as an isolated infection, involving almost any organ. Cutaneous infection, sometimes resembling molluscum contagiosum, is common, as is meningitis or other central nervous system disease. Cryptococcal peritonitis is often described in patients with hepatic cirrhosis, ventriculo-peritoneal shunts or in those receiving ambulatory peritoneal dialysis.²⁻⁴ Patients with compromised immunity (those with AIDS, malignancy, transplant history, or glucocorticoid therapy) are also at risk, as are those taking tumor necrosis factor (TNF)- α blockers. Furthermore, those with compromised immunity may also present with unusual clinical manifestations and infection with multiple species.^{5,6} Although uterine involvement has been reported with other disseminated mycotic infections, e.g., coccidioidomycosis,⁷ a MEDLINE search using the term "cryptococcosis" combined with "uterus," "endometrium," "salpingitis," and "ovary" yielded no reports since 1966 of upper genital tract cryptococcosis in humans.

Pulmonary cryptococcosis is most common cause of disseminated cryptococcosis. It is believed to result from inhalation of airborne yeast cells and/or basidiospores with subsequent hematogenous spread from the lungs. In our patient, there was no clinical or radiologic evidence of pulmonary disease. This is not an uncommon finding in patients with cryptococcosis. Although a primary pulmonary portal of entry has not been ruled out, we suggest another possible speculative mode of infection: sexual transmission. Cryptococcal prostatitis has been reported⁸ and is a known reservoir of cryptococcosis in males. An ascending infection, especially

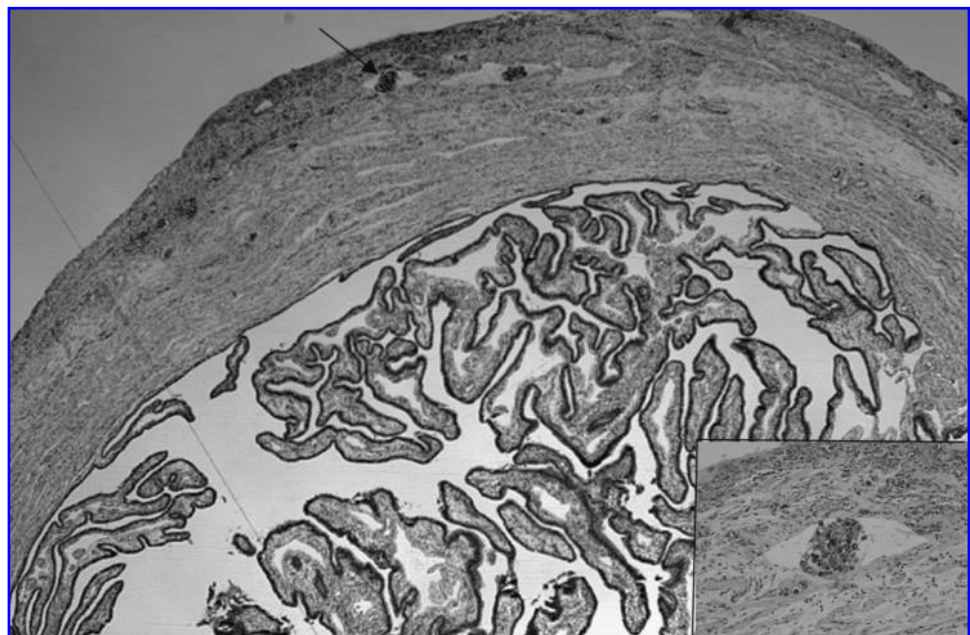


FIG. 1. Fallopian tube, showing encapsulated yeast forms within subserosal lymphatics (arrow and inset). Mucicarmine stain. Magnification for the large figure is 200 \times and the inset is 400 \times .

in an immunocompromised host, could explain this patient's genital tract disease, with subsequent peritonitis and dissemination via the blood stream or lymphatics.

The most prominent symptom in our patient was menorrhagia, which necessitated transfusion and ultimately required hysterectomy. The etiology of the uterine bleeding has not been established, nor is there a clear relationship with cryptococcosis. One might speculate that antifungal therapy could perhaps have ameliorated the bleeding had the correct diagnosis been made earlier in the course of the disease, but insufficient information is available to draw this conclusion. The patient had cryptococcal endometritis, and endometritis is associated with abnormal bleeding, but the bleeding is rarely as heavy as it was here. It is possible that a bleeding diathesis, in combination with endometritis, caused this patient's menorrhagia. Abnormal coagulation has been reported in patients with AIDS⁹ and the patient did have thrombocytopenia; however, her initial platelet count was not in the range associated with profuse bleeding, and there were no other clinical manifestations of a bleeding disorder.

The most striking gross pathologic finding at the time of surgery was the presence of large blood vessels throughout the myometrium. Such prominent vasculature has not been reported, to our knowledge, with other myometrial infections, nor with cryptococcal infiltration of other organs, and there was no clinical or histologic evidence of recent pregnancy. No extrauterine vascular abnormalities were seen. Histologic examination of the hypertrophic vessels did not reveal cryptococcal vascular infiltration. Thus the etiology of this unique finding remains speculative. Even in the absence of a clear etiology, however, it seems logical to relate our patient's myometrial vascular hypertrophy to her intractable bleeding.

This case demonstrates that disseminated cryptococcosis may involve the upper genital tract in women, and may be associated with profuse vaginal bleeding. Prominent myometrial vasculature is an associated finding, whose relationship to the bleeding and to the cryptococcosis remains unknown. Nevertheless, we suggest that clinicians should include cryptococcal disease in the differential diagnosis among immunosuppressed patients presenting with unusual infections or symptoms, including those involving the upper genital tract.

Author Disclosure Statement

No competing financial interests exist.

References

1. Perfect JR, Casadevall A. Cryptococcosis. *Infect Dis Clin North Am* 2002;16:837-874.
2. Park WB, Choe YJ, Lee KD, et al. Spontaneous cryptococcal peritonitis in patients with liver cirrhosis. *Am J Med* 2006;119:169-171.
3. Yinnon AM, Solages A, Treanor JJ. Cryptococcal peritonitis: Report of a case developing during continuous ambulatory peritoneal dialysis and review of the literature. *Clin Infect Dis* 1993;17:736-741.
4. Crum CP, Feldman CS. Cryptococcal peritonitis complicating a ventriculoperitoneal shunt in unsuspected cryptococcal meningitis. *Hum Pathol* 1981;12:660-663.
5. Crum-Cianflone N, Truett A, Wallace MR. Cryptococcal meningitis manifesting as a large abdominal cyst in a HIV-infected patient with a CD4 count greater than 400 cells/mm³. *AIDS Patient Care STDs* 2008;22:359-363.
6. Manfredi R, Fulgaro C, Sabbatani S, Legnani G, Fasulo G. Emergence of amphotericin B-resistant *Cryptococcus laurentii* meningoencephalitis shortly after treatment for *Cryptococcus neoformans* meningitis in a patient with AIDS. *AIDS Patient Care STDs* 2006;20:227-232.
7. DeOtazu RD, Garcia-Nieto L, Izaguirre-Gondra E, et al. Endometrial coccidiosis. *J Clin Pathol* 2004;57:1104-1105.
8. Adams J Jr, Mata JA, Culkin DJ, Fowler M, Venable DD. Acquired immunodeficiency syndrome manifesting as a prostate nodule secondary to cryptococcal infection. *Urology* 1992;39:289-291.
9. Evatt BL. HIV infection and thrombocytopenia. *Curr Hematol Rep* 2005;4:149-153.

Address reprint requests to:
 Manish Gopal, M.D.
 3400 Spruce Street
 5 Penn Tower
 Philadelphia, PA 19104

E-mail: manishgopal@yahoo.com

This article has been cited by:

1. M Patel, K P Beckerman, S Reznik, R P Madan, D L Goldman. 2012. Transplacental transmission of *Cryptococcus neoformans* to an HIV-exposed premature neonate. *Journal of Perinatology* **32**:3, 235-237. [[CrossRef](#)]