

9-1-2011

Scleroderma renal crisis-like acute renal failure associated with mucopolysaccharide accumulation in renal vessels in a patient with scleromyxedema.

Young H Lee
Thomas Jefferson University

Joya Sahu
Thomas Jefferson University, Joya.Sahu@jefferson.edu

Marie S O'Brien
Thomas Jefferson University

Vivette D D'Agati
Thomas Jefferson University

Sergio A. Jimenez
Thomas Jefferson University, Sergio.Jimenez@jefferson.edu

[Let us know how access to this document benefits you](#)

Follow this and additional works at: <http://jdc.jefferson.edu/sclerodermaf>

 Part of the [Medicine and Health Sciences Commons](#)

Recommended Citation

Lee, Young H; Sahu, Joya; O'Brien, Marie S; D'Agati, Vivette D; and Jimenez, Sergio A., "Scleroderma renal crisis-like acute renal failure associated with mucopolysaccharide accumulation in renal vessels in a patient with scleromyxedema." (2011). *Scleroderma Center Faculty Papers*. Paper 5.
<http://jdc.jefferson.edu/sclerodermaf/5>

Scleroderma renal crisis-like acute renal failure in a patient with scleromyxedema.

Young H. Lee, B.A.¹; Joya Sahu, M.D.¹; Marie S. O'Brien, D.O.²; Vivette D. D'Agati, M.D.³; Sergio A. Jimenez, M.D.¹

¹Jefferson Institute of Molecular Medicine and Division of Connective Tissue Diseases,
Department of Dermatology and Cutaneous Biology, Thomas Jefferson University, Philadelphia,
PA

²Department of Arthritis and Rheumatology, Lehigh Valley Physician Group, Allentown, PA

³Department of Pathology, College of Physicians and Surgeons, Columbia University, New
York, NY

Abstract word count: 99

Text word count: 1,988

Figures: 4

Keywords: Scleromyxedema, renal crisis, systemic sclerosis, nephrogenic systemic fibrosis,
acute renal failure.

Conflicts of interest: None.

Address all correspondence to:

Sergio A. Jimenez, MD

233 S 10th St., Suite 509 BLSB

Philadelphia, PA 19107

Phone: 215-503-5042

Fax: 215-923-4649

Email: Sergio.Jimenez@jefferson.edu

Abstract

Scleromyxedema is a systemic disease characterized by lichenoid papules, nodules, and plaques on the skin and often diffuse skin induration resembling the cutaneous involvement of systemic sclerosis. The systemic involvement affects the musculoskeletal, pulmonary, cardiovascular, gastrointestinal, and central nervous systems and the disorder is universally associated with a paraproteinemia. Involvement of the kidney is rare and not considered a feature of the disease. Here, we describe an unusual case of scleromyxedema complicated by the development of scleroderma renal crisis-like acute renal failure caused by a marked intimal deposition of mucin, mucopolysaccharides, and hyaluronic acid in the intrarenal vessels.

Introduction

Scleromyxedema is a rare fibromucinous connective tissue disorder of unknown etiology characterized by the presence of either firm cutaneous lichenoid papules and nodules or diffusely indurated skin, resembling the cutaneous alterations typical of systemic sclerosis (SSc) [1-4]. It is a chronic and progressive disease that besides skin can affect multiple organ systems, including the musculoskeletal, pulmonary, cardiovascular, gastrointestinal, and central nervous systems. Histologically, there is diffuse deposition of mucin in the reticular dermis, an increase in collagen accumulation, and marked proliferation of irregularly arranged fibroblasts [1]. The disease is universally associated with a paraproteinemia, most commonly an IgG-lambda monoclonal gammopathy [1,3]. Associations with other gammopathies such as IgG-kappa, IgM- or IgA-lambda or -kappa, and biclonal IgG- and IgA-lambda have also been reported [2,4]. Despite the association of a monoclonal gammopathy with scleromyxedema, progression to multiple myeloma occurs in only about 10% of cases [1].

Although scleromyxedema is a systemic disease, involvement of the kidney has been reported only rarely and is not generally considered a manifestation of the disease. Here we describe a patient with biopsy-proven scleromyxedema who developed acute renal failure, leading to death. The renal biopsy findings disclosed a remarkable intimal deposition of mucin, mucopolysaccharides and hyaluronic acid causing clinical manifestations which closely resembled those of “scleroderma renal crisis” despite the absence of SSc serologic and clinical features.

Case Report

A 51-year-old female presented in 2003 with progressive skin induration and pruritus. The skin induration initially affected only her hands and face but within the ensuing few months became diffuse, affecting essentially her entire body. Serum protein electrophoresis showed a monoclonal gammopathy of IgG-kappa. Serologic testing on several occasions was negative for ANA, anti-centromere, anti-Scl-70, anti RNA polymerase III, anti-RNP, anti-Sm, anti-SS-A, and anti-SS-B. A skin biopsy showed cutaneous fibrosis, an increase in the number of fibroblasts and remarkable mucin deposition in the deep reticular dermis, confirmed by colloidal iron staining [Figure 1] which are considered diagnostic features of scleromyxedema. Extensive clinical and laboratory studies failed to disclose any evidence indicative of visceral involvement or suggestive of SSc. Specifically, there was no Raynaud’s phenomenon, esophageal dysmotility, pulmonary fibrosis or cardiomyopathy. She was treated with moderate doses of prednisone and IVIG every six to eight weeks, resulting in improvement of symptoms and progressive skin softening. In 2007, she presented with painful red papular lesions, and skin induration of her chest and extremities. The IVIG treatment regimen was increased to every four

weeks, but she developed a pulmonary embolism in the absence of deep vein thrombosis, which was considered to be secondary to serum hyperviscosity caused by the IVIG and this treatment was discontinued.

Three months later, she began to complain of fatigue and muscle weakness. Examination confirmed substantial (grade 3/5) muscle weakness in proximal muscle groups. Subsequent laboratory studies exhibited elevated creatine phosphokinase (CPK, 1032 IU/L; N 8-50 IU/L), aldolase (20.8 U/L; N 0-7 U/L), aspartate aminotransferase (AST, 91 IU/L; N 9-25 IU/L), and alanine aminotransferase (ALT, 137 IU/L; N 7-30 IU/L). Polymyositis was suspected based on her clinical presentation and her elevated CPK, aldolase, AST, and ALT. A repeated CPK showed critically high levels (4488 IU/L), and she was hospitalized and treated with methylprednisolone 1000 mg IV once daily for 3 days. A muscle biopsy of her right thigh was taken several days following the IV pulse-dose of corticosteroids. The histopathologic examination showed an increased variation of muscle fiber diameter with many angular fibers and some markedly atrophic fibers, foci of degenerating and regenerating fibers, and a sparse lymphocytic infiltrate with a more prominent macrophagic infiltrate associated with degenerating fibers, suggestive of a treated inflammatory myopathy. Oral prednisone was administered following the corticosteroid pulse at a dose of 60 mg/day for 2 months followed by slow taper.

In August 2009, she developed intense fatigue, weakness, dyspnea, severe ankle edema and poorly controlled hypertension. xLaboratory tests revealed a serum creatinine of 5.92 mg/dL and blood urea nitrogen 120 mg/dL. Creatine phosphokinase was within the normal range.

She was admitted to a local hospital for nephrologic evaluation of acute renal failure. On admission, she was found to have a creatinine of 6.20 mg/dL and persistent hypertension, peaking at 162 mm Hg (systolic) and 105 mm Hg (diastolic). On exam, she demonstrated

cushingoid facies, a decreased oral aperture and lower extremity edema. A chest x-ray was within normal limits and showed no signs of pulmonary edema or congestive heart failure. An electrocardiogram showed sinus bradycardia with premature atrial contractions and nonspecific repolarization abnormalities. A renal ultrasound revealed mildly echogenic kidneys of normal size consistent with diffuse renal parenchymal disease. A renal biopsy showed multifocal thrombotic microangiopathy of interlobular arteries and arterioles with luminal narrowing by prominent concentric onion-skin intimal thickening with focal superimposed fibrin thrombosis. Immunofluorescence evaluation revealed intimal deposition of IgM, C3, C1, and fibrin/fibrinogen in small and medium-sized arteries, supporting a thrombotic microangiopathy with predominant involvement of the vessels [Figure 2]. The cortex displayed tubular atrophy, interstitial fibrosis, and a mild mononuclear leukocyte interstitial infiltrate. Glomeruli exhibited varying degrees of global ischemic-type retraction and simplification of the tuft with wrinkling and thickening of the glomerular basement membranes [Figure 3]. Alcian blue and colloidal iron stains revealed strong staining in the expanded arterial intimas [Figure 4]. Electron microscopy revealed many glomerular capillaries which were narrowed by widening of the subendothelial zone due to collections of electron lucent flocculent matrix. In many of these areas, there was endothelial swelling and degeneration as well as partial mesangial interposition and duplication of glomerular basement membrane. In several glomeruli, the subendothelial flocculent matrix extended into the mesangium and was associated with mesangiolysis and detachment of mesangial cell processes from the glomerular basement membrane reflection. Some glomerular basement membranes displayed ischemic-type wrinkling and retraction. No typical immune type electron dense deposits or endothelial tubuloreticular inclusions were seen. Foot process effacement involved approximately 50% of the glomerular capillary surface area and there was

moderate tubular atrophy and interstitial fibrosis as well as focal acute tubular injury with loss of brush border, dilatation of endoplasmic reticulum and shedding of cytoplasmic fragments into the tubular lumen. An interlobular artery was nearly occluded by onion-skin mucoid intimal edema.

Treatment with escalating doses of captopril was started at 25 mg three times a day. One week after admission, her blood pressure remained elevated, and her creatinine increased up to 6.80 mg/dL, prompting hemodialysis. Several hours following placement of a hemodialysis catheter in the right internal jugular vein, she experienced a syncopal episode. At this time, her hemoglobin and hematocrit were 8.6 g/dL and 25.7 g/dL, respectively. An abdominal CT scan showed evidence of a diffuse retroperitoneal hemorrhage, and her hemoglobin decreased further to 5.2 g/dL. She was transfused with multiple units of packed red blood cells, and contrast angiographic studies showed an arteriovenous fistula in the right kidney, which was attempted to be sealed by interventional radiology embolization. Continued clinical deterioration led to an emergency exploratory laparotomy. Immediately after surgery, the patient developed severe hypotension and shock leading to death.

Discussion

The patient described herein exhibited symptoms, clinical findings, and laboratory alterations typical of scleromyxedema, including characteristic cutaneous thickening, a monoclonal gammopathy, and a skin biopsy showing abundant mucin deposition, fibroblastic cell proliferation, and dermal fibrosis. She also developed a myopathy with critically high creatine phosphokinase levels. Proximal muscle weakness is found in 27% of scleromyxedema patients and can be associated with elevations in muscle enzymes, and histology usually shows a

nonspecific vacuolar myopathy with little to no muscle fiber necrosis or interstitial inflammatory infiltrate [1]. Several other investigators have also reported myopathy occurring in scleromyxedema [4-9], typically presenting as proximal or generalized weakness and usually appearing following the onset of skin lesions [2]. Histology most commonly shows a vacuolar myopathy [6-7], muscle fibers of variable size [5-6], and atrophy of muscle fibers [5-9]. Interstitial inflammatory infiltrates, a hallmark of polymyositis, are uncommon but usually involve macrophages [5-7], and mucin deposits occur only rarely in the muscle tissue [8-9]. The muscle biopsy in the patient described here revealed findings consistent with a scleromyxedema myopathy, substantiating her diagnosis of scleromyxedema.

Shortly following the diagnosis of inflammatory myopathy, the patient developed a sudden increase in blood pressure with rapidly progressive renal failure. Despite aggressive treatment with ACE-inhibitor therapy and hemodialysis, hypertension and renal failure remained uncontrolled and eventually led to her demise. Although both scleromyxedema and SSc may cause diffuse cutaneous induration as well as involvement of various internal organs overlapping in clinical presentation, renal involvement is common in SSc whereas it is extremely rare in scleromyxedema. Furthermore, the skin biopsy obtained from this patient showed deposition of abundant mucin in the reticular dermis, which is consistent with scleromyxedema. This contrasts with the histologic changes in SSc, which typically include dense fibrosis with minimal deposition of mucin. Other characteristic clinical components of SSc, such as Raynaud phenomenon or gastrointestinal, pulmonary or cardiac involvement were absent, and serologic studies were repeatedly negative for antinuclear antibodies or SSc-specific antibodies, including anti-Scl-70, anti-RNA polymerase III, or anti-centromere antibodies.

Renal disease is a rare manifestation of scleromyxedema largely considered to be incidental [3]; only a few cases have been reported. In 1986, Kantor *et al.* [10] described a patient with scleromyxedema who was hospitalized with severe headaches and uncontrolled hypertension. A kidney biopsy showed concentric lamellar fibrosis of the small arteries with intimal proliferation and mural myxoid degeneration. The patient rapidly developed renal failure, became acutely psychotic, and died. Autopsy results showed concentric lamellar intimal proliferation, with the intimal cells surrounded by a mucoïd extracellular matrix composed of acid mucopolysaccharides. More recently, Gwinner *et al.* [11] reported a case of a female patient with scleromyxedema and normal renal function at diagnosis. Five years later, she was admitted for severe hypertension and acute renal failure requiring hemodialysis. Renal biopsy showed typical characteristics of thrombotic microangiopathy and deposition of mucin in the vessel walls. Peeters *et al.* [12] also described a patient with scleromyxedema that developed renal failure, with renal biopsy showing mucin deposition in the arteriolar walls and ischemic glomerular changes. The patient eventually received a cadaveric renal transplant, which functioned well for 5 years before the development of allograft dysfunction. Renal allograft biopsy disclosed ischemic glomeruli, interstitial fibrosis, and concentric narrowing of arterioles with accumulation of mucopolysaccharides in the arteriolar walls, findings also observed in the subsequent allograft nephrectomy.

The clinical and histopathological findings in our case are similar to those described by Peeters *et al.* [12]. Histopathological findings included global ischemic-type glomerular retractions, some with dissolution of the mesangial matrix, causing confluence of the glomerular capillaries. Multiple small, medium, and large arteries were severely narrowed or focally occluded by concentric onion-skin mucoïntimal edema associated with endothelial swelling and

necrosis. There was similar severe narrowing and focal occlusion of arterioles by concentric intimal sclerosis. Alcian blue and colloidal iron staining showed marked acid mucopolysaccharide and mucin deposits, respectively, in the expanded arterial intimas, causing occlusion of the vessel lumens.

When taken in conjunction with the observations in the three patients described previously in the literature, it appears that the pathologic process affecting the kidneys represents a unique form of subendothelial deposition of mucin and mucopolysaccharides associated with concentric, onion-skin appearing cellular proliferative changes in the vessel wall. Thus, the description of our case provides strong support to the concept that systemic effects of scleromyxedema may extend to the kidneys.

Differential diagnosis of our patient's cutaneous findings and renal failure also includes Nephrogenic Systemic Fibrosis (NSF), a condition characterized by extensive thickening of the skin clinically reminiscent of scleromyxedema [13-15]. Histologic examination with alcian blue and colloidal iron stains in some patients with NSF reveals mucinous deposits between the haphazardly arranged fibrocytes and collagen bundles within the dermis [23-27]. However, the patient described here had no previous exposure to gadolinium. Thus, this case conclusively demonstrates that scleromyxedema can involve intrarenal vessels leading to hypertensive renal crisis and acute renal failure. Renal involvement must be considered a rare but potentially life-threatening complication of scleromyxedema.

References

- [1] Rongioletti F, Rebora A. Updated classification of papular mucinosis, lichen myxedematosus, and scleromyxedema. *J Am Acad Dermatol.* 2001;44:273-281.
- [2] Dinneen AM, Dicken CH. Scleromyxedema. *J Am Acad Dermatol.* 1995;33:37-43.
- [3] Pomann JJ, Rudner EJ. Scleromyxedema revisited. *Int J Dermatol.* 2003;42:31-35.
- [4] Gabriel SE, Perry HO, Oleson GB, et al. Scleromyxedema: a scleroderma-like disorder with systemic manifestations. *Medicine.* 1988;67:58-65.
- [5] Harvey JM, Zilko PJ, Cheah PS, et al. Scleromyxedema and inflammatory myopathy: a clinicopathologic study of three patients. *Aust N Z J Med.* 1986;16:329-335.
- [6] Fudman EJ, Golbus J, Ike RW. Scleromyxedema with systemic involvement mimics rheumatic diseases. *Arthritis Rheum.* 1986;29:913-917.
- [7] Helfrich DJ, Walker ER, Martinez AJ, et al. Scleromyxedema myopathy: case report and review of the literature. *Arthritis Rheum.* 1988;31:1437-1441.
- [8] Rothe MJ, Rivas R, Gould E, et al. Scleromyxedema and severe myositis. *Int J Dermatol.* 1989;28:657-660.
- [9] Wu MY, Hong JB, Yang CC, et al. Scleromyxedema with myopathy was successfully treated by thalidomide. *J Eur Acad Dermatol Venereol.* 2009;23:189-190.
- [10] Kantor GR, Bergfeld WF, Katzin WE, et al. Scleromyxedema associated with scleroderma renal disease and acute psychosis. *J Am Acad Dermatol.* 1986;14:879-888.
- [11] Gwinner W, Erdbruegger U, Mengel M, et al. Scleroderma-like acute renal crisis in a patient with scleromyxedema. *Nephrol Dial Transplant.* 2007;22:2063-2067.
- [12] Peeters P, Praet M, Van Vlem B, et al. End-stage disease of native kidneys in a patient with biopsy-proven Arndt-Gottron scleromyxoedema and recurrence in the transplanted kidney. *Nephrol Dial Transplant.* 2007;22:3065-3069.
- [13] Cowper SE, Robin HS, Steinberg SM, et al. Scleromyxoedema-like cutaneous diseases in renal-dialysis patients. *Lancet.* 2000;356:1000-1001.
- [14] Cowper SE, Su LD, Bhawan J, et al. Nephrogenic fibrosing dermopathy. *Am J Dermatopathol.* 2001;23:383-393.
- [15] Mendoza FA, Artlett CM, Sandorfi N, et al. Description of 12 cases of nephrogenic fibrosing dermopathy and review of the literature. *Semin Arthritis Rheum.* 2006;35:238-249.

Acknowledgements

The authors gratefully acknowledge the assistance of M. Marcucci in the preparation of the manuscript. Dr. S.A. Jimenez is supported by NIH Grant 5R01 AR019161.

Figure Legends

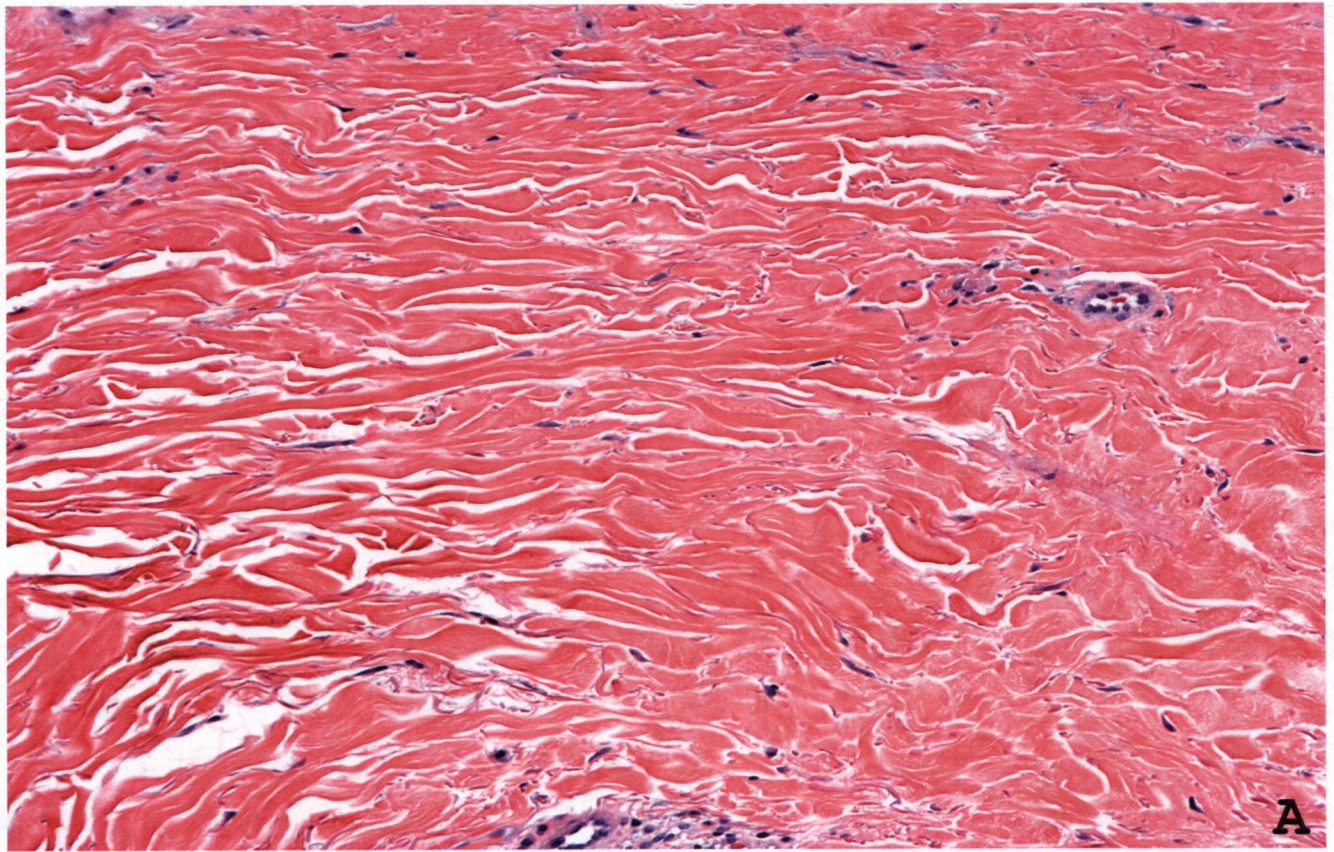
Figure 1. Skin biopsy. A. Hematoxylin and Eosin stain. Abundant thickened collagen fibers with numerous elongated fibrocytes splayed interstitially between thickened bundles of collagen (x200). B. Colloidal iron stain showing abundant mucin present between undulating and markedly thickened bundles of collagen (x400).

Figure 2. Renal biopsy. A, Hematoxylin and Eosin stain showing evidence of arterial thrombotic microangiopathy with luminal narrowing by concentric onion-skin intimal thickening and superimposed fibrin thrombosis (x400). B, Immunofluorescence stain for fibrin, demonstrating occlusion of arterial lumens by intraluminal and intimal fibrin (x500).

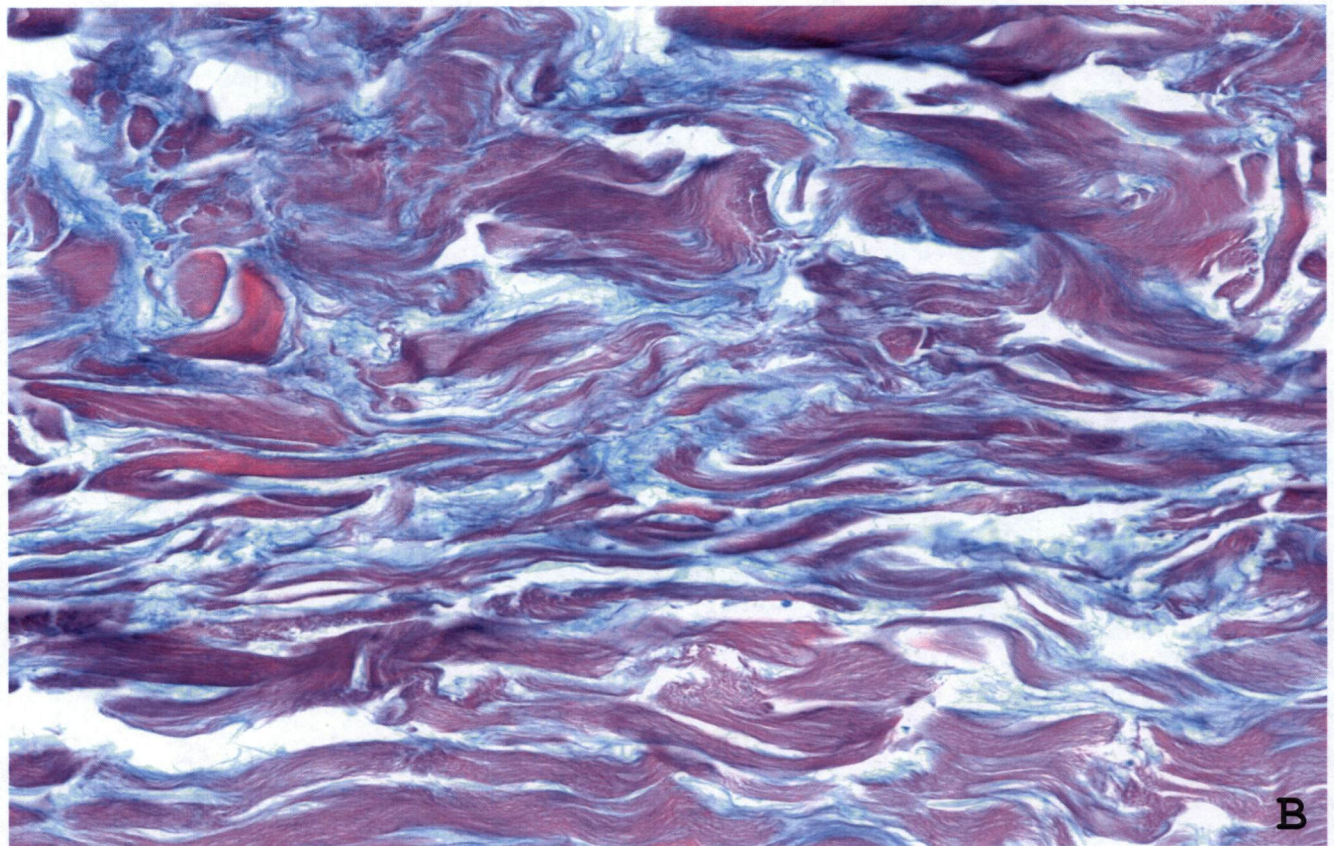
Figure 3. Renal biopsy. A, Hematoxylin and Eosin stain showing reduplication of the elastic layer of an artery and marked concentric myointimal proliferation (x400). B, Jones methenamine silver (JMS) stain showing a glomerulus with global ischemic-type retraction (x400). C, Periodic acid-schiff (PAS) stain showing acute ischemic tubular injury with intact tubular basement membranes (x400).

Figure 4. Renal biopsy. A, Low-powered alcian blue stain pH 2.5 (x200), and B, high-powered alcian blue stain (x400), showing accumulation of acid mucopolysaccharides in the thickened intima of interlobular arteries. C, Low-powered colloidal iron stain (x200), and D, high-powered colloidal iron stain (x400), showing mucin deposition in the expanded arterial intimal layer, severely narrowing the vessel lumens.

Figure 1



A



B

Figure 2

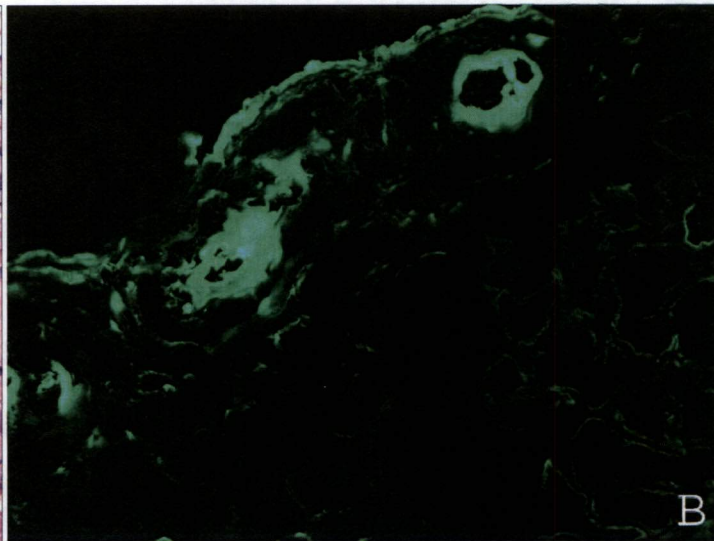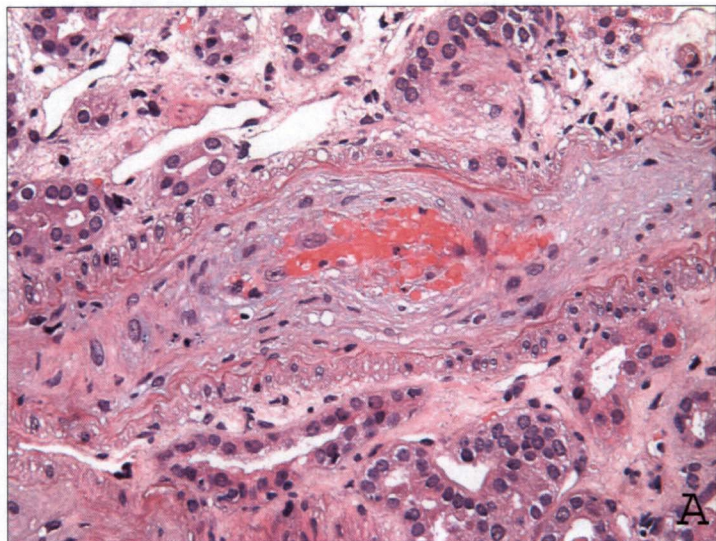


Figure 3

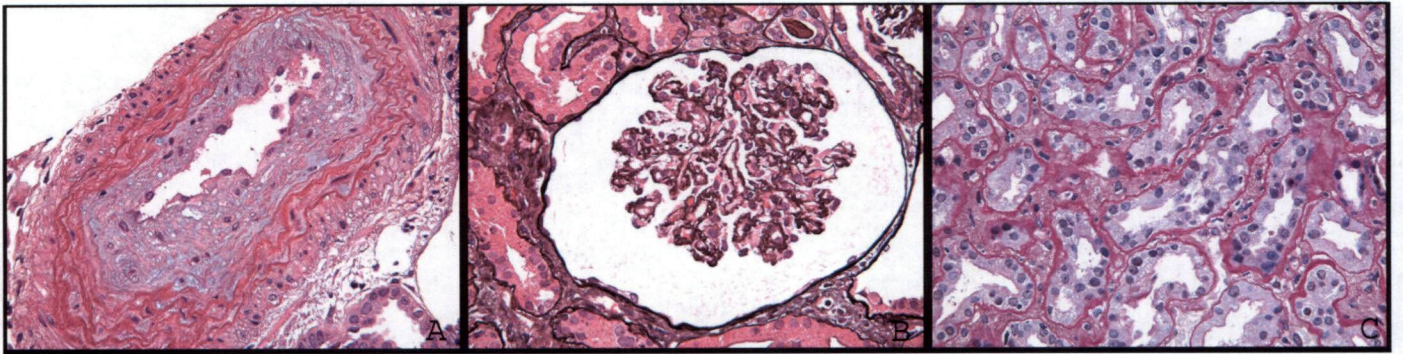

Figure 4

