



Thomas Jefferson University  
Jefferson Digital Commons

Department of Urology Faculty Papers

Department of Urology

4-1-2008

## Robotic dismembered pyeloplasty in a horseshoe kidney after failed endopyelotomy.

Mark L. Pe

*Thomas Jefferson University*

Steven N. Sterious

*Thomas Jefferson University*

Ji-Bin Liu

*Thomas Jefferson University*

Costas D. Lallas

*Thomas Jefferson University, [costas.lallas@jefferson.edu](mailto:costas.lallas@jefferson.edu)*

### [Let us know how access to this document benefits you](#)

Follow this and additional works at: <http://jdc.jefferson.edu/urologyfp>

 Part of the [Urology Commons](#)

#### Recommended Citation

Pe, Mark L.; Sterious, Steven N.; Liu, Ji-Bin; and Lallas, Costas D., "Robotic dismembered pyeloplasty in a horseshoe kidney after failed endopyelotomy." (2008). *Department of Urology Faculty Papers*. Paper 4.

<http://jdc.jefferson.edu/urologyfp/4>

This Article is brought to you for free and open access by the Jefferson Digital Commons. The Jefferson Digital Commons is a service of Thomas Jefferson University's [Center for Teaching and Learning \(CTL\)](#). The Commons is a showcase for Jefferson books and journals, peer-reviewed scholarly publications, unique historical collections from the University archives, and teaching tools. The Jefferson Digital Commons allows researchers and interested readers anywhere in the world to learn about and keep up to date with Jefferson scholarship. This article has been accepted for inclusion in Department of Urology Faculty Papers by an authorized administrator of the Jefferson Digital Commons. For more information, please contact: [JeffersonDigitalCommons@jefferson.edu](mailto:JeffersonDigitalCommons@jefferson.edu).

# Robotic Dismembered Pyeloplasty in a Horseshoe Kidney After Failed Endopyelotomy

Mark L. Pe, MD, Steven N. Sterious, Ji-Bin Liu, MD, Costas D. Lallas, MD

## ABSTRACT

We report our experience performing a robot-assisted dismembered pyeloplasty on a patient with a ureteropelvic junction obstruction in a horseshoe kidney and a prior history of endopyelotomy. We provide 18-month follow-up demonstrating that robotic pyeloplasty is a reasonable second treatment option for patients with horseshoe kidneys with failed prior endourological management.

**Key Words:** Ureteropelvic junction obstruction, Horseshoe kidney, Endopyelotomy, Robotics, Minimally invasive, Congenital anomalies.

## INTRODUCTION

Horseshoe kidneys are the most common renal fusion anomalies, occurring in approximately 1/400 births to 1/1000 births. It is estimated that ureteropelvic junction obstruction (UPJO) is seen in 15% to 33% of patients in this population.<sup>1</sup> Despite the presence of aberrant anatomy, both open and laparoscopic dismembered pyeloplasty have been reported to be performed successfully with good functional results.<sup>2,3</sup> In addition, endopyelotomy has been shown to be a viable treatment option as well.<sup>1</sup> Robotic surgery has gained increasing popularity and acceptance in urologic practice, providing improved operative performance and simplified suturing. Robotic pyeloplasty has been reported to be a feasible primary treatment option in patients with UPJO of a horseshoe kidney; however, data are limited.<sup>4</sup> To our knowledge, robotic pyeloplasty after failed primary repair has not been reported. We demonstrate that robotic pyeloplasty is a reasonable treatment modality for patients with horseshoe kidneys after prior unsuccessful endourological intervention.

## CASE REPORT

An 81-year-old female was admitted for acute pyelonephritis. Workup revealed a horseshoe kidney with UPJO and hydronephrosis of the left moiety. The patient was initially taken to the operating room, where her left UPJ was evaluated with endoluminal ultrasound. Multiple crossing vessels were visualized (**Figure 1**). Holmium laser endopyelotomy was performed in an area of avascularity. The patient tolerated the procedure well and was discharged that day with an indwelling ureteral stent, which was removed after 8 weeks.

Imaging after 3 months revealed marked dilation of the left renal pelvis. A Lasix nuclear renal scan was obtained showing obstruction of the left renal moiety with no excretion of contrast, consistent with reobstruction of her left UPJ. Differential renal function was 71% on the right and 29% on the left. Treatment options were discussed with the patient, and she elected to undergo a robotic pyeloplasty.

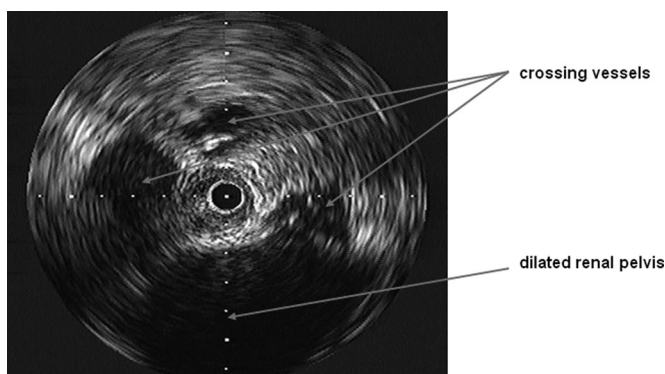
Robotic dismembered pyeloplasty was subsequently per-

Department of Urology, Thomas Jefferson University, Philadelphia, PA, USA (Drs Pe, Lallas, Mr Sterious).

Department of Radiology, Thomas Jefferson University, Philadelphia, PA, USA (Dr Liu).

Address reprint requests to: Costas D. Lallas, MD, Department of Urology, Thomas Jefferson University, 1025 Walnut St, Ste 1112 College Building, Philadelphia, PA 19107, USA. Telephone: 215 955 6961, Fax: 215 923 1884, E-mail: costas.lallas@jefferson.edu

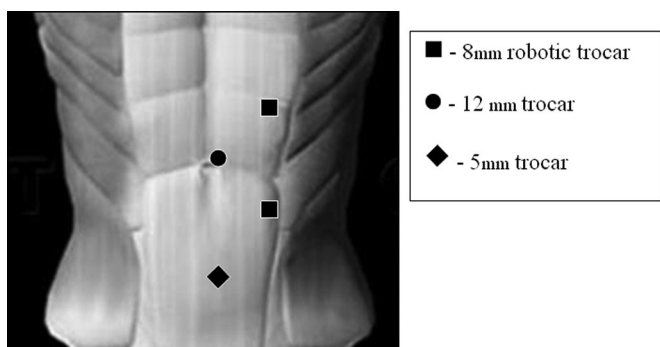
© 2008 by JSLS, *Journal of the Society of Laparoendoscopic Surgeons*. Published by the Society of Laparoendoscopic Surgeons, Inc.



**Figure 1.** Intraoperative endoluminal ultrasound illustrating crossing vessels across the left ureteropelvic junction and dilated renal pelvis.

formed. The procedure was transperitoneal and used our 4-port robotic template (**Figure 2**). Anteriorly crossing vessels were visualized and left intact. The left ureter was dissected up to the level of the endopyelotomy scar, which was surrounded by aberrant vasculature. Dismemberment was performed at this level, and the renal pelvotomy was made at the most dependent portion of the renal pelvis. A double pigtail ureteral stent was advanced to the level of the renal pelvis, and reanastomosis of the UPJ was performed using 4–0 vicryl suture on an R-B needle in an interrupted fashion. Tisseal sealant was placed over the completed anastomosis. A flank drain and Foley catheter were placed. Operative time was 210 minutes, and the estimated blood loss was 25 mL. The catheter was removed on postoperative day number one. There was no subsequent increase in output noticed from the drain, and it was removed prior to patient discharge on postoperative day number 2. The ureteral stent was removed after 6 weeks.

The patient's postoperative course and follow-up have



**Figure 2.** Port placement in left robot-assisted laparoscopic pyeloplasty.

been uneventful. A repeat Lasix nuclear renal scan at 1-year follow-up showed no obstruction of the left moiety, with improved differential function (62% right, 38% left) compared with her preoperative study. Another follow-up renal scan at 18 months showed no deterioration in renal function.

## DISCUSSION

The management of UPJO in patients with horseshoe kidneys follows similar principles for treatment of patients with normal anatomical kidneys. Endopyelotomy has been reported by many groups as a successful treatment option.<sup>1</sup> In addition, both open and laparoscopic dismembered pyeloplasty have been shown to be established treatment modalities as well.<sup>1–3</sup> With the advances in minimally invasive surgery, a laparoscopic approach to performing dismembered pyeloplasty is becoming the treatment of choice for management of UPJO.<sup>5</sup>

Reports describing the efficacy, feasibility, and successful short-term outcomes of robotic pyeloplasty have established the procedure as an emerging therapeutic approach to the patient with UPJO.<sup>6</sup> Recently, Schwentner et al<sup>7</sup> reported a relatively short learning curve for the surgeon and staff regarding robotic pyeloplasty and demonstrated long-term success rates comparable to those of traditional open pyeloplasty. However, data are limited regarding this treatment option applied to patients who have UPJO of a horseshoe kidney.<sup>4,7</sup> In addition, to our knowledge, there are no reports regarding robotic pyeloplasty as a secondary treatment modality after failed primary endourological treatment. Pyeloplasty is an accepted, if not preferred, method to treat failed endopyelotomy. In this particular case, our patient had an initial laser endopyelotomy that reobstructed after 3 months, requiring a more definitive robotic pyeloplasty. Operative time, estimated blood loss, and length of hospital stay were similar when compared with our own institutional experience of over 50 robotic pyeloplasties in patients with normal anatomical kidneys. Follow-up at 18 months with serial nuclear medicine renal scans showed persistent improvement in renal function compared with preoperative status. Strict long-term follow-up is recommended; through our institutional treatment experience of over 200 patients for UPJO with over 5 years of follow-up data, we have found that late failures and recurrences do occur in a small yet significant percentage of cases.

With the emergence of robotic surgery in urologic practice, urologists have expanded their repertoire to include increasingly challenging pelvic and retroperitoneal proce-

dures. We have shown that robotic pyeloplasty in a horseshoe kidney after failed endopyelotomy is a feasible and successful procedure. The inherent advantages of the da Vinci robot allowed us to tackle a technically demanding case where meticulous dissection through dense scar was needed. In addition, exploration through aberrant anatomy as well as precise suturing and reconstruction were simplified. When encountering unique and potentially challenging cases, such as the one illustrated, one should consider using the da Vinci robot as a viable treatment modality.

## CONCLUSION

Robot-assisted laparoscopic pyeloplasty is a reasonable second treatment option after failed primary endopyelotomy in the management of UPJO in horseshoe kidneys.

## References:

1. Yohannes P, Smith AD. The endourological management of complications associated with horseshoe kidney. *J Urol.* 2002; [168:5–8.](#)
2. Pitts WR Jr., Muecke EC. Horseshoe kidneys: a 40-year experience. *J Urol.* 1975; [113:743–746.](#)
3. Bove P, Ong AM, Rha K-H, et al. Laparoscopic management of ureteropelvic junction obstruction in patients with upper urinary tract anomalies. *J Urol.* 2004; [171:77–79.](#)
4. Chammas M Jr., Feuillu B, Coissard A, et al. Laparoscopic robotic-assisted management of pelvi-ureteric junction obstruction in patients with horseshoe kidneys: technique and 1-year follow-up. *BJU Int.* 2006; [97:579–583.](#)
5. Eden CG. Minimally invasive treatment of ureteropelvic junction obstruction: A critical analysis of results. *Eur Urol.* 2007; [52:983–989.](#)
6. Patel V. Robotic-assisted laparoscopic dismembered pyeloplasty. *Urology.* 2005; [66:45–49.](#)
7. Schwentner C, Pelzer A, Neuruer R, et al. Robotic Anderson-Hynes pyeloplasty: 5-year experience of one centre. *BJU Int.* 2007; [100:880–885.](#)