

November 2009

The Region of the Arm

Let us know how access to this document benefits you

Follow this and additional works at: http://jdc.jefferson.edu/regional_anatomy



Part of the [History of Science, Technology, and Medicine Commons](#)

Recommended Citation

"The Region of the Arm" (2009). *Regional anatomy McClellan, George 1896 Vol. 1*. Paper 16.
http://jdc.jefferson.edu/regional_anatomy/16

This Article is brought to you for free and open access by the Jefferson Digital Commons. The Jefferson Digital Commons is a service of Thomas Jefferson University's [Center for Teaching and Learning \(CTL\)](#). The Commons is a showcase for Jefferson books and journals, peer-reviewed scholarly publications, unique historical collections from the University archives, and teaching tools. The Jefferson Digital Commons allows researchers and interested readers anywhere in the world to learn about and keep up to date with Jefferson scholarship. This article has been accepted for inclusion in *Regional anatomy McClellan, George 1896 Vol. 1* by an authorized administrator of the Jefferson Digital Commons. For more information, please contact: JeffersonDigitalCommons@jefferson.edu.

during an operation would be countenanced by one whose scalpel had ever unravelled the intricacies of these parts in his student days.

THE REGION OF THE ARM.

The arm extends from the axilla to the elbow. It has already been stated (page 332) that the shape of the shaft of the humerus above the deltoid insertion is cylindrical; below it is prismatic and slopes gradually downward and slightly forward to the lower end, where it becomes transversely flattened (Plate 28). The central portion of the lower end of the humerus is peculiarly formed for articulation with the ulna. It is called the *trochlea*, and consists of a smooth, rounded, condyloid surface, which is constricted at the middle so that the inner portion is somewhat larger and projects lower than the outer. Above the constriction anteriorly there is a depression for the reception of the coronoid process of the ulna when the forearm is flexed, called the *coronoid fossa*. Posteriorly there is a similar but larger depression, the *olecranon fossa*, for the olecranon process of the ulna when the forearm is extended. The portion of bone between these fossæ is exceedingly thin and translucent, and sometimes perforated, forming the *supra-trochlear foramen*. Jutting out from the internal portion of the trochlear surface is a prominent process, the *internal epicondyle*, and to the periosteum over this process the flexor muscles of the wrist and hand are attached. The internal epicondyle looks directly inward when the arm hangs naturally at the side, and occupies a lower plane than the *external epicondyle*, which is the corresponding process upon the outer portion of the trochlear surface. The latter is rough and comparatively short, and gives attachment to the origins of some of the extensor muscles. Upon the outer surface of the trochlea is a small spheroidal forward projection, called the *capitulum*, upon which the cup-shaped depression on the head of the radius rests and glides within the elbow-joint. The outer and inner borders are directly continuous with the epicondyles, and are known as the *external* and *internal supra-condyloid ridges*. Upon the posterior surface of the *internal epicondyle* there is a slight *groove for the ulnar nerve*. The epicondyles are the only parts of the humerus which are subcuta-

neous, and, although the shaft of the humerus can be felt through the soft structures, there are no other bony prominences, and therefore the *surface-marking*, which is due to the contour of the various muscles, is of particular interest in relation to the subjacent parts. This is more pronounced in well-developed muscular men than among women whose arms are rounded and of regular outline. Fat, here, as in other parts of the body, always subdues the depressions and renders them less discernible.

The *skin* on the front and inner surface of the arm is especially smooth, free from hairs, delicate, and extremely sensitive, while on the back and outer surface it is somewhat thicker and less sensitive. The skin is also loosely attached to the deeper parts by the *subcutaneous fascia*. This is often manifest in cellulitis, and in amputation through this part of the upper extremity the laxity of the integument allows it to be drawn away from the muscles with very little effort. For this reason the method of applying the knife *from without inward* in amputation through the arm is suggested to those who may be called upon to do this operation without much practical experience, as it secures *flaps with bevelled edges* (Plate 51, Fig. 1).

The triangular depression caused by the insertion of the deltoid muscle (page 335) can generally be recognized upon the surface with ease, and, as it indicates the precise mid-point of the shaft of the humerus, it is an important landmark. Exactly opposite to it, upon the inside of the arm, is the insertion of the coraco-brachialis muscle. The bulge of the biceps muscle causes its outline to be usually well defined in the front of the arm, so that there are furrows or depressions upon each side of it. The *outer bicipital depression* extends from the bend of the elbow to the insertion of the deltoid, and corresponds to the position thus far of the *cephalic vein* (Plate 45, Fig. 1, No. 29), which ascends above this in the groove between the deltoid and pectoralis major muscles and empties into the axillary vein. It is accompanied by the descending branch of the acromio-thoracic artery and the upper external cutaneous nerve. Sometimes there is a connecting vein between the cephalic vein and the external jugular or the subclavian, which passes over the clavicle, and, being subcutaneous, is readily seen during life. The *inner bicipital depression* is more notice-

PLATE 47.

Figure 1.

The radial border of the forearm and elbow, showing the relations of the superficial veins—the superficial fascia being carefully removed—to the muscles and tendons.

- | | |
|-----------------------------------------------------------------------------------------------------------------------------------------------------------------------------------------------------------------------------------------------------------------------------------------------------------------------------------------------------------------------------------------------------------------------------------------------------------------------------------------------------------|-----------------------------------------------------------------------------------------------------------------------------------------------------------------------------------------------------------------------------------------------------------------------------------------------------------------------------------------------------------------------------------------------------------------------------------------------------------------------------------------------------------------------------------------------------------------------------------------------------|
| <ol style="list-style-type: none">1. The biceps muscle.2. The external cephalic vein, a direct continuation of the radial vein.3. Branches of the musculo-cutaneous nerve.4. The musculo-spiral nerve.5. The tendon of the extensor communis digitorum muscle.6. The tendon of the extensor secundi internodii pollicis muscle.7. The posterior annular ligament.8. The external brachial vein.9. The median nerve. | <ol style="list-style-type: none">10. The basilic vein.11. The bicipital fascia.12. The median vein.13. Branches of the musculo-spiral nerve.14. The tendon of the flexor carpi radialis muscle.15. The tendon of the supinator longus muscle.16. The radial nerve passing round to the back of the wrist.17. The tendon of the extensor ossis metacarpi pollicis muscle.18. The tendon of the extensor primi internodii pollicis muscle.19. The radial artery, seen through the deep carpal fascia. |
|-----------------------------------------------------------------------------------------------------------------------------------------------------------------------------------------------------------------------------------------------------------------------------------------------------------------------------------------------------------------------------------------------------------------------------------------------------------------------------------------------------------|-----------------------------------------------------------------------------------------------------------------------------------------------------------------------------------------------------------------------------------------------------------------------------------------------------------------------------------------------------------------------------------------------------------------------------------------------------------------------------------------------------------------------------------------------------------------------------------------------------|

Figure 2.

The anterior view of the left elbow to show particularly the bicipital fascia in relation to the superficial veins and the deep vessels and nerves.

- | | |
|----------------------------------------------------------------------------------------------------------------------------------------------------------------------------------------------------------------------------------------------------------------------------------------------------------------------------------------------------------------------------------------------------------------------------------------|------------------------------------------------------------------------------------------------------------------------------------------------------------------------------------------------------------------------------------------------------------------------------------------------------------------------------------------------------------------------------------------------------------------------|
| <ol style="list-style-type: none">1. The brachial artery.2. The basilic vein.3. The anastomotica magna artery.4. The ulnar nerves.5. The internal cutaneous nerve.6. The branches of the ulnar and internal cutaneous nerves around the internal condyle of the humerus.7. The ulnar vein.8. The branches of the internal cutaneous nerve in the forearm. | <ol style="list-style-type: none">9. The biceps muscle.10. The median nerve.11. The brachial vein.12. The median basilic vein.13. The brachial artery at the bend of the elbow.14. The tendon of the biceps muscle.15. The median cephalic vein.16. The vena anastomotica.17. The bicipital fascia.18. The median vein. |
|----------------------------------------------------------------------------------------------------------------------------------------------------------------------------------------------------------------------------------------------------------------------------------------------------------------------------------------------------------------------------------------------------------------------------------------|------------------------------------------------------------------------------------------------------------------------------------------------------------------------------------------------------------------------------------------------------------------------------------------------------------------------------------------------------------------------------------------------------------------------|

Figure 3.

Dissection of the veins on the back of the hand and forearm, with their relations to the underlying tendons and nerves.

- | | |
|---------------------------------------------------------------------------------------------------------------------------------------------------------------------------------------------------------------------------------------------------|-------------------------------------------------------------------------------------------------------------------------------------------------------------------------------------------------------------------------|
| <ol style="list-style-type: none">1. The posterior ulnar vein.2. The common ulnar vein.3. The posterior annular ligament.4. The carpal branch of the ulnar nerve.5. The <i>vena salvatella</i>. | <ol style="list-style-type: none">6. The posterior radial vein.7. The radial vein.8. The radial nerve.9. The radial artery.10. One of the dorsal interossei arteries. |
|---------------------------------------------------------------------------------------------------------------------------------------------------------------------------------------------------------------------------------------------------|-------------------------------------------------------------------------------------------------------------------------------------------------------------------------------------------------------------------------|

Fig 1

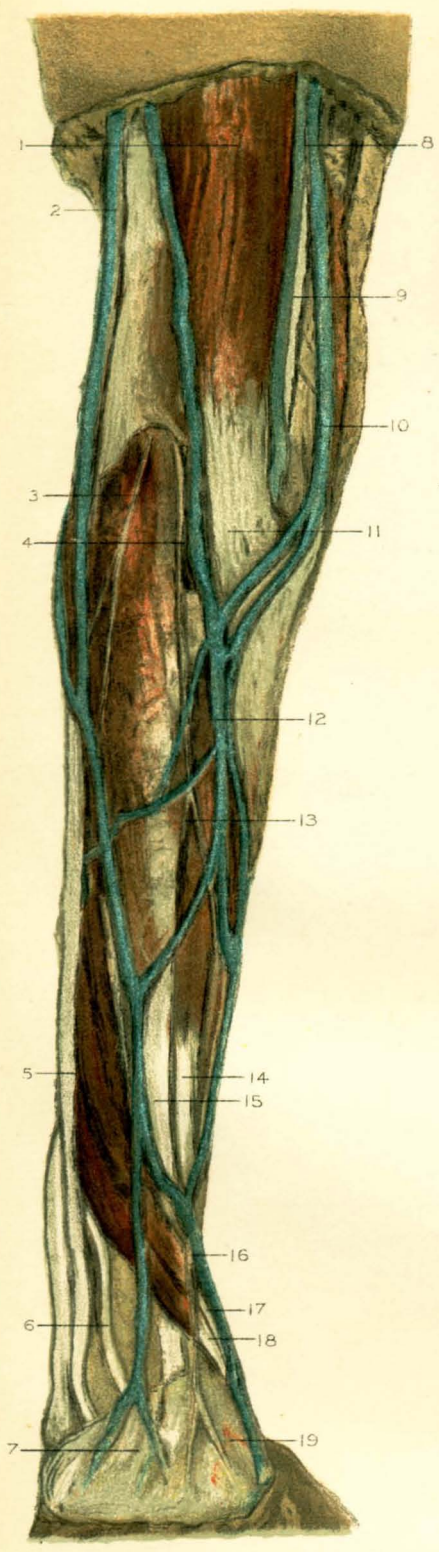


Fig 2

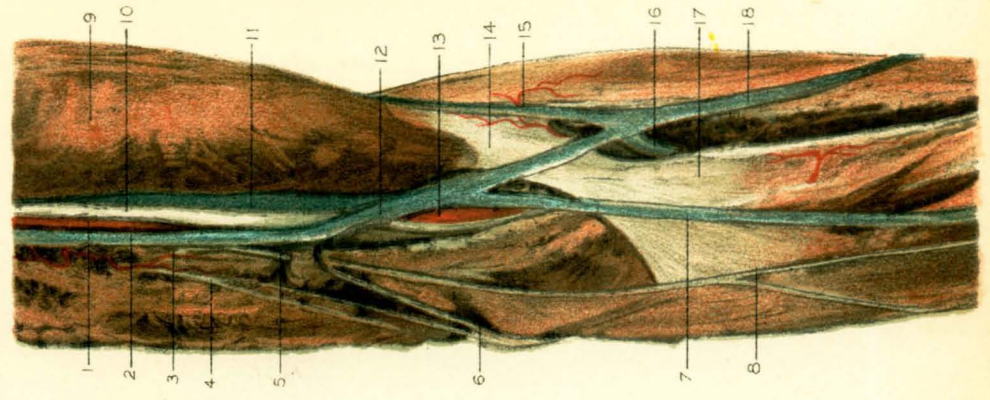
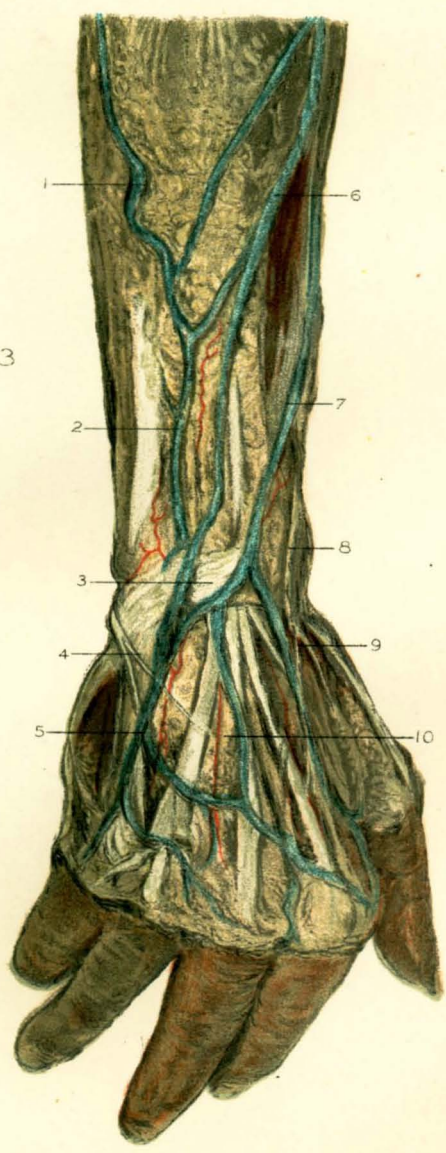



Fig 3





able than the outer; it extends from the middle of the bend of the elbow all the way to the axilla, and indicates the course of the brachial artery and its companion veins and nerves.

The *deep fascia of the arm* is a continuation from the fascia of the shoulder and axilla. It forms a close-fitting investment for all the muscles in this region, and sends into each condyloid ridge of the humerus strong septa which divide the muscles in front from those behind. In certain localities it expands so as to form protected passage-ways for important vessels and nerves, as over the *musculo-spiral groove* on the posterior surface of the humerus for the nerve of that name and the superior profunda artery which accompanies it, and on the border of the humerus above the internal condyle, where it sometimes forms a dense band across the median nerve. Here its attachment to the humerus is occasionally ossified, presenting a hook-shaped process of bone, which is then called the *supra-condyloid process*. The deep fascia is also pierced here and there by the nerves which pass down to be distributed to the forearm, and at the middle of the internal bicipital depression there is an oval opening, the *hiatus semilunaris*, for the basilic vein.

There is marked variability in the density of the deep fascia in its different relations. Thus, over the biceps it is quite thin, but upon the inside of the arm, where it passes between the biceps and the brachialis anticus, it is very strong, forming a dense sheath for the brachial vessels and nerves and binding them upon the surface of the latter muscle. At the back of the arm the fascia constitutes a strong envelope over the biceps muscle, and in front, as it approaches the elbow in relation to the tendon of the biceps, it is also remarkably strong.

The *biceps muscle* is so called because it has a double origin. The *long head* arises by a long round tendon from the top of the glenoid cavity and the glenoid ligament, and, arching over the head of the humerus within the capsule of the shoulder-joint, pierces the latter between the two tuberosities and descends in the bicipital groove between them, covered with a reflection of the synovial membrane of the joint (page 334), which serves to lubricate it and facilitate its movements. It is held in place by the tendon of the pectoralis major muscle, which passes over it to be

inserted into the outer ridge of the groove, being also connected to the latter muscle by its sheath. The *short head* arises by fleshy and tendinous fibres from the point of the coracoid process together with the coraco-brachialis muscle (Plate 44, Fig. 2, No. 23). About the middle of the arm the two heads unite and form a single mass of muscle, which is subject to great variation in development in different individuals, and terminates suddenly in a strong flat tendon. This tendon is of considerable length, is subcutaneous, and can be readily felt upon contraction of the muscle. It *twists* somewhat upon itself and sinks into the ante-cubital fossa to be inserted into the lower and posterior part of the bicipital tubercle of the radius, a bursa being interposed between the tendon and the front of the tubercle. Before the tendon enters the fossa it gives off from its inner border a *semilunar fold of fascia* which protects the brachial vessels and the median nerve at the bend of the elbow (Plates 46 and 47).

The *action* of the biceps muscle is to both *flex* and *supinate* the forearm. The function of supination ensues upon the manner of its insertion into the *posterior* part of the tubercle of the radius, and is most effectually accomplished when the elbow is bent, because the tendon then passes at a right angle to its insertion. The peculiar *ligamentous* function of the long tendon at the shoulder-joint has already been described (page 333). The biceps receives two branches from the brachial artery. One of these is called the *vas aberrans* (page 355). It enters about the middle of the muscle, and divides within its substance into ascending and descending branches. Each head of the muscle receives a branch from the musculocutaneous nerve (page 362).

The *coraco-brachialis* (Plate 44, Fig. 2, No. 7, and Plate 45, Fig. 2, No. 29) is a slender muscle on the inner side of the short head of the biceps, in common with which it arises by fleshy fibres from the coracoid process of the scapula. It is inserted by a flat tendon at the middle of the inner surface of the shaft of the humerus, just above the foramen for the nutrient artery to that bone. This muscle is pierced by the musculocutaneous nerve in its upper portion (Plate 45, Fig. 2, No. 27), which also supplies it. Its action is to draw the arm forward and inward upon the

side of the chest. Not only is the upper portion of this muscle the guide to the axillary artery (page 343), but, as the brachial artery is in relation to its *flat* tendon of insertion, it can here be effectually compressed if the pressure is directed outward. This is the usual site for the application of a tourniquet; but it should always be remembered that the close relation of the median nerve (page 357) renders it liable to be included in the pressure and therefore to cause great pain. There is a bursa interposed between the tendons of the coraco-brachialis and the short head of the biceps and the tendon of the subscapularis muscle over the head of the humerus.

The *brachialis anticus muscle* arises by two fleshy portions, one upon each side of the insertion of the deltoid, and from the lower part of the front surface of the humerus, which it covers. Its inner border is also connected with the septum from the deep fascia which separates it from the triceps posteriorly. Its fibres are arranged in nearly parallel bundles, so that they form a broad thick mass superposed upon the capsule of the elbow-joint, to which it is slightly attached. Its tendon is flat, and upon the outer border extends into the substance of the muscle. It is chiefly inserted into the coronoid process of the ulna, and reflected upon a ridge from this process to the tuberosity of the ulna. It forms a pad to the elbow, upon which the brachial vessels and the median and musculo-cutaneous nerves are supported internally, as they pass across the joint under protection of the expansion from the tendon of the biceps muscle. Externally the brachialis anticus is quite superficial, and separated from the supinator longus muscle by a furrow in which is lodged the musculo-spiral nerve (Plate 47, Fig. 1, No. 4), from which it receives a small branch, although its main nerve-supply is from the musculo-cutaneous nerve upon its inner side. Its *action* is to flex the elbow.

The *triceps extensor cubiti* is so called from its triple origin and its peculiar function of being the sole extensor muscle of the forearm. It is situated at the back of the arm. The *long* or *middle head* arises by a strong thick tendon from the infra-glenoid depression and the lower portion of the glenoid ligament. It is closely connected with the capsule of the shoulder-joint. As it passes between the tendons of the teres

minor and major muscles (page 329) it becomes more fleshy. The *outer head* begins immediately below the attachment of the teres minor muscle, and is itself attached all the way to the musculo-spiral groove and to the reflection of the deep fascia. The *inner head* arises close to the insertion of the teres major muscle, and from the posterior surface of the humerus below the musculo-spiral groove nearly as far as the internal epicondyle. Its fibres arrange themselves into an oblique tendon which blends with the muscular mass composed by the union of the fleshy portions of the other two heads about the middle of the back of the arm. The combined tendon thus formed is thick and remarkably strong. It is inserted into the summit and sides of the olecranon process of the ulna. Between the tendon and the back part of the capsule of the elbow-joint there is a cushion of fatty tissue, which has sometimes been described as a bursa. From the tendinous portion of the inner head some muscular fibres pass directly to the olecranon and the adjacent portion of the capsule, and have been specialized as the *sub-anconeus muscle*. The musculo-spiral nerve separates the outer from the inner heads, and sends branches to all the heads of the triceps muscle.

The **brachial artery** is the continuation downward of the axillary artery. It commences at the lower border of the posterior fold of the axilla, at the inner border of the coraco-brachialis muscle, whence it passes along the inner border of the biceps muscle to the middle of the flexure of the elbow, where, opposite the head of the radius, it divides into the radial and ulnar arteries. The above muscles slightly overlap the artery in its course, which is at first internal to the shaft of the humerus upon the triceps and brachialis anticus muscles and subsequently gradually inclines to the front of the lower end of the bone beneath the bicipital semilunar fascia. The brachial artery gives off seven or eight muscular branches from its outer side to the contiguous muscles, and four principal branches from its inner side, as follows:

The *superior profunda artery* usually arises from the brachial below the teres major muscle, although it is sometimes given off in common with the posterior circumflex from the axillary. Soon after its origin it distributes *muscular branches* to the deltoid, the coraco-brachialis, and the

long head of the triceps muscle; also a *communicating branch* to the posterior circumflex, which plays an important rôle in the collateral circulation after ligature of the main vessel in this locality, and a *nutrient branch*, which enters the upper end of the humerus beneath the outer head of the triceps. About the middle of the arm the superior profunda subdivides into two principal branches, one of which, the *cubital*, descends through the substance of the triceps muscle to the olecranon process, where it anastomoses with the *anastomotica magna*, posterior ulnar, and interosseous recurrent arteries, assisting in the formation of the *rete olecrani*; while the other branch accompanies the musculo-spiral nerve to the outer side of the arm, where, after piercing the intermuscular septum, it descends deeply with the radial nerve in the furrow between the brachialis anticus and supinator longus muscles to anastomose with the radial recurrent artery about the external epicondyle.

The *inferior profunda artery* arises either in common with the superior profunda or by a separate origin at the middle of the arm, and pursues a course with the ulnar nerve through the intermuscular septum to the interval between the internal epicondyle and the olecranon, where it also terminates in the *rete olecrani*. The *main nutrient artery* is usually derived from one of the muscular branches of the brachial. It pierces the tendon of the coraco-brachialis muscle to enter the nutrient foramen, and within the medullary canal divides into ascending and descending branches which anastomose with the nutrient vessels derived from the periosteum. The *anastomotica magna* arises from the brachial about six centimetres, or two and a half inches, above the bend of the elbow. It runs at first inward across the brachialis anticus muscle, and then divides into branches, one of which descends anteriorly between the brachialis anticus and pronator radii teres muscles in front of the internal epicondyle to anastomose with the anterior ulnar recurrent artery, another pierces the intermuscular septum posteriorly to anastomose with the posterior ulnar recurrent and inferior profunda arteries in the *rete olecrani*, while a third usually arches over the olecranon fossa and joins the superior profunda artery. Besides these regular branches of the brachial artery there is another, called the *vas aberrans*, which ordinarily is quite insignificant

and arises near the origin of the superior profunda or in common with it, and descends *over* the median nerve to supply the neighboring part of the biceps muscle. This vessel occasionally plays an important *rôle* in replacing the brachial artery when that vessel has undergone some modifying change in consequence of interference with its development during foetal life. In such cases it pursues the ordinary course of the brachial artery, except that it is placed over instead of under the median nerve, and it joins the radial artery, or very rarely the ulnar. It is of variable size, and, owing to its substituting one or other of the terminal branches of the main vessel, it occasions the condition called the *high bifurcation* of the brachial. The possibility of such an occurrence should never be lost sight of in the operation of tying the brachial artery. The *line of reference for the brachial artery* is practically a continuation of the line for the axillary artery (page 343), and may be drawn along the internal bicipital depression from the middle of the axillary space to the middle of the bend of the elbow. The incision should be made along the above line, with the arm abducted and rotated outward. The basilic vein (page 351) will be found in the superficial fascia, and can be drawn aside. The deep fascia should be divided upon a grooved director, and when the biceps muscle has been drawn outward the sheath of the brachial vessels will be exposed, with the median *nerve* lying directly over it; and, as the nerve may therefore receive pulsations from the artery, it requires careful examination lest it be mistaken for the vessel itself.

After much experience as a teacher of operative surgery, the author feels justified in stating that the inexperienced generally find more difficulty in securing the brachial artery properly than in securing any other artery in the body. This may be due to the belief that the task is an easy one, owing to the straight course and somewhat superficial position of the vessel. The disposition of the median nerve is most important, and if understood it may serve as a deep guide to the artery. This nerve in the upper part of the arm is generally at the *outer* side of the artery, but it very soon approaches the sheath of the brachial vessels and overlies it as far as the semilunar bicipital fascia, where the artery passes to the middle of the elbow-joint, and the nerve continues, at its

inner side, to descend between the two heads of the pronator radii teres muscle. There is an investment of the deep fascia which retains the nerve in this relation to the sheath of the vessels even if the position of the arm is changed in extension, but if the forearm is flexed after the deep fascia is divided the nerve can be drawn to one side or the other and the underlying sheath exposed. When the latter is opened, the artery will be found with a companion vein upon each side of it. It should be further remembered that the upper part of the artery is *over* the musculospiral nerve, that the ulnar nerve is close to its inner side as far as the insertion of the coraco-brachialis muscle, and that toward the elbow the internal cutaneous nerve is either in front of or close to its inner side.

The *venæ comites of the brachial artery* are the continuations of the deep radial and ulnar veins (Plate 46, Fig. 2). The internal is usually much larger than the artery, and often overlaps it. They are frequently united by cross veins, similar to those about the axillary artery, either in front of or behind the artery, and they unite in a single trunk in the axilla to empty into the axillary vein near the tendon of the subscapularis muscle.

The *terminal branches of the brachial plexus of nerves* (page 344) are the median, the musculo-cutaneous, the ulnar, the two internal cutaneous, and the musculospiral nerves. The *median nerve* is composed of a *plexiform* arrangement of fibres derived from two heads which arise respectively from the outer and inner cords of the brachial plexus and unite to form a single nerve-cord external to the axillary artery, generally beneath the pectoralis minor muscle (Plate 45, Fig. 2, No. 23). In its course down the arm the median nerve does not normally give off any branches. It is usually at first at the outer side of the artery, near the axilla, although not always so, and it soon overlies the sheath of the brachial vessels until it reaches the elbow, where it is at the inner side of the artery, as already described. The deep fibres of origin to the outer head of the median nerve are derived from the sixth and seventh cervical nerves, and those to the inner head are derived from the eighth cervical and first dorsal nerves. The *musculo-cutaneous nerve* arises from the outer cord of the brachial plexus in common with the external head of the

PLATE 48.

Figure 1.

Dissection of the palm of the right hand, showing the superficial layer of the palmar fascia.

1. The abductor pollicis muscle.
2. Slip of the palmar fascia, passing to the proximal phalanx of the thumb.
3. Lateral nerve to the thumb.
4. Accessory transverse slip of the palmar fascia, arching over the vessels and nerves to the thumb.
5. The princeps pollicis artery.
6. The superficial layer of the palmar fascia, showing its longitudinal fibres and expansion.
7. Arch of the palmar fascia, between the metacarpal bones of the index and middle fingers, over the digital vessels and nerves.
8. Tendon of the palmaris longus muscle.
9. The ulnar artery, at the wrist.
10. The abductor minimi digiti muscle.
11. The external lateral nerve and artery to the little finger.
12. Arch of the palmar fascia, between the little and ring fingers.
13. The branches of the median nerve.

Figure 2.

Dissection of the palm of the right hand. The superficial layer of the palmar fascia is hooked aside to show the deep layer of the fascia and the *superficial* palmar arterial arch.

1. The superficialis volæ artery.
2. The abductor pollicis muscle.
3. The continuation of the superficialis volæ artery.
4. The deep layer of the palmar fascia, over the median nerve and the flexor tendons.
5. The flexor brevis pollicis muscle.
6. The superficial palmar arch.
7. Digital branches of the median nerve.
8. The superficial layer of the palmar fascia, hooked aside.
9. Branches of the median nerve, dividing at the cleft of the fingers into digital nerves.
10. The annular ligament.
11. The ulnar artery.
12. The ulnar nerve.
13. The abductor minimi digiti muscle.
14. Branches of the median nerve.
15. The external lateral artery to the little finger.
16. Branch of the superficial palmar arch.
17. Tendinous insertion of the palmar fascia to the metacarpal bone of the ring finger.
18. Superficial flexor tendon to the ring finger.
19. Digital nerves from the median nerve.

Figure 3.

Dissection of the palm of the right hand, showing the position of the superficial arterial arch and the relations of its digital branches to the nerves and flexor tendons.

1. The flexor carpi radialis tendon.
2. The median nerve, above the annular ligament.
3. The abductor pollicis muscle.
4. The median nerve, below the annular ligament.
5. The princeps pollicis artery.
6. The flexor tendon to the index finger.
7. Aponeurotic arch.
8. Sheath of flexor tendons.
9. Aponeurotic arch.
10. The subdivision of the superficial flexor tendons, to be inserted in the sides of the second, or intermediary, phalanx.
11. Anastomosing branches of the digital arteries, across the phalangeal joint.
12. Aponeurotic arch.
13. Terminal arterial plexus.
14. The ulnar artery.
15. The annular ligament.
16. The ulnar nerve.
17. The superficial palmar arch.
18. Superficial flexor tendon.
19. Aponeurotic arch of the flexor tendon to the ring finger.
20. Deep flexor tendon of the ring finger.

Figure 4.

Dissection of the palm of the right hand. The tendons are cut away to show the *deep* palmar arterial arch and its relations, etc.

1. The median nerve, above the annular ligament.
2. The opponens pollicis muscle.
3. The abductor pollicis muscle.
4. The superficialis volæ artery.
5. The flexor brevis pollicis muscle.
6. Branch of the median nerve to the thumb.
7. The adductor pollicis muscle.
8. The tendon of the flexor longus pollicis muscle.
9. The cut ends of the flexor tendons.
10. Sheath of the flexor tendons.
11. Aponeurotic arch.
12. Terminal arterial plexus.
13. The ulnar nerve.
14. The ulnar artery.
15. The annular ligament.
16. The median nerve, below the annular ligament.
17. The flexor brevis minimi digiti muscle.
18. The deep palmar arch.
19. The superficial palmar arch.
20. The cut ends of the flexor tendons.
21. Aponeurotic arch.
22. Insertion of superficial flexor tendon into the sides of the intermediary phalanx of the ring finger.
23. Terminal arterial plexus.

Fig 1

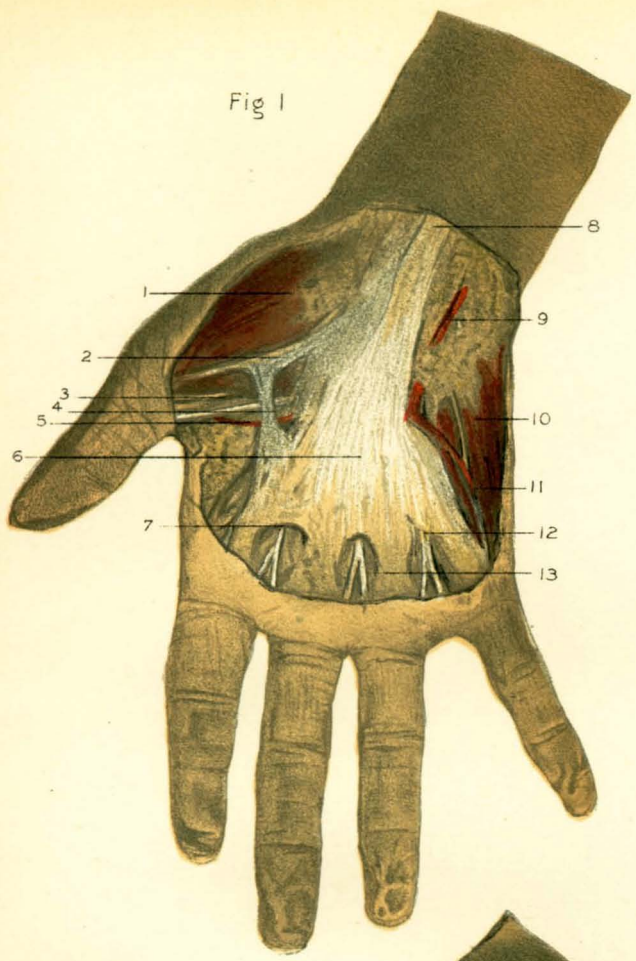


Fig 2

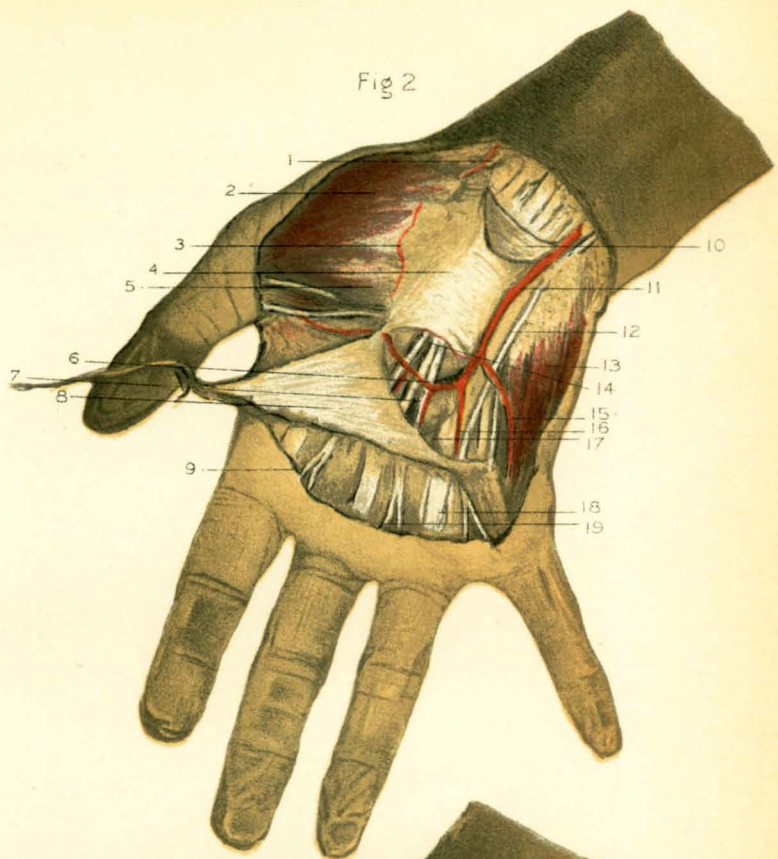


Fig 3

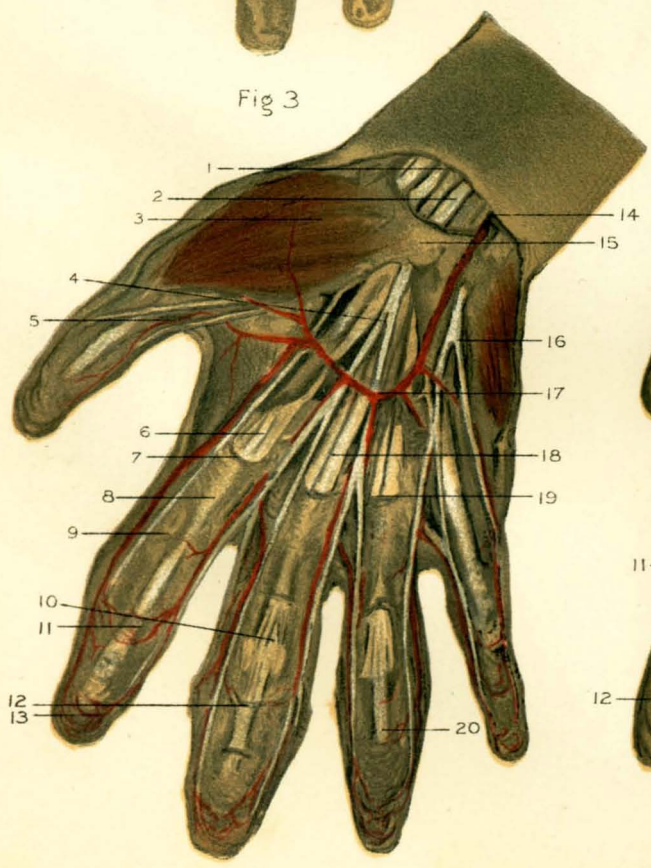
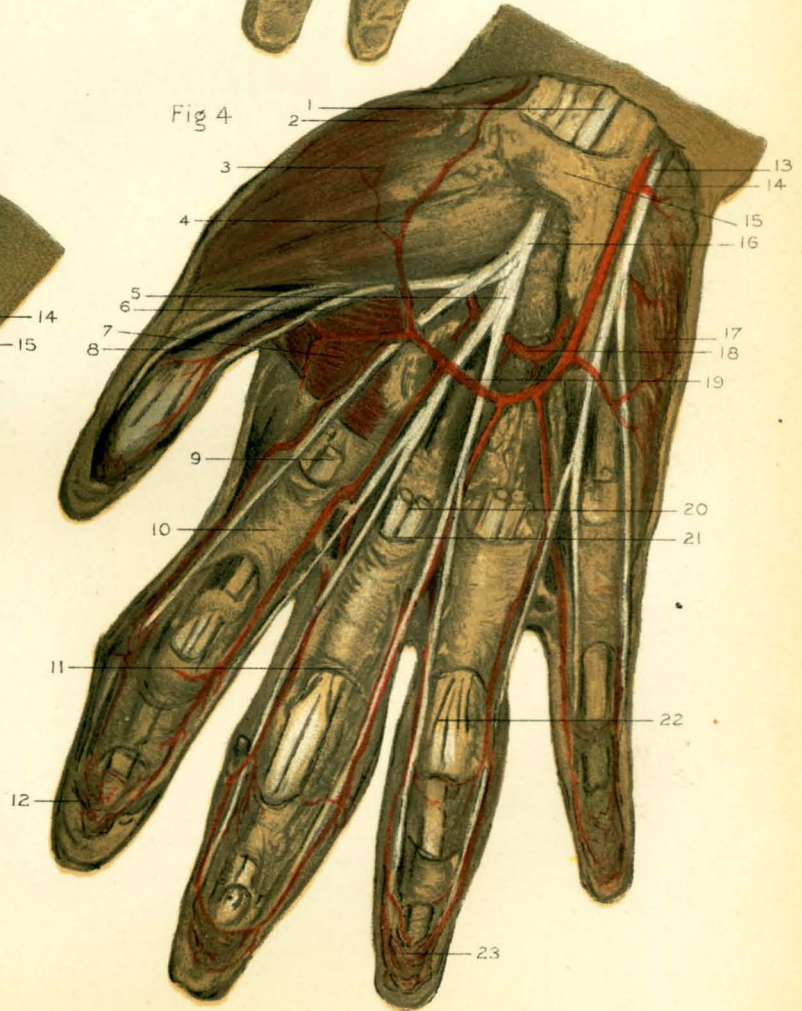


Fig 4



median nerve, at the outer side of the axillary artery. It pierces the coraco-brachialis muscle and passes obliquely to the septum between the biceps and brachialis anticus muscles. Above the outer side of the elbow the nerve pierces the deep fascia between the tendon of the biceps and supinator longus muscles, and becomes subcutaneous beneath the median cephalic vein (Plate 46, Fig. 1, No. 9). It supplies branches to the coraco-brachialis, the coracoid head of the biceps, and the brachialis anticus muscles. This nerve is sometimes derived from the median nerve, or, if it is absent, the median nerve distributes the branches ordinarily supplied by it,—the whole of the outer cord of the brachial plexus, in such instances, contributing to the formation of the median. Division of the musculo-cutaneous nerve at its origin will result in paralysis of the flexor muscles at the elbow. Its fibres have been traced to the fifth and sixth cervical nerves.

The *ulnar nerve* arises from the inner cord of the brachial plexus in common with the internal head of the median nerve and the internal cutaneous nerve. In its course normally this nerve gives off no branches in the arm. At first it is internal to the brachial artery, but it soon leaves it to accompany the inferior profunda artery, with which it pierces the intermuscular septum fourteen centimetres, or about five inches, above the elbow, and descends on the inner head of the triceps muscle to reach the space between the internal epicondyle and the olecranon. Here it is accommodated in a shallow groove upon the back of the epicondyle (page 348), and can be felt through the skin.

The *internal cutaneous nerve*, after its origin from the inner cord of the brachial plexus, descends at first beneath the deep fascia on the inner side of the brachial artery. About the middle of the arm it pierces the fascia at the *hiatus semilunaris*, which also admits the basilic vein (page 351), and divides into anterior and posterior branches. The *anterior branch* passes under the median basilic vein and supplies the skin on the forearm as far as the wrist, where it communicates with cutaneous branches of the ulnar nerve. The posterior branch soon subdivides into several branches, one of which is distributed to the back of the internal epicondyle and communicates with the lesser internal cutaneous

nerve, and another to the back of the forearm as far as the wrist, above which there is a connection between it and the ulnar nerve. The fibres composing both the ulnar and the internal cutaneous nerves are originally derived from the eighth cervical and first dorsal nerves. The *lesser internal cutaneous nerve* (of *Wrisberg*) arises also from the inner cord of the brachial plexus, receiving its filaments from the first dorsal nerve. It is at first upon the inner side of the axillary vein, and near the anterior fold of the axilla it usually unites with the posterior division of the lateral cutaneous branch of the second intercostal nerve, or *intercosto-humeral nerve* (page 339): the compound nerve thus formed pierces the deep fascia and supplies the skin of the inside of the arm as far as the elbow.

The *musculo-spiral nerve* arises from the posterior cord of the brachial plexus, in common with the circumflex nerve (page 346), their original filaments being derived from the sixth, seventh, and eighth cervical and first dorsal nerves. The musculo-spiral nerve is the largest of the nerves of the arm. It descends behind the upper part of the brachial artery and passes between the external and the internal heads of the triceps muscle, winding obliquely round the back of the shaft of the humerus with the superior profunda artery in the musculo-spiral groove. Thence it pierces the intermuscular septum and enters the furrow between the brachialis anticus and supinator longus muscles, both of which it supplies upon the outer side of the lower third of the arm, where it divides into two terminal branches, the radial and posterior interosseous nerves. In the first part of its course, behind the brachial artery, the musculo-spiral nerve gives off branches as follows: the *nerve to the long head of the triceps*; the *posterior internal cutaneous nerve*, which supplies the area of skin behind that supplied by the intercosto-humeral nerve; the *nerve to the inner head of the triceps*, from which a little branch sometimes passes to join the ulnar nerve; the *nerve to the anconeus muscle*; the *nerve to the outer head of the triceps*; and the *posterior external cutaneous nerve*, which usually arises from the main nerve within the musculo-spiral groove and subdivides into two branches, the *superior* of which becomes superficial below the deltoid insertion and supplies the skin of the arm between that point and the elbow external to the cephalic vein. The

inferior branch descends within the superficial fascia of the forearm and supplies the skin over the ulna (page 378). It is interesting to note that the musculo-spiral nerve supplies *all* the extensor and *all* the supinator muscles, except the biceps. In consequence of its close connection with the humerus, this nerve is frequently injured by contusions, or in fractures at the middle of the shaft of the bone.

Fracture of the shaft of the humerus is a very common accident, both from direct and from indirect violence, but much undue stress has been laid upon the influence of muscular action upon the displacement of the fragments of the bone. In fact, marked displacement is rarely met with, notwithstanding the possibilities usually ascribed to the injury with reference to its occurrence above or below the insertion of the deltoid muscle. The weight of the arm tends to overcome displacement, and seldom allows much shortening. In the treatment of all fractures of the arm it is of the utmost importance that both the shoulder-joint and the elbow-joint should be properly supported, so as to maintain the fragments *in perfect line*. *Non-union* would probably be far less common if this were understood. *In amputation through the middle* of the arm by the antero-posterior oval-flap method, the relations of the important parts as they appear in the flaps when made upon the *left* arm are as follows (Plate 51, Fig. 1). The anterior flap consists chiefly of the biceps muscle (No. 1), while the posterior flap is composed chiefly of the triceps muscle (No. 5), containing the anastomotica magna artery (No. 11). Between the flaps on the inner side are the ulnar nerve (No. 4), the median nerve (No. 3), and the brachial vessels (No. 8). On the outer side, in the angle between the flaps will be found the severed superior profunda artery (No. 9) and the musculo-spiral nerve (No. 10).

At birth the *ossification of the shaft of the humerus* is nearly completed, although the extremities are entirely cartilaginous. Bone is not developed in the head before the second year, or in the tuberosities before the third year. There is generally but one centre of ossification for the two tuberosities, but there may be one for each tuberosity. The bicipital groove is produced by the constant and forcible impression of the long tendon of the biceps muscle on the growing bone. About the fifth year the centres

for the head and tuberosities coalesce and form the upper epiphysis, which is not united to the shaft until about the twenty-second year. The radial portion of the articular surface of the lower end of the humerus is developed by a centre of ossification in the third year, and the ulnar surface does not begin to ossify before the twelfth year. The internal epicondyle is formed about the fifth year, and the external epicondyle in the fourteenth year. The epicondyles and the trochlear surface become united about the seventeenth year and form the lower epiphysis, which generally unites with the shaft a year later. It should be noted that after the sixteenth year the growth of the humerus chiefly depends upon the upper epiphysis.

THE REGION OF THE ELBOW.

The elbow is formed by the lower end of the humerus and the upper end of the ulna, which are so adapted to each other that they establish a hinge-joint of very considerable strength, by which the arm is connected with the forearm. The peculiar conformation of the lower end of the humerus has already been described (page 348). The upper end of the ulna is one of the most remarkable portions of the skeleton, and possesses many singular features. It consists of two conspicuous processes separated by a deep hollow. The process which extends backward is called the *olecranon*, because it forms the prominence of the elbow. It is a thick, strong, bony eminence ending in a curved tip which is received into the olecranon fossa of the humerus when the forearm is extended. The base of the olecranon process is constricted where it joins the shaft, corresponding to the line of the olecranon epiphysis, and is the usual seat of fracture when this part of the bone is broken. The upper posterior surface of the olecranon is somewhat square-shaped, and presents a rough impression for the attachment of the triceps muscle (page 354). The anterior surface is smooth, and forms the upper part of the deep hollow called the *greater sigmoid cavity*, which articulates with the trochlear surface on the humerus. The bottom of this cavity is marked transversely by a line, which indicates the constriction at the base of the olecranon above referred to. The cavity terminates below in the *coronoid process*, the broad projection from the shaft of the ulna which