

June 2007

# Breast specific gamma imaging: Role in evaluation of breast disease

Anne L. Rosenberg

*Thomas Jefferson University, raf0608@hotmail.com*

Kristin L. Brill

*Thomas Jefferson University*

R. A. Flynn

Lillian Stern

*Methodist Hospital, Philadelphia, PA*

E. M. Ferguson

*Methodist Hospital, Philadelphia, PA*

## Let us know how access to this document benefits you

Follow this and additional works at: <http://jdc.jefferson.edu/surgeryfp>Part of the [Surgery Commons](#)

### Recommended Citation

Rosenburg, Anne L.; Brill, Kristin L.; Flynn, R. A.; Stern, Lillian; and Ferguson, E. M., "Breast specific gamma imaging: Role in evaluation of breast disease" (2007). *Department of Surgery Faculty Papers*. Paper 7.

<http://jdc.jefferson.edu/surgeryfp/7>

# Breast Specific Gamma Imaging: Role in evaluation of breast disease

A. L. Rosenberg,<sup>1</sup> K. L. Brill,<sup>1</sup> R.A. Flynn,<sup>2</sup> L. Stern,<sup>2</sup> E. M. Ferguson<sup>3</sup>

1. Surgery, Jefferson Medical College, Kimmel Cancer Center, Cherry Hill, NJ, 2. Radiology, Jefferson Medical College/Methodist Hospital, Philadelphia, PA, 3. Radiology, Methodist Hospital, Philadelphia, PA.

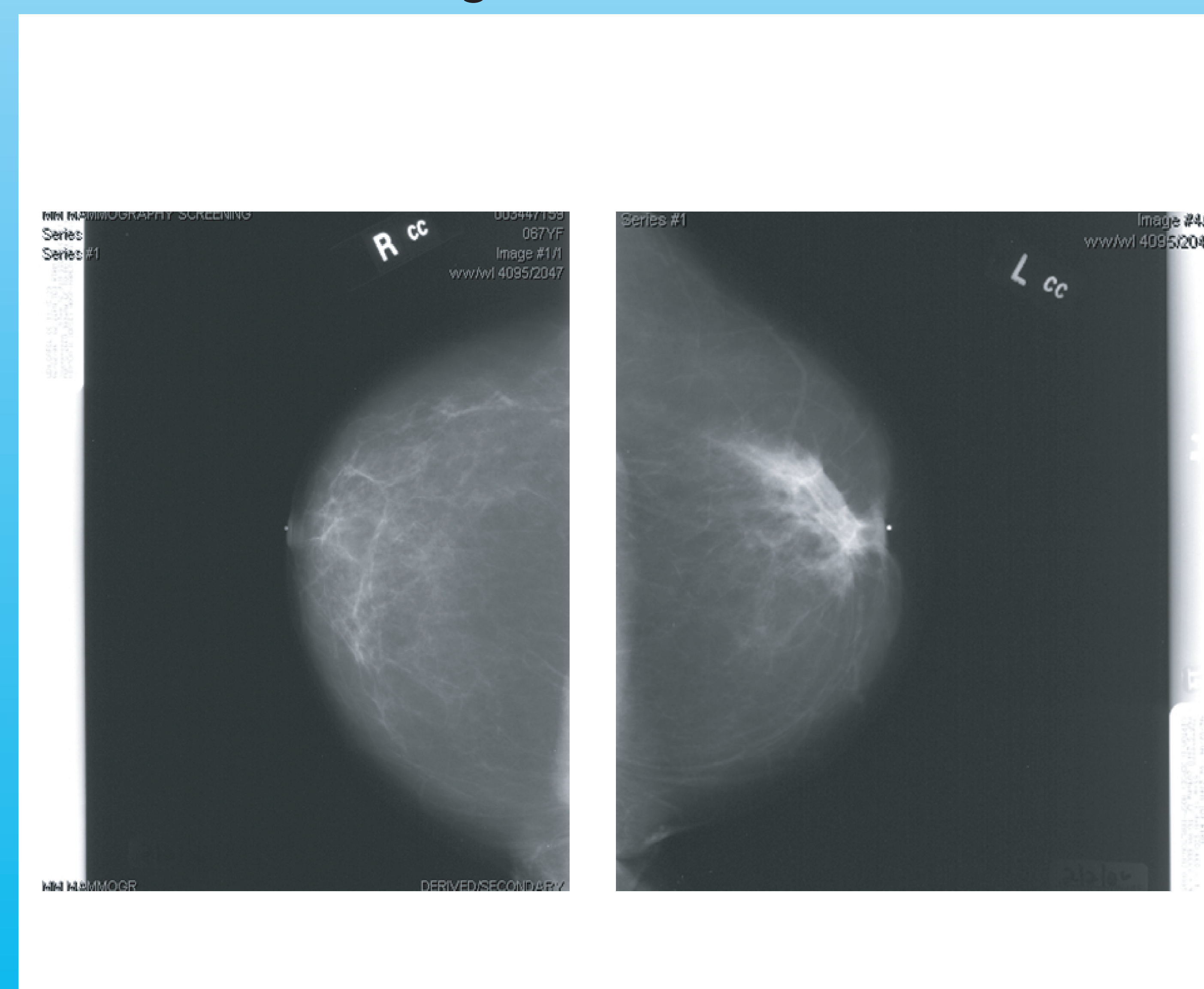
## Introduction

Although mammography is the gold standard for screening for breast cancer, 10 to 15% of lesions are missed, and this is higher with dense breasts. Alternative diagnostic modalities are being developed. One of these, breast specific gamma imaging (BSGI), which is not effected by dense tissue, utilizes the increased metabolic activity of tumors to localize and distinguish benign from malignant processes in the breast. The test can be used for screening and diagnostic purposes.

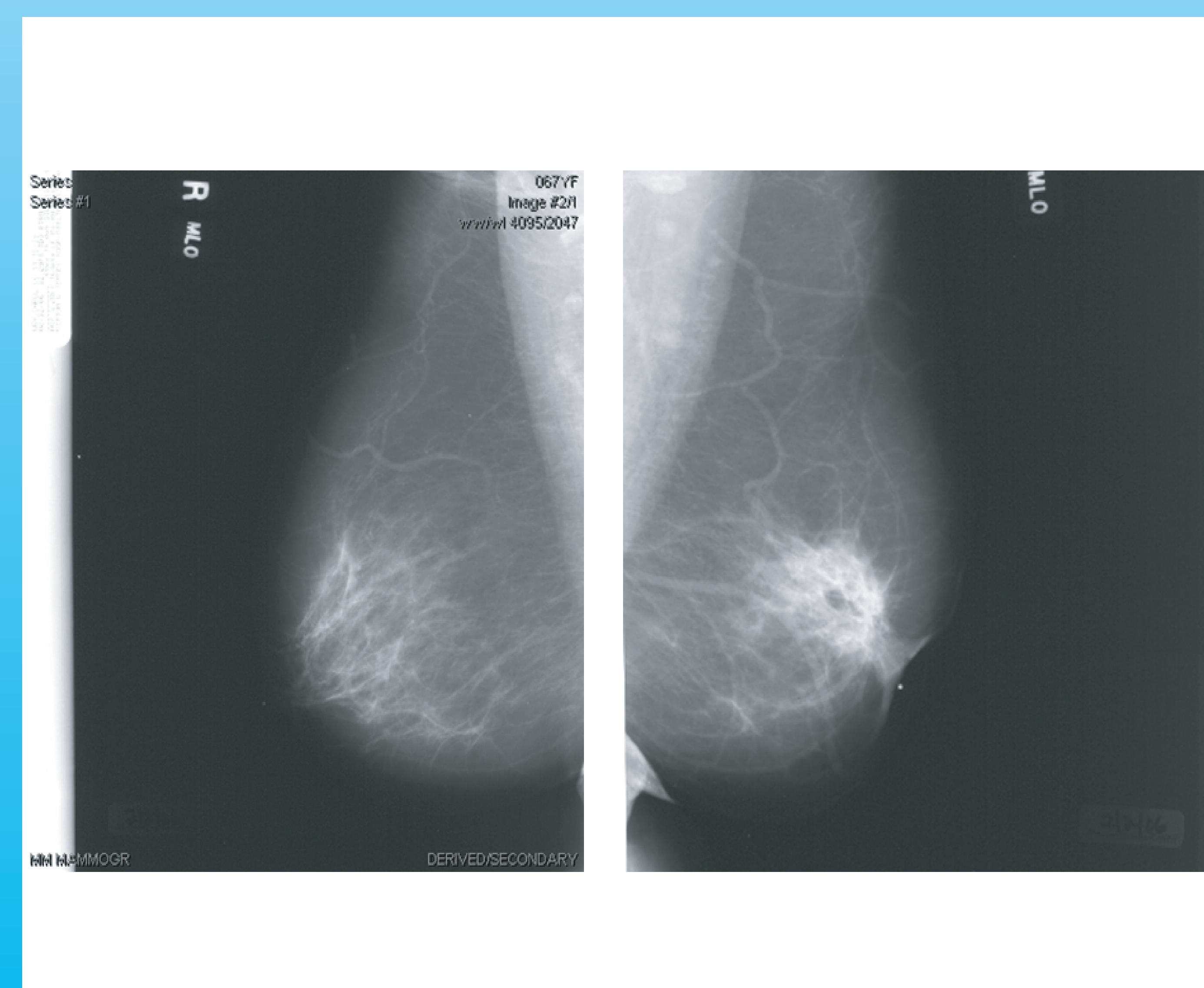
## Methods

Using review of radiographs and medical records, we reviewed our experience with BSGI from 5/01/06 to 5/01/07. Demographic information, indications for study and results of BSGI were collected along with available mammography, ultrasound and MRI examinations.

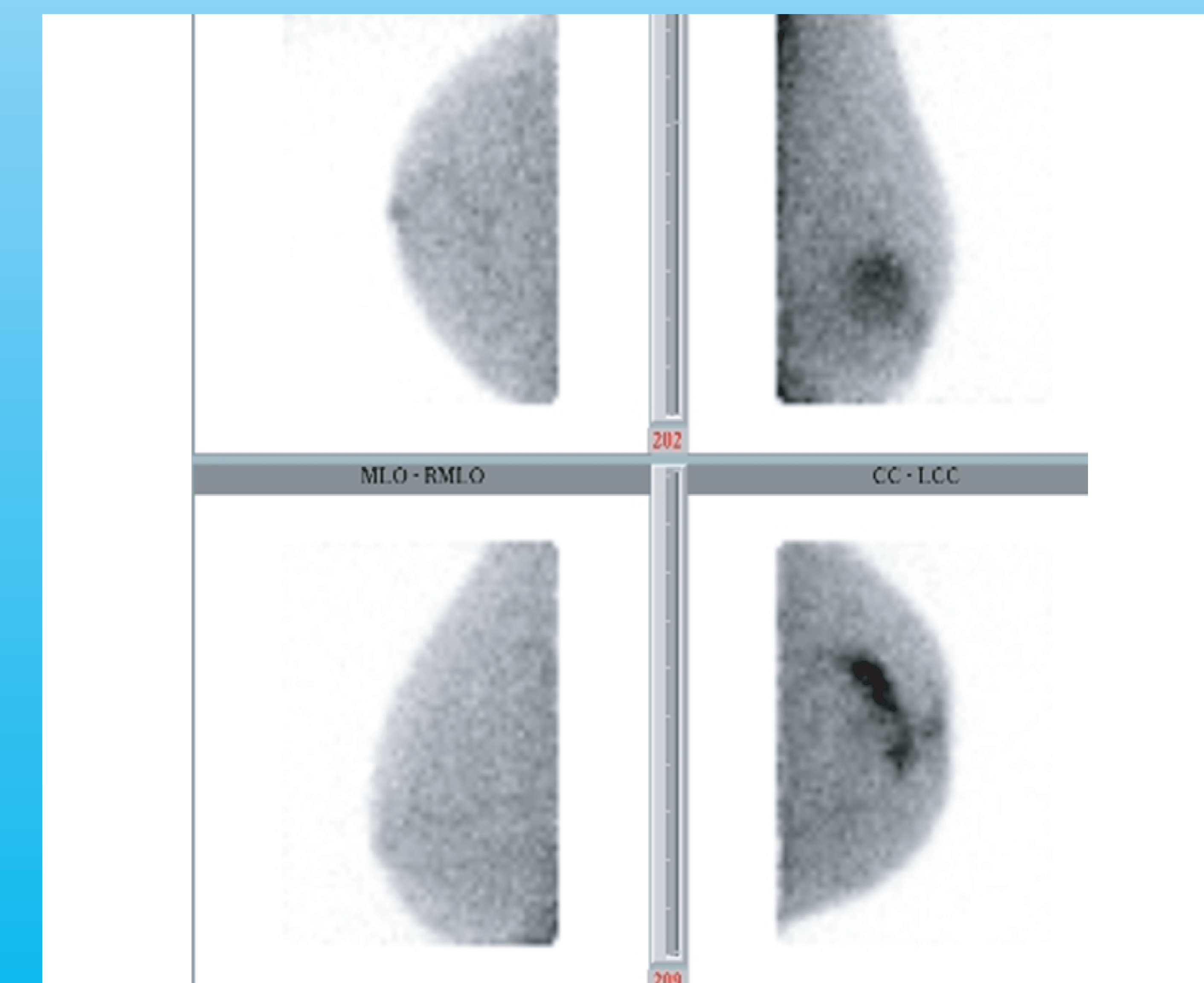
A - Mammogram, Craniocaudal view



B - Mammogram, Madeiolateral view



C - BSGI



76 year old woman with history of stage 2 cancer of the right breast 12 years ago treated with breast conservation therapy. new lesion right axillary tail. incidental large lobular carcinoma of the left breast discovered on BSGI

## Results

Indications for BSGI included patients with: 1) recently diagnosed breast cancer to look for multifocality and multicentricity. 2) BRCA mutations. 3) past history of breast cancer/recurrence, 3) multiple masses on mammography and/or ultrasound, 4) unexplained pain or palpable abnormalities, 5) extremely dense breasts, and 6) indeterminate calcifications.

Of the 421 women who underwent BSGI, 28 also had MRI.

Results were analyzed by BIRADS categories. Seven of 8 patients were classified as BIRADS 5 or 6 on BSGI also had a positive MRI. All 7 patients that had a positive BSGI and MRI had a positive biopsy for cancer. One patient negative on MRI was also negative on biopsy. This would indicate a sensitivity of 87.5% and a specificity of 87.5% for BIRADS 5 and 6 patients.

Six of 15 patients classified as BIRADS 4 on BSGI had concurrent MRI

classification. Three of 5 patients with BIRADS 3 on MRI were thought to have fibroadenomas and 4 others were BIRADS 2 on MRI.



## Conclusions

These preliminary findings indicate a high sensitivity and specificity for BSGI similar to what other investigators have found, with results comparable to MRI. BSGI is simpler, less expensive, without a claustrophobic setting or prone positioning and with no contraindications for any metal in patients. Results are available immediately with only one screen or film to interpret. BSGI shows great promise in detecting breast cancer. These preliminary results have prompted a multi-institutional prospective study in the near future.