



Thomas Jefferson University
Jefferson Digital Commons

Department of Orthopaedic Surgery Faculty Papers

Department of Orthopaedic Surgery

March 2007

Three-portal technique for anterior cruciate ligament reconstruction: Use of a central medial portal

Steven B. Cohen

Thomas Jefferson University, Steven.Cohen@rothmaninstitute.com

Freddie H. Fu

University of Pittsburgh

[Let us know how access to this document benefits you](#)

Follow this and additional works at: <http://jdc.jefferson.edu/orthofp>

 Part of the [Orthopedics Commons](#)

Recommended Citation

Cohen, Steven B. and Fu, Freddie H., "Three-portal technique for anterior cruciate ligament reconstruction: Use of a central medial portal" (2007). *Department of Orthopaedic Surgery Faculty Papers*. Paper 11.

<http://jdc.jefferson.edu/orthofp/11>

This Article is brought to you for free and open access by the Jefferson Digital Commons. The Jefferson Digital Commons is a service of Thomas Jefferson University's [Center for Teaching and Learning \(CTL\)](#). The Commons is a showcase for Jefferson books and journals, peer-reviewed scholarly publications, unique historical collections from the University archives, and teaching tools. The Jefferson Digital Commons allows researchers and interested readers anywhere in the world to learn about and keep up to date with Jefferson scholarship. This article has been accepted for inclusion in Department of Orthopaedic Surgery Faculty Papers by an authorized administrator of the Jefferson Digital Commons. For more information, please contact: JeffersonDigitalCommons@jefferson.edu.

1
2
3
4
5
6
7
8
9
10
11
12
13
14
15
16
17
18
19
20
21
22
23
24
25
26
27
28
29
30
31
32
33
34
35
36
37
38
39
40
41
42
43
44
45
46

**The Three Portal Technique for ACL Reconstruction: Use of an
Accessory Medial Portal**

Technical Note

**Steven B. Cohen, MD
Freddie H. Fu, MD, DSc, DPs (Hon)**

From the University of Pittsburgh Center for Sports Medicine, Pittsburgh, PA

Corresponding author:
Freddie H. Fu, MD, DSc, DPs (Hon)
Center for Sports Medicine
University of Pittsburgh Medical Center
3200 S. Water Street
Pittsburgh, PA 15203
ffu@upmc.edu
412-432-3662
Fax: 412-432-3690

47 **Introduction**

48 Traditional endoscopic anterior cruciate ligament (ACL) reconstruction is
49 performed using two standard portals. The anterolateral portal is used as the viewing
50 portal and the anteromedial portal is used as the working portal. When performing ACL
51 reconstruction however the posterior aspect of the lateral intercondylar notch may be
52 difficult to view entirely through the lateral portal. There have been numerous
53 descriptions for portal locations for knee arthroscopy, but no article has noted optimal
54 locations for specific portals relating to ACL reconstruction.[1-6] In fact, Kurosaka has
55 used a similar multiple portal technique for ACL reconstruction for several years
56 [personal communication, 2002].

57 Conventionally, the anterolateral portal is positioned above the joint line just
58 lateral to the lateral border of the patella tendon. Likewise, the anteromedial portal can
59 be created by direct visualization using a spinal needle but is located slightly above the
60 joint line and just off or nearly 1 cm medial to the medial border of the patella tendon.
61 From our experience these portals limit anatomic placement of both the tibial and femoral
62 tunnels during ACL reconstruction by preventing proper visualization of both the tibial
63 plateau and lateral wall of the intercondylar notch. Our current technique for endoscopic
64 anatomic double bundle ACL reconstruction, a modification from Kurosaka, has been
65 well described and involves the use of three portals [7, 8], which are used
66 interchangeably as viewing and working portals based on the specific task being
67 performed, much like that of arthroscopy of the shoulder.(**Table 1**)

68 **Portal Location**

69 *“High” Anterolateral Portal*

70 The anterolateral portal is initially used as the viewing portal. It is located just
71 lateral to the patella tendon with the most inferior portion of the portal at the level of the
72 inferior pole of the patella when the knee is flexed to 60 degrees (**Figure 1**). The portal
73 is created with an 11-scalpel blade taking care to avoid damage to the articular cartilage
74 when penetrating the capsule. This portal avoids penetration into the fat pad and is used
75 for the diagnostic arthroscopy, as it allows complete viewing of the patellafemoral,
76 medial, and lateral compartments of the knee without significant resection of the fat pad.
77 Additionally, the anterolateral portal is used to determine the precise position of the
78 anteromedial (AM) and posterolateral (PL) bundles of the ACL at its insertion on the
79 tibia. These sites are marked in preparation for drilling the two tibial tunnels for ACL
80 reconstruction (**table 2**). The superior position of the portal allows a wider view of the
81 tibial insertion of the ACL.

82 *Anteromedial Portal (Central Portal)*

83 The anteromedial or “central” portal is used as a working and a viewing portal. It
84 is placed nearly 1 cm lateral to the medial border of the patella tendon (intra-tendinous)
85 just inferior from the inferior pole of the patella when the knee is flexed to 60 degrees
86 (**Figure 1**). Again, the portal is created with an 11-scalpel blade taking care to avoid the
87 articular cartilage of the trochlea. This portal is specifically used for viewing the wall of
88 the lateral intercondylar notch and marking the insertion sites of the AM and PL bundles
89 of the ACL (**Table 2**). While viewing through this portal, the accessory medial portal
90 becomes the working portal. By working in this fashion, no “notchplasty” or

91 “wallplasty” is required because there is no obstruction to viewing the notch, and each
92 bundle is placed in its anatomic insertion while avoiding impingement of the posterior
93 cruciate ligament (PCL). Additionally, the anteromedial portal is used to place the guide
94 (which is set on 45 degrees) for drilling the AM tibial tunnel.

95 *Accessory Medial Portal*

96 The accessory medial portal is used mainly as the working portal for PL bundle
97 femoral tunnel placement. Nearly 30% of the time it is also used for AM bundle femoral
98 tunnel placement when the transtibial technique does not allow for anatomic AM femoral
99 tunnel drilling. The portal is created using direct visualization with a 18-gauge spinal
100 needle typically just superior to the medial joint line approximately 2 cm medial to the
101 medial border of the patella tendon (**Figure 1 & 2**). This allows the proper angle to drill
102 the PL (and if necessary the AM) femoral tunnel with avoidance of injury to the cartilage
103 of the medial femoral condyle. It is also used to place the guide (which is set on 55
104 degrees) for the PL bundle tibial tunnel. By placing the guide in different portals for the
105 AM and PL tunnels in the tibia, this allows for a larger bone bridge and the proper angle
106 for tunnel placement (**Table 2**). In addition, the accessory medial portal may be used as
107 a viewing portal to view the femoral insertion of the ACL in the notch.

108 **Discussion**

109 In shoulder arthroscopy, multiple portals are used to perform specific tasks.
110 Similarly, arthroscopy of the knee and more specifically ACL reconstruction, portal
111 placement is critical to successfully perform the intended procedure. Each of the three
112 portals described above have specific roles during surgery (**Figure 3**). It is crucial to
113 visualize the ACL footprint on the tibia to determine the precise anatomic location of the

114 AM and PL bundles of the ACL for tibial tunnel placement (**Figure 4**). Likewise,
115 viewing the lateral aspect of the intercondylar notch through the standard lateral portal
116 without a notchplasty to define the anatomic femoral insertion of the ACL can be quite
117 limited (**Figure 5**). This may cause nonanatomic femoral tunnel placement during single
118 or double bundle reconstruction. As a result, we recommend the use of the medial portal
119 as the viewing portal for femoral tunnel drilling and the use of an accessory medial
120 working portal. This prevents the need for removal of any bone from the notch.

121 During anatomic double bundle ACL reconstruction, it is helpful to use a variety
122 of portals throughout the surgery. For marking the anatomic insertions of the ACL on the
123 tibia and tibial tunnel drilling, we recommend using the “high” lateral portal for its
124 greatest visualization of the tibial footprint. Contrary to traditional ACL reconstruction,
125 we advocate using the anteromedial (middle) viewing portal to determine the femoral
126 origin of the AM and PL bundles of the ACL on the femur. In order to do this, the
127 accessory medial portal is used as a working portal for drilling the PL femoral tunnel and
128 if necessary the AM femoral tunnel. Most commonly, the AM femoral tunnel can be
129 placed with the transtibial technique, however if the transtibial technique places the AM
130 tunnel too vertical or non-anatomic, the accessory medial portal is used to drill the AM
131 femoral tunnel.

132 The most common complication associated with ACL reconstruction is erroneous
133 tunnel placement.[9] There are a variety of causes of this, but poor visualization of the
134 anatomic landmarks is will likely cause inaccurate tunnel placement. We propose the
135 solution to poor intercondylar notch visualization is not notchplasty or wallplasty but
136 rather altering the viewing location and adding an accessory medial working portal. This

137 will allow improved visualization of both tibial and femoral anatomic insertions of the
138 ACL and may prevent improper tunnel position during ACL reconstruction.

139
140

141 **References**

142

- 143 1. Dandy DJ. Basic technique: The standard approach. In: McGinty JB, ed. Operative
144 Arthroscopy. Philadelphia: Lippincott-Raven, 1996;243:252-253.
- 145 2. Eriksson E, Sebik A. A comparison between the transpatellar tendon and lateral
146 approach to the knee joint during arthroscopy: A cadaveric study. *Am J Sports Med*
147 1980;8:103.
- 148 3. Kim SJ, Kim HJ. High portal: Practical philosophy for positioning portals in knee
149 arthroscopy. *Arthroscopy* 2001;17:333-337.
- 150 4. Ong BC, Shen FH, Musahl V, Fu FH, Diduch DR. Knee: Patient positioning, portal
151 placement, and normal arthroscopic anatomy. In: Miller MD, Cole BJ, eds. *Textbook*
152 *of Arthroscopy*. Philadelphia: Elsevier, 2004;46:463-469.
- 153 5. Parisien JS. Normal arthroscopic anatomy, portals, and techniques. Presented at the
154 62nd Annual meeting of the American Academy of Orthopaedic Surgeons, Feb 1995;
155 Orlando, FL.
- 156 6. Stetson WB, Templin K. Two-versus three-portal technique for routine knee
157 arthroscopy. *Am J Sports Med* 2002;30:108-111.
- 158 7. Cohen SB, Starman J, Fu FH. Anatomic double bundle anterior cruciate ligament
159 reconstruction. *Tech Knee Surg*. In press.
- 160 8. Zelle B, Brucker PU, Feng MT, Fu FH. Anatomical double-bundle anterior cruciate
161 ligament reconstruction. *Sports Med* 2006;36:99-108.
- 162 9. Sommer C, Friederich NF, Muller W. Improperly placed anterior cruciate ligament
163 grafts: correlation between radiological parameters and clinical results. *Knee Surg*
164 *Sports Traumatol Arthrosc* 2000;8(4):207-13.

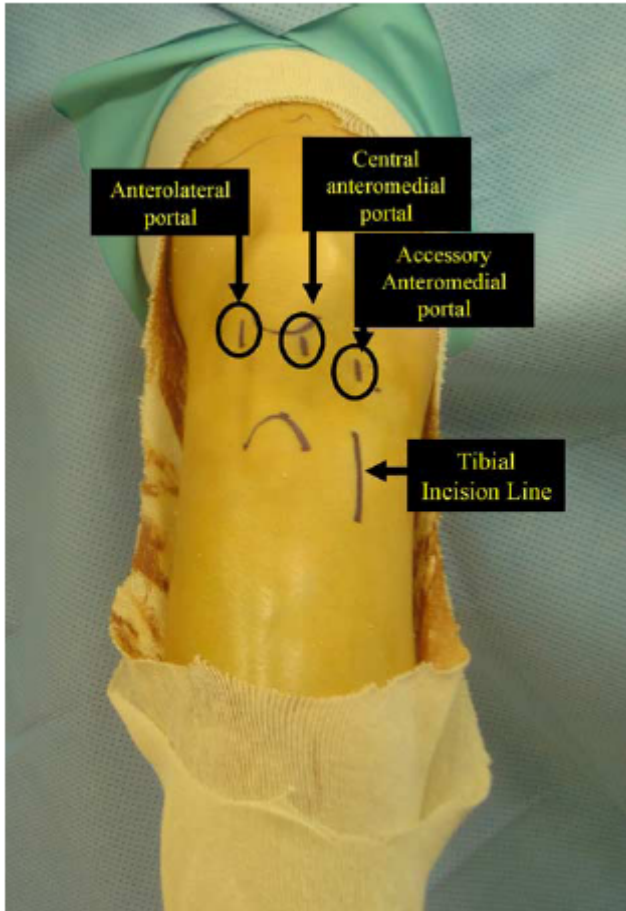
165 **Figures**

166

167

168 **Figure 1:** Portal locations marked on skin for ACL reconstruction

169



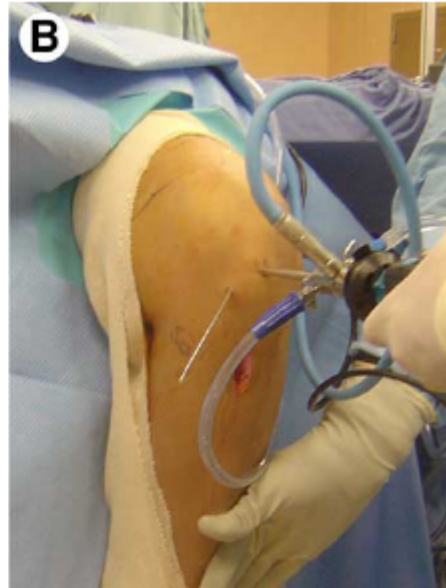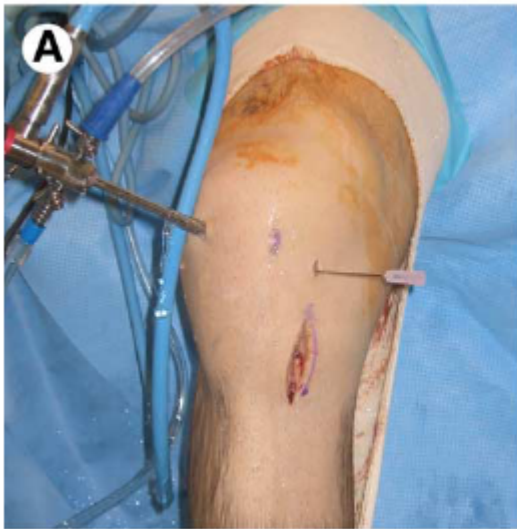170

171

172

173

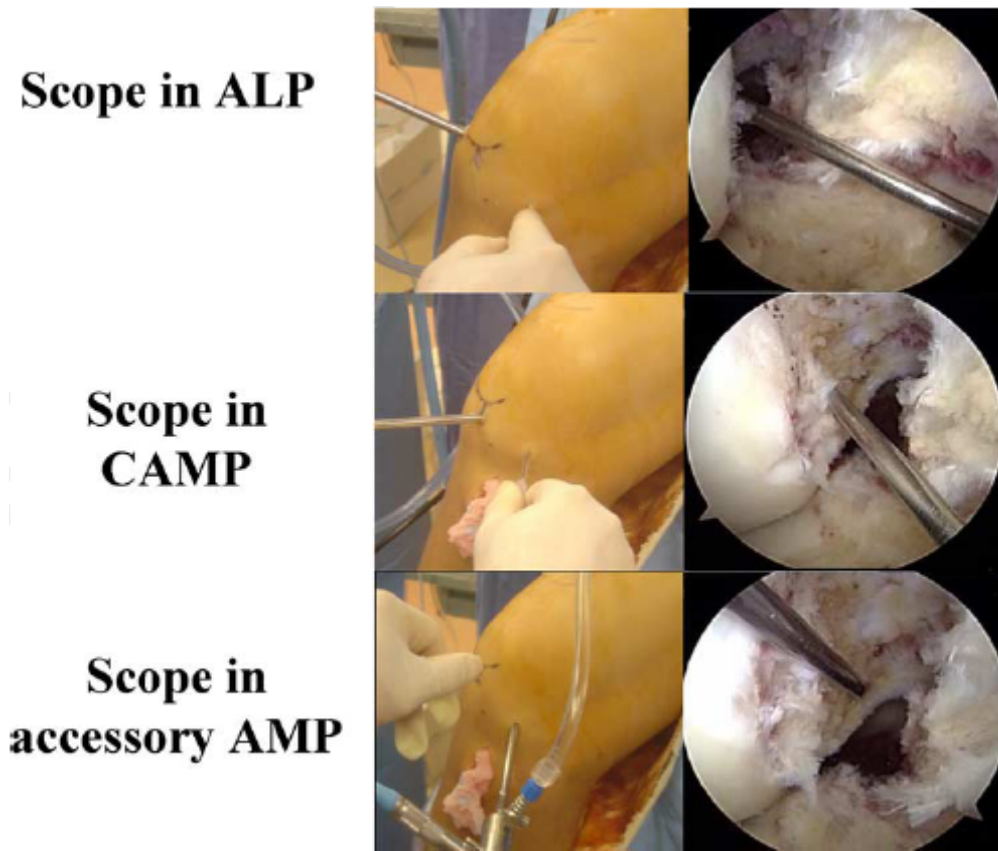
174 **Figure 2:** External view of arthroscopic instruments during ACL reconstruction. A)
175 Scope in the anterolateral portal and a spinal needle used to identify location of the
176 accessory medial portal in a right knee, B) Scope in anteromedial portal and guide-pin
177 placed in the accessory medial portal for placement of the posterolateral bundle tunnel in
178 the femur of the left knee
179



180
181

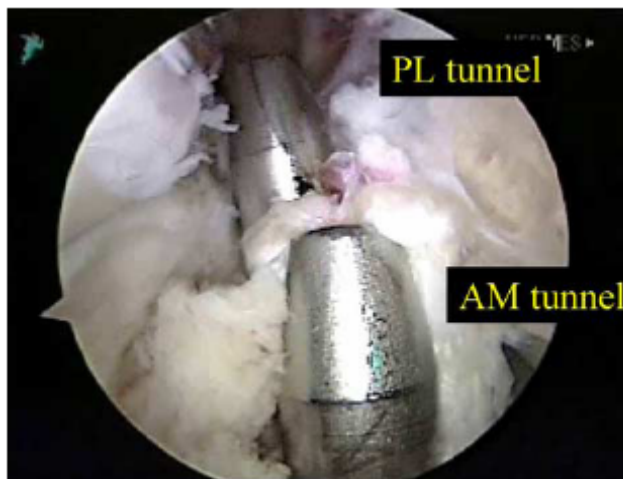
182
183
184
185

Figure 3: Arthroscopic view of the intercondylar notch of a right knee from the anterolateral portal (ALP), anteromedial portal (AMP), and accessory medial portal (MP)



186
187
188
189
190
191
192

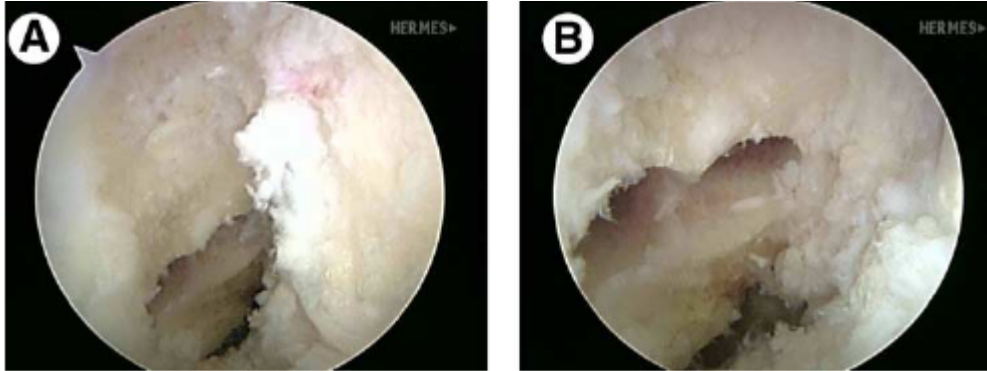
Figure 4: Arthroscopic view of the tibial plateau of a right knee through the anterolateral portal after placement of the anteromedial and posterolateral bundle tunnels in the tibia



193

194
195
196
197
198

Figure 5: Arthroscopic view of the intercondylar notch of a right knee from the anterolateral portal (A) and the anteromedial portal (B) after placement of the 2 femoral tunnels during ACL reconstruction



199
200
201
202
203
204

Table 1: Use of portals in anatomic double bundle ACL reconstruction

Portal	Viewing Advantage	Surgical Purpose	Working Portal
Anterolateral	Anatomic insertion of ACL on Tibia	Viewing tibia for tibial tunnel placement	Inside-out medial meniscal repair
Anteromedial	Anatomic insertion of ACL in Intercondylar Notch	Viewing intercondylar notch for femoral tunnel placement	Tibial guide placement for drilling AM tunnel
Accessory Medial	Anatomic insertion of ACL in Intercondylar Notch	Placement of PL and if necessary AM tunnels in femur	Tibial guide placement for drilling PL tunnel

205
206
207
208
209

Table 2: Specific portal use for anatomic double bundle ACL reconstruction

Tunnel for ACL Reconstruction	Viewing Portal	Instrument Portal
Tibia – Anteromedial Bundle	Anterolateral	Anteromedial
Tibia – Posterolateral Bundle	Anterolateral	Accessory Medial
Femur – Anteromedial Bundle	Anteromedial	Transtibial or Accessory Medial
Femur – Posterolateral Bundle	Anteromedial	Accessory Medial

210