

**Acute Heart Failure Assessment: The Role of Focused Emergency Cardiopulmonary  
Ultrasound in Identification and Early Management**

**Robinson M. Ferre, MD**

**Department of Emergency Medicine**

**Vanderbilt University**

**Ovidiu Chioncel, MD**

**Institute of Emergency for Cardiovascular Diseases**

**Bucuresti, Romania**

**Peter S. Pang, MD**

**Department of Emergency Medicine**

**Indiana University**

**Roberto M. Lang, MD**

**Noninvasive Cardiac Imaging Laboratories, Section of Cardiology**

**Department of Medicine**

**University of Chicago Medical Center**

**Mihai Gheorghide, MD**

**Division of Cardiology**

**Center for Cardiovascular Innovation**

**Northwestern University**

**Sean P. Collins, MD, MSc**

**Department of Emergency Medicine**

**Vanderbilt University**

---

This is the author's manuscript of the article published in final edited form as:

Ferre, R. M., Chioncel, O., Pang, P. S., Lang, R. M., Gheorghide, M., & Collins, S. P. (2015). Acute heart failure: the role of focused emergency cardiopulmonary ultrasound in identification and early management. *European Journal of Heart Failure*, 17(12), 1223–1227. <http://doi.org/10.1002/ejhf.421>

## **Background**

Patients presenting to the Emergency Department (ED) with acute heart failure (AHF) represent a heterogeneous group in terms of clinical presentation, pathophysiology, and prognosis, with symptoms ranging from a mild increase in their baseline exertional dyspnea to severe cardiogenic shock. Rapidly distinguishing AHF from other common causes of dyspnea is the cornerstone to appropriate management and risk-stratification. When ED physicians base their diagnosis of AHF on history and physical exam only, misdiagnosis rates may be as high as 33%.<sup>1</sup> Ancillary testing helps, but even after chest radiography and natriuretic peptide testing the diagnosis may still be unclear in 15-20% of patients.<sup>2-4</sup> Little has changed, in terms of ancillary testing, in the past two decades to help physicians in the ED rapidly diagnose and then appropriately treat AHF in the ED.

Patients with prior episodes of AHF have undergone assessment of left ventricular performance and are characterized as having a reduced LVEF (HFrEF) or preserved LVEF (HFpEF) based on this. This information was often obtained once hospitalized after the ED phase of management, providing little help to physicians who are involved with the initial diagnosis and management of the patient. We believe a focused bedside ultrasound assessment during an AHF episode at the time of ED presentation would assist with acute management, improve ED diagnostic accuracy, and direct initial therapeutic decisions in these complex patients who present with undifferentiated symptoms.

The ACCF/AHA Heart Failure Guidelines state that 2-D ECHO with Doppler is the most important diagnostic test to answer three fundamental questions: 1) Is the LVEF preserved or

reduced? 2) Is structure normal or abnormal? 3) Are there other structural abnormalities that might contribute to the HF?<sup>5</sup> While these recommendations were not intended for the ED setting, we hypothesize that such knowledge could have potentially important diagnostic and therapeutic value in the ED (**Table 1**). Indeed, a recent consensus document suggests focused cardiac ultrasound should be used to establish the diagnosis of AHF and its potential etiologies.<sup>6</sup> The European Association of Cardiovascular Imaging (EACVI) recognizes the utility of clinician performed focused cardiac ultrasound in the ED and intensive care unit as an important and viable way to assess patients who present with signs or symptoms of cardiac dysfunction. Knowledge of LV function and identification of specific cardiac structural abnormalities, such as severe mitral regurgitation or aortic stenosis, are important for clinicians when choosing the initiation and type of IV vasoactive therapies for patients presenting with AHF. Identification of other conditions, including pericardial or pleural effusion would also change the therapeutic approach.

Regardless of when or where patients present with AHF, a standard approach for diagnosing and treating AHF is important. Many precipitants and etiologies are established with laboratory testing (infarction, worsening renal function), chest radiography (pneumonia) and clinical history (dietary and medication indiscretion). However, clinician performed bedside cardiopulmonary ultrasound allows the clinician to identify the relevant pathophysiology, identify other precipitants and etiologies, and assess the heart from a physiologic perspective. Therefore, we believe a strategic approach that is generalizable and can be accomplished rapidly in the ED is necessary.

**Rapid Assessment of Pulmonary Congestion, Central Venous Filling Pressures and Ejection Fraction in Dyspneic ED Patients using Cardiopulmonary Ultrasound.**

We suggest a new paradigm in the approach to the patient who presents with signs and symptoms of AHF, one that uses EP performed bedside ultrasound measures of left ventricular performance and congestion to not only diagnose AHF, but to tailor treatment and disposition decisions. This focused approach, incorporated into the traditional ED work-up, is referred to as the **C**ardiopulmonary **A**ssessment in **R**eal-time to **D**etermine **D**iastric and **S**ystolic function with **S**onography (CARDDSS) exam. **(Figure 1)**

As part of the CARDDSS exam, we propose **four** step-by-step sonographic elements that can help differentiate AHF from other causes of dyspnea by assessing for pulmonary edema, central venous congestion, assessing for elevated left ventricular end diastolic pressure (LVEDP) and broadly differentiating between HFrEF and HFpEF.

#### Step 1: Pulmonary Ultrasound to assess for pulmonary vascular congestion:

Pulmonary ultrasound has been well described in the emergency and critical care literature in patients with dyspnea and respiratory failure<sup>7-10</sup> and has been shown to be accurate in detecting AHF with reported sensitivities of 86-100% and specificities of 95-98%.<sup>9,10</sup> Lungs that have increased interstitial or alveolar edema produce characteristic sonographic comet tail artifacts known as B-lines that arise from the visceral-parietal lung interface, extend to the bottom of the viewing field, move with respiration, are less than 7mm apart and erase the reverberation artifacts referred to as A-lines. Lungs that have 3 or more B-lines per viewing field are pathologic and constitute a condition known as alveolar interstitial syndrome (AIS) which can be focal and unilateral (e.g. pneumonia) or diffuse and bilateral (e.g. pulmonary edema). Any condition that causes fluid buildup in the lymphatic interlobular septae at the pleural surface will cause AIS. Thus limiting the ability of pulmonary ultrasound alone to discriminate between AHF from other causes of pulmonary edema.

#### Step 2: IVC size and collapsibility to estimate CVP:

Sonographic assessment of IVC size and collapsibility is the most frequently used non-invasive technique for estimation of right sided filling pressures.<sup>11</sup> It is routinely performed with the patient in a supine position at end expiration and during a deep inhalation<sup>12</sup>. Using these parameters, IVC size and Collapsibility Index (CI = IVCD max- IVCD min/IVCD max) have been shown in a number of studies to correlate with right atrial pressure,<sup>13</sup> pulmonary capillary wedge pressure,<sup>12</sup> and risk for hospital readmission for AHF.<sup>14</sup>

IVC size and collapsibility is known to vary as much as 40% based on patient positioning alone. Fortunately, studies by EPs of ED patients in an upright position suggest the IVC collapsibility index yields strong diagnostic accuracy to predict AHF with optimal cut-off values of 1 cm for maximal IVC diameter and a CI of less than 15-33%.<sup>15-17</sup>

### Step 3: Doppler Interrogation of Left sided filling pressures

The American and European cardiology and echocardiography societies recommend tissue Doppler (TD) be used in combination with MV inflow velocities to determine if patients with normal systolic function have AHF.<sup>18</sup> Tissue and flow Doppler provides non-invasive measures of the driving pressure needed to move blood into the LV. Early diastolic lengthening velocities (e'), measured and averaged at the septal and lateral portion of the MV annulus, used in combination with peak early (E) flow velocities across the mitral valve have been used to identify elevated LVEDP. The ratio of "E" to "e'" (E/e') correlates closely with LV filling pressures. There is a strong correlation in patients with HFpEF, and a moderate correlation in HFrEF, when E/e' > 15.<sup>19</sup>

Performing and interpreting MV inflow and TD patterns is the most difficult part of our proposed algorithm and is beyond the scope of many EPs who are not trained to perform this type of exam. We expect most of the subjects in our proposed algorithm will have AHF diagnosed prior

to proceeding to this step and thus will not need Doppler interrogation of MV inflow velocities. However, studies done by EP have found this to be feasible and accurate.

#### Step 4: Differentiating between preserved and reduced LVEF

Once the diagnosis of AHF has been established, assessment of LV function should differentiate between the two different phenotypes of AHF. Various M-mode methods of LVEF estimation including E-point septal separation, mitral annular plane systolic excursion, fractional shortening, and visual estimation are established methods EP have used to estimate LVEF. Thus, LVEF estimations are placed in broad categories of normal, moderately reduced and severely reduced<sup>20-22</sup> according to recommendations by both the American College of Emergency Physicians (ACEP) and the American Society of Echocardiography (ASE).<sup>21</sup>

From a theoretical perspective, initial treatment of AHF patients with HFpEF should be different than those with HFrEF. Patients with HFpEF have higher filling pressures as a result of ventricular stiffness, rather than volume overload, which may be seen more often in patients with HFrEF. AHF patients with hypertension, many of whom have HFpEF, have a pathophysiology that is dominated by fluid redistribution into the lower pressure pulmonary vascular bed rather than an absolute increase in intravascular volume.<sup>23-25</sup> As a result, aggressive use of vasodilators in patients with HFpEF to decrease ventricular preload and afterload is key to improving cardiac output and removing fluid from the pulmonary vascular bed. Many patients with HFrEF cannot tolerate benefit from diuresis, but aggressive vasodilation could result in hypotension.

### **Training and Competency in Performing and Interpreting Focused Cardiopulmonary Ultrasound**

In the past decade, training and use of ultrasound by clinicians of many different specialties has dramatically increased. EACVI supports the use of focused and goal directed cardiac ultrasound

(referred to as FoCUS by EACVI) in the evaluation of patients presenting with signs and symptoms of acute cardiac dysfunction regardless of specialty, as long as these physicians have received appropriate training.<sup>26,27</sup> Similarly, ACEP and ASE have also established guidelines that support using focused cardiac ultrasound in the ED.<sup>28-14</sup> These and other professional societies have recognized the value that ultrasound provides to clinicians during the early stages of diagnosis and treatment of multiple diseases, including AHF. Focused cardiac ultrasound is by nature limited, goal directed and focused. It is not a replacement for comprehensive echocardiography, but rather serves as a means to improve the efficiency and accuracy of care in the ED when patients present with signs and symptom of acute cardiac dysfunction.

### **Future Investigations with Focused ED Ultrasound**

While preliminary data suggests our conceptual model may improve patient care in ED patients with AHF, we propose 3 formal investigations to quantify this impact. First, a diagnostic algorithm, such as the one we propose, should be compared with the traditional “clinical assessment” model of EP diagnosis. This would allow quantification of the incremental improvement in diagnostic accuracy provided by bedside ultrasound. Second, once patients have been diagnosed as AHF, goal directed therapy can be assessed. The impact of diuretics and vasodilators on patient’s ultrasound findings of congestion could be followed over time. Preliminary data suggests vasodilators may be more beneficial in patients with HFpEF, but changes in cardiac function and congestion on ultrasound would help delineate the most efficacious approach. Our third and final proposed study would evaluate the incremental prognostic information obtained on bedside ultrasound in the ED. While prior and in-hospital EF and natriuretic peptides have been shown to be prognostic, measures of LVEF and congestion based on bedside ultrasound have not been incorporated into risk models or ED-based decision making. Comparing ED-based decision making with and without knowledge of ultrasound

findings, and incorporating these findings into predictive instruments would be important to quantify.

## **Conclusion**

In summary, knowledge of initial cardiac structure, function, and hemodynamics in ED patients with AHF may have an impact on diagnostic accuracy, treatment selection, and perhaps risk-stratification. It may also contribute to identification of AHF etiologies and precipitants. We suggest a combined approach of clinical examination, laboratory testing, chest radiography, and focused cardiopulmonary ultrasound examinations following the steps outlined in the proposed CARDDSS exam. This proposed algorithm, while in need of prospective testing, can be performed rapidly at the bedside and may improve the management and outcomes of patients in the ED with AHF.



Table 1. Comparison of focused ED cardiac ultrasound with comprehensive echocardiography.

	<b>ECHO Modalities</b>	<b>Goals of ECHO</b>	<b>Limitations</b>
<b>ED Presentation</b>	<i>Focused</i> -TTE M Mode, Color and Spectral Doppler, TDI	-Diagnosis of AHF -Initiation of therapies -Disposition Decisions	-Not comprehensive -only qualitative assessments (present or absent) -Patient cooperation may be difficult -Not ECG gated
<b>In-hospital management</b>	<i>Comprehensive</i> -TTE and TEE M Mode, Color and Spectral Doppler, TDI, Speckle tracking, RT3DE	-HF Etiology -Detection of Ischemia or new focal wall motion abnormalities -Detection of contractile reserve -Candidates for cardiac surgery -Candidates for devices	-Costs -Availability of technologists and time to perform test -Inability to send unstable patients to ECHO suite

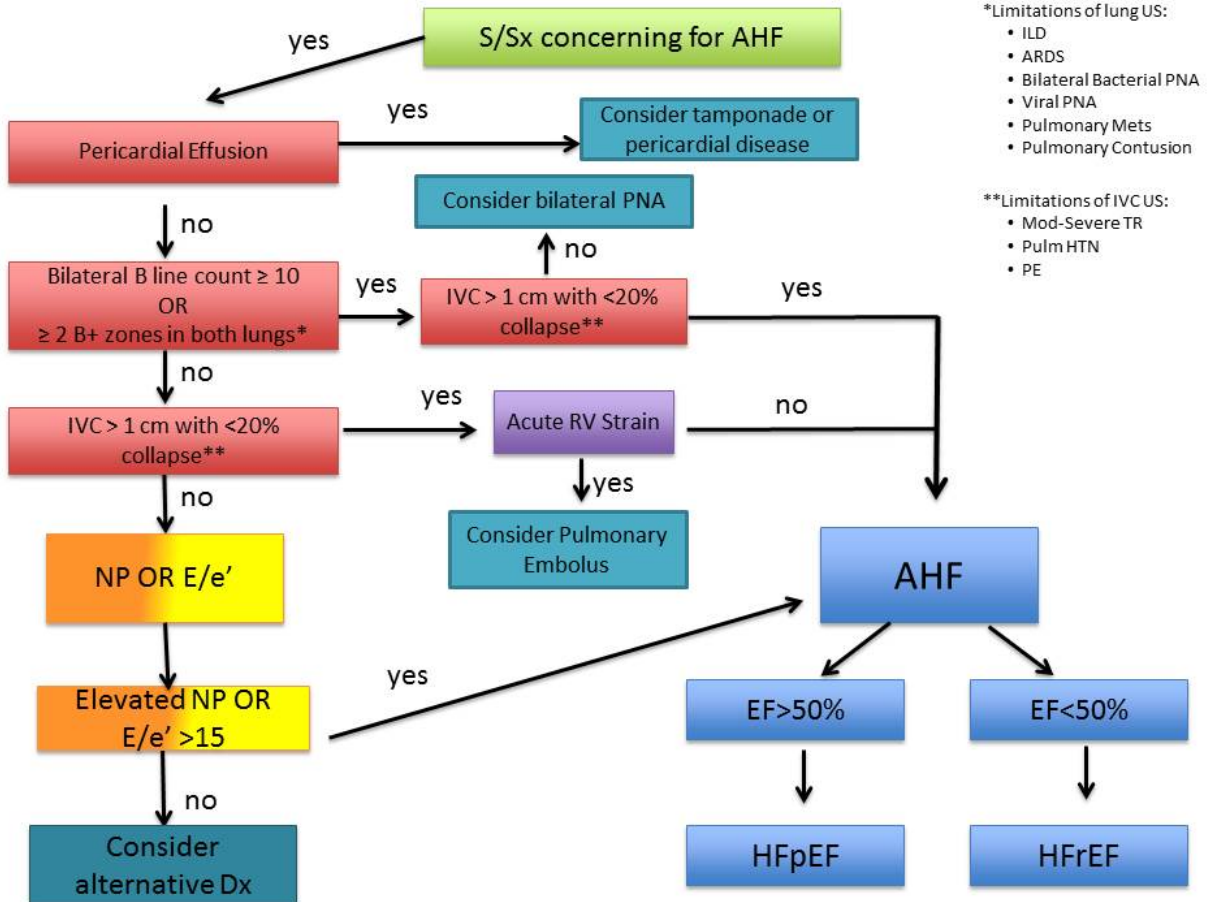
TTE – transthoracic echocardiogram; TEE- transesophageal echocardiogram; TDI- tissue Doppler index; RT3DE- real time three dimensional echocardiography

Table 3. Interpreting results of the CARDDSS exam to assist with differentiating AHF from other acute pathophysiology, as well as characterizing the underlying pathophysiology in AHF.

	P	I	E/e'>15	EF<45
Chronic HF, check BNP	-	-	-	+
PE,RV MI, congenital	-	+	+	-
RV dysf>LV dysf	-	+	+/-	+
LV dysf+low volume status	-	-	+	+
Acute MR	+	-	+	-
Noncardiac	+	-	-	-
Chronic LV decompensation	+	-	-	+
Right decompensation with pre-existing LV decompensation	-	+	-	+
AHF Unlikely	-	-	+/-	-

PE- pulmonary embolism; RV- right ventricular; LV- left ventricular; MR- mitral regurgitation; AHF- acute heart failure

Figure 1. Proposed CARDDSS algorithm for determining signs of AHF and HFpEF or HFrEF in dyspneic ED patients.



## References

1. Mebazaa A, Pang PS, Tavares M, et al. The impact of early standard therapy on dyspnoea in patients with acute heart failure: the URGENT-dyspnoea study. *European heart journal*. Apr 2010;31(7):832-841.
2. Collins SP, Lindsell CJ, Storrow AB, Abraham WT. Prevalence of negative chest radiography results in the emergency department patient with decompensated heart failure. *Annals of emergency medicine*. Jan 2006;47(1):13-18.
3. Maisel AS, Krishnaswamy P, Nowak RM, et al. Rapid measurement of B-type natriuretic peptide in the emergency diagnosis of heart failure. *The New England journal of medicine*. Jul 18 2002;347(3):161-167.
4. Collins SP, Peacock WF, Lindsell CJ, et al. S3 detection as a diagnostic and prognostic aid in emergency department patients with acute dyspnea. *Annals of emergency medicine*. Jun 2009;53(6):748-757.
5. Hunt SA, Abraham WT, Chin MH, et al. 2009 focused update incorporated into the ACC/AHA 2005 Guidelines for the Diagnosis and Management of Heart Failure in Adults: a report of the American College of Cardiology Foundation/American Heart Association Task Force on Practice Guidelines: developed in collaboration with the International Society for Heart and Lung Transplantation. *Circulation*. Apr 14 2009;119(14):e391-479.
6. Via G, Hussain A, Wells M, et al. International evidence-based recommendations for focused cardiac ultrasound. *J Am Soc Echocardiogr*. Jul 2014;27(7):683 e681-683 e633.
7. Volpicelli G, Caramello V, Cardinale L, Mussa A, Bar F, Frascisco MF. Bedside ultrasound of the lung for the monitoring of acute decompensated heart failure. *Am J Emerg Med*. Jun 2008;26(5):585-591.
8. Volpicelli G, Cardinale L, Garofalo G, Veltri A. Usefulness of lung ultrasound in the bedside distinction between pulmonary edema and exacerbation of COPD. *Emergency radiology*. May 2008;15(3):145-151.
9. Volpicelli G, Mussa A, Garofalo G, et al. Bedside lung ultrasound in the assessment of alveolar-interstitial syndrome. *Am J Emerg Med*. Oct 2006;24(6):689-696.
10. Lichtenstein DA, Meziere GA. Relevance of lung ultrasound in the diagnosis of acute respiratory failure: the BLUE protocol. *Chest*. Jul 2008;134(1):117-125.
11. Milan A, Magnino C, Veglio F. Echocardiographic indexes for the non-invasive evaluation of pulmonary hemodynamics. *J Am Soc Echocardiogr*. Mar 2010;23(3):225-239; quiz 332-224.
12. Blair JE, Brennan JM, Goonewardena SN, Shah D, Vasaiwala S, Spencer KT. Usefulness of hand-carried ultrasound to predict elevated left ventricular filling pressure. *Am J Cardiol*. Jan 15 2009;103(2):246-247.
13. Brennan JM, Blair JE, Goonewardena S, et al. A comparison by medicine residents of physical examination versus hand-carried ultrasound for estimation of right atrial pressure. *Am J Cardiol*. Jun 1 2007;99(11):1614-1616.
14. Goonewardena SN, Gemignani A, Ronan A, et al. Comparison of hand-carried ultrasound assessment of the inferior vena cava and N-terminal pro-brain natriuretic peptide for predicting readmission after hospitalization for acute decompensated heart failure. *JACC. Cardiovascular imaging*. Sep 2008;1(5):595-601.

15. Blehar DJ, Dickman E, Gaspari R. Identification of congestive heart failure via respiratory variation of inferior vena cava diameter. *Am J Emerg Med.* Jan 2009;27(1):71-75.
16. Miller JB, Sen A, Strote SR, et al. Inferior vena cava assessment in the bedside diagnosis of acute heart failure. *Am J Emerg Med.* Jun 2012;30(5):778-783.
17. Anderson KL, Jenq KY, Fields JM, Panebianco NL, Dean AJ. Diagnosing heart failure among acutely dyspneic patients with cardiac, inferior vena cava, and lung ultrasonography. *Am J Emerg Med.* Aug 2013;31(8):1208-1214.
18. Nagueh SF, Appleton CP, Gillebert TC, et al. Recommendations for the evaluation of left ventricular diastolic function by echocardiography. *European journal of echocardiography : the journal of the Working Group on Echocardiography of the European Society of Cardiology.* Mar 2009;10(2):165-193.
19. Dokainish H, Nguyen JS, Bobek J, Goswami R, Lakkis NM. Assessment of the American Society of Echocardiography-European Association of Echocardiography guidelines for diastolic function in patients with depressed ejection fraction: an echocardiographic and invasive haemodynamic study. *European journal of echocardiography : the journal of the Working Group on Echocardiography of the European Society of Cardiology.* Nov 2011;12(11):857-864.
20. Jones AE, Tayal VS, Kline JA. Focused training of emergency medicine residents in goal-directed echocardiography: a prospective study. *Acad Emerg Med.* Oct 2003;10(10):1054-1058.
21. Labovitz AJ, Noble VE, Bierig M, et al. Focused cardiac ultrasound in the emergent setting: a consensus statement of the American Society of Echocardiography and American College of Emergency Physicians. *J Am Soc Echocardiogr.* Dec 2010;23(12):1225-1230.
22. Moore CL, Rose GA, Tayal VS, Sullivan DM, Arrowood JA, Kline JA. Determination of left ventricular function by emergency physician echocardiography of hypotensive patients. *Acad Emerg Med.* Mar 2002;9(3):186-193.
23. Fallick C, Sobotka PA, Dunlap ME. Sympathetically mediated changes in capacitance: redistribution of the venous reservoir as a cause of decompensation. *Circ Heart Fail.* Sep 2011;4(5):669-675.
24. Cotter G, Felker GM, Adams KF, Milo-Cotter O, O'Connor CM. The pathophysiology of acute heart failure--is it all about fluid accumulation? *American heart journal.* Jan 2008;155(1):9-18.
25. Cotter G, Metra M, Milo-Cotter O, Dittrich HC, Gheorghide M. Fluid overload in acute heart failure--re-distribution and other mechanisms beyond fluid accumulation. *Eur J Heart Fail.* Feb 2008;10(2):165-169.
26. Neskovic AN, Edvardsen T, Galderisi M, et al. Focus cardiac ultrasound: the European Association of Cardiovascular Imaging viewpoint. *European heart journal cardiovascular Imaging.* Sep 2014;15(9):956-960.
27. Neskovic AN, Hagendorff A, Lancellotti P, et al. Emergency echocardiography: the European Association of Cardiovascular Imaging recommendations. *European heart journal cardiovascular Imaging.* Jan 2013;14(1):1-11.
28. Emergency ultrasound imaging criteria compendium. American College of Emergency Physicians. *Annals of emergency medicine.* Oct 2006;48(4):487-510.