

Published in final edited form as:

Neurogastroenterol Motil. 2015 February ; 27(2): 201–211. doi:10.1111/nmo.12464.

Esophageal Acid Stimulation Alters Insular Cortex Functional Connectivity in Gastroesophageal Reflux Disease

Robert M. Siwiec[#], Arash Babaei^{*}, Mark Kern^{*}, Erica A. Samuel^{*}, Shi-Jiang Li[†], and Reza Shaker^{*}

[#]Department of Medicine, Division of Gastroenterology & Hepatology, Indiana University School of Medicine, Indianapolis, IN

^{*}Department of Medicine, Gastroenterology & Hepatology, Medical College of Wisconsin, Milwaukee, WI

[†]Department of Biophysics, Medical College of Wisconsin, Milwaukee, WI

Abstract

Background—The insula plays a significant role in the interoceptive processing of visceral stimuli. We have previously shown that GERD patients have increased insular cortex activity during esophageal stimulation, suggesting a sensitized esophago-cortical neuraxis. However, information regarding the functional connectivity (FC) of the insula during visceral stimulation is lacking. The primary aim of this study was to investigate the FC of insular subregions during esophageal acid stimulation.

Methods—Functional imaging data was obtained from 12 GERD patients and 14 healthy subjects during four steady state conditions: (1) presence of transnasal esophageal catheter (pre-infusion); (2) neutral solution; (3) acid infusion; (4) presence of transnasal esophageal catheter following infusions (post-infusion). The insula was parcellated into 6 regions of interest (ROI). FC maps between each insular ROI and interoceptive regions were created. Differences in FC between GERD patients and healthy subjects were determined across the 4 study conditions.

Key Results—All GERD patients experienced heartburn during and after esophageal acidification. Significant differences between GERD patients and healthy subjects were seen in: (1) insula-thalamic FC (neutral solution infusion, acid infusion, post-infusion); (2) insula-amygdala FC (acid infusion, post-infusion); (3) insula-hippocampus and insula-cingulate FC (post-infusion).

Conclusions & Inferences—Esophageal stimulation in GERD patients revealed significant insular cortex FC differences with regions involved in viscerosensation and interoception. The

CORRESPONDING AUTHOR. Reza Shaker, MD, Division of Gastroenterology and Hepatology, Medical College of Wisconsin, 9200 West Wisconsin Avenue, Milwaukee, WI 53226, Phone: 414-955-6840, Fax: 414-955-6215, rshaker@mcw.edu.

The authors have no conflict of interest to disclose.

AUTHOR CONTRIBUTIONS

Robert M. Siwiec and Arash Babaei contributed to data acquisition, analysis and interpretation of the data, drafting of the manuscript, and critical revision of the manuscript.

Mark Kern, Erica A. Samuel, and Shi-Jiang Li contributed to study design, statistical analysis, interpretation of the data, and manuscript revision.

results of our study provide further evidence that the insula, located at the transition of afferent physiologic information to human feelings, is essential for both visceral homeostasis and the experience of heartburn in GERD patients.

Keywords

INTRODUCTION

Gastroesophageal reflux disease (GERD) is the most common malady of the esophagus with heartburn being the predominant symptom (1). The esophagus is innervated by vagal afferents and visceral spinal afferents that transmit stimuli to specific centers within the central nervous system (2). Animal studies have shown the existence of acid sensitive afferents in the esophagus (3–5) and human studies utilizing functional magnetic resonance imaging (fMRI) have documented cerebral cortical activity in response to unperceived esophageal acidification in healthy individuals (6, 7). Functional neuroimaging studies examining esophageal chemical stimulation in GERD patients have shown increased cortical recruitment and activity within the insula compared to healthy subjects (8–10), suggesting sensitization along the esophago-cortical neuraxis (11). Despite these findings, many questions regarding esophageal sensory physiology and cortical processing, especially with regards to chemical esophageal stimulation and heartburn perception in patients with GERD, remain unanswered.

Functional neuroimaging studies of visceral sensation and pain have utilized classic stimulus based paradigms to identify brain regions involved in interoceptive processing (6, 12–16). Although this “localizationist/modular” approach has provided insight into which regions are active during visceral stimulation, little to no information regarding the interactions of these brain regions and specialized networks has been gained (17). Functional connectivity (FC) analysis measures changes in temporal correlations of blood oxygenated level dependent (BOLD) signal of various brain regions (18). Biswal *et al.* were the first to demonstrate that the BOLD signal time series from the motor cortex was strongly and significantly correlated with the contralateral and midline regions within the motor system during rest (19). Combined diffusion-based and resting-state functional methodologies have provided evidence that BOLD signal correlations between cortical regions are mediated by both direct and indirect anatomical projections (20). With the advent of these techniques, study of the interactions between brain regions involved in human visceral sensation is now within reach.

The insula is considered a central brain region in sensorimotor, visceral, interoceptive processing, homeostatic functions, and emotional awareness of self, interacting with various limbic regions including the amygdala and hippocampus (21). Distinctions between regions of the insula along the rostral-caudal axis have been described by Craig, proposing that bilateral midposterior insular cortices receive interoceptive information about the physiological state of the body via afferent input from medial thalamic nuclei (22, 23). This information is then projected to regions involved in subjective evaluations of internal physiologic conditions as well emotional awareness and affective response (24).

Although increased cortical recruitment within the insular cortex during esophageal stimulation in patients with GERD has previously been reported (8–10), the FC properties of the insula in patients with GERD have not been investigated. The overarching hypothesis for the present study was that chronic acid exposure in patients with GERD leads to a sensitized esophago-cortical neuraxis resulting in altered insular FC patterns compared to healthy controls. The primary aim of the study was to investigate the FC of insular subregions with previously implicated cortical areas involved in interoceptive homeostatic and emotional processing in patients with GERD during esophageal stimulation.

MATERIALS AND METHODS

The present study was designed to determine FC changes of insular subregions in GERD patients when the esophageal mucosa is exposed to acid. We proposed that the effects of acid play a pivotal role in the pathophysiology of GERD beyond just mucosal injury. Therefore, we targeted GERD patients with healed esophagitis in order to avoid interference of mucosal injury and specifically focused on the esophago-cortical neuraxis. It is known that infusion of a neutral solution produces mechanical distention similar to acid infusion but without the chemical effects; thus, the neutral infusion scan was utilized as the main control for acid infusion in the present study. The delivery of these solutions requires presence of a nasoesophageal tube. Nasoesophageal intubation could potentially affect the FC of insular subregions. Therefore, we considered the presence of the nasoesophageal tube as our implicit baseline and acquired pre-infusion and post-infusion data, accounting for the lingering effects of acid on the esophago-cortical neuraxis.

Study Participants

Twelve GERD patients (age: 32 ± 11 years, range 20 – 55 years, 6 females) and fourteen healthy subjects (age : 27 ± 14 years, range 21 – 42 years, 7 females) participated in the study. All study participants were evaluated by a personal interview, physical examination, upper endoscopy, GERD symptom questionnaire, and detailed health questionnaire. Inclusion into the GERD group required typical GERD symptoms of either heartburn or acid regurgitation as well as endoscopic evidence of erosive esophagitis within one year of study participation. At the time of study enrollment all GERD patients were well-controlled on acid suppressive therapy and were asymptomatic. Exclusion criteria included history of upper gastrointestinal surgery, Barrett's esophagus, peptic ulcer disease, diabetes mellitus, functional gastrointestinal disorders, psychiatric or neurological disorders, and daily usage of agents that are known to interfere with BOLD response (e.g. psychotropic medications, beta-blockers, caffeine). The Institutional Review Board Committee at the Medical College of Wisconsin approved the study and all study participants provided written informed consent before the study.

MRI Scanning

All MR images were acquired using a 3.0-Tesla General Electric Signa LX scanner (General Electric Medical Systems, Waukesha, WI) equipped with an eight-channel receiver head coil and body quadrature transmit radiofrequency coil. Cardiorespiratory monitoring during scanning was performed with a pulse oximeter and respiratory bellows equipment at a

sampling rate of 40 Hz. Anatomical scans were acquired using a high-resolution spoiled gradient recalled (SPGR) acquisition technique consisting of 120 sagittal whole brain 1.2 mm thick slices over a 240 mm field of view and 256×256 within-slice pixel resolution. These high-resolution anatomic images were used for subsequent superposition of cortical maps derived from the echo planar BOLD contrast images.

Study Protocol

Before placing study participants in the MRI scanner, the location of the lower esophageal sphincter (LES) was determined by either manometry or transnasal endoscopy (25, 26). A double lumen 2.4 mm external diameter catheter was inserted transnasally such that the side-hole perfusion ports were positioned 5–7 cm above the upper border of the lower esophageal sphincter. Each perfusate (i.e. neutral solution and acid) had its own dedicated perfusion port throughout the duration of the study. We waited fifteen minutes until volunteers became accustomed to the transnasal catheter prior to acquiring imaging data.

fMRI data was acquired using T2-weighted echo planar imaging (EPI) (34 interleaved sagittal slices without a gap, FOV = 24 cm, 64×64 matrix, $3.75 \times 3.75 \times 4$ mm voxels, TE = 23.4 ms, TR = 2000 ms) during 4 study conditions: 1) pre-infusion with a nasoesophageal catheter; 2) esophageal neutral solution (phosphate buffered saline (PBS) with pH = 7.4 at 1 mL min^{-1}); 3) esophageal acid infusion (0.1 N hydrochloric acid (HCl) with pH = 1.4 at 1 mL min^{-1}); 4) post-infusion with the nasoesophageal catheter. The scan time for each study condition was 9 minutes (270 repetitions). Study participants were instructed to relax, keep their eyes closed, and think of nothing in particular during scanning. Heartburn severity before and after each functional MRI scan was assessed with a 10-point Likert scale (1 = no heartburn, 10 = severe heartburn).

fMRI Analysis

All fMRI data were preprocessed and analyzed using Analysis of Functional Neuroimages (AFNI) software package (27). Preprocessing steps included correcting for respiratory and cardiovascular related signal changes as well as linear trend removal (28). fMRI datasets were interpolated to $2 \times 2 \times 2$ mm voxels (29), registered to the high resolution anatomical image using a 12-degrees of freedom registration (30), and normalized to the Talairach-Tournoux atlas (31, 32). fMRI BOLD signal trend components were independently removed over the course of the time series on a voxel by voxel basis using linear least squares. Undesirable signal changes related to white matter, cerebral spinal fluid (CSF), and global noise were regressed out as signals of non-interest (33, 34). Residual times series were spatially blurred to a full-width-half-maximum (FWHM) Gaussian kernel of 6 mm and temporally smoothed to a target frequency range of 0.015 – 0.1 using Fourier transformation bandpass filtering.

After preprocessing, regions of interest (ROI) within the insula were identified anatomically *a priori* and based on prior published studies of esophageal and visceral stimulation (35–40). The bilateral insular ROIs included the following: dorsal posterior, dorsal middle, dorsal anterior, ventral posterior, ventral middle, and ventral anterior. For each insular ROI, a

representative BOLD time-course was obtained by averaging the signals of the voxels within a sphere of 5 mm radius on a single subject basis.

The FC between insular ROIs and bilateral regions involved in interoceptive homeostatic and emotion processing (thalamus, anterior cingulate cortex, middle cingulate cortex, amygdala, and hippocampus) was characterized in GERD patients and healthy volunteers across all study conditions. The Pearson product moment correlation coefficient was calculated from the blood oxygen level dependent (BOLD) time series between each insular ROI and target interoceptive regions (Figure 1). Fisher's r -to- z transformation was applied to normalize FC values across study groups and voxel-wise comparison using unpaired t -tests was carried out to identify differences between the study groups. Results were corrected for multiple comparisons using a minimal cluster volume threshold of 57 mm³ of contiguous voxels with uncorrected p -value < 0.005 . Clusters with significant difference (corrected $p < 0.05$) were superimposed on a standardized anatomical image in Talairach-Tournoux space to visually depict topographic location of insula seed region and target cluster.

RESULTS

All study participants completed the study protocol with no adverse events. None of the healthy subjects developed heartburn during any of the study conditions. The GERD patients had no heartburn at the time of study initiation and after the pre-infusion and neutral infusion scans. All GERD patients, however, developed heartburn during acid infusion as evidenced by a mean Likert score of 5.2 with range of 3 to 8. Following the post-infusion scan, 11 of 12 GERD patients continued to have heartburn (mean Likert score = 3.2, range = 2 – 5).

Insula-Thalamic Connectivity

The right dorsal middle insula demonstrated significantly greater connectivity ($p < 0.05$) with both the right and left medial thalamus during neutral solution infusion, acid infusion, and post-infusion in GERD patients compared to healthy subjects (Figure 2A). Figure 2B depicts the mean connectivity Z-scores for each group between the right dorsal middle insula and the right and left thalamus across all four study conditions. The right and left ventral posterior insula demonstrated significantly greater connectivity with the left medial thalamus but only during acid infusion and post-infusion (Figure 3A and 3B, respectively). No significant differences in insula-thalamic FC properties were found between the groups during the pre-infusion period.

Insula-Amygdala Connectivity

During the acid infusion and post-infusion scans, connectivity between the right ventral posterior insula and the right amygdala (Figure 4A) was significantly greater in the GERD patients than in the healthy subjects ($p < 0.05$). The right dorsal posterior insula also demonstrated significant FC differences with the right amygdala between GERD patients and healthy subjects but only during esophageal acid infusion ($p < 0.05$) (Figure 4B).

Significant between group differences in insula-amygdala connectivity, however, were not found during the pre-infusion and neutral solution infusion scans.

Insula-Hippocampus and Insula-Cingulate Connectivity

No significant between group FC differences were found between the insula and hippocampus as well as between the insula and cingulate during the pre-infusion, neutral solution infusion, and acid infusion scans. During the post-infusion scan, three insular regions of interest demonstrated significant connectivity differences between GERD patients and healthy subjects (Figure 5). FC between the left ventral anterior insula and left hippocampus was significantly greater in GERD patients compared to healthy subjects ($p < 0.05$) (Figure 5A). Similarly, FC between the right dorsal anterior insula and right hippocampus was significantly greater in the GERD patients than in the healthy subjects ($p < 0.05$) (Figure 5B). FC between the right dorsal middle insula and right hippocampus was significantly different between the groups during the post-infusion scan ($p < 0.05$) (Figure 5C). Lastly, FC between the right ventral posterior insula and the right anterior cingulate was significantly greater ($p < 0.05$) in the GERD patients following acid infusion (i.e. post-infusion) (Figure 6).

DISCUSSION

The present study investigated the FC of insular subregions with previously implicated regions involved in viscerosensation and interoceptive processing. GERD patients and healthy subjects did not demonstrate any significant FC differences prior to esophageal stimulation (i.e. pre-infusion scan). Insular-thalamic FC differences between GERD patients and healthy subjects were found during neutral solution infusion, acid infusion, and post-infusion. Insular-cortical and insular-limbic FC differences were also found between the groups but only during or after esophageal acid stimulation. Figure 7 provides a schematic map of the significant FC differences found between GERD patients and healthy subjects during the different study conditions. Esophageal stimulation with either neutral solution or acid affects bilateral medial thalamic connectivity with the insula. However, during and after acid infusion, the majority of connectivity differences with the insula are lateralized to the right hemisphere. These results provide further evidence for an altered esophago-cortical neuraxis in patients with GERD and demonstrate the functional differentiation and lateralization within the human insula.

Information regarding the internal physiological milieu of the body is transmitted to the brain through a lamina-I spinothalamocortical pathway (22). Sympathetic afferents that innervate all tissues of the body provide input to lamina-I while parasympathetic afferents send input to the nucleus tractus solitarius via the vagus nerve. A direct projection from lamina-I to bilateral medial thalamic nuclei represents all homeostatic afferent input that is then projected to both posterior and middle insula (23). Information from here is then represented in the anterior insula (24) in addition to being projected to other cortical regions that have been implicated in viscerosensation and affective processing including the anterior and middle cingulate cortex, amygdala, and hippocampus.

The insula has been implicated in both interoceptive homeostatic and affective functions as well as sensorimotor processing. The insula plays an integrative role in the perception of afferent interoceptive information that is crucial for the maintenance of body integrity (21). Previous studies have shown that the insula is organized in a hierarchical fashion in a caudal-rostral direction, whereby primary sensory inputs projecting to the posterior insula, including those from the viscera, are progressively elaborated and integrated across modalities in the middle and anterior insula (35). Neuroimaging studies have elucidated the role the insula plays in cortical processing of esophageal pain and stimulation (14,16) as well as its involvement in cortical sensitization during esophageal acidification (41). Taken together, the insula is a key component in the neural circuitry responsible for processing visceral sensations and interoceptive information from the esophagus.

Variations in pulse rate (42) or respiratory rate (43) as markers of autonomic nervous system activity state have been shown to significantly affect resting state FC patterns of the brain (44). The recording of stimulus independent skin conductance response as an index of autonomic arousal state has been shown to significantly correlate with FC between the posterior cingulate cortex and ventromedial prefrontal cortex as well as between the anterior cingulate and anterior insula (45). The anterior insula and the anterior cingulate cortex have both been implicated in general monitoring and control of autonomic nervous activity (46). Regarding sympathetic associated brain regions, measurement of thermo-neutral skin sympathetic nerve activity has been shown to correlate with the ventromedial thalamus, bilateral anterior insula, orbitofrontal cortex, precuneus, and bilateral anterior mid-cingulate cortex (47). Although vagal nerve stimulation studies have shown significant variability, activations in the medulla/brainstem, limbic regions (insula, anterior cingulate cortex, hippocampus, amygdala, and hypothalamus), thalamus, cerebellum, and periaqueductal grey (PAG) were most commonly observed (48). Our study findings demonstrate consistency with these studies in which the insula serves as the cortical gateway for interoceptive information.

Liminal acid stimulation and subliminal esophageal distention by neutral solution infusion both affected insular-thalamic FC in GERD patients compared to healthy subjects. The amygdala has been known as an important region in forming the “stress response” or “emotional affective response” (49). Significant differences in insular-amygdala connectivity were found during and after acid infusion, times when GERD patients developed and experienced heartburn. Altered FC between the insula and the hippocampus occurred only during the post-infusion condition, which was accompanied by a gradual resolution of perceived heartburn. This can be attributed to the hippocampus’ role in pain processing, stress response, and memory recollection (50).

There were FC alterations between insular ROIs and interoceptive regions that were only present during acid infusion and/or post-acid infusion (Figures 3 – 6) and not during the pre-infusion or neutral solution infusion scans. Some of these FC alterations may be a direct result of esophageal acid infusion while others may arise directly from heartburn perception. Alternatively, some of the FC alterations may be due to both esophageal acid infusion and heartburn perception. Because acid infusion in all GERD patients led to the development of heartburn which persisted through the post-infusion scan, it is not feasible to discriminate

the concurrent cortical effects of acid stimulation from the consequences of heartburn symptom generation within the interoceptive network.

The findings of the present study provide additional evidence for a sensitized esophago-cortical neuraxis in patients with a history of chronic acid-related mucosal injury, and does not address whether observed differences could be extended to other phenotypes of esophageal reflux disease without evidence of mucosal injury. The esophago-cortical neuraxis is thought to play an important role in the setting of non-erosive reflux disease (NERD), and we believe that studies in these patients will be important and clinically relevant. However, NERD patients are a heterogeneous population for which there is no universal agreement on pathophysiologic mechanisms or well-defined diagnostic criteria. Future studies will be needed to delineate whether or not alterations seen in patients with a history of erosive reflux disease are also present in patients with NERD. Furthermore, the current study focuses on the significant role of the insula in reflux disease given its pivotal role in interoceptive homeostatic processing without excluding the possibility that other brain regions that were not included in our analysis could show altered functional connectivity (FC) in GERD patients or healthy controls. It should be noted that addition of brain regions exponentially increases the number of hypotheses tested requiring a significant statistical cost to correct for multiple comparisons that could negatively impact the power of the investigation. Determination of these regions' role requires additional hypothesis driven independent experiments.

Majority of the FC alterations that were differentially observed in GERD patients (compared to healthy controls) were during or after esophageal acid stimulation. Some of the FC changes may have been the directly related to esophageal acid stimulation while alternatively others can be related to heartburn perception or a combination of both. Since acid infusion in all GERD patients led to heartburn that persisted throughout the post-infusion fMRI scan in an overwhelmingly number of GERD patients, it is not feasible to discriminate the cortical effects of acid stimulation from the consequences of symptom generation in the current study. Additional studies will be needed to differentiate between the cortical registration of esophageal acid stimulation from the cortical consequences of heartburn perception within the interoceptive network.

In conclusion, GERD patients have significant differences in insular FC when compared to healthy subjects. Esophageal chemical stimulation and development of heartburn in GERD patients is associated with significant insular cortex FC differences with regions involved in emotional awareness and subjective evaluation of internal physiologic conditions. The results of the present study provide further evidence that the insular cortex, located at the transition of afferent physiologic information to human feelings, likely functions as a central node in neural networks underlying visceral homeostasis and the experience of heartburn in GERD patients

Acknowledgments

This project was supported by the NIDDK through grant numbers R01DK025731-29 and T32DK061923-06 (R. Shaker) and by the National Center for Research Resources and Advancing Translational Sciences through grant numbers 8KL2TR000056 and 8UL1TR000055 (A. Babaei).

Reza Shaker had a major role in study concept and design, drafting of the manuscript, funding, supervision, and critical revision of the manuscript for important intellectual content.

ABBREVIATIONS

AFNI	analysis of functional neuroimages
BOLD	blood oxygenated level dependent
FC	functional connectivity
fMRI	functional magnetic resonance imaging
GERD	gastroesophageal reflux disease
ROI	region of interest

REFERENCES

1. Kahrilas PJ. Gastroesophageal reflux disease. *New England Journal of Medicine*. 2008; 359:1700–1707. [PubMed: 18923172]
2. Sengupta JN. An overview of esophageal sensory receptors. *American Journal of Medicine*. 2000; 108:87S–89S. [PubMed: 10718458]
3. Peles S, Medda BK, Zhang Z, Banerjee B, Lehmann A, Shaker R, et al. Differential effects of transient receptor vanilloid one (TRPV1) antagonists in acid-induced excitation of esophageal vagal afferent fibers of rats. *Neuroscience*. 2009; 161(2):515–525. [PubMed: 19324074]
4. Qin C, Farber JP, Foreman RD. Intraesophageal chemicals enhance responsiveness of upper thoracic spinal neurons to mechanical stimulation of esophagus in rats. *American Journal of Physiology Gastrointestinal and Liver Physiology*. 2008; 294(3):G708–G716. [PubMed: 18187515]
5. Randich A, Gebhart GF. Vagal afferent modulation of nociception. *Brain Research Brain Research Reviews*. 1992; 17(2):77–99. [PubMed: 1327371]
6. Kern MK, Birn RM, Jaradeh S, Jesmanowicz A, Cox RW, Hyde JS, et al. Identification and characterization of cerebral cortical response to esophageal mucosal acid exposure and distention. *Gastroenterology*. 1998; 115(6):1353–1362. [PubMed: 9834262]
7. Hojo M, Takahashi T, Nagahara A, Sasaki H, Oguro M, Asaoka D, et al. Analysis of brain activity during visceral stimulation. *Journal of Gastroenterology and Hepatology*. 2012; 27(Suppl 3):49–52. [PubMed: 22486871]
8. Kern M, Hofmann C, Hyde J, Shaker R. Characterization of the cerebral cortical representation of heartburn in GERD patients. *American Journal of Physiology Gastrointestinal and Liver Physiology*. 2004; 286(1):G174–G181. [PubMed: 14512287]
9. Xu S, Zheng F, Zhao X, Chen Y, Kong X, Wang C, et al. Brain processing of visceral sensation upon esophageal chemical stimulation in different types of GERD. *European Journal of Radiology*. 2010; 75(3):352–359. [PubMed: 20434286]
10. Wang K, Duan LP, Zeng XZ, Liu JY, Xu-Chu W. Differences in cerebral response to esophageal acid stimuli and psychological anticipation in GERD subtypes--an fMRI study. *BMC Gastroenterology*. 2011; 11:28. [PubMed: 21439078]
11. Shaker R. Gastroesophageal reflux disease: beyond mucosal injury. *Journal of Clinical Gastroenterology*. 2007; 41(Suppl 2):S160–S162. [PubMed: 17575516]
12. Larsson MB, Tillisch K, Craig AD, Engstrom M, Labus J, Naliboff B, et al. Brain responses to visceral stimuli reflect visceral sensitivity thresholds in patients with irritable bowel syndrome. *Gastroenterology*. 2012; 142(3):463–472. e3. [PubMed: 22108191]
13. Naliboff BD, Berman S, Suyenobu B, Labus JS, Chang L, Stains J, et al. Longitudinal change in perceptual and brain activation response to visceral stimuli in irritable bowel syndrome patients. *Gastroenterology*. 2006; 131(2):352–365. [PubMed: 16890589]

14. Aziz Q, Andersson JL, Valind S, Sundin A, Hamdy S, Jones AK, et al. Identification of human brain loci processing esophageal sensation using positron emission tomography. *Gastroenterology*. 1997; 113(1):50–59. [PubMed: 9207261]
15. Dunckley P, Wise RG, Aziz Q, Painter D, Brooks J, Tracey I, et al. Cortical processing of visceral and somatic stimulation: differentiating pain intensity from unpleasantness. *Neuroscience*. 2005; 133(2):533–542. [PubMed: 15896917]
16. Kern MK, Shaker R. Cerebral cortical registration of subliminal visceral stimulation. *Gastroenterology*. 2002; 122(2):290–298. [PubMed: 11832444]
17. Van Oudenhove L. Understanding gut-brain interactions in gastrointestinal pain by neuroimaging: lessons from somatic pain studies. *Neurogastroenterology and motility : the official journal of the European Gastrointestinal Motility Society*. 2011; 23(4):292–302. [PubMed: 21255193]
18. Fox MD, Raichle ME. Spontaneous fluctuations in brain activity observed with functional magnetic resonance imaging. *Nature reviews Neuroscience*. 2007; 8(9):700–711.
19. Biswal B, Yetkin FZ, Haughton VM, Hyde JS. Functional connectivity in the motor cortex of resting human brain using echo-planar MRI. *Magnetic resonance in medicine : official journal of the Society of Magnetic Resonance in Medicine / Society of Magnetic Resonance in Medicine*. 1995; 34(4):537–541.
20. Koch MA, Norris DG, Hund-Georgiadis M. An investigation of functional and anatomical connectivity using magnetic resonance imaging. *NeuroImage*. 2002; 16(1):241–250. [PubMed: 11969331]
21. Kurth F, Zilles K, Fox PT, Laird AR, Eickhoff SB. A link between the systems: functional differentiation and integration within the human insula revealed by meta-analysis. *Brain structure & function*. 2010; 214(5–6):519–534. [PubMed: 20512376]
22. Craig AD. How do you feel? Interoception: the sense of the physiological condition of the body. *Nature reviews Neuroscience*. 2002; 3(8):655–666.
23. Craig AD. Interoception: the sense of the physiological condition of the body. *Current opinion in neurobiology*. 2003; 13(4):500–505. [PubMed: 12965300]
24. Craig AD. How do you feel—now? The anterior insula and human awareness. *Nature reviews Neuroscience*. 2009; 10(1):59–70.
25. Shaker R, Saeian K. Unsedated transnasal laryngo-esophagogastroduodenoscopy: an alternative to conventional endoscopy. *The American journal of medicine*. 2001; 111(Suppl 8A):153S–156S. [PubMed: 11749942]
26. Siwiec RM, Dua K, Surapaneni SN, Hafeezullah M, Massey B, Shaker R. Unsedated transnasal endoscopy with ultrathin endoscope as a screening tool for research studies. *The Laryngoscope*. 2012; 122(8):1719–1723. Epub 2012/05/09. [PubMed: 22565357]
27. Cox RW. AFNI: software for analysis and visualization of functional magnetic resonance neuroimages. *Computers and biomedical research, an international journal*. 1996; 29(3):162–173.
28. Glover GH, Li TQ, Ress D. Image-based method for retrospective correction of physiological motion effects in fMRI: RETROICOR. *Magnetic resonance in medicine : official journal of the Society of Magnetic Resonance in Medicine / Society of Magnetic Resonance in Medicine*. 2000; 44(1):162–167.
29. Saad ZS, Glen DR, Chen G, Beauchamp MS, Desai R, Cox RW. A new method for improving functional-to-structural MRI alignment using local Pearson correlation. *NeuroImage*. 2009; 44(3):839–848. [PubMed: 18976717]
30. Ernst T, Speck O, Itti L, Chang L. Simultaneous correction for interscan patient motion and geometric distortions in echoplanar imaging. *Magnetic resonance in medicine : official journal of the Society of Magnetic Resonance in Medicine / Society of Magnetic Resonance in Medicine*. 1999; 42(1):201–205.
31. Cox RW, Jesmanowicz A. Real-time 3D image registration for functional MRI. *Magnetic resonance in medicine : official journal of the Society of Magnetic Resonance in Medicine / Society of Magnetic Resonance in Medicine*. 1999; 42(6):1014–1018.
32. Talairach, J.; Tournoux, P. Co-planar stereotaxic atlas of the human brain : 3-dimensional proportional system : an approach to cerebral imaging. Stuttgart ; New York: Georg Thieme; 1988. p. 122

33. Jo HJ, Saad ZS, Simmons WK, Milbury LA, Cox RW. Mapping sources of correlation in resting state fMRI, with artifact detection and removal. *NeuroImage*. 2010; 52(2):571–582. [PubMed: 20420926]
34. Birn RM, Diamond JB, Smith MA, Bandettini PA. Separating respiratory-variation-related fluctuations from neuronal-activity-related fluctuations in fMRI. *NeuroImage*. 2006; 31(4):1536–1548. [PubMed: 16632379]
35. Cauda F, D'Agata F, Sacco K, Duca S, Geminiani G, Vercelli A. Functional connectivity of the insula in the resting brain. *NeuroImage*. 2011; 55(1):8–23. [PubMed: 21111053]
36. Coen SJ, Gregory LJ, Yaguez L, Amaro E Jr, Brammer M, Williams SC, et al. Reproducibility of human brain activity evoked by esophageal stimulation using functional magnetic resonance imaging. *American journal of physiology Gastrointestinal and liver physiology*. 2007; 293(1):G188–G197. [PubMed: 17395900]
37. Coen SJ, Yaguez L, Aziz Q, Mitterschiffthaler MT, Brammer M, Williams SC, et al. Negative mood affects brain processing of visceral sensation. *Gastroenterology*. 2009; 137(1):253–261. 61 e1–61 e2. [PubMed: 19582887]
38. Critchley HD, Wiens S, Rotshtein P, Ohman A, Dolan RJ. Neural systems supporting interoceptive awareness. *Nature neuroscience*. 2004; 7(2):189–195.
39. Naidich TP, Kang E, Fatterpekar GM, Delman BN, Gultekin SH, Wolfe D, et al. The insula: anatomic study and MR imaging display at 1.5 T. *AJNR American journal of neuroradiology*. 2004; 25(2):222–232. [PubMed: 14970021]
40. Ture U, Yasargil DC, Al-Mefty O, Yasargil MG. Topographic anatomy of the insular region. *Journal of neurosurgery*. 1999; 90(4):720–733. [PubMed: 10193618]
41. Lawal A, Kern M, Sanjeevi A, Antonik A, Mepani R, Rittmann T, et al. Neurocognitive processing of esophageal central sensitization in the insula and cingulate gyrus. *American journal of physiology Gastrointestinal and liver physiology*. 2008; 294(3):G787–G794. [PubMed: 18187518]
42. Shmueli K, van Gelderen P, de Swart JA, Horovitz SG, Fukunaga M, Jansma JM, Duyn JH. Low-frequency fluctuations in the cardiac rate as a source of variance in the resting-state fMRI BOLD signal. *Neuroimage*. 2007; 38(2):306–320. [PubMed: 17869543]
43. Birn RM, Murphy K, Bandettini PA. The effect of respiration variations on independent component analysis results of resting state functional connectivity. *Human brain mapping*. 2008; 29(7):740–750. [PubMed: 18438886]
44. Iacovella V, Hasson U. The relationship between BOLD signal and autonomic system functions: implications for processing of physiological noise. *Magnetic resonance imaging*. 2011; 29(10):1338–1345. [PubMed: 21543181]
45. Fan J, Xu P, Van Dam NT, Eilam-Stock T, Gu X, Luo YJ, Hof PR. Spontaneous brain activity relates to autonomic arousal. *Journal of neuroscience*. 2012; 32(33):11176–11186. [PubMed: 22895703]
46. Critchley HD, Nagai Y, Gray MA, Mathias CJ. Dissecting axes of autonomic control in humans: insights from neuroimaging. *Autonomic Neuroscience*. 161(1–2):34–42. 2–11.
47. James C, Henderson L, Macefield VG. Real-time imaging of brain areas in the generation of spontaneous skin sympathetic nerve activity at rest. 2013; 74:188–194.
48. Reyt S, Picq C, Sinniger V, Clarencon D, Bonaz B, David O. Dynamic causal modeling and physiological confounds: a functional MRI study of vagus nerve stimulation. *Neuroimage*. 2010; 52(4):1456–1464. [PubMed: 20472074]
49. Mora F, Segovia G, Del Arco A, de Blas M, Garrido P. Stress, neurotransmitters, corticosterone, and body-brain integration. *Brain research*. 2012; 1476:71–85. [PubMed: 22285436]
50. Liu MG, Chen J. Roles of the hippocampal formation in pain information processing. *Neuroscience bulletin*. 2009; 25(5):237–266. [PubMed: 19784080]

Key Messages

The insula plays a significant role in the interoceptive processing of visceral stimuli. The aim of the study was to investigate the functional connectivity (FC) of the insula with previously implicated cortical areas involved in emotional awareness and subjective evaluation of internal physiologic conditions in patients with GERD during esophageal stimulation.

Functional connectivity between insular subregions and a priori defined interoceptive regions was compared between GERD patients and healthy controls during four steady state conditions: (1) presence of transnasal esophageal catheter (pre-infusion); (2) neutral solution infusion; (3) acid infusion; (4) presence of transnasal esophageal catheter following infusions (post-infusion).

Significant differences were found between GERD patients and healthy controls in: (1) insula-thalamic FC (neutral solution infusion, acid infusion, post-infusion); (2) insula-amygdala FC (acid infusion, post-infusion); and (3) insula-hippocampus and insula-cingulate FC (post-infusion).

Esophageal acid stimulation in patients with GERD produces significant insular cortex functional connectivity differences with regions underlying interoception and viscerosensation.

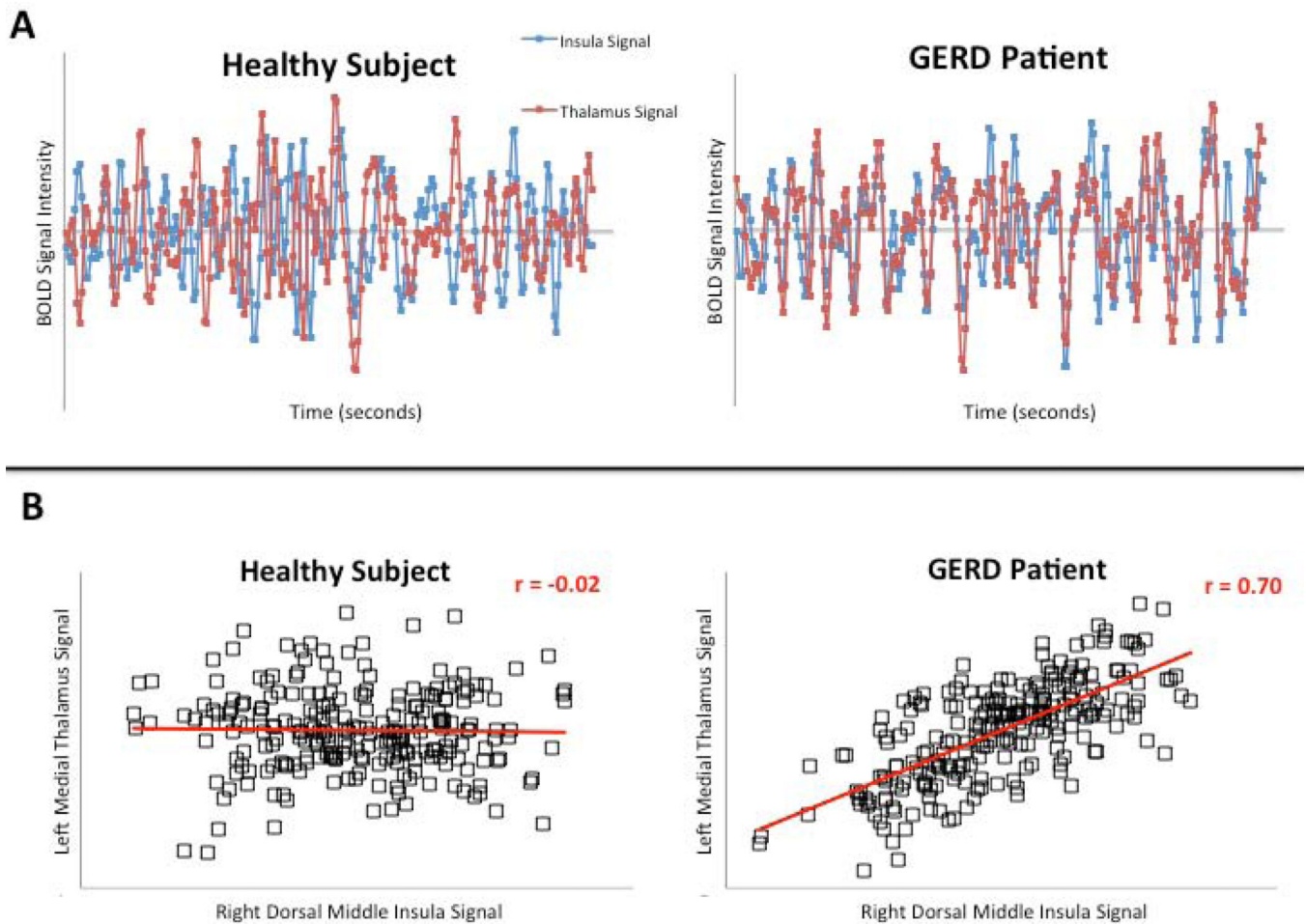


Figure 1. Determining functional connectivity (FC) values from blood oxygen level dependent (BOLD) time series

(A) Representative BOLD time-series from a healthy subject and a GERD patient between a seed region (right dorsal middle insula) and the target interoceptive region (left medial thalamus). (B) The scatter plot and calculated cross correlation coefficient of the corresponding BOLD time-series from panel A.

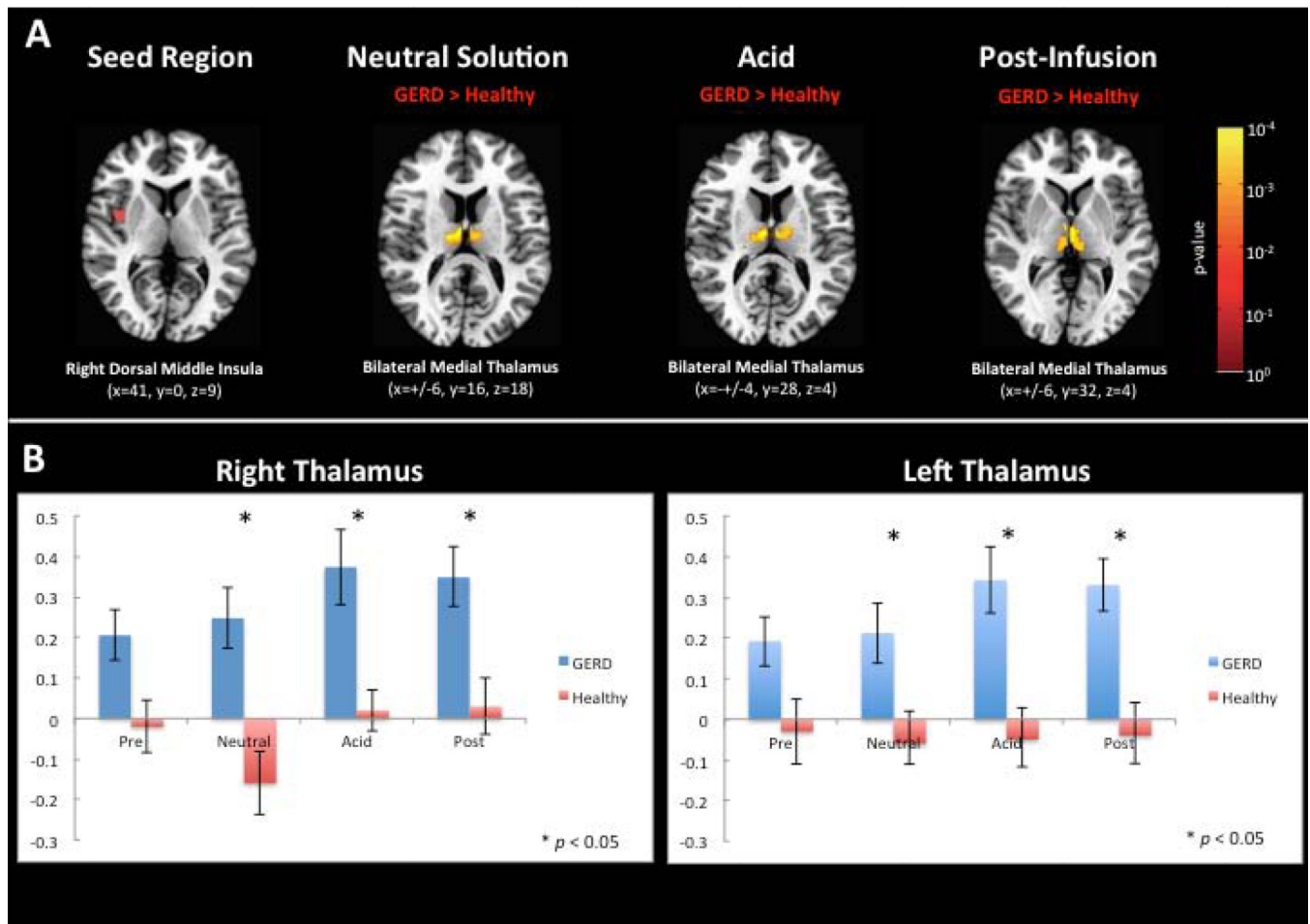


Figure 2. Insula-thalamic functional connectivity differences between GERD patients and healthy subjects during neutral solution and acid infusion and after acid stimulation
 The insula seed region of interest is depicted as a red circle (right dorsal middle insula) and significantly different clusters (corrected $p < 0.05$) between healthy subjects and the GERD patients are shown as a yellow-orange overlay on an axial standard brain image (Panel A). Standard coordinates in Talairach-Tournoux space are also noted below each brain image. The color-scale to the right of figure corresponds to uncorrected voxel-wise p-value of unpaired t-test between healthy controls and GERD patients. Mean normalized functional connectivity scores \pm SEM are shown for both healthy subjects and GERD patients for all study conditions as a bar graph (Panel B).

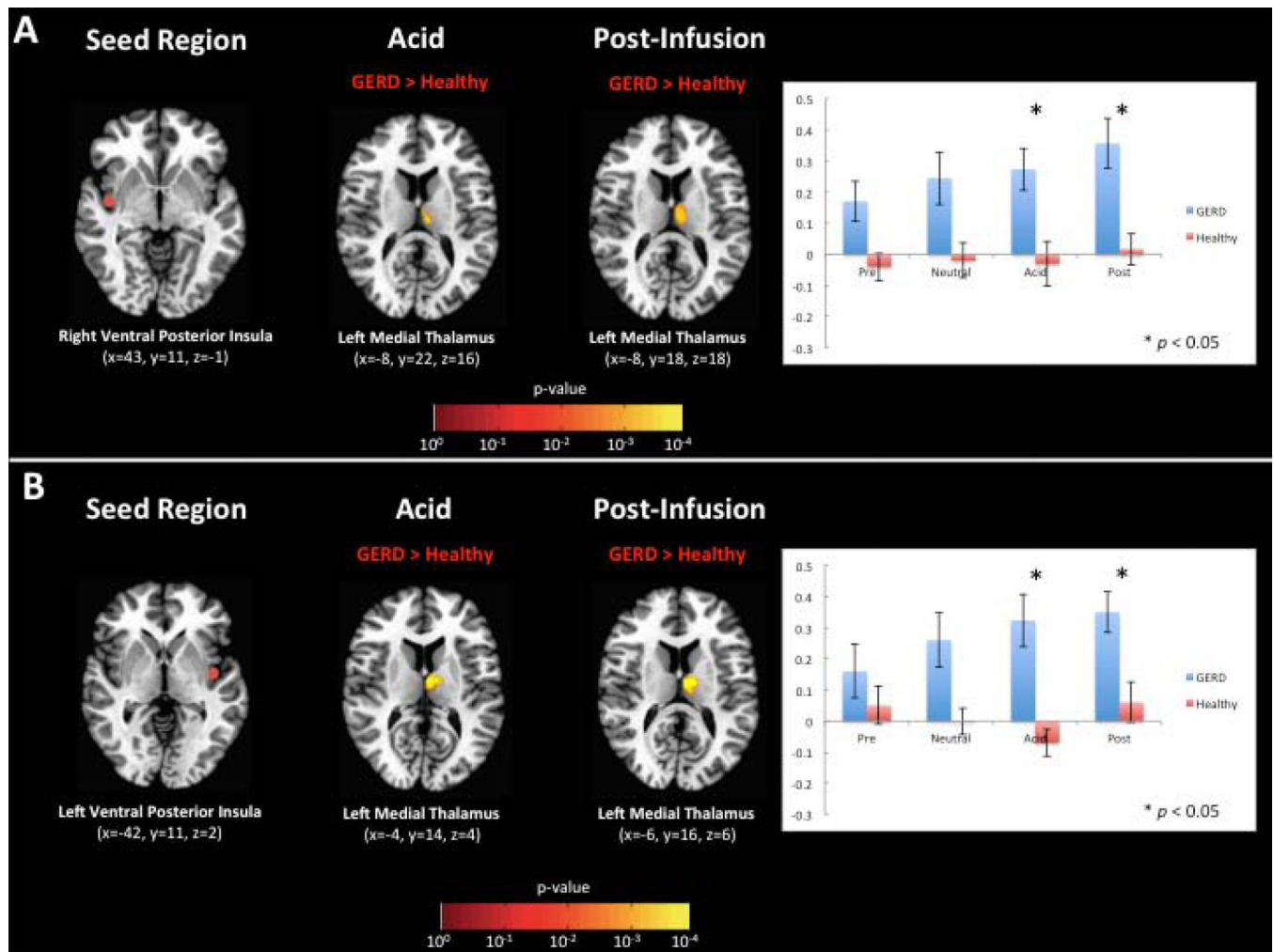


Figure 3. Insula-thalamic functional connectivity differences between GERD patients and healthy subjects during and after esophageal acid stimulation

The insula seed region of interest is depicted as a red circle and significantly different clusters (corrected $p < 0.05$) between healthy subjects and the GERD patients are shown as a yellow-orange overlay on an axial standard brain image. Standard coordinates in Talairach-Tournoux space are also noted below each brain image. The color-scale below the brain images corresponds to uncorrected voxel-wise p-value of unpaired t-test between healthy controls and GERD patients. Mean normalized functional connectivity scores \pm SEM are shown for both healthy subjects and GERD patients for all study conditions as a bar graph. (A) Right ventral posterior insula and left medial thalamus. (B) Left ventral posterior insula and left medial thalamus.

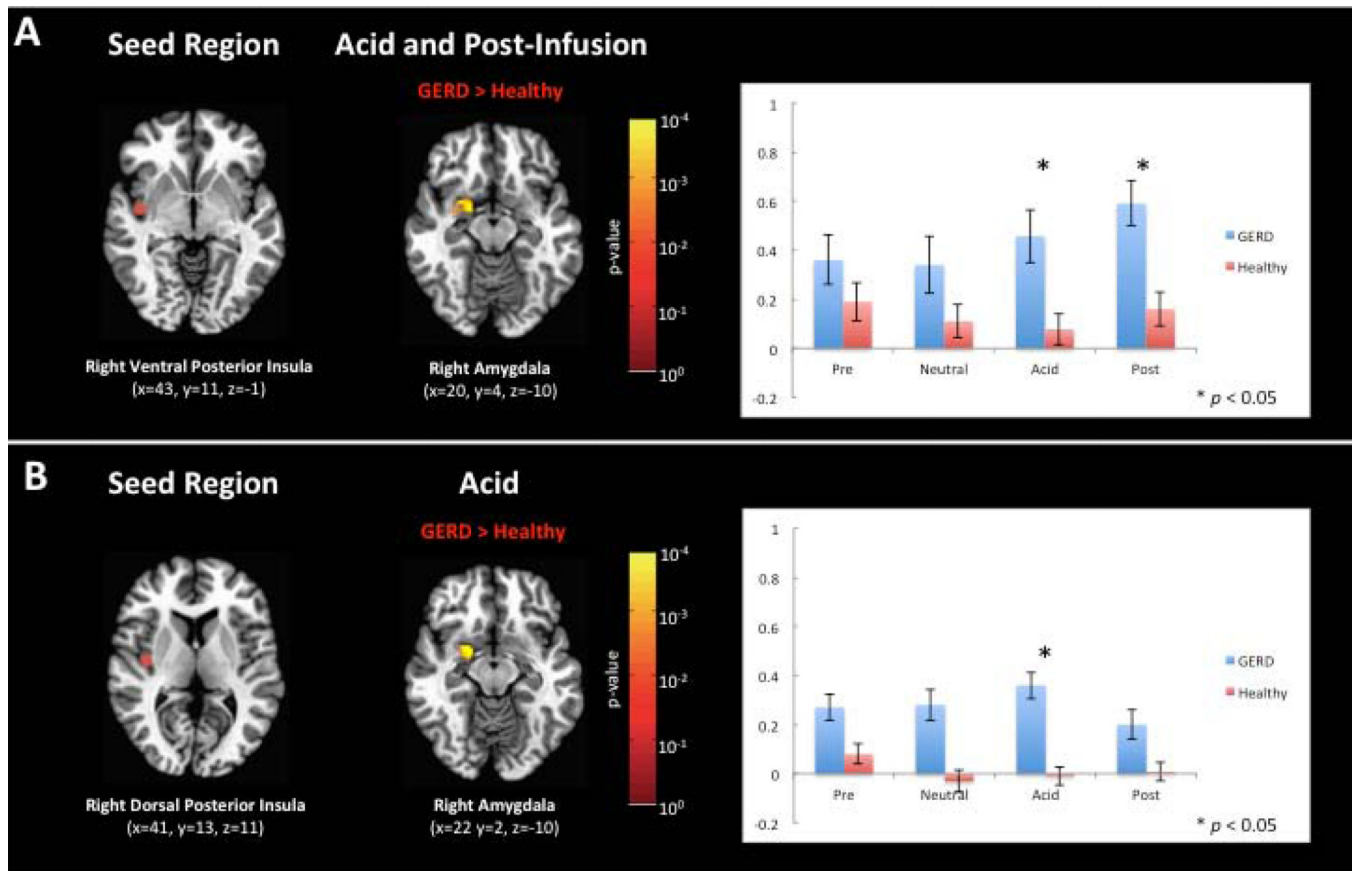


Figure 4. Differences in insula-amygdala functional connectivity between GERD patients and healthy subjects

The insula seed region of interest is depicted as a red circle and significantly different clusters (corrected $p < 0.05$) between healthy subjects and the GERD patients are shown as a yellow-orange overlay on an axial standard brain image. Standard coordinates in Talairach-Tournoux space are also noted below each brain image. The color-scale to the right of figure corresponds to uncorrected voxel-wise p-value of unpaired t-test between healthy controls and GERD patients. Mean normalized functional connectivity scores \pm SEM are shown for both healthy subjects and GERD patients for all study conditions as a bar graph. (A) Right ventral posterior insula and right amygdala. (B) Right dorsal posterior insula and right amygdala.

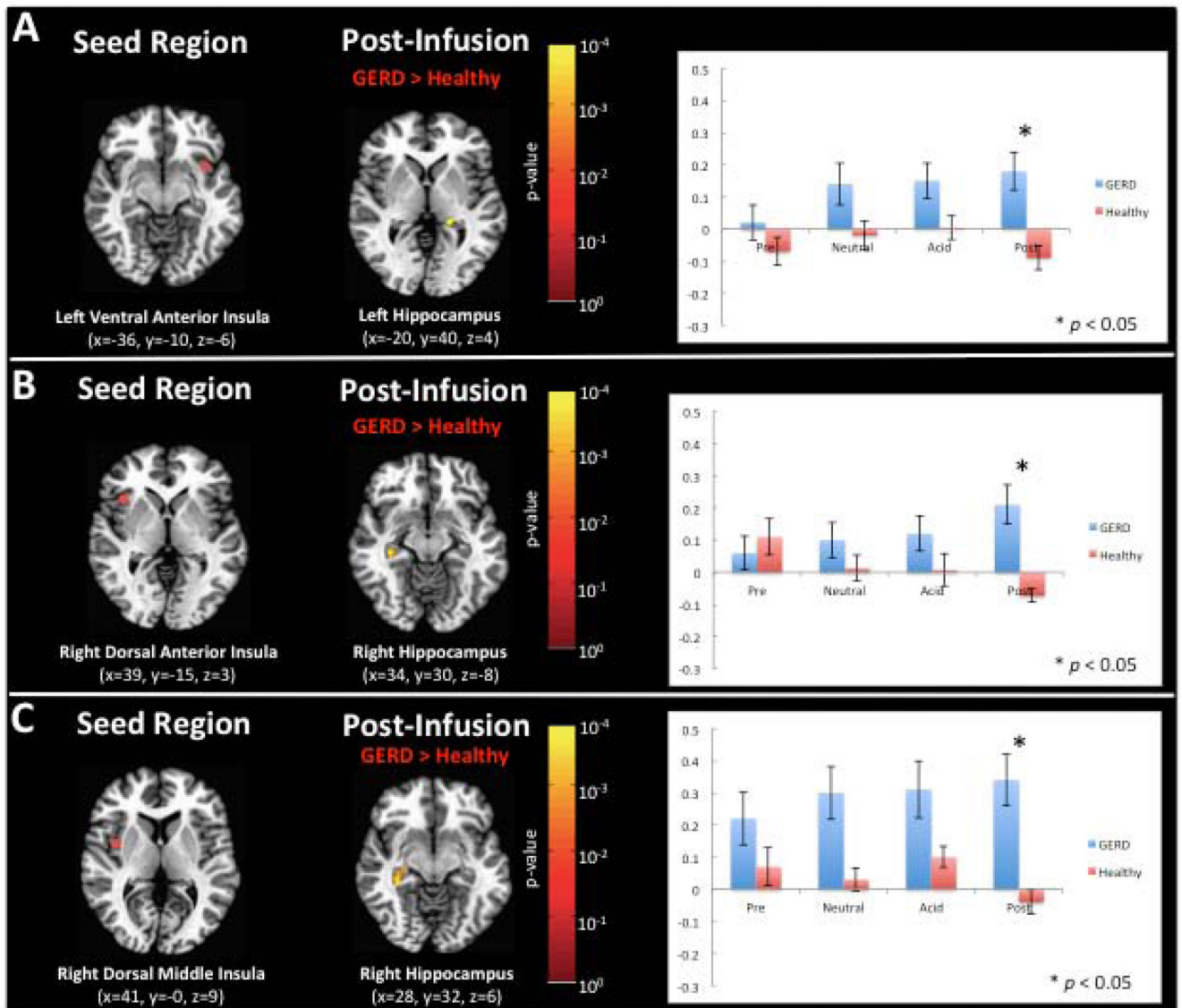


Figure 5. Insula-hippocampus functional connectivity differences between GERD patients and healthy subjects following esophageal acid stimulation
 The insula seed region of interest is depicted as a red circle and significantly different clusters (corrected $p < 0.05$) between healthy subjects and the GERD patients are shown as a yellow-orange overlay on an axial standard brain image. Standard coordinates in Talairach-Tournoux space are also noted below each brain image. The color-scale to the right of figure corresponds to uncorrected voxel-wise p-value of unpaired t-test between healthy controls and GERD patients. Mean normalized functional connectivity scores \pm SEM are shown for both healthy subjects and GERD patients for all study conditions as a bar graph. (A) Left ventral anterior insula and left hippocampus. (B) Right dorsal anterior insula and right hippocampus. (C) Right dorsal middle insula and right hippocampus.

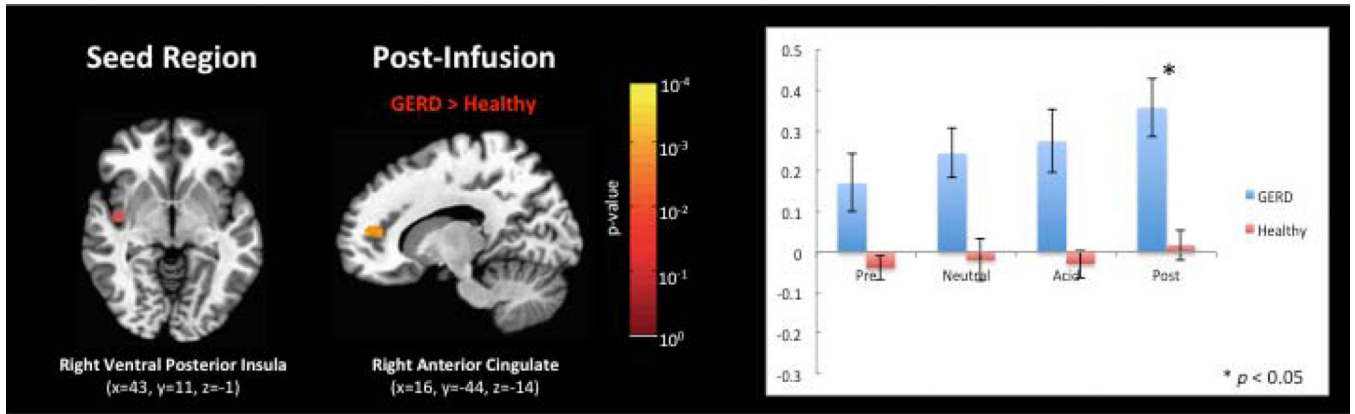


Figure 6. Differences in insular-cingulate functional connectivity between GERD patients and healthy subjects following esophageal acid stimulation

The insula seed region of interest (right ventral posterior insula) is depicted as a red circle and significantly different clusters (corrected $p < 0.05$) between healthy subjects and the GERD patients are shown as a yellow-orange overlay on an axial standard brain image. Standard coordinates in Talairach-Tournoux space are also noted below each brain image. The color-scale to the right of figure corresponds to uncorrected voxel-wise p-value of unpaired t-test between healthy controls and GERD patients. Mean normalized functional connectivity scores \pm SEM are shown for both healthy subjects and GERD patients for all study conditions as a bar graph.

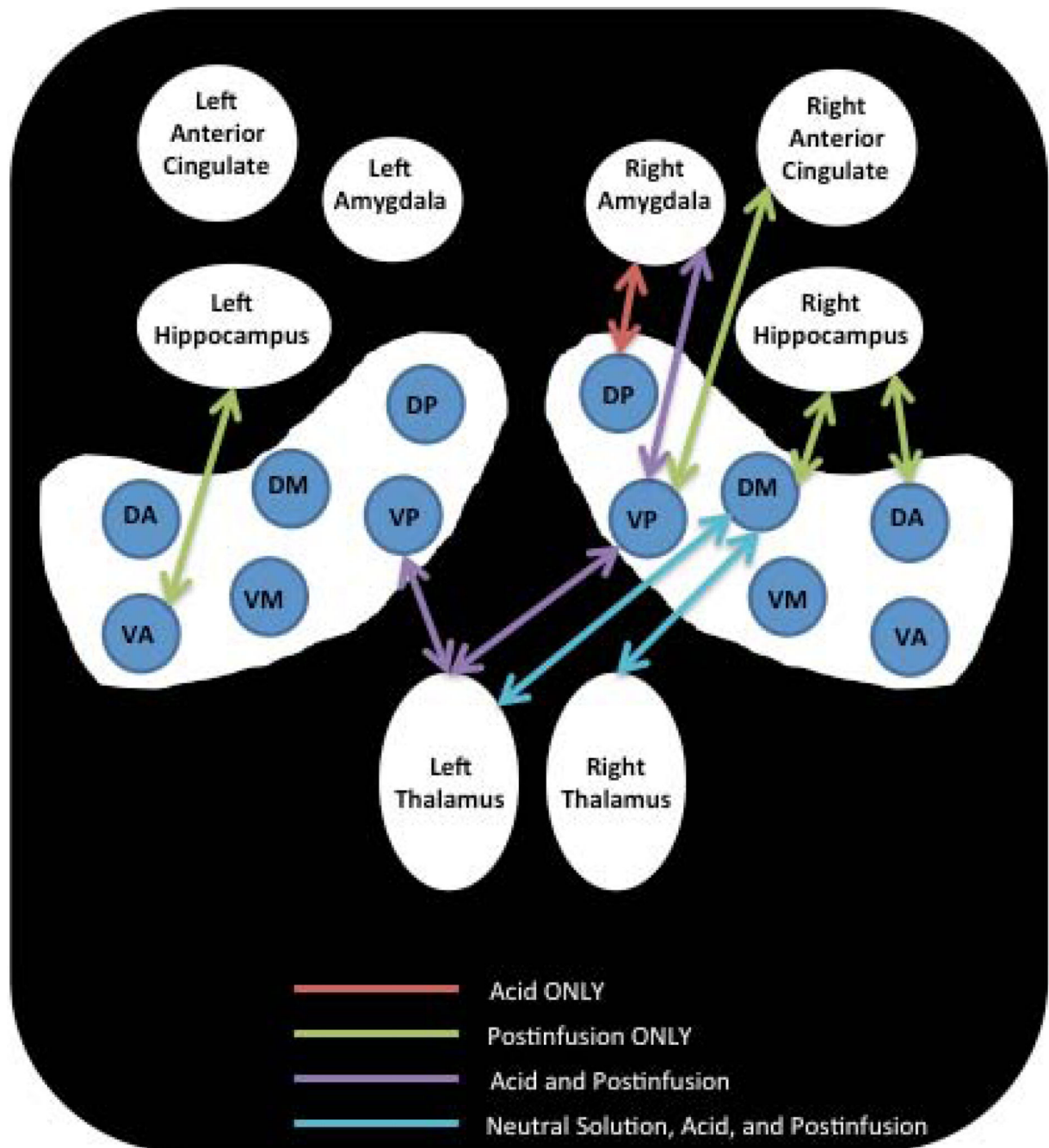


Figure 7.

Schematic representation of bilateral insular functional connectivity differences with interoceptive brain regions between GERD patients and healthy subjects during (1) acid infusion only (red line), (2) postinfusion only (green line), (3) acid and postinfusion (purple line), and (4) neutral solution, acid, and postinfusion (blue line). Right and left parcellated insular regions are abbreviated: DA = dorsal anterior; VA = ventral anterior; DM = dorsal middle; VM = ventral middle; DP = dorsal posterior; VP = ventral posterior.