

From the Clinic

Early *Enterococcus*-associated acute postinfectious glomerulonephritis after kidney transplant

Background

Postinfection as an etiology for glomerulonephritis (GN) is rarely described in post-transplant recipients and may be due to impaired immune response. It is also possible that such cases are not biopsied or not reported. There are rare case reports in the literature [1–3]. We report here a rare first case of *Enterococcus*-related postinfectious GN in a transplant recipient seen in our center.

Case report

A 64-year-old Caucasian man with past medical history of diabetes and hypertension on hemodialysis for 12 years underwent deceased donor kidney transplant. He underwent induction with Thymoglobulin[®], early steroid withdrawal, and was maintained on tacrolimus and mycophenolic acid. Early post-transplant course was uncomplicated and serum creatinine improved to 1.6 mg/dL (141 μ mol/L) by Day 8. He was discharged with an indwelling urinary catheter due to urinary retention which was removed 2 days after discharge and had to be reinserted on Day 12 due to retention. On Day 23, he had a fever and was found to have vancomycin-resistant *Enterococcus* (VRE) urinary tract infection (UTI) which was treated with meropenem for 10 days. On Day 58, he was found to have an elevated creatinine of 2.4 mg/dL (212 μ mol/L), and recurrent VRE UTI. Despite treatment of the UTI and clinical improvement, the graft function continued to deteriorate and creatinine peaked at 4.1 mg/dL (362 μ mol/L). He had 0.5 g of proteinuria. Urinalysis showed 53 white blood cells (WBCs) and >182 red blood cells (RBCs), with many dysmorphic RBCs, but no evidence of tubular casts. Donor-specific antibodies were negative.

Despite antibiotics, intravenous fluids and reduction of immunosuppression, there was no improvement in renal function, and WBCs and RBCs in urine. A transplant kidney biopsy was performed, which showed hypercellular glomeruli with mesangial and capillary loop infiltration of mononuclear cells as well as neutrophils and eosinophils, along with borderline tubulitis (Banff borderline), acute tubular damage and mild isometric vacuolization of the cytoplasm. Crescents were not noted, but there was a minor duplication of the glomerular basement membranes (Figure 1). C4d and BK virus stains were negative. Electron microscopy showed sub-endothelial and mesangial electron-dense deposits (Figure 2). Immunofluorescence showed antibodies to IgG (2–3+), IgM (2+), C3 (4+), C1q (2–3+), kappa (2–3+) and lambda (trace to 1+) granular mesangial and capillary loop staining. Antibodies to fibrinogen, IgA and albumin were negative. Complement C3 and C4 were low at 26 mg/dL (reference range 65–180 mg/dL) and 10 mg/dL (reference range 13–52 mg/dL), respectively, with negative ANCA and ANA. The tacrolimus levels were not elevated at any

time as to be concerned about toxicity. Cardiac echocardiogram was negative for any vegetation and blood cultures were persistently negative. Findings were most consistent with postinfectious GN in the setting of UTI. He was given methylprednisone 500 mg daily in three doses and did require one session of hemodialysis for volume overload. Oral prednisone was resumed after he had completed his antibiotic therapy, and then discharged on a steroid taper over 10 days. He continued to have repeated episodes of UTI requiring antibiotics with creatinine stabilizing at 2.7 mg/dL (238 μ mol/L). Due to persistent urinary retention seen on urodynamics, he underwent ileal loop diversion to the transplanted kidney 2.5 months post-transplant. Following the procedure, his creatinine improved to 1.5 mg/dL (132 μ mol/L) and is currently, at 19 months post-transplant, 1.2 (106 μ mol/L) with 0.32 g of proteinuria.

Discussion

Postinfectious GN is the most common cause of acute nephritis in children in developing countries. It is more frequent and severe in nontransplant immunocompromised patients such as elderly, HIV, malignancy, alcoholic liver cirrhosis, diabetes or obstructive lung disease. However, despite the high rate of infections in post-transplant patients, it is rarely reported post-transplant. Infections are the most common reason for admissions early post kidney transplant. In one case series, only 3 of 827 patients developed postinfectious GN even though 65% of the patients developed at least one significant bacterial infection during follow-up [1]. Long-term outcome was poor as two of the three patients subsequently lost their graft. The reported 11 cases of transplant biopsy-proven postinfectious secondary GN have been due *Staphylococcus aureus* sepsis, *Staphylococcus* urosepsis, post-pharyngitis streptococcal GN, cytomegalovirus infections and *Salmonella enteritidis*, with variable outcomes.

The pattern of the postinfectious GN seems to be changing in the general population and is no longer associated with only streptococcus or staphylococcal infections. The major pathogenetic mechanism is *in situ* immune complex formation due to deposition of nephritogenic antigens within the glomerulus. An alternative hypothesis is glomerular trapping of circulating immune complexes. Immunosuppressive agents previously initiated for prevention of rejection should theoretically interfere with the immune response to the infectious agent and prevent the formation of immune complexes. Our case shows the course of VRE-associated postinfectious GN in a transplant patient, which has not been previously described. There is no established therapy for treatment of acute postinfectious GN in these cases aside from aggressive treatment of infection with the appropriate antibiotics to remove the antigenic stimulation. The role of steroids in the treatment of postinfectious GN in these cases is unclear. Five of the reported 11 cases were treated with pulse steroids. Based on limited cases, some authors suggest a short course of pulse steroids while others disagree arguing that it would predispose to further infections. We felt a short steroid

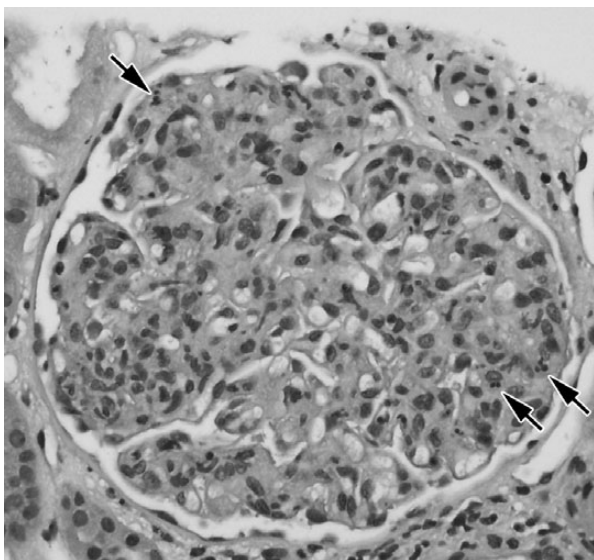


Fig. 1. H&E light microscopy section showing hypercellular glomeruli with neutrophilic infiltration (arrows).

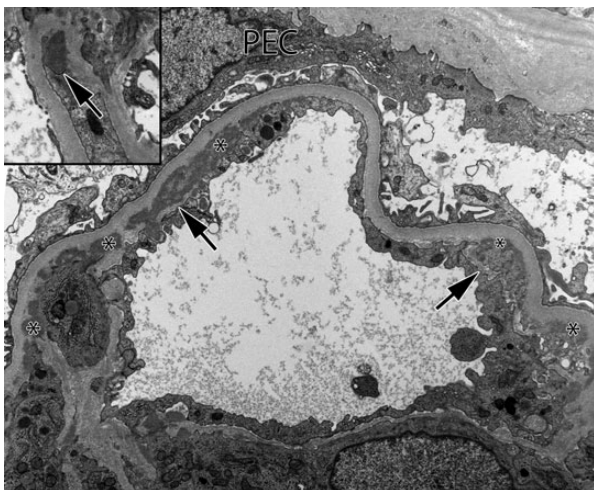


Fig. 2. Electron micrograph of a glomerular capillary loop showing subendothelial and paramesangial electron dense deposits (indicated with an asterisk symbol). Early duplication of glomerular basement membranes is present but interrupted (arrows). In the inset image at upper left, an isolated subepithelial electron dense 'hump' deposit is seen in the mesangial notch region. Original magnification of both images was $\times 9450$. PEC, parietal epithelial cell.

course was beneficial for the anti-inflammatory effect aside from aggressive antibiotic therapy and reversal of

any potential inciting events. The long-term prognosis of postinfectious GN is poor even in nontransplanted patients where up to 27% have chronic kidney disease and 10% end up on dialysis at 7.5 years of follow-up. To date, there are only three cases of *Enterococcus*-related GN in native kidneys, of which two were crescentic GN and one membranous [4, 5]. To date, there are no cases of *Enterococcus*-related GN in transplant recipients.

In conclusion, we report the first case of *Enterococcus*-related postinfectious GN in a transplant recipient on immunosuppression. These cases are generally associated with extremely poor long-term outcome of graft function. However, with early detection, antibiotics and surgical intervention, sustained long-term renal function is possible.

Conflict of interest statement. The results of this case have not been published previously elsewhere. The authors of this manuscript have no related conflicts of interest to disclose.

¹Division of Nephrology, Department of Medicine, Indiana University School of Medicine, University Hospital, Indianapolis, IN, USA

²Department of Pathology, Indiana University School of Medicine, Indianapolis, IN, USA

Teena Tandon¹
M. Mujtaba¹
Dennis Mishler¹
Carrie Phillips²
Asif Sharfuddin¹

Correspondence and offprint requests to: Asif Sharfuddin; E-mail: asharfud@iu.edu

References

1. Moroni G, Papaccioli D, Banfi G et al. Acute post-bacterial glomerulonephritis in renal transplant patients: description of three cases and review of the literature. *Am J Transplant* 2004; 4: 132–136
2. Plumb TJ, Greenberg A, Smith SR et al. Postinfectious glomerulonephritis in renal allograft recipients. *Transplantation* 2006; 82: 1224–1228
3. Sorof JM, Weidner N, Potter D et al. Acute post-streptococcal glomerulonephritis in a renal allograft. *Pediatr Nephrol* 1995; 9: 317–319
4. Kirkpantur A, Altinbas A, Arici M et al. Enterococcal endocarditis associated with crescentic glomerulonephritis. *Clin Exp Nephrol* 2007; 11: 321–325
5. Iida H, Mizumura Y, Uraoka T et al. Membranous glomerulonephritis associated with enterococcal endocarditis. *Nephron* 1985; 40: 88–90

Received for publication: 17.3.14; Accepted in revised form: 10.6.14

doi: 10.1093/ckj/sfu069

Advance Access publication 1 July 2014