

and 11-dehydro-thromboxane B₂ (TXB₂) excretion rates were measured as previously described.⁴ The study protocol was approved by the local ethics committee, and patients provided written informed consent.

The effects of LAGB surgery were assessed using Friedman and Wilcoxon tests for paired samples. The Spearman rank correlation test and stepwise multiple linear regression analysis (using log-transformed data) were performed to assess variables associated with urinary 11-dehydro-TXB₂ excretion rates. Two-sided *P* values of less than .05 were considered to be statistically significant.

Results | The clinical and laboratory characteristics of the participants are shown in the **Table**. Lipid peroxidation (8-iso-PGF_{2α}) and platelet activation (11-dehydro-TXB₂), as well as C-reactive protein levels, progressively decrease at any time point following LAGB, with significant correlation among the 3 variables (*P* = .001). By pooling data from each time point after LAGB, we found that changes in urinary 8-iso-PGF_{2α} and 11-dehydro-TXB₂ excretion were significantly correlated ($\rho = 0.67$, *P* < .001). Moreover, both changes were significantly related to the amount of weight lost and to changes in body mass index, waist circumference, fasting plasma glucose level, and high-density lipoprotein cholesterol level. Changes in the homeostatic model assessment of insulin resistance (HOMA-IR) index correlated with changes in 11-dehydro-TXB₂ ($\rho = 0.466$, *P* = .02).

A multiple regression analysis of pooled data from baseline and 6 and 12 months after LAGB indicates that only the 8-iso-PGF_{2α} excretion rate ($\beta = 0.611$, *t* = 6.03, *P* < .001) and the HOMA-IR index ($\beta = 0.385$, *t* = 3.81, *P* = .001) can predict the rate of 11-dehydro-TXB₂ excretion, independent of body mass index, waist circumference, serum lipid levels, fasting plasma glucose levels, postprandial plasma glucose levels, fat mass, and C-reactive protein levels (adjusted *R*² = 0.665, *P* = .001).

Discussion | We previously identified a novel mechanism through which obesity may affect cardiovascular morbidity and mortality (namely, thromboxane-dependent platelet activation).⁵ Moreover, we established that isoprostanes may be a link between obesity and platelet activation. Notably, a 10% reduction in body weight, obtained through a successful diet-induced weight loss program, was associated with more than a 50% reduction in thromboxane biosynthesis.⁴

In our study, the rates of 8-iso-PGF_{2α} and 11-dehydro-TXB₂ excretion were significantly reduced 12 months after LAGB (by approximately 45% and approximately 60%, respectively), correlated with an approximately 18% decrease in body weight and with a concomitant decrease (~30%) in the level of C-reactive protein, a marker of systemic inflammation. However, because severe obesity is characterized by a very high rate of thromboxane biosynthesis, all but 4 values of thromboxane metabolite excretion did not return to the normal range 12 months after LAGB.

Moreover, weight loss following the surgical procedure significantly affected the fasting plasma glucose level, the postprandial plasma glucose level, and insulin sensitivity in our

obese participants. Thus, the HOMA-IR index and the 8-iso-PGF_{2α} excretion rate were the only predictors of the rate of thromboxane biosynthesis.

In conclusion, LAGB ameliorates the vicious cycle of inflammation, oxidative stress, and thromboxane-dependent platelet activation in obesity. However, the incomplete normalization of thromboxane biosynthesis in the majority of the obese participants may support the concept that different genotypic/phenotypic subtypes of obesity may exist.

Natale Vazzana, MD

Maria Teresa Guagnano, MD

Liberato Aceto, MD

Paolo Innocenti, MD

Giovanni Davì, MD

Author Affiliations: Department of Internal Medicine, Center of Excellence on Aging, "G. d'Annunzio" University of Chieti, Chieti, Italy (Vazzana, Guagnano, Davì); Unit of General and Laparoscopic Surgery, "G. d'Annunzio" University of Chieti, Chieti, Italy (Aceto, Innocenti).

Corresponding Author: Giovanni Davì, MD, Department of Internal Medicine, Center of Excellence on Aging, "G. d'Annunzio" University, Via Colle dell'Ara, 66013 Chieti, Italy (gdavi@unich.it).

Published Online: December 17, 2014. doi:10.1001/jamasurg.2014.1682.

Author Contributions: Drs Davì and Innocenti had full access to all of the data in the study and take responsibility for the integrity of the data and the accuracy of the data analysis.

Study concept and design: Guagnano, Innocenti, Davì.

Acquisition, analysis, or interpretation of data: All authors.

Drafting of the manuscript: Vazzana, Aceto, Innocenti, Davì.

Critical revision of the manuscript for important intellectual content: Guagnano.

Statistical analysis: Vazzana.

Obtained funding: Guagnano, Davì.

Administrative, technical, or material support: Guagnano, Aceto.

Study supervision: Innocenti, Davì.

Conflict of Interest Disclosures: None reported.

1. Courcoulas AP, Christian NJ, Belle SH, et al: Longitudinal Assessment of Bariatric Surgery (LABS) Consortium. Weight change and health outcomes at 3 years after bariatric surgery among individuals with severe obesity. *JAMA*. 2013;310(22):2416-2425.
2. Field AE, Camargo CA Jr, Ogino S. The merits of subtyping obesity: one size does not fit all. *JAMA*. 2013;310(20):2147-2148.
3. Sjöström L, Peltonen M, Jacobson P, et al. Bariatric surgery and long-term cardiovascular events. *JAMA*. 2012;307(1):56-65.
4. Davì G, Guagnano MT, Ciabattini G, et al. Platelet activation in obese women: role of inflammation and oxidant stress. *JAMA*. 2002;288(16):2008-2014.
5. Davì G, Patrono C. Platelet activation and atherothrombosis. *N Engl J Med*. 2007;357(24):2482-2494.

ASSOCIATION OF VA SURGEONS

Ultrasonography-Guided Identification With Methylene Blue Tattooing of the Ilioinguinal Nerve for Neurectomy for Chronic Pain: A Case Series

Chronic ilioinguinal pain is a common but morbid complication of inguinal herniorrhaphy for 12% to 62% of patients.¹ Although pharmacologic options exist (such as nerve blocks), long-term pain relief is inferior to surgical neurectomy.^{2,3} We present our experience in ilioinguinal neurectomy with preoperative ultrasonography-guided identification and perineural injection of methylene blue to tattoo the nerve.

Methods | Four patients with inguinodynia who responded favorably to nerve blocks were referred for neurectomy. Three patients had pain from herniorrhaphy, and 1 patient had neuropathic pain. Before inducing anesthesia, a staff anesthesiologist localized the proximal nerve using ultrasonography above the anterior superior iliac spine, anterior to the midaxillary line, between the transversus abdominis and internal oblique muscle planes. A 21-gauge nerve stimulator needle reproduced preoperative pain. The intramuscular plane was hydrodissected with 0.5 to 5 mL of normal saline, followed by perineural tattooing with 0.3 to 0.5 mL of methylene blue and 2 to 5 mL of bupivacaine hydrochloride, 0.5%. The skin was marked to triangulate approximate nerve position. Under general anesthesia, a 3-cm transverse incision was made, and the external and internal oblique muscles were split in the direction of the fibers, allowing exposure of the transversus abdominis with self-retaining retractors. Within the blue-stained fibers of the transversus abdominis, we identified and dissected out the ilioinguinal nerve (Figure). The nerve was ligated proximally and distally, and a segment was sent for frozen section. All patients were discharged home without complications and were followed up for 4 weeks after surgery.

Results | During surgery, the nerve was positively identified in all patients. The time from incision to localization was as short as 7 minutes. At follow-up, all patients had expected numbness over the distribution of the nerve. Three of the 4 patients experienced complete or near-complete resolution of pain, although 1 of the 3 patients had incisional hyperesthesia. The fourth patient experienced numbness but no pain relief. However, this patient's pain was eventually relieved by the excision of an inguinal lymph node.

Discussion | Ilioinguinal neurectomy is effective at reducing pain after inguinal herniorrhaphy.⁴ Traditionally, surgeons have relied on anatomic landmarks in the postoperative groin; success depends on finding the nerve within scarred and obliterated tissue planes. Dissection may be arduous, may damage surrounding structures, or may require mesh removal.⁵ Using

stimulator needle localization with directed cutdown can improve detection, but this advantage is lost if the needle slips. These problems necessitated a more reproducible, efficient technique that permits the quick identification of the nerve without the aforementioned pitfalls.

Our technique is based on the transversus abdominis plane block, which is used in our facility for postoperative analgesia.⁶ A strong ultrasonographic experience is critical to identifying the nerve within the muscle but can be time-consuming. After confirmation of the nerve by stimulation, minimizing dye injection prevents tattooing too wide an area. Localization allows for a small, roughly 3-cm incision far from previous scar tissue, and dissection is similar to the Rocky-Davis approach to appendectomy. Within the transversus abdominis fibers, the nerve will be visible against blue-stained muscle, allowing for easier ligation and division. None of our patients required removal of mesh. The time required for identification of the nerve varies based on the learning curve and the depth of the subcutaneous tissues, and good retraction is critical for visualization. Overall, this procedure reduces morbidity while allowing the surgeon to more quickly and easily treat the patient's inguinodynia.

Andrew Curtiss Eppstein, MD

Imtiaz A. Munshi, MD, MBA

Bryan Sakamoto, MD, PhD

Kenneth Gwartz, MD

Author Affiliations: Surgery Service, Section of General Surgery, Richard L. Roudebush VA Medical Center, Indianapolis, Indiana (Eppstein, Munshi); Department of Surgery, Section of General Surgery, Indiana University School of Medicine, Indianapolis, Indiana (Eppstein, Munshi); Department of Anesthesiology, Richard L. Roudebush VA Medical Center, Indianapolis, Indiana (Sakamoto, Gwartz); Department of Anesthesiology, Indiana University School of Medicine, Indianapolis (Sakamoto, Gwartz).

Corresponding Author: Andrew Curtiss Eppstein, MD, Surgery Service, Section of General Surgery, Richard L. Roudebush VA Medical Center, 1481 W Tenth St, Indianapolis, IN 46202 (aeppei@iupui.edu).

Published Online: December 17, 2014. doi:10.1001/jamasurg.2014.1098.

Author Contributions: Drs Eppstein and Sakamoto had full access to all of the data in the study and take responsibility for the integrity of the data and the accuracy of the data analysis.

Study concept and design: Eppstein, Sakamoto, Gwartz.

Acquisition, analysis, or interpretation of data: Munshi.

Drafting of the manuscript: Eppstein.

Critical revision of the manuscript for important intellectual content: All authors.

Statistical analysis: Eppstein.

Administrative, technical, or material support: All authors.

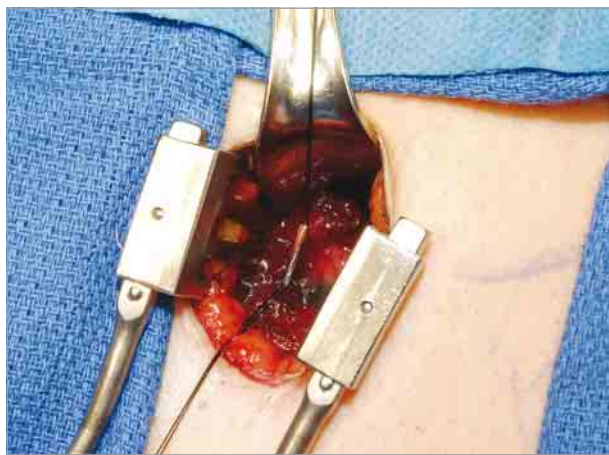
Study supervision: Eppstein, Munshi.

Conflict of Interest Disclosures: None reported.

Previous Presentation: This paper was presented at the 38th Annual Surgical Symposium of the Association of VA Surgeons; April 8, 2014; New Haven, Connecticut.

1. Rauchwerger JJ, Giordano J, Rozen D, Kent JL, Greenspan J, Closson CW. On the therapeutic viability of peripheral nerve stimulation for ilioinguinal neuralgia: putative mechanisms and possible utility. *Pain Pract*. 2008;8(2):138-143.
2. Zacet AC, Magill ST, Anderson VC, Burchiel KJ. Long-term outcome following ilioinguinal neurectomy for chronic pain. *J Neurosurg*. 2010;112(4):784-789.
3. Johner A, Faulds J, Wiseman SM. Planned ilioinguinal nerve excision for prevention of chronic pain after inguinal hernia repair: a meta-analysis. *Surgery*. 2011;150(3):534-541.
4. Malekpour F, Mirhashemi SH, Hajinasrolah E, Salehi N, Khoshkar A, Kolahi AA. Ilioinguinal nerve excision in open mesh repair of inguinal hernia—results of

Figure. Ilioinguinal Nerve Visible Against Blue-Stained Transversus Abdominis Muscle



a randomized clinical trial: simple solution for a difficult problem? *Am J Surg.* 2008;195(6):735-740.

5. Loos MJ, Scheltinga MR, Roumen RM. Tailored neurectomy for treatment of postherniorrhaphy inguinal neuralgia. *Surgery.* 2010;147(2):275-281.

6. Gofeld M, Christakis M. Sonographically guided ilioinguinal nerve block. *J Ultrasound Med.* 2006;25(12):1571-1575.

ASSOCIATION OF VA SURGEONS

Decreased Wait Times After Institution of Office-Based Hand Surgery in a Veterans Administration Setting

Carpal tunnel syndrome is a common peripheral nerve compression disorder causing symptoms of numbness, tingling, weakness, and muscle atrophy. Open carpal tunnel release (CTR) is a common treatment modality traditionally performed in the operating room with sedation or general anesthesia. It can also be performed in the surgeon's office under local anesthesia only.¹ In our study, we examined the number of days from initial consultation and visit to operative intervention in a Veterans Administration (VA) setting. A significant decrease in wait time from initial consultation to operative intervention and from initial visit to operative intervention was hypothesized to occur with the transition to office-based hand surgery procedures, without an increase in complications.

Methods | Institutional review board approval from the Richard L. Roudebush VA Medical Center was obtained to construct a database of recent surgical procedures performed for carpal tunnel syndrome by the plastic surgery service. Operations including CTR in conjunction with other procedures were excluded. The minor procedure room is located within the plastic surgery clinic, with a single nurse serving as a circulating nurse. The hand and forearm are prepped and draped, and both monopolar cautery and bipolar cautery are available. A more specific description to a similar configuration can be found in Leblanc et al.² The study variables collected were age, sex, tobacco use, procedure, time from initial consultation to surgery (in days), time from initial clinic visit to surgery (in days), location of the procedure (the minor procedure room in the surgeon's office or the operating room), and complications. An independent 2-tailed *t* test was used to compare mean values using SPSS version 20 (IBM).

Results | Two separate types of CTR were analyzed: office-based CTR (44 patients) and operating room-based CTR (54 patients). The **Table** contains a comparison of the 2 groups of patients who underwent 1 of the 2 types of CTR. Significant decreases in time from initial consultation to surgery and from initial clinic visit to surgery were observed in the office-based group ($P < .05$). There was no difference in complications between the 2 groups. Complications in the operating room-based group included 2 infections requiring oral antibiotics and 4 minor wound dehiscences that resolved with local wound care. In the office-based group, there were 2 infections (one requiring intravenous antibiotics and the other resolving with oral antibiotics) and 2 minor wound dehiscences.

Table. Demographic and Wait-Time Data

Data	Location Where Hand Surgery Was Performed		P Value
	Operating Room (n = 54)	Office (n = 44)	
Age, mean (SD), y	59.5 (11.9)	59.0 (12.2)	.84
Smoking status, No. (%)			
Current	17 (31.5)	12 (27.3)	
Former	13 (24.1)	6 (13.6)	
Never	23 (42.6)	24 (54.5)	
Unknown	1 (1.9)	2 (4.5)	
Female sex, No. (%)	5 (9.3)	4 (9.1)	.97
Time, mean (SD), d			
From initial visit to surgery	247.5 (178.2)	122.5 (139.4)	.05
From consultation to surgery	310.7 (168.7)	233.7 (154.3)	.05
Experienced complications, No. (%)	6 (11.1)	4 (9.1)	.75

Discussion | Office-based hand surgery procedures have been validated in a variety of settings but are not the default method of performing hand surgery procedures in the United States. We have demonstrated a significant decrease in time to procedure with the use of an office-based procedure in a VA setting, without sacrificing quality. Open CTR can be completed safely in the office; the complication rate was not statistically different between the 2 groups in our series. To our knowledge, this is the first description of decreased times to surgery due to the institution of office-based open CTR. Previous studies demonstrated that early intervention is associated with a faster return to daily activities of living and to normal function compared with late intervention.³ The limitations of our study include its retrospective nature and the steps of conservative management, including steroid injections, which are often offered to patients who do not wish to undergo surgery immediately. A wider application of office-based minor hand surgery would likely result in significantly increased patient access to surgery in the VA system.

Stephen Duquette, MD
Naveed Nosrati, MD
Adam Cohen, MD
Imtiaz Munshi, MD, MBA
Sunil Tholpady, MD, PhD

Author Affiliations: Division of Plastic Surgery, Department of Surgery, Indiana University, Indianapolis (Duquette, Nosrati, Cohen, Tholpady); Richard L. Roudebush VA Medical Center, Indianapolis, Indiana (Cohen, Munshi, Tholpady).

Corresponding Author: Sunil Tholpady, MD, PhD, Division of Plastic Surgery, Department of Surgery, Indiana University, RI 2514, 705 Riley Hospital Dr, Indianapolis, IN 46202 (stholpad@iupui.edu).

Published Online: December 23, 2014. doi:10.1001/jamasurg.2014.1239.

Author Contributions: Drs Duquette and Tholpady had full access to all the data in the study and take responsibility for the integrity of the data and the accuracy of the data analysis. Drs Duquette and Nosrati contributed equally to the manuscript and are considered as co-first authors.

Study concept and design: Duquette, Nosrati, Tholpady.

Acquisition, analysis, or interpretation of data: All authors.

Drafting of the manuscript: Duquette, Nosrati, Tholpady.

Critical revision of the manuscript for important intellectual content: All authors.

Statistical analysis: Duquette, Nosrati, Tholpady.