

## **Endodontic management of an Infected Immature Tooth with Spontaneous Root Closure and Type II Dens Invaginatus: A Case Report**

Ryan W. Baker, Kenneth J. Spolnik, Ahmed Ghoneima, **Ygal Ehrlich\***

**\*Correspondence: Ygal Ehrlich**

Indiana University School of Dentistry

Endodontics / Room 302

1121 W. Michigan Street

Indianapolis, IN 46202

**Phone: 317-274-7280**

**Fax: 317-274-5308**

**E-mail: [yehrich@iu.edu](mailto:yehrich@iu.edu)**

Ryan W. Baker, DDS, MSD is an Endodontist in private practice in Avondale, Arizona

Kenneth J. Spolnik, DDS, MSD Diplomate of ABE, Chair and Program Director, Endodontics, IUSD

Ahmed Ghoneima BDS, MSc, PhD, Orthodontics & Oral Facial Genetics, IUSD

Ygal Ehrlich, DMD Research Director Endodontics, Assistant Clinical Professor of Endodontics, IUSD

### **Acknowledgement**

We are grateful to D. Heid for her administrative support and editing of the manuscript and to N. Alderson from Illustrations IUSD for graphic editing.

This is the author's manuscript of the article published in final edited form as:

Baker, R. W., Spolnik, K. J., Ghoneima, A., Ehrlich, Y. (2015). Endodontic management of an Infected Immature Tooth with Spontaneous Root Closure and Type II Dens Invaginatus: A Case Report. *Journal of the Indiana Dental Association*, 94 (1), 36–41.

### **Abstract**

Apical periodontitis in an immature maxillary lateral incisor (#10) with arrested root development and a natural closure of the open apex in 22-year-old male was endodontically treated in a manner that conserved the existing hard tissue barrier (HTB). A dens invaginatus Oehlers II was also present. The patient reported no symptoms, but did recall an incident of dental trauma as a child. A 3D image showed

the nature of the HTB closing the open foramen as well as the anatomy of the immature root with the dens invaginatus. Porosities were seen in the HTB and that is consistent with the histological “Swiss Cheese” appearance known to occur in apexification. Endodontic treatment was performed in a single-visit. Access to the root canal system (RCS) included penetration through the dens invaginatus. The canal was not mechanically cleaned, but only irrigated with sodium hypochlorite, ethylenediaminetetra-acetic acid (EDTA), chlorhexidine using the EndoVac® system. The barrier was maintained and covered with a 5mm layer of mineral trioxide aggregate (MTA). A sterile damp sponge was placed on the MTA. On the following visit the MTA had set, and an EndoSequence fiber post was placed in the canal and EndoSequence dual-cure core build-up material was used to close the access and restore the tooth. A clinical and radiographic follow-up, 30 months after the initial treatment revealed resolution of the radiolucency and apical trabecular bone deposition and the patient was asymptomatic.

## **Introduction**

Closure of the open apex in an infected immature tooth is usually achieved after disinfection of the root canal and dressing it with calcium hydroxide or other materials. Spontaneous natural closure of an open apex in an immature tooth with a hard tissue barrier (HTB) has been observed following luxation injuries, but it is not commonly seen. (1, 2)

A single-visit endodontic treatment was performed in a 22-year-old man who presented with asymptomatic apical periodontitis (AP) in an immature maxillary lateral incisor (#10) with spontaneous root closure and a dens invaginatus Oehlers II. The research done on apexification and in regenerative endodontics provided the background for the treatment provided. The nature of the unusual anatomy of this tooth was assessed using Cone Beam Computed Tomography (CBCT) imaging. The treatment aims were to address the AP by disinfecting the RCS and yet not harm the HTB created or the cells responsible for its creation and maintenance. Disinfection of the canal was done solely by copious

irrigation with sodium hypochlorite, ethylenediaminetetra-acetic acid (EDTA) and chlorhexidine (CHX), and mineral trioxide aggregate (MTA) was placed over the HTB. After the MTA had set, the tooth was to be restored with resin restoration and a fiber post.

## **Case Report**

A 22-year-old male presented to the Graduate Endodontic Clinic at Indiana University School of Dentistry (IUSD) for evaluation of tooth #10. A periapical radiolucency (PARL) was detected on tooth #10 in radiographs taken as part of a hygiene recall exam. The patient presented with no symptoms. The tooth exhibited a lingual pit invagination (Figure 1) suggestive of a dens invaginatus. His medical history was unremarkable. The periapical radiographs and the CBCT scans (Figures 2 and 3) revealed:

1. A dens invaginatus, Oehlers Type II in which the dens ends below the proximal CEJ (Fig. 3)
2. An immature root with a wide canal and arrested root development
3. Natural closure of the open apex with a HTB containing a number of porosities.
4. A large PARL with extensive bone loss.

The clinical examination did not elicit a vital pulpal response and the tooth was not sensitive to percussion or palpation.

The clinical diagnosis was pulp necrosis with asymptomatic apical periodontitis in an immature tooth with arrested root development and a dens invaginatus (Type II).

After anesthesia and rubber dam isolation, access to the canal was achieved. The dens was included in the

access. The HTB was probed with a hand file and found to be complete, and the foramen was not patent.

Disinfection was done with copious irrigation (15 ml) with NaOCl 6%, using a conventional syringe and the EndoVac system (SybronEndo, Glendora, CA). It was then followed by irrigation with 6ml's each of EDTA

(Henry Schein, Melville, NY), 70% isopropyl alcohol (Dux Dental, Oxnard CA) and CHX 2% (CHX-Plus, Vista, Racine, WI) in that order using the EndoVac system (SybronEndo, Glendora, CA). Following disinfection, a layer of grey MTA, (MTA, Dentsply Tulsa Dental Specialties, Tulsa, OK) 5mm in depth was manually placed, followed by a sterile sponge moistened with sterile H<sub>2</sub>O. An interim restoration of grey Cavit (3M ESPE, St. Paul, MN) was placed over the sponge. A layer of IRM (Dentsply Caulk, Milford, DE) was placed over the grey Cavit to improve the seal (Figure 4).

On the following appointment (1 week later), the interim restoration was removed, and the MTA layer of had fully hardened. A final irrigation was performed with 5ml NaOCl 6%. The canal was dried and acid etched with phosphoric acid (35%) (UltraDent, South Jordan, UT) for 20 seconds, followed by a thin layer of bonding agent (OptiBond, Kerr, Orange, CA) which was then light cured. The canal was then back filled with EndoSequence (Brasseler, Savannah, GA) shade A2 dual-cure core build-up and an EndoSequence 0.06 fiber post was placed to length. The core material was light cured for 40 seconds and allowed to self-cure for 4 additional minutes. The post and core material were then trimmed flush with the cavo-surface margin. The occlusion was checked with articulating paper and adjusted so that there was minimal occlusal contact (Figure 4). Clinical and radiographic follow-up, 30 months after the initial treatment revealed resolution of the radiolucency (Figure 5) and apical trabecular bone deposition and the patient was asymptomatic.

A CBCT scan was taken using (Kodak 9000 Extraoral Imaging System, Carestream Health Inc. Rochester NY) according to the following protocol (Kv 85, MA 10 Voxel 76, scan time 45 seconds). The scanning data was assessed and the 3D images of the tooth and the HTB were reconstructed using InVivoDental Imaging software program (Anatomage Incorporated, San Jose, CA). The porosities seen in the HTB were consistent with the histological "Swiss Cheese appearance" of the HTB previously reported and which referred to soft tissue inclusions within the HTB. (3) On the following visit after the MTA had set, the tooth was restored with a fiber post and a resin core restoration.

The patient was observed for up to 30 months. Clinical and radiographic evidence of healing was seen and confirmed with a follow-up CBCT scan.

### Discussion

Clinicians frequently encounter the sequelae of trauma and are rarely present when the trauma actually occurs. It is important to be aware of possible healing responses. In this case we report the spontaneous closure of an open apex in an infected immature tooth with arrested root development. AP was controlled solely by irrigation and without instrumentation of the canal. The HTB was maintained and incorporated in the root canal filling.

Root development of the treated tooth was arrested when  $\frac{3}{4}$  of the root was formed and the foramen was fully open. It can be estimated (4) that the offending event occurred between the ages 8-11. This coincides with the patient's vague recollection of a dental trauma when he was very young. Apical periodontitis eventually developed after bacteria gained access to the root canal system (RCS) possibly through the lingual invagination. It could also be that infection at that age was the initiating event that interrupted root formation and not the early facial trauma. Hard tissue deposition can occur in the presence of infection (5-7) and a HTB can be formed even before the inflammation had been resolved. (8, 9) The wide diameter of the open apex and possible remnants of dental pulp cells could have contributed to the hard tissue deposition.<sup>19, 2</sup> Interestingly, the tooth had been asymptomatic for years and AP was only noticed on a routine oral hygiene exam.

Disinfection of the RCS in the immature tooth is challenging. Copious irrigation with minimal instrumentation is now recommended for disinfection of the infected immature tooth in regenerative procedures, (10) and was the treatment of choice for this case. An alcohol rinse was done before the irrigation with CHX to prevent interaction with sodium hypochlorite and potential discoloration.<sup>(11)</sup> EndoVac was included in our irrigation protocol as it was shown to be able to produce a sterile environment *in vivo*. (12, 13) The HTB was complete. The foramen was not patent nor was patency forcibly

attempted. The goal was to reduce the microbial insult causing the AP and maintain the HTB and use it as a barrier for containing the disinfectants and obturating material within the canal space. Furthermore, the naturally formed barrier has the potential to maintain itself as a protective barrier against the ingress of irritants.

The CBCT and the 3D imaging showed that the HTB contained porosities which were not seen in the periapical radiograph (Fig 2, 3). A 5mm layer of MTA was used placed on the HTB to seal the porosities and to augment the existing barrier (14, 15). MTA has also been successfully used in one visit apexification treatments MTA has mild antibacterial properties, is biocompatible with the apical tissue. (16) Intracanal MTA causes an increase in pH across dentin and has potential anti-resorptive properties.(17) Exposure of dentin to MTA can also bring about the release of fossilized bioactive molecules such as TGF  $\beta$ 1. (18) These could activate dental cells to form mineralized tissue which could contribute to the maintenance of the HTB.

The nature of the HTB formed in apexification has been investigated and the calcified tissue has been found to contain a mixture of cementum, bone, and dentin with inclusions of soft connective tissue islands giving the barrier a "Swiss Cheese" histological appearance.(3) These inclusions could be the voids seen in the CBCT image.

Hard tissue, cementum, dentin and bone can be formed in the presence of infection (5-7) and a HTB can be formed before the inflammation has been resolved. (8, 9) The wide diameter of the open apex and possible remnants of dental pulp cells could have contributed to the hard tissue deposition. (19, 20)

Restoration of the tooth was done with a fiber post and resin material which can bond to dentin and make the tooth less susceptible to tooth fracture as has been suggested. (16, 21, 22)

The naturally occurring HTB demonstrates the regenerative potential of the apical area. In the future, regenerative treatment of immature tooth may enable hard tissue to be preferentially formed all along

the canal walls including the cervical area. This could make which would make treated immature teeth less susceptible to root fracture.

Conflict of interest: We declare that there is no conflict of interest.

## References

1. Cvek M. Endodontic Management and the Use of Calcium Hydroxide in Traumatized Permanent Teeth. In: Andreasen JO, Andreasen FM, Andersson L, editors. Traumatic Injuries to the teeth. 4th ed. Oxford, UK: Blackwell Munksgaard; 2007. p. 598-657.
2. Barker BC, Mayne JR. Some unusual cases of apexification subsequent to trauma. *Oral Surg Oral Med Oral Pathol* 1975;39(1):144-150.
3. Trope M. Endodontic Considerations in Dental Trauma. In: Ingle JI, Bakland BL, Baumgartner CJ, editors. *Ingle's Endodontics*. India: BC Decker Inc; 2008.
4. Moorrees CF, Fanning EA, Hunt EE, Jr. Age Variation of Formation Stages for Ten Permanent Teeth. *J Dent Res* 1963;42:1490-1502.
5. Wang X, Thibodeau B, Trope M, Lin LM, Huang GT. Histologic characterization of regenerated tissues in canal space after the revitalization/revascularization procedure of immature dog teeth with apical periodontitis. *J Endod* 2010;36(1):56-63.
6. Torneck CD, Smith JS, Grindall P. Biologic effects of endodontic procedures on developing incisor teeth. II. Effect of pulp injury and oral contamination. *Oral Surg Oral Med Oral Pathol* 1973;35(3):378-388.
7. Torneck CD. Effects and clinical significance of trauma to the developing permanent dentition. *Dent Clin North Am* 1982;26(3):481-504.
8. Chosack A, Sela J, Cleaton-Jones P. A histological and quantitative histomorphometric study of apexification of nonvital permanent incisors of vervet monkeys after repeated root filling with a calcium hydroxide paste. *Endod Dent Traumatol* 1997;13(5):211-217.
9. Felipe WT, Felipe MC, Rocha MJ. The effect of mineral trioxide aggregate on the apexification and periapical healing of teeth with incomplete root formation. *Int Endod J* 2006;39(1):2-9.
10. AAE. Regenerative Endodontics. In. <http://www.aae.org/regenerativeendo/>; 2013.
11. Basrani BR, Manek S, Sodhi RN, Fillery E, Manzur A. Interaction between sodium hypochlorite and chlorhexidine gluconate. *J Endod* 2007;33(8):966-969.
12. Cohenca N, Heilborn C, Johnson JD, Flores DS, Ito IY, da Silva LA. Apical negative pressure irrigation versus conventional irrigation plus triantibiotic intracanal dressing on root canal disinfection in dog teeth. *Oral Surg Oral Med Oral Pathol Oral Radiol Endod* 2010;109(1):e42-46.
13. da Silva LA, Nelson-Filho P, da Silva RA, Flores DS, Heilborn C, Johnson JD, et al. Revascularization and periapical repair after endodontic treatment using apical negative pressure irrigation versus conventional irrigation plus triantibiotic intracanal dressing in dogs' teeth with apical periodontitis. *Oral Surg Oral Med Oral Pathol Oral Radiol Endod* 2010;109(5):779-787.
14. Steinig TH, Regan JD, Gutmann JL. The use and predictable placement of Mineral Trioxide Aggregate in one-visit apexification cases. *Aust Endod J* 2003;29(1):34-42.
15. Simon S, Rilliard F, Berdal A, Machtou P. The use of mineral trioxide aggregate in one-visit apexification treatment: a prospective study. *International Endodontic Journal* 2007;40(3):186-197.
16. Bogen G, Kuttler S. Mineral trioxide aggregate obturation: a review and case series. *J Endod* 2009;35(6):777-790.

17. Heward S, Sedgley CM. Effects of intracanal mineral trioxide aggregate and calcium hydroxide during four weeks on pH changes in simulated root surface resorption defects: an in vitro study using matched pairs of human teeth. *J Endod* 2011;37(1):40-44.
18. Tomson PL, Grover LM, Lumley PJ, Sloan AJ, Smith AJ, Cooper PR. Dissolution of bio-active dentine matrix components by mineral trioxide aggregate. *J Dent* 2007;35(8):636-642.
19. Laureys WG, Cuvelier CA, Dermaut LR, De Pauw GA. The critical apical diameter to obtain regeneration of the pulp tissue after tooth transplantation, replantation, or regenerative endodontic treatment. *J Endod* 2013;39(6):759-763.
20. Andreasen JO, Paulsen HU, Yu Z, Bayer T. A long-term study of 370 autotransplanted premolars. Part IV. Root development subsequent to transplantation. *Eur J Orthod* 1990;12(1):38-50.
21. Hemalatha H, Sandeep M, Kulkarni S, Yakub SS. Evaluation of fracture resistance in simulated immature teeth using Resilon and Ribbond as root reinforcements--an in vitro study. *Dent Traumatol* 2009;25(4):433-438.
22. Desai S, Chandler N. The restoration of permanent immature anterior teeth, root filled using MTA: a review. *J Dent* 2009;37(9):652-657.

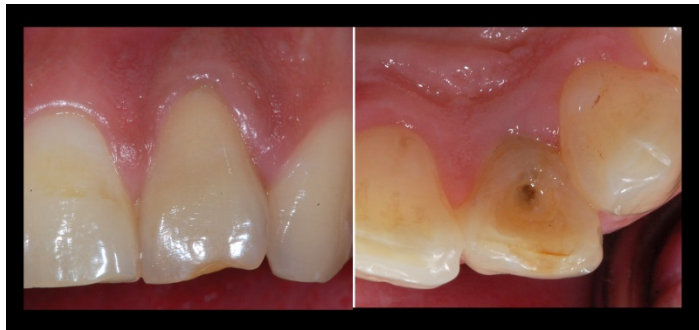

Fig 1. Clinical view taken at initial visit

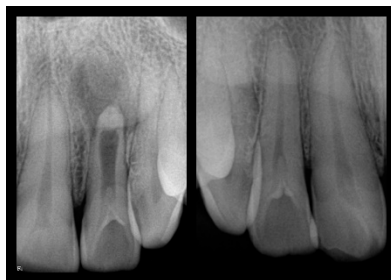


Fig 2 a. PA radiograph of maxillary lateral incisor #10 region at initial visit. Immature root with arrested root and spontaneous closure of the open apex is seen. A dens invaginatus type II is also noted **b**. A dens invaginatus type II was also seen on contralateral # 7, but root formation in # 7 was complete.



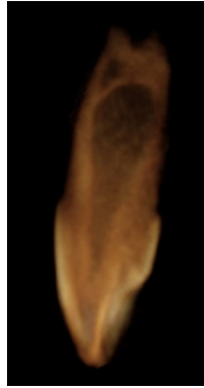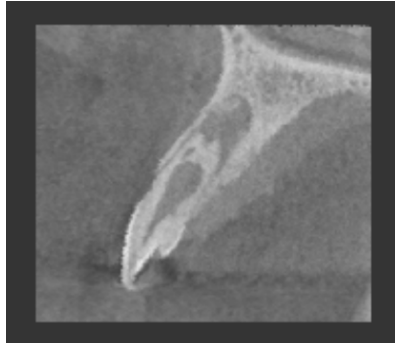


Fig 3 a. A CBCT image showing the immature root ,voids in the HTB and a PARL b. A 3D image of # 10, the void in the HTB is evident as well as the extension of the invagination into the tooth c. A 3D image of #10 video can be seen at <https://www.dentistry.iu.edu/index.php/departments/endodontics/research-case-reports/case-reports/>

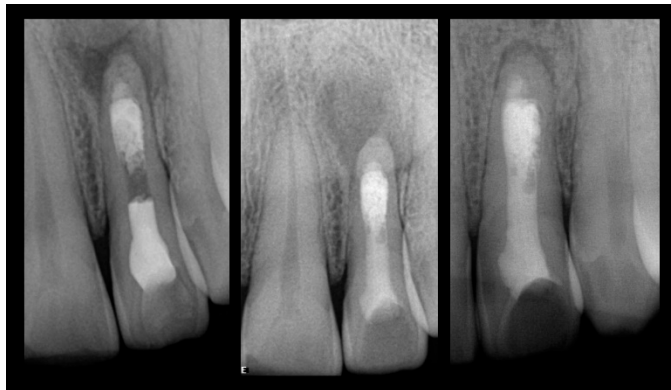


Fig 4. Stages in the Treatment. a. 5mm MTA was placed over the HTB and MTA was covered with a moist sponge and sealed with IRM b. Post and core restoration with EndoSequence post and EndoSequence core material c. #10: 30 month follow-up

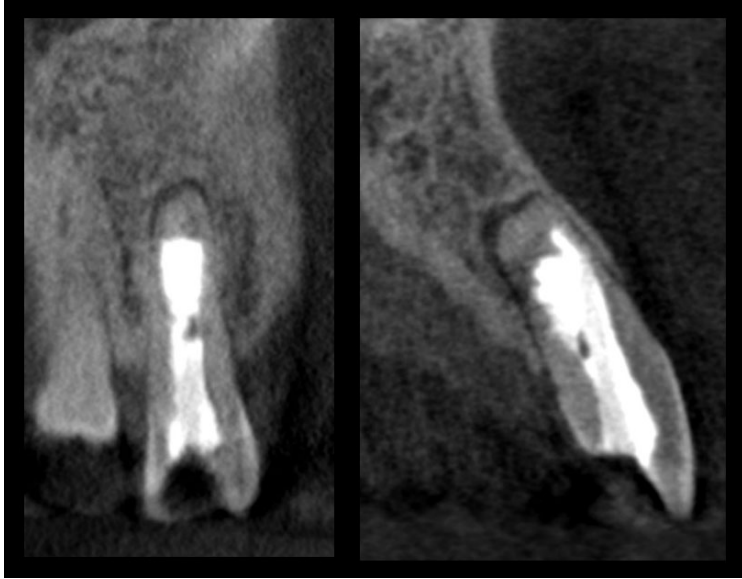


Fig 5. Post Op CBCT. Evidence of bone healing is seen in the apical area of #10. MTA layer appears relatively homogenous, but voids are seen in the composite resin restorations