

TOPICAL ANTIBIOTIC TREATMENT OF INFECTED
DENTAL PULPS OF MONKEYS

By

G. Richard Baker

Submitted to the Faculty of the Graduate School in
partial fulfillment of the requirements for the degree
of Master of Science in Dentistry, Indiana University,
School of Dentistry, 1966.

ACKNOWLEDGEMENTS

My wife Sydney, and children, Sarah and Richard, have been a great source of encouragement during this period of graduate education. It is to them that I dedicate this thesis.

Dr. David Mitchell has contributed immensely to this research and his guidance has been indeed appreciated.

I especially wish to thank Dr. Ralph McDonald who has been such a good friend and has provided assistance in so many ways.

Thanks to Miss Shirley Shazer and Dr. Milecent Henry for the very fine histologic sections. Mrs. Redford was an exceptional help in caring so well for the animals and preparing them for surgery.

Miss Rosmary Rocap, my classmates, and the members of the Pedodontic staff, assisted willingly when called upon.

Thanks to the Illustrations Department for preparation of photographic material and to Miss Lei Houchin for the splendid typing of this paper.

To the University of Indiana I wish to express my gratitude for the opportunity to have participated in the program of graduate education.

TABLE OF CONTENTS

	<u>Page</u>
INTRODUCTION.....	1
REVIEW OF THE LITERATURE.....	4
STATEMENT OF THE PROBLEM.....	24
EXPERIMENTAL PROCEDURE.....	25
I PILOT STUDY	
II PRINCIPAL STUDY	
DATA.....	34
TABLES AND ILLUSTRATIONS.....	43
DISCUSSION.....	58
SUMMARY AND CONCLUSIONS.....	67
REFERENCES.....	73
CURRICULUM VITAE	
ABSTRACT	

List of Tables

<u>Table</u>		<u>Page</u>
I	Histologic Results for Pulps Treated with the Antibiotic Compound.....	46
II	Histologic Results for Pulps Treated with the Starch Control.....	47

List of Illustrations

<u>Figures</u>	<u>Page</u>
1. Photograph, typical pulp exposure.....	48
2. Photomicrograph, section from an exposed pulp left open 24 hours.....	49
3. Photomicrograph, section from a tooth treated with the antibiotic compound (30 days postoperatively).....	50
4.&5. Photomicrographs, sections from teeth treated with the starch control (30 days postoperatively).....	50 & 51
6. Photomicrograph, section from a tooth treated with the antibiotic compound (30 days postoperatively).....	51
7. Photomicrograph, section from a tooth demonstrating epithelial proliferation (30 days postoperatively).....	52
8. Photomicrograph, section from a tooth demonstrating a fixation artifact.....	52
9.&10. Photomicrographs, sections from a tooth demonstrating perforation of the pulpal floor.....	53
11. Photomicrograph, section from a tooth treated with the antibiotic compound (90 days postoperatively).....	54
12. Photomicrograph, section from a tooth treated with the antibiotic compound (90 days postoperatively).....	54
13. Photomicrograph, section from a tooth treated with the starch control (90 days postoperatively).....	55

14.	Photomicrograph, section from a tooth treated with the starch control (90 days postoperatively).....	55
15.	Photomicrograph, section from a tooth treated with the starch control (90 days postoperatively).....	56
16.	Photograph, demonstrating intra-oral lesions (90 days postoperatively).....	56
17.	Photograph, demonstrating intact restorations (90 days postoperatively).....	57
18.	Photograph, demonstrating intra-oral lesion (90 days postoperatively).....	57

INTRODUCTION

Antibiotics have been used alone as pulp capping agents and as components of various pulp capping compounds in an attempt to preserve the vitality of teeth following pulpal exposure. In this regard they have been employed both locally and systemically. Success has been evaluated clinically and histologically. To date the results are inconclusive, as reports of clinical success are not corroborated by histological evidence. However, in reality, considering the many antibiotics that have long been available to dental research, and the fact that some twenty years have elapsed from the first antibiotic pulp capping experiment, there is a paucity of well controlled, thoroughly documented, investigations.

Presently, it is generally accepted that pulp capping procedures be limited to young, vital, asymptomatic teeth, accidentally exposed for a brief period of time in a relatively aseptic environment. Pre-operative diagnosis of pulpal status, based on objective and subjective evaluation, is thought to be critical and determines the method of treatment. The criteria of selection are so oriented that one must choose to treat only those pulps with minimal infection. If adhered to, the probability of extensive or advanced

involvement is lessened. However, the pathological status of a pulp so evaluated may well be of a more severe nature and yet still retain a significant degree of vitality. Regardless of the remaining vitality, if the tooth fails to meet the rigid criteria for capping, it cannot be considered a candidate for the procedure, and thus must be treated by more radical methods of conservation, or be removed. Therein lies the need for a pulp capping agent that can potentiate the innate ability of the vital pulp to effectively control and reverse the more severe infections.

This modified double-blind investigation was undertaken to examine the hypothesis that for any given species the utilization of an antimicrobial agent, innocuous to healthy tissue yet potent enough to destroy or control the invasive pathogenic oral microorganisms, could allow the natural defense mechanism of a vital pulp to overcome the infection, repair the damage, and survive.

In this experiment, two antibiotics in a starch vehicle were placed over surgically exposed and intentionally infected pulps of monkey teeth. In general, it was hoped that the results of this experiment would expand existing knowledge of the histologic response of the pulp to topically applied antibiotics, and possibly demonstrate

their effectiveness in treatment of the exposed vital pulp. More specifically, it was hoped that this particular compound would prove to be compatible with vital tissue and yet facilitate resolution of pulpal infection.

REVIEW OF THE LITERATURE

Antibiotics were prescribed for dental problems soon after their first clinical application in medicine. In 1942 penicillin therapy, as an entity, first appeared in the Quarterly Cumulative Index Medicus.¹ At approximately the same time the Index to Dental Literature² listed several dental publications which made reference to the drug. Great expectations were envisioned for its use in dentistry. It was only a matter of time until penicillin was used as a pulp capping agent. Since then, many different antibiotics, in numerous combinations, have been used for this purpose.

For purposes of organization and clarity this section will be broken down into sub-sections, each considered separately as it pertains to the treatment of pulp exposures with antibiotics. They are as follows: (1) use of antibiotics alone, (2) use of antibiotics combined with miscellaneous medicaments, and (3) use of antibiotics combined with corticosteroids.

The Use of Antibiotics Alone

3

In 1947, Bonner³ reported that out of 162 carious pulp exposures, only eight pulpal deaths resulted following the placement of a capping agent consisting of dry crystalline penicillin mixed with glycerine. It was felt that the pulp was a durable organ, and if infection was present,

it could be treated in the same manner as any other body tissue. Pre-operative and post-operative evaluations were not very thorough nor well documented; however the results were very encouraging.

4

In 1950, Kutscher reported the use of a penicillin capping agent on cariously exposed pulps. Clinical evaluation of 54 teeth six weeks post-operatively showed a 98 percent success rate. The author felt that penicillin, in effective concentrations, would be bacteriocidal against the bacteria most common in dental caries, diseased pulp chambers, and infected root canals. It was thought that this procedure demonstrated a definite advance in pulp therapy as most operators were reluctant to cap a "clean" surgically exposed pulp, let alone one resulting from the invasion of caries.

5

Webb, reporting in 1950, recommended the intramuscular injection of 300,000 units of procaine penicillin for the treatment of painful pulpitis and hyperemia. He believed one injection usually was sufficient; two were sometimes needed. No other adjunctive or supportive procedures were used. Sample size, controls, and methods of evaluation were not given. The article predominantly was conjectural in nature, but is significant in that it

emphasized a systemic mode of treating painful pulpitis.

6

In 1951, Gilberg, reported that when a pulp capping paste, consisting of penicillin and distilled water was placed over 205 pulpal exposures, 200 were considered clinically successful after a 36 month period of observation. The age range of the patients was from two to 50 years and age was not considered a significant factor in success or failure.

7

Rosen, in 1952, reported a 90 percent success rate using a penicillin pulp capping agent on deciduous teeth.

8

Amler further attempted to control pulpitis by systemic antibiotic therapy using penicillin and terramycin in 1954. He achieved 68 percent success in the treatment of 22 teeth which were candidates for root canal therapy or extraction and which had a history of pain. No adjunctive treatment was used.

9

James et al in 1957, investigated the histologic response of amputated pulps to calcium compounds and antibiotics. The teeth selected for the study had vital pulp exposures, presented a history of pain, and were ordered for extraction. The teeth were sedated for from one to seven days prior to the pulpotomy procedure. The total sample consisted of 113 teeth. Various calcium compounds

and antibiotics were used. From the data collected there appeared to be a direct relationship between the severity of inflammation and the incidence of internal resorption; and an inverse relationship between the degree of inflammation and the incidence of bridging. Since most of the antibiotic pulp studies conducted by this time had been with penicillin, it is interesting to note the responses in this study. Of nine teeth treated with penicillin, 11 percent showed calcific bridge formation or organization, 56 percent demonstrated internal resorption, and 89 percent showed moderate to severe inflammation. The other antibiotic preparations which were used were Grossman's polyantibiotic (penicillin, bacitracin, sodium caprylate), oxytetracycline* and chlortetracycline.⁺ The pulpal response to these was quite similar to that of penicillin. When an antibiotic was combined with a calcium compound, the pulpal response resembled that occurring as a result of the antibiotic alone rather than being due to the calcium.

* Terramycin, Pfizer Laboratories, New York, New York

+ Aureomycin, Lederle Laboratories (A Division of American Cyanamide Co.) Pearl River, New York

It is of interest to note the findings of Kutscher¹⁰ and Yigdall who stated that the antibacterial activity of penicillin is nearly completely destroyed when incorporated with calcium hydroxide. Their report showed that Aureomycin, streptomycin, and Terramycin retained some antibacterial activity when incorporated with calcium hydroxide.

¹¹
Ramnarine, reporting in 1956, included 75 teeth with carious exposures, 150 large cavities, and 20 pulp-tomies, in a study that described the use of Terramycin on infected pulps in children. The author reported three failures out of 245 teeth treated. His method specified that the antibiotic be left in place for only two to four minutes prior to placing the filling. The post-operative evaluation was made after three months and roentgenograms were made when deemed necessary.

¹²
In 1958, Seltzer and Bender observed that pulpal necrosis and the development of an apical granuloma occurred in every instance when an aqueous solution of 250,000 units of penicillin was used on vital pulp tissue of dogs. The medicament was applied to the pulp tissue, in solution, for a very short period. Following this application, asbestos fibers were used to cover the

exposure site and a covering of amalgam was placed. The sample consisted of 58 teeth from three dogs, observed for periods of seven, 30, and 90 days.

13

Maeth, in a 1959 study, observed successful resolution of pulpally involved teeth with deep carious lesions, complicated by rarefying osteitis, when treated with oxytetracycline applied topically. In addition, if the condition was acute, with a history of pain, oxytetracycline was administered systemically for 24 hours. Sample size was not given and many details were lacking.

14

Burke and Holmes investigated, in 1961, the effect of local antibacterial agents on bacteria in the dental pulps of rats. Bacteremias were induced by the intravenous injection of known quantities of Staphylococcus aureus. Various antibacterial agents were placed over the exposed pulps of 196 teeth. These agents were combined with zinc oxide and eugenol. Cultures were taken on one group of rats one day after injection, and on the other group at a seven day post-injection interval. Penicillin and Bacitracin* were the antibiotics used; they showed 47.5 percent and 50.9 percent positive cultures respectively. The same two drugs, on a smaller sample of rats, demon-

* Bacitricin, Lilly and Company, Eli; Indianapolis, Indiana

strated 6.9 percent and 0.0 percent positive cultures after the seven day interval.

The Use of Antibiotics Combined with Miscellaneous Medicaments

15

Burkman, in 1951, achieved a 75 percent success rate when a compound containing penicillin and camphorated parachlorophenol was used. The sample consisted of teeth so badly damaged that endodontics or extraction usually would have been the treatment. There was a history of pain in most cases and early periapical changes were seen on the radiographs of some. In this experiment care was taken not to expose the pulp, and the deeper layers of decayed dentin were not removed. In essence, the treatment amounted to an indirect pulp capping procedure.

16

Roth, in 1952, recommended that Aureomycin be mixed with zinc oxide - eugenol, copper cement, or zinc phosphate cement to be used as a pulp capping compound for deciduous teeth. Statistics were not given in this report and the observations were empirical. The author stated that by using the compound there resulted prolonged retention of the deciduous member until shed. Reference was not made as to whether resolution of the pathosis

17

took place. Lepine et al had previously observed that aureomycin interfered with pulp healing by retarding

proliferation of the fibroblasts and epithelial cells.

18

In 1953, Roberts reported on the adjunctive use of intramuscular penicillin injections in the treatment of exposed vital pulps. Calcium hydroxide was used locally. After 60 days 94 percent were evaluated clinically as being successful. After three years 23 of the original 44 treated pulps were re-evaluated. Of this number, 21 were still vital.

19

Seelig et al, in 1954 stated the results of an investigation whereby surgically exposed pulps of a Rhesus monkey were capped with penicillin G potassium plus calcium carbonate. This was the first histological evaluation of an antibiotic pulp study. The pulps of 20 teeth were exposed and the pulp tissue macerated by the bur. The experimental penicillin capping compound was then placed over the exposure site in 11 teeth. Of the remaining teeth a mixture of zinc oxide - eugenol was placed on four, zinc phosphate cement on one, two were left open, and nothing was done on the other two. There was a time lapse of seven days from the time of operation to that of sacrifice and fixation. It was observed at the time of extraction that seven of the 11 zinc phosphate cement coverings, over the antibiotic paste, were missing and one

was loose. When the zinc oxide - eugenol contacted the pulp an inflammatory response occurred with subsequent abscess formation. Similar results occurred when the zinc phosphate cement was placed in direct contact with the pulp. A normal pulp was observed under all applications of the penicillin capping compound. Unfortunately the sample size was small and the loss of so many protective coverings, over the experimental drug, further mitigated the conclusions.

20

Via, reporting in 1955, described a histologic study of four monkey teeth. Pulpotomies were performed and the following materials placed; (1) Grossman's poly-antibiotic (penicillin-bacitracin-streptomycin-sodium caprylate in a vehicle of silicone fluid) plus barium sulphate, (2) Calcium hydroxide, (3) Barium sulphate and, (4) A control of zinc oxide - eugenol. Success was achieved in 1, 2, and 3. The sample was very small and the antibiotics were not tested apart from the other ingredients.

21

Englander et al conducted, in 1956, a clinical evaluation of pulpotomies in young adults. The sample consisted of 228 teeth of which the majority had been associated with a history of pain and had been ordered for

extraction. Grossman's PBSC paste, tetracyclines (Aureomycin and Terramycin), penicillin powder, and *Chloramphenicol, were some of the antibiotics used on 61 teeth. The tetracyclines in calcium salts (unspecified), and Grossman's PBSC demonstrated 100 percent clinical success. Tetracycline in non-calcium dilutants showed 82 percent success; penicillin powder (undiluted) 36 percent success; and chloramphenicol was not successful at all. The findings seemed to indicate that antibiotics in combination with one another, or with calcium compounds, enhanced their therapeutic value in pulpotomy.

22

Feitelson, in 1956, tested a pulp capping paste which combined calcium hydroxide and approximately 10,000 units of crystalline penicillin G. Out of 83 permanent and deciduous teeth with carious pulp exposures, followed for a minimum of one year, only seven failures resulted. Acute periapical abscess or periapical bone change constituted failure. The rate of success was 91 percent in the primary teeth and 92 percent in the permanent teeth.

23

In 1957, Gollobin reported the use of a compound containing Terramycin and zinc oxide - eugenol, on an unspecified number of teeth with near or actual pulpal

* Chloramphenicol, Parke; Davis, and Company, Detroit, Michigan

exposure, and on pulpotomized teeth. Statistics were not given concerning sample size, controls, or degree of success. Operated teeth were followed for one year and the author observed few failures.

24

Sanders, in 1959, described the use of a paste containing *Achromycin, camphorated parachlorophenol, and calcium hydroxide suspended in a solution of methyl cellulose. The sample consisted of extensively carious teeth with some having pulp exposures. Of 38 teeth treated, 34 were considered successful. Success was achieved if all adverse clinical symptoms had disappeared upon re-examination of the patient at a later date, the time of which was unspecified.

25

In 1960 Shay et al used a pulp capping paste containing achromycin, parachlorophenol, and calcium hydroxide. They achieved a 97 percent success rate when this paste was applied to pulp exposures.

26

Gardner et al reported, in 1962, on experimentally induced pulp exposures on the teeth of dogs made by high speed instruments. The basic drug evaluated was Neosporin.

* Achromycin; Lederle Laboratories (A Division of American Cyanamide Co.) Pearl River, New York

+ Neosporin, Burroughs, Wellcome & Co. (USA) Inc., Tuckahoe, New York

The drug is a combination of polymixin B, bacitracin, and *Neomycin. Para-monochlorophenol was used with Neosporin on one part of a sample of 27 teeth. The other portion was capped with the above mentioned drugs in addition to calcium hydroxide. When the 27 teeth were histologically evaluated 26 showed degenerative changes, including acute pulpitis in 24 of the teeth, an abscess in one, and hyaline necrosis in another.

The Use of Antibiotics Combined with Corticosteroids

27

Sidky in 1957 described the use of a medicament for use in pulpotomy; it consisted of hydrocortisone, ommacillan, and calcium hydroxide. Prerequisites for its use were asymptomatic teeth in young healthy patients. He considered the medication to be very effective.

28

Kiryati reported, in 1958, that a combination of drugs was more effective than one drug used alone. The sample consisted of 192 maxillary first molars in 96 albino rats. Different combinations of medicaments were placed and the results evaluated histologically. Hydrocortisone was in all combinations except one, that being a mixture of oxytetracycline and chloramphenicol with calcium carbonate, or zinc oxide - eugenol. The animals

* Neomycin, Lilly and Company, Eli; Indianapolis, Indiana

were sacrificed at two, four, and from eight to 12 week intervals. Serial sections were then made. The most effective combination, when evaluated from eight to 12 weeks, was hydrocortisone, oxytetracycline and chloramphenicol, which produced complete healing in 52 percent of the teeth, incomplete healing in 38 percent, with necrosis occurring in 12 percent. Hydrocortisone, Neomycin, and bacitracin produced 20 percent complete healing, 20 percent incomplete healing, and 20 percent necrosis, over the same period of time. The antibiotic mixture without hydrocortisone, but still with calcium hydroxide or zinc oxide - eugenol, showed 40 percent complete healing, 30 percent incomplete, and necrosis occurred in 30 percent. In this study, incomplete healing is described as calcific bridging still in the primary stages of formation, showing irregular fibrous calcification without regular dentin being formed, but with the final result of healing.

It was mentioned that the pulps were exposed and left open from one to 48 hours. Reference is made to this throughout the article, but thorough documentation and any correlations with regard to the extent of infection and the time left exposed is lacking. It is interesting to note the similarity of procedure in this experiment and that of

29

Kakeashi et al who made pulpal exposures on the molar teeth of germ-free and conventional rats.

30

Kiryati observed the effects of streptokinase in combination with oxytetracycline and cortisone in 1962. Pulpal exposures were made in the molar teeth of white rats and treated with various combinations of the aforementioned drugs. Streptokinase did not seem to affect the healing potential of the drug. There was a similar pulpal response under all the medications; however, the combination containing streptokinase, oxytetracycline, and cortisone was found to be more successful.

31

In 1962 Schroeder and Triadan reported on the incorporation of a synthetic corticoid, triamcinolone, into an ointment containing Chloramphenicol and a four percent xylocaine solution. This ointment was used on vital teeth that presented a history of severe pulpitic toothache. A total of 214 teeth, mostly posteriors, were treated. The average patient age was 28.5 years. Pain disappeared in most instances two to three hours following the initial application. At the end of two to three weeks pain was not in evidence and all teeth showed normal vitality. The histologic picture of two teeth, one healthy, the other diseased, was briefly described. A diseased canine of a

17 year old patient with a history of clinically severe pulpitis, demonstrated slight hyperemia with no signs of acute inflammation.

32

In 1962, Fiore-Donno and Baume experimented with the application of various compounds, each containing a corticosteroid and an antibiotic, on pulpotomized teeth with a history of painful pulpitis. Although clinical symptoms disappeared, giving every indication of successful resolution of the inflammatory status of the pulp, histological corroboration of success was lacking. Serious disadvantages to the use of these corticoid-antibiotic compounds included the absence of a solid barrier. An open pulp may become increasingly susceptible to reinfection as the hermeticity of the filling material decreases with age. Also metaplastic fibrosis of the pulp, arrested dentin formation, and residual or induced chronic inflammation were observed.

33

In 1964, Olsen reported on the use of a cortico-antibiotic preparation on 370 cases of hyperemia, pulpitis, and apical periodontitis. After six to 12 months of clinical observation only one percent of the teeth treated were considered failures.

34

Mager reported, in 1964, on the treatment of pulpitis with synthetic steroids combined with antibiotics. This

experiment constituted a clinical pilot study. The experimental compound used was Ledermix - R. Of the 20 teeth treated, 19 remained vital at the end of six months.

35

In 1964, Ehrman described the use of Ledermix "A" and "B" on a variety of pulpal conditions ranging from hyperemia to acute suppurative pulpitis. It was significant that 16 of 22 teeth, in the suppurative pulpitis category tested non-vital six months following treatment even though the initial pain had subsided. Success with the compound was higher in the treatment of hyperemia than in the more severe forms of pulpal pathology.

36

Lawson and Mitchell, combined erythromycin and streptomycin with a potent steroid, *flurandrenolone, to treat 52 teeth giving a history of painful pulpitis. A double-blind procedure was used in which the pulps were capped with the experimental compound in 25 teeth and with a starch control in 27 teeth. The results were evaluated up to 164 days. There were no failures among the teeth treated with the experimental drug and the teeth treated with the control showed 52 percent success.

An attempt was made to correlate the clinical and histological condition of seven teeth. Histopathologically,

* Cordran R Lilly and Company, Eli; Indianapolis, Indiana

the pulps capped with the experimental compound showed a decided advantage over those treated with the control. In the former, tissue reactions were less severe and new hard tissue formation was more evident in an attempt to close off the exposure site.

Clinically, painful pulpitis appeared to be reversible. The limited histological evaluation tended to support this. However, it was mentioned that what appeared to be clinical success at the present, may prove to be future failures.

37

Baume listed indications for treatment of various pulpal conditions in 1965. He recommended that pulp capping be used only when the cavity is in close proximity to the pulp or when there has been an accidental exposure. Further, the tooth must be asymptomatic. Caution is made against the use of mixtures of cortisone, antibiotics, and calcium hydroxide, which seem to produce clinical success but when evaluated histologically, show a degenerative condition. It was stated that, without exception, there occurred fibrous metaplasia of pulpal tissue, irreversible inhibition of dentinogenesis, and chronic inflammation. All of the preceding occur without clinical symptoms and may result in the pulp dying after what

had appeared to be successful healing.

Mullaney et al³⁸ continued, in 1966, with a study³⁸ initiated by Lawson and Mitchell in which a portion of the original sample was recalled for further clinical evaluation. Of 21 teeth that received treatment, 15 were still considered to be successful. This represented a significant drop from the 100 percent success reported in the preliminary investigation. A stringent double-blind testing procedure was used in this portion of the investigation and also in the histologic portion of the study.

In the second part of this investigation the experimental corticoid-antibiotic compound (erythromycin, streptomycin, flurandrenolone) and the starch control were applied to the mechanically exposed pulps of monkey teeth. A modified double-blind procedure was used in which one-half of the sample of 28 teeth were treated with the experimental compound and the other one-half treated with the control. Twelve teeth were removed and histologically evaluated after 90 days and the remainder after 180 days. Regardless of when the teeth were removed, for both the experimental drug and the control, the major portion of the pulp tissue in all teeth was

normal, with the exception of two starch controls which showed abscess formation and marked inflammation. The corticoid-antibiotic treated teeth showed a significantly larger deposition of dentinoid "bridging" material under the exposure site when compared to teeth treated with the starch controls.

The clinical portion of the investigation indicated that painful pulpitis was a reversible process and that the corticoid-antibiotic mixture is of therapeutic value. The animal study indicated that there was some advantage to using the experimental drug, although there was not an appreciable difference from those pulps which were treated with the starch controls.

39

Schneider and Lawson conducted a double-blind pulp capping study which attempted to evaluate on a comparative basis a corticoid-antibiotic mixture^{36,38} and a calcium hydroxide powder for treating exposed pulps in primary teeth. Clinical success was recorded: 76 percent in 29 teeth treated with the corticoid-antibiotic mixture and 90 percent in 29 teeth treated with calcium hydroxide. Calcium hydroxide proved to be more effective in the treatment of carious exposures. An attempt was made to do all capping procedures under conditions approximating asepsis.

Eleven of 14 teeth removed for histopathologic study were pre-planned surgical exposures. Histologically, none were considered to be completely successful although all were considered clinically successful.

STATEMENT OF THE PROBLEM

Pathogenic microorganisms are considered to play a prominent role in the initiation of pulpal pathology when the vital dental pulp is exposed. There is evidence to indicate that the presence of bacteria is the most significant factor in prohibiting healing.

The review of literature describes many experiments whereby antibiotics have been used to cap exposed pulps. It is felt that additional investigation into this area is warranted since the results have tended to be conflicting and inconclusive.

This double-blind investigation was undertaken to examine the hypothesis that for any given species, the utilization of an antimicrobial agent, innocuous to healthy tissue, yet potent enough to destroy or control the invasive pathogenic organisms, would allow the natural defense mechanism of a vital pulp to overcome the infection, repair the damage, and survive.

This experiment should expand existing knowledge of the pulp's response to topically applied antibiotics, and reveal the effectiveness of such treatment for the exposed, contaminated, vital pulp.

EXPERIMENTAL PROCEDURE

PILOT STUDY

Preparation of the Animal for Surgery

One Macaca mulatta monkey was used for the study. The animal was removed from its cage and anesthetized with the help of laboratory assistants. Nembutal sodium was injected intraperitoneally by means of a 20 gauge short needle. The recommended dosage was used; 1.00 ml (10 mg) of nembutal sodium for every three pounds of body weight. It was necessary in several instances to give an additional $\frac{1}{2}$ ml to obtain a more profound level of anesthesia.

The animal was then placed on the operating table in a supine position with the head tilted back to provide an unobstructed airway. To facilitate movement of the tongue for ease of operation and visibility, it proved advantageous to clamp the tip of the tongue with a large hemostat. This also aided in keeping a clear airway by preventing ingress of the tongue.

Surgical Procedure

The pulps of the permanent maxillary and mandibular central incisors were surgically exposed. Bacterial contamination was desirable and therefore a rubber dam or other aseptic measures were not employed.

A class V cavity preparation was made on each permanent tooth. High speed rotary instrumentation, using a No. 57 or No. 58 friction grip bur rotating at maximum speed, under approximately 30 pounds of pressure, was used to cut the preparation to a depth closely approximating the pulp. A water spray was not used in the cutting procedure. An assistant intermittently administered short blasts of air to clear the area of debris. A careful attempt was then made, with a slowly revolving latch type No. 4 round bur, to remove additional dentin to a point just short of entering the pulp.

It had been intended that the exposure be made with a hand instrument to minimize the number of dentin chips introduced during surgical exposure. An explorer point was used to expose the pulps of the two maxillary incisors and the No. 4 round bur penetrated the pulps of the two mandibular incisors. The actual exposures were fairly large in each instance and bleeding was induced with the No. 4 bur or the explorer point.

The exposed pulps were left open to the oral environment for approximately 24 hours. At the end of 24 hours, the teeth were extracted and placed in a 10 percent formalin solution.

Conventional surgical procedures were used to extract the teeth. Removal of the labial plate of bone with an automatic bone impactor (Dudley) facilitated the extractions. Pedodontic forceps No. 101 proved to be of considerable value as they were readily adaptable to the anatomical form of the teeth.

Laboratory Procedure

The teeth were then removed from the 10 percent formalin solution and ground down on the mesial or distal surface of the tooth with a rotating stone wheel under a water spray until the pulpal outline could be seen. The teeth were then placed back in the 10 percent formalin for complete fixation.

Decalcification and the remainder of the work was performed by a laboratory technician. Serial paraffin sections seven microns thick were made through the exposure site. Alternate sections were then stained with a Brown and Brenn stain which is a differential staining method for demonstrating bacteria in tissue sections. Selected alternate sections of each tooth also were stained with hematoxylin and eosin in the conventional manner.

PRINCIPAL STUDY

Formulation of Medicaments

The drugs used in this study were manufactured by Eli Lilly and Company. The composition of the experimental compound was as follows:

Erythromycin estolate (Ilosone R)	10%
Streptomycin sulfate	10%
Starch	q. s.

The control capping material was composed of pure starch.

The materials to be tested, coded and labeled compound A and B, were dispensed in small brown bottles to the investigator who was not aware of the identity of the contents. The study was then carried out using one principle of a double-blind testing procedure. The investigator, not aware which medicament he was using, could not be biased in favor of either material.

The physical properties of the two materials were very similar and could not be visually differentiated unless labeled. The bottle labeled compound A contained the starch control and the bottle labeled compound B contained the antibiotic compound.

Preparation of the Animals for Surgery

Two Macaca speciosa and one Macaca mulatta monkeys were used for the study. Each animal was removed from its cage and anesthetized with the help of laboratory assistants. Nembutal sodium was injected intraperitoneally by means of a 20 gauge short needle. The recommended dosage was used; 1.00 ml (60 mg) of Nembutal sodium for every three pounds of body weight. It was necessary in several instances to give an additional $\frac{1}{2}$ ml to obtain a more profound level of anesthesia.

The animal was then placed on the operating table in a supine position with the head tilted back to provide an unobstructed airway. At this time full mouth radiographs were made. To facilitate movement of the tongue for ease of operation and visibility, it proved advantageous to clamp the tip of the tongue with a large hemostat. This also aided in keeping a clear airway by preventing ingress of the tongue.

Surgical and Therapeutic Procedures

The pulps of 57 anterior and posterior permanent teeth and nine posterior deciduous teeth were surgically exposed. Bacterial contamination was desirable and therefore a rubber dam or other aseptic measures were not employed.

A class V cavity preparation was made on each permanent tooth and an occlusal preparation made for each deciduous tooth. High speed rotary instrumentation, using a No. 57 or No. 58 friction grip bur rotating at maximum speed under approximately 30 pounds of pressure, was used to cut the preparation to a depth closely approximating the pulp. A water spray was not used in the cutting procedure. An assistant intermittently administered short blasts of air to clear the area of debris.

The method of exposing the pulp for the permanent anterior teeth was essentially the same as that used in the pilot study. However the pulps of the permanent posterior teeth and the deciduous teeth were routinely exposed with a high speed friction grip No. 57 or No. 58 bur rotating at maximum speed under approximately 30 pounds of pressure. After each exposure the pulp was further macerated by an explorer point or by the bur itself. The actual exposures were fairly large in each instance (Figure 1).

Each exposed pulp was left open to the oral environment for at least 24 hours and no longer than 26 hours. The animal was then anesthetized in essentially the same manner as the day before. Impacted food debris was

removed by means of a small spoon excavator and short blasts of air. The cavity preparation was wiped clear with a cotton pledget moistened with saline solution. Just prior to insertion of the capping material saliva from the tongue and vestibular areas was carried into the pulp on the tip of an explorer point in a further attempt at contamination. This also served to disrupt the blood clot.

The preparations were then dried with air and one of the experimental pulp capping agents was placed into and over the exposed pulp.

The capping agents were mixed with ordinary tap water to a slightly moist, but firm, consistency. An amalgam carrier was used to carry the capping agent to place and a TP 3 plastic instrument (Tarno) was used to firmly tamp the material to position. In the process a small amount of the material was purposely forced into the pulp and a moderate amount was spread out over the floor of the preparation. Upon setting the excess material was then trimmed from the walls of the preparation with a No. 557 bur rotating at a very low speed. This was followed by the insertion of a thick mix of zinc oxide - eugenol into which crystals of zinc acetate had been incorporated to

accelerate setting. The surface of the restoration was then smoothed to conform to the outline of the tooth.

Twenty-nine permanent teeth and nine deciduous teeth were extracted 30 days following treatment. Twenty-eight permanent teeth were extracted 90 days following treatment.

Conventional surgical procedures were used to extract the teeth. Removal of the labial and buccal plates of bone with an automatic bone impactor (Dudley) or surgical bur greatly facilitated the extractions. Pedodontic forcep No. 101 proved to be of considerable value as the beaks were readily adaptable to the anatomical form of the teeth.

Immediately upon extracting a tooth it was placed in a 10 percent formalin solution for initial fixation. Alternate placement of the unknown capping materials was used in order to obtain a better distribution of teeth treated with the antibiotic compound and the starch control.

The animals were placed on a soft diet until sacrificed in order to minimize abrasion of the restorations.

Clinical Observations

A brief oral examination was made 15 days postoperatively to check primarily on the intactness of the zinc oxide - eugenol restorations.

At the time each animal was sacrificed a very complete

oral examination was given. Soft tissues were observed for evidence of clinical pathology, restorations checked for intactness, and each tooth tested for mobility. In addition, the weight of each animal was recorded and compared to the pre-operative weight. Full mouth radiographs were also taken at this time.

Laboratory Procedures

The teeth were then removed from the fixing solution and ground down with a rotating stone wheel under a water spray until the pulpal outline could be seen. The teeth were then placed back in the 10 percent formalin for complete fixation. Decalcification and the remainder of the work was performed by a laboratory technician. Serial paraffin sections seven microns thick were made through the exposure site. Alternate sections were then stained with hematoxylin and eosin in the conventional manner. Selected alternate sections of each tooth were stained with Brown and Brenn stain which is a differential staining method for demonstrating bacteria in tissue sections.

DATA

The pilot portion of the investigation was designed to ascertain if the surgically exposed pulps of a Macaca mulatta monkey were actually infected by being left open to the oral environment for a period of approximately 24 hours.

Histologic serial sections were made of two maxillary and two mandibular central incisors. Microorganisms were demonstrated by using a Brown and Brenn ⁴⁰ staining technique. The microorganisms were observed in scattered clusters in the immediate area of the exposure and appeared to be gram-positive cocci (Figure 2). The gram-positive cocci were the only bacteria which could be identified with reasonable ⁴¹ accuracy when this staining technique was used. Stanley has made the observation that in their studies, using the Brown and Brenn staining technique, they do not look for gram-negative organisms because dead gram-positive bacteria will frequently appear gram-negative.

In the principal portion of this investigation 57 permanent teeth and nine deciduous teeth were extracted for microscopic study. The pulps had been surgically exposed, left open to the oral environment for approximately 24 hours, and then capped with either the antibiotic or control medicaments. Histological evaluation of each specimen

may be seen in Tables I and II.

CLINICAL OBSERVATIONS

Oral Examination 15 Days Following Treatment. The animals were forcibly restrained and only a superficial examination was given at this time. There were no detectable discrepancies and all of the restorations appeared to be intact.

Oral and Radiographic Examination 30 Days Following Treatment.

All of the animals registered weight gains and appeared to be in good health. An oral examination was given each while under general anesthesia. The class V restorations in the permanent teeth were in place and appeared to be intact. Six of the occlusal restorations in the deciduous teeth had been lost and three appeared to be loose. A small mass of fibrous tissue was observed in three of the cavity preparations from which the restorations had been lost. Excessive mobility was negative for all of the permanent teeth and positive for six of nine deciduous teeth.

Draining palatal fistulas were observed in the area of the permanent maxillary right second molar and the permanent maxillary left second premolar, designated No. 16 and 20 in Table II. An area of vestibular swelling and drainage was seen opposite the lower left first premolar,

designated No. 22 in Table II. Intra oral radiographs revealed radiolucent areas around the roots of these teeth.

Oral and Radiographic Examination 90 Days Following Treatment.

Only one animal remained at this examination. Once again a weight gain was registered and the clinical picture was relatively unchanged at this time. The intra oral lesions observed at the 30 day examination continued to be evident and presented a quite similar appearance both clinically and radiographically (Figures 16 and 17).

It is very significant that the zinc oxide - eugenol restorations were in place and apparently intact in each of the teeth treated with antibiotic capping material or starch control capping material (Figure 18).

Although not pertinent to this investigation, it was observed that marked deposits of calculus accumulated in the 90 day post-operative period (Figures 1, 17 and 18).

HISTOLOGIC EVALUATIONS

Histologic Evaluation of Permanent Teeth 30 Days Following Treatment. An inflammatory response of varying degree was seen at the exposure site in each of 26 pulps evaluated 30 days following treatment. Inflammation was considered to be relatively mild or moderate in all of the antibiotic

treated pulps and was limited to the immediate vicinity of the exposure in six specimens of this group. The remainder showed inflammatory cells extending beyond the exposure but still limited to the coronal portion of the pulp. The inflammatory cells were few in number and were mostly lymphocytes and plasma cells. By far, the greater portion of the pulp was intact, free of inflammation, and considered to be normal (Figure 3).

Pulps treated with the starch control capping material exhibited a much wider range of inflammation. In the majority of the control teeth, there was a picture of severe inflammation extending into the deeper confines of the pulp (Figure 4). Complete necrosis was evident in several pulps (Figure 5) and microorganisms could often be observed when the pulp was necrotic. Five pulps treated with the control capping material presented a response quite similar to those treated with the antibiotic, in that they showed a mild to moderate inflammatory picture with moderate to large depositions of reparative dentin. However, one of the five pulps exhibited a small amount of reparative dentin.

As a group, the pulps treated with the antibiotic compound demonstrated a decidedly milder and more favorable

inflammatory response than did those pulps treated with the starch control. Some vaso-dilatation was observed in all of the pulps when vital tissue was present.

Reparative dentin was deposited on the walls and around dentin chips which had been introduced in exposing the pulp, in large amounts in all pulps treated with the antibiotic medication. The dentin formed according to the pattern of the disturbed odontoblastic processes cut during cavity preparation in the vicinity of the exposure and appeared to form on the opposite wall only when dentin chips were located in close proximity. Reparative dentin around a chip often coalesced with that around other chips and with depositions on the walls to create an attempt at bridging. Complete bridging was not seen in any pulp but the extent of this phenomena appeared to be proportional to the alignment and number of chips and the amount of reparative dentin deposited around them (Figure 6).

Pulps treated with the control medication did not show consistent deposition of dentin on the walls nor around the dentin chips. The majority exhibited small to negligible amounts. Three pulps in this group demonstrated deposition in abundance with a good bridging attempt. In most instances a negligible amount of reparative dentin was seen when

the pulp was severely inflamed or necrotic.

A thin band of epithelial tissue had proliferated over the exposure site in one of the antibiotic treated pulps (Figure 7). Beneath this were many chronic inflammatory cells which were limited to the coronal portion of the pulp and diminished in number as they extended apically. Reparative dentin was present in large amounts but the arrangement of the chips was not conducive for coalescence of the new dentin.

A maxillary left lateral incisor presented an unusual appearance which was the result of having been allowed to remain out of the fixative solution for approximately 12 hours (Figure 8) before being found. After having been initially fixed for approximately two hours the tooth was lost while grinding it down to the pulpal outline in order to achieve a more complete fixation.

Three other teeth extracted at this time were not considered acceptable for the study. Sufficient histologic detail for evaluation was lacking in two and another was discarded because the pulpal chamber was perforated upon exposing the pulp. The importance of serial sectioning is well illustrated in this example as one section shows an intact lower pulp chamber while in another the perforation

is obvious and shows a peri-coronal granuloma (Figures 9 and 10).

Prior to sacrificing one animal, the pulps of two unoperated teeth were exposed in essentially the same manner as the other pulps. One pulp remained exposed for one-half hour and the other for one hour. They were then extracted, prepared for histologic study, and serially sectioned. Brown and Brenn stained sections were negative for bacterial contamination.

Histologic Evaluation of Deciduous Teeth 30 Days Following Treatment. The pulps of nine deciduous teeth were exposed and treated in essentially the same manner as were the permanent teeth. The only difference being that each exposure was made on the occlusal surface. This was necessary due to severe attrition which had sharply reduced the clinical crown height thereby making class V preparations impractical.

Many complications were encountered with the deciduous teeth. Two teeth which were badly fragmented during extraction could not be microscopically studied. Advanced physiological root resorption distorted the histologic picture of two others and three teeth exhibited pulp polyp formation in the cavities from which restorations had been lost.

At the time of extraction six of nine restorations had been lost and the other three were loose. In order to correctly evaluate the pulps treated with the two capping materials an effective seal of the preparation was considered to be essential. Since the restorations were lost and there was not an adequate seal of the cavity, and in view of the previously mentioned complications, there was considerable doubt as to the reliability of the histologic interpretations. A decision was made to eliminate from the study the results for the deciduous teeth.

Histologic Evaluation of Permanent Teeth 90 Days Following

Treatment. An inflammatory response of varying degree was seen at the exposure site in each of 26 pulps evaluated 90 days following treatment. Ten of 13 pulps treated with the antibiotic preparation were considered to have a mild to moderately inflamed pulp (Figure 11). The remaining three showed severe inflammation with abscess formation. In one of these a substance thought to be the zinc oxide - eugenol dressing was observed adjacent to the pulp tissue (Figure 12).

The pulps treated with the starch control were in sharp contrast to the majority of those described above. Twelve of the thirteen specimens were severely inflamed

or necrotic, (Figure 13). All but two of those demonstrated abscess formation and necrosis ranging from partial to complete (Figures 14 and 15).

Substantial amounts of reparative dentin were deposited in all but one of the pulps treated with the antibiotic compound. Only four of 13 pulps treated with the starch control showed substantial deposits of dentin and the great majority showed minimal or negligible amounts.

The relative inflammatory and reparative status of the antibiotic treated pulps was decidedly better than those treated with the starch control.

In addition to the 26 teeth previously described, two others were extracted at this time which could not be histologically evaluated. Due to sectioning difficulties the exposures could not be seen entering the pulps.

TABLES AND ILLUSTRATIONS

PREFACE TO TABLES I AND II

A. Method of exposure; refers to the method by which entrance was made into the pulp.

1. EP -- explorer point.
2. HSB -- high speed bur, rotating at maximum speed, under approximately 30 pounds of air pressure.
3. SSB -- slow speed bur.

B. Reparative dentin formation; refers to the formation of reparative dentin on the walls of the chamber, canal, and around the dentin chips in the vicinity of the exposure.

1. Large amount -- present in abundance with an attempt at bridging by a coalescence from several niduses.
2. Moderate amount -- a smaller amount of dentin is present and coalescence is less pronounced.
3. Small amount -- much less formation with little coalescence.
4. Negligible amount -- minimal or none.

C. Inflammatory status of the pulp.

1. Mild -- the inflammation is limited to the immediate vicinity of the exposure site with an

excellent attempt by the pulp to form a connective tissue barrier to minimize further pulpal involvement. The inflammatory cells are primarily chronic in nature and are relatively few in number. The remainder of the pulp is relatively normal.

2. Moderate -- the inflammation has extended beyond the immediate exposure but is still limited to the coronal portion of the pulp and there is a positive attempt by the pulp to minimize severe pulpal involvement. The inflammatory cells are primarily chronic in nature and are relatively few in number. The remainder of the pulp is relatively normal.
3. Severe -- the inflammation is widespread and has penetrated to the deeper portions of the pulp with a heavy concentration of mixed inflammatory cells. The inflammatory picture is relatively quite severe. Abscess formation is frequently seen.
4. Partial necrosis -- necrosis is widespread but there is some vital tissue remaining.
5. Complete necrosis -- the pulp is completely

necrotic and peri-apical lesions are sometimes seen.

D. Pulpal reaction; refers to the comprehensive health status of the major portion of the pulp and its response to the insult.

1. Satisfactory -- the major portion of the pulp is healthy and the potential for complete resolution of the insult is thought to be good.
2. Unsatisfactory by reason of severe and extensive inflammation -- the insult has produced an overwhelming inflammatory picture and it is thought that the potential for healing is not very good.
3. Unsatisfactory by reason of extensive necrosis -- it is thought that prospects for healing are greatly diminished and practically nil.

TABLE I

Histologic Results for Pulp of Permanent Teeth Treated with
the Antibiotic Compound

No.	Tooth	Method of Exposure	Reparative Dentin Formation	Inflammatory Status of Pulp	Pulpal Reaction
<u>Animal Number I -- 30 Days</u>					
1.	UL1	EP	Large	Mild	1
2.	UL2	EP	Large	Mild	1
3.	UL6	HSB	Moderate	Moderate	1
4.	LR1	EP	Large	Mild	1
5.	LR2	EP	Moderate	Moderate	1
6.	LL7	HSB	Large	Moderate	1
7.	LR6	HSB	Moderate	Moderate	1
<u>Animal Number II -- 30 Days</u>					
8.	UR1	EP	Large	Moderate	1
9.	UR2	EP	Large	Mild	1
10.	LL1	SSB	Large	Mild	1
11.	UL2	EP	Large	Mild	1
12.	LL7	HSB	Moderate	Mild	1
13.	LR6	HSB	Large	Moderate	1
<u>Animal Number III -- 90 Days</u>					
14.	UR1	EP	Small	Severe*	2
15.	UR2	EP	Large	Moderate	1
16.	UR5	HSB	Moderate	Mild	1
17.	UR6	HSB	Large	Mild	1
18.	UL3	EP	Moderate	Moderate	1
19.	UL4	HSB	Moderate	Moderate	1
20.	UL7	HSB	Large	Moderate	1
21.	LL1	EP	Moderate	Severe*	2
22.	LL2	EP	Moderate	Moderate	1
23.	LL5	HSB	Large	Moderate	1
24.	LL6	HSB	Large	Severe*	2
25.	LR3	HSB	Large	Mild	1
26.	LR7	HSB	Large	Moderate	1

Note: Evaluations could not be made on three other permanent teeth treated with this preparation

<u>Symbols</u>	<u>Numbers</u>
*-----Abscess Formation	1-----Satisfactory
#-----Peri-apical Lesion	2-----Unsatisfactory (inflammation)
C-----Complete	3-----Unsatisfactory (necrosis)
P-----Partial	

TABLE II

Histologic Results for Pulp of Permanent Teeth Treated
with the Starch Control

No.	Tooth	Mode of Exposure	Reparative Dentin Formation	Inflammatory Status of Pulp	Pulpal Reaction
<u>Animal Number I -- 30 Days</u>					
1.	UR1	EP	Neg.	Severe*	2
2.	UR2	EP	Neg.	Necrotic-C	3
3.	UR6	HSB	Small	Severe*	2
4.	UR7	HSB	Neg.	Severe*	2
5.	LL1	EP	Moderate	Severe	2
6.	LL2	EP	Neg.	Necrotic-C	3
7.	LR7	HSB	Moderate	Mild	1
<u>Animal Number II -- 30 Days</u>					
8.	UL1	EP	Moderate	Severe*	2
9.	UL6	HSB	Large	Moderate	1
10.	LL2	EP	Small	Mild	1
11.	LR1	EP	Neg.	Necrotic-C	3
12.	LL6	HSB	Small	Severe*	2
13.	LR7	HSB	Large	Mild	1
<u>Animal Number III -- 90 Days</u>					
14.	UL1	HSB	Neg.	Severe*	2
15.	UL2	HSB	Neg.	Necrotic-P	3
16.	UL5	HSB	Neg.	Necrotic-C#	3
17.	UL6	HSB	Large	Moderate	1
18.	UR3	EP	Neg.	Severe*	2
19.	UR4	HSB	Neg.	Necrotic-P#	3
20.	UR7	HSB	Neg.	Necrotic-C#	3
21.	LL3	EP	Neg.	Severe*	2
22.	LL4	HSB	Small	Necrotic-C#	3
23.	LL7	HSB	Moderate	Severe*	2
24.	LR1	EP	Moderate	Severe*	2
25.	LR2	HSB	Moderate	Severe	2
26.	LR5	HSB	Neg.	Severe*	2

Note: Evaluation could not be made on two other permanent teeth treated with this preparation.

<u>Symbols</u>	<u>Numbers</u>
*-----Abscess Formation	1-----Satisfactory
#-----Peri-apical Lesion	2-----Unsatisfactory (inflammation)
C-----Complete	3-----Unsatisfactory (necrosis)
P-----Partial	

Figure 1. Photograph demonstrating typical surgically exposed pulps.

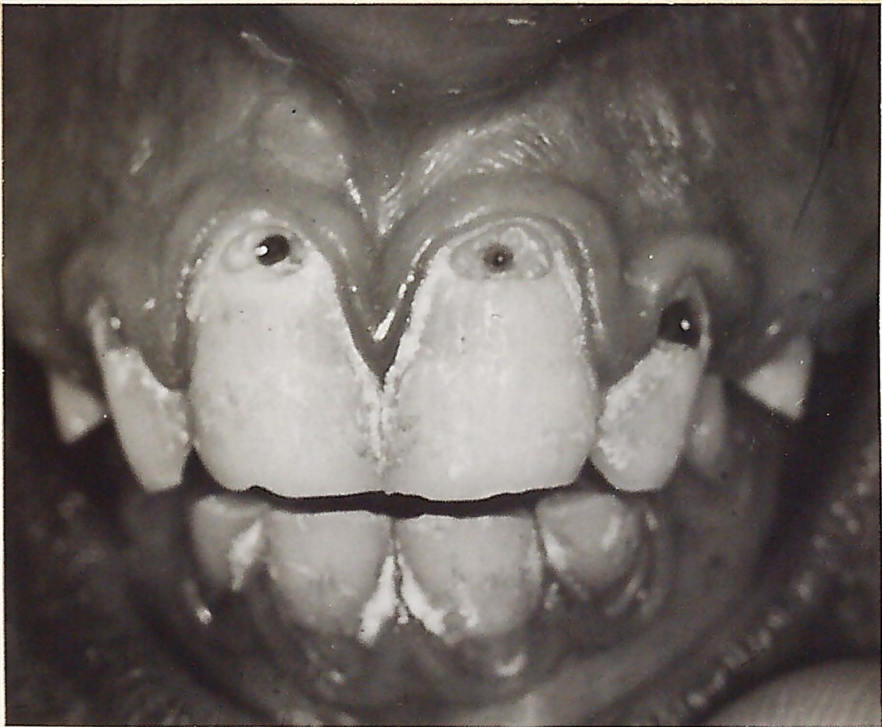

Figure 2. Microscopic section of a mandibular left central incisor. The pulp had been left open for 24 hours following exposure. Clusters of microorganisms are seen scattered throughout the exposure area. Brown and Brenn X 28.

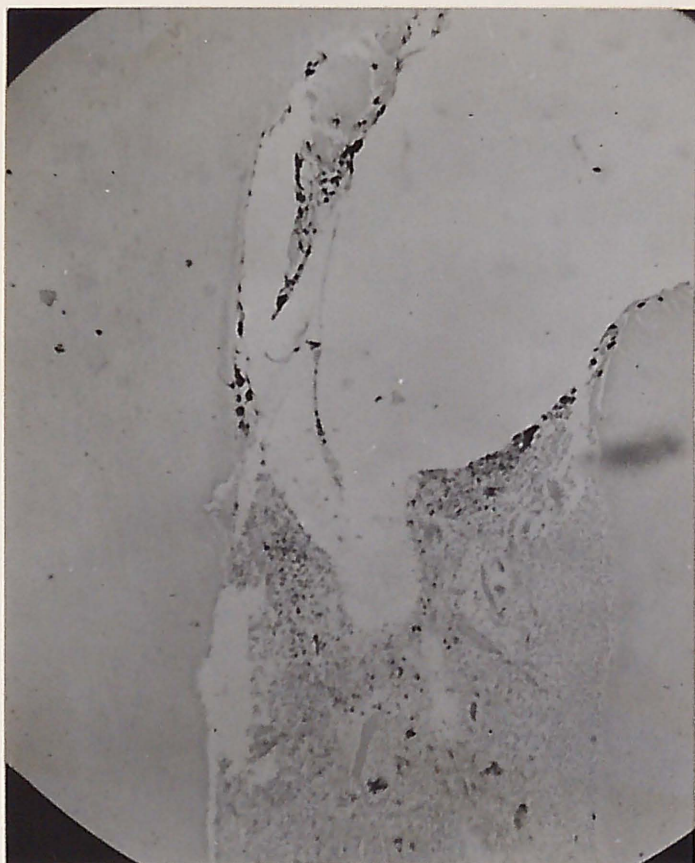


Figure 3. Microscopic section of a maxillary left central incisor treated with the anti-biotic preparation, 30 days postoperatively, showing inflammation limited to the immediate vicinity of the exposure. Hematoxylin and eosin X 28.

Figure 4. Microscopic section of a maxillary right lateral incisor treated with the starch control, 30 days postoperatively, showing a severe inflammatory response, abscess formation and negligible amounts of reparative dentin. Hematoxylin and eosin X 28.

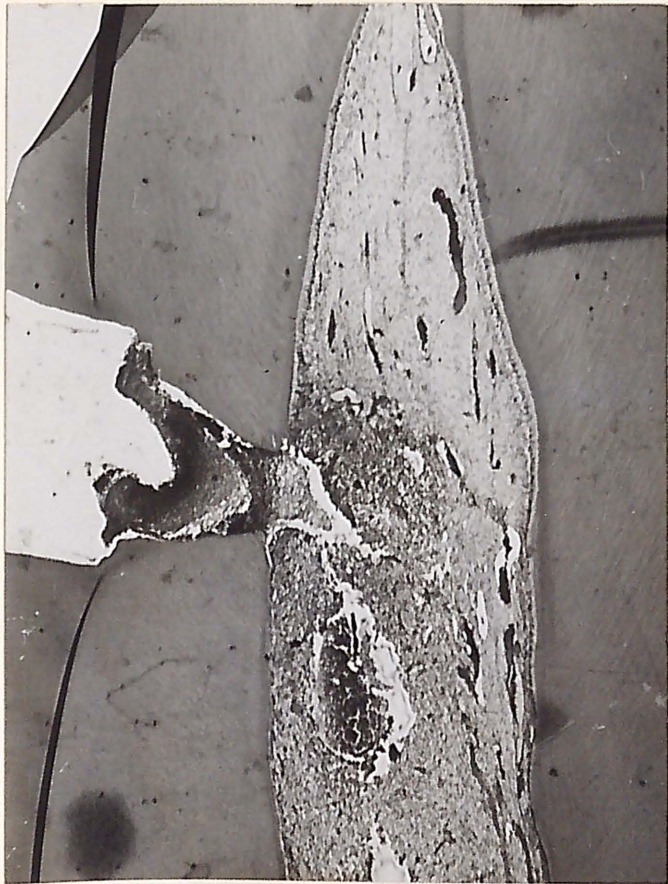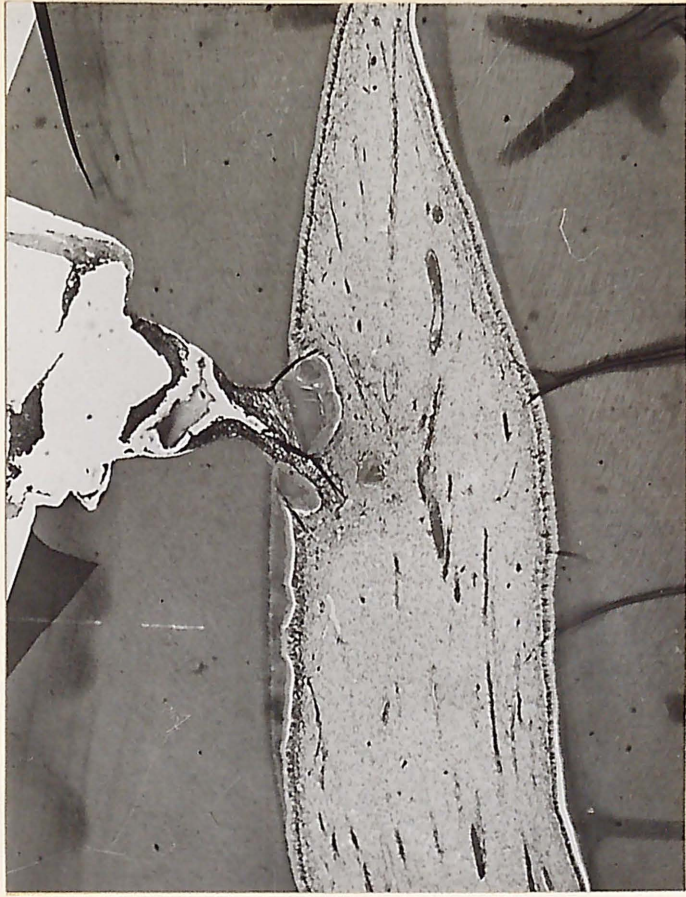


Figure 5. Microscopic section of a maxillary right central incisor treated with the starch control, 30 days postoperatively, exhibiting complete necrosis. Hematoxylin and eosin X 28.

Figure 6. Microscopic section of maxillary left lateral incisor treated with the anti-biotic preparation, 30 days postoperatively, showing good alignment of dentin chips contributing to the bridging attempt. Hematoxylin and eosin X 28.

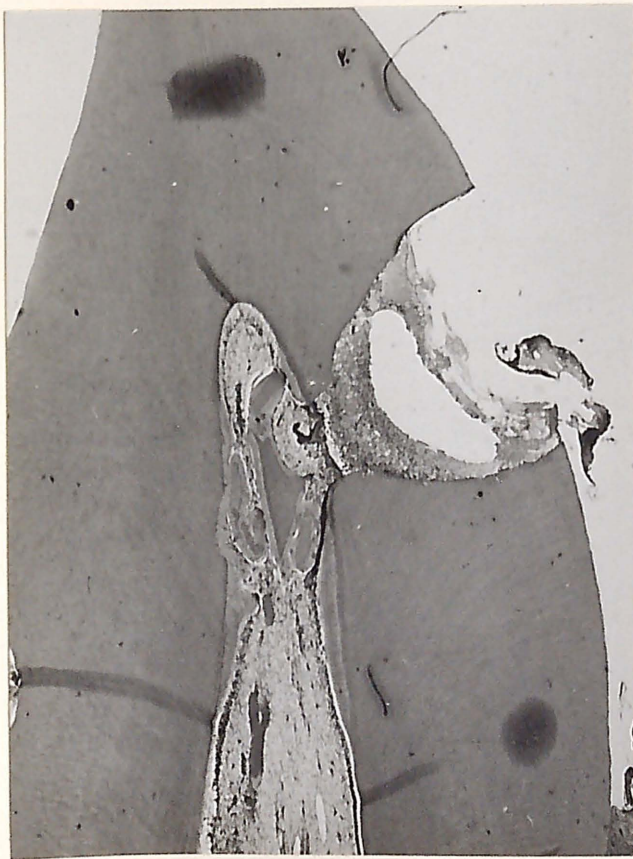
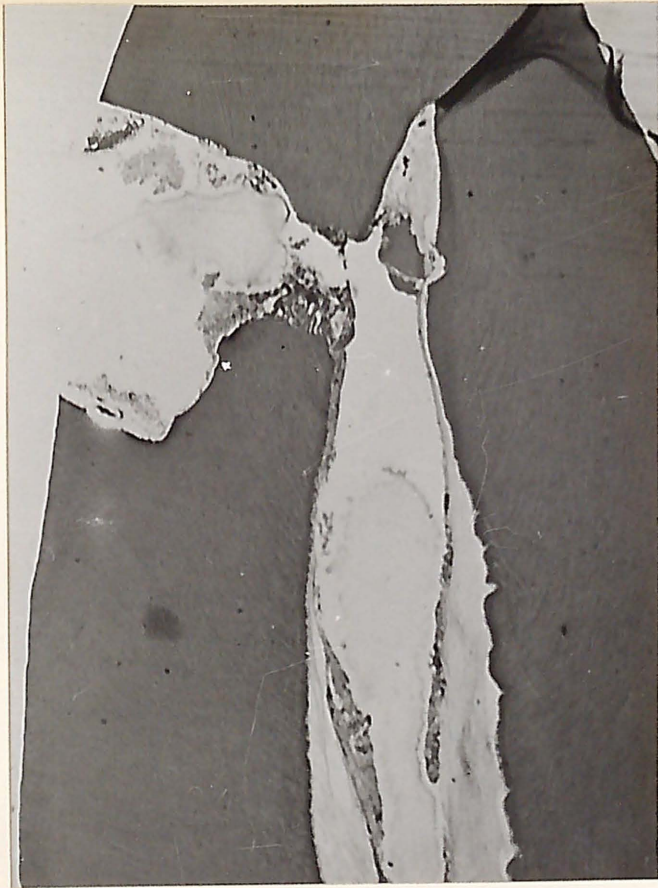

Figure 7. Microscopic section of mandibular right lateral incisor treated with the antibiotic preparation, 30 days postoperatively, demonstrating a thin band of epithelium across the exposure site. Hematoxylin and eosin X 28.

Figure 8. Microscopic section of a maxillary left lateral incisor treated with the antibiotic preparation, 30 days postoperatively, showing distortion attributed to incomplete fixation by being left out of formalin for 12 hours. Hematoxylin and eosin X 28.

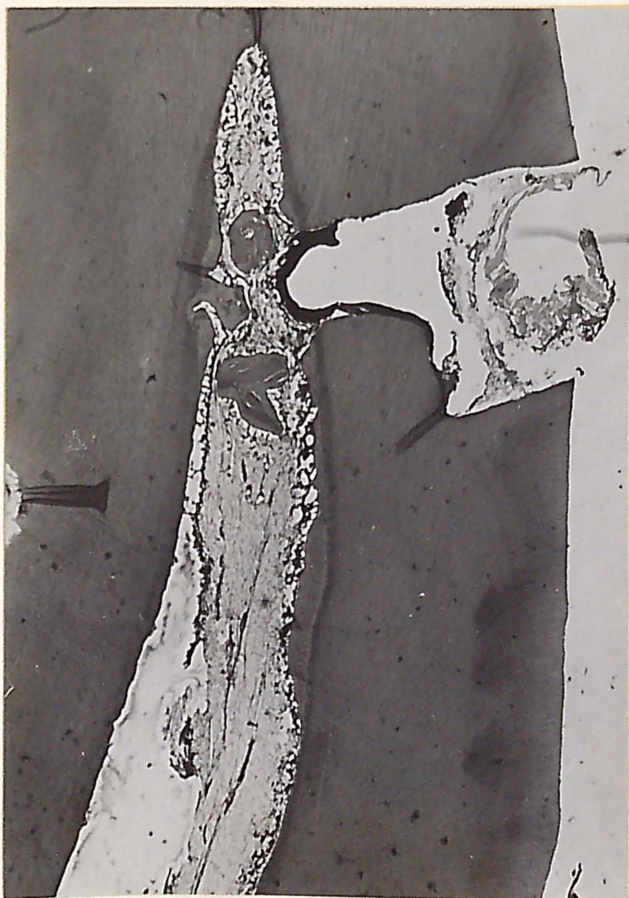
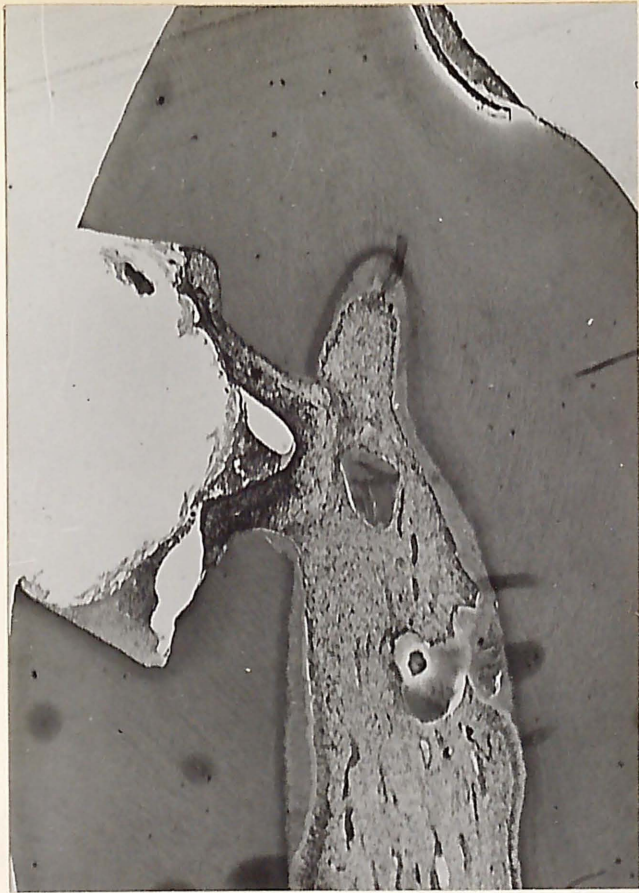


Figure 9. Microscopic section of a mandibular left first molar showing a pericoronal granuloma resulting from a perforation of the pulp chamber. Hematoxylin and eosin X 28.

Figure 10. Microscopic section of the same tooth demonstrating the need for serial sections. Hematoxylin and eosin X 28.



Figure 11. Microscopic section of a maxillary right second premolar treated with the anti-biotic preparation, 90 days postoperatively, with inflammation limited to the exposure site and pulp horn. Hematoxylin and eosin X 28.

Figure 12. Microscopic section of a mandibular left central incisor treated with the anti-biotic preparation, 90 days postoperatively, showing a substance thought to be zinc oxide - eugenol adjacent to the pulp. Hematoxylin and eosin X 28.

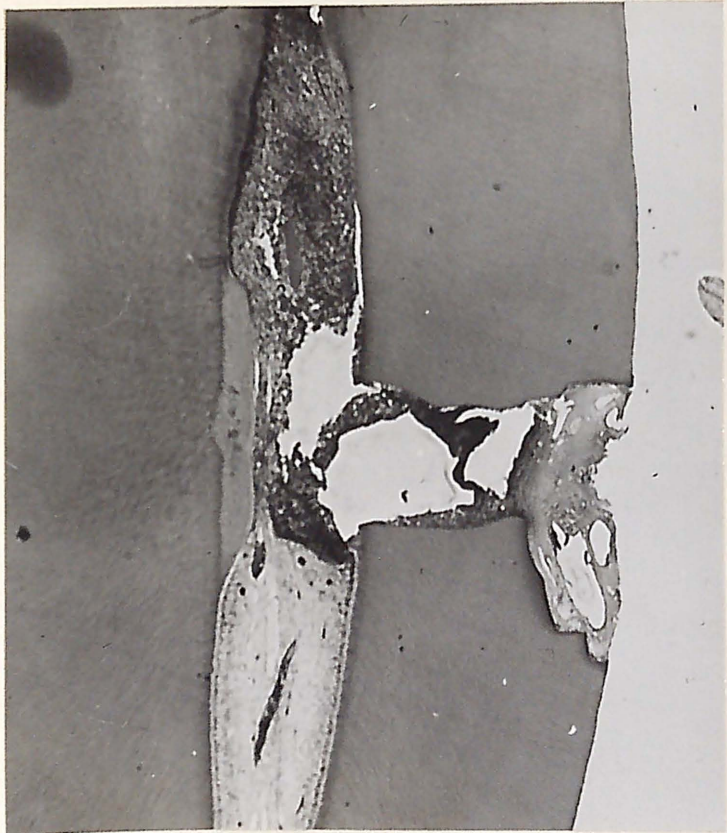
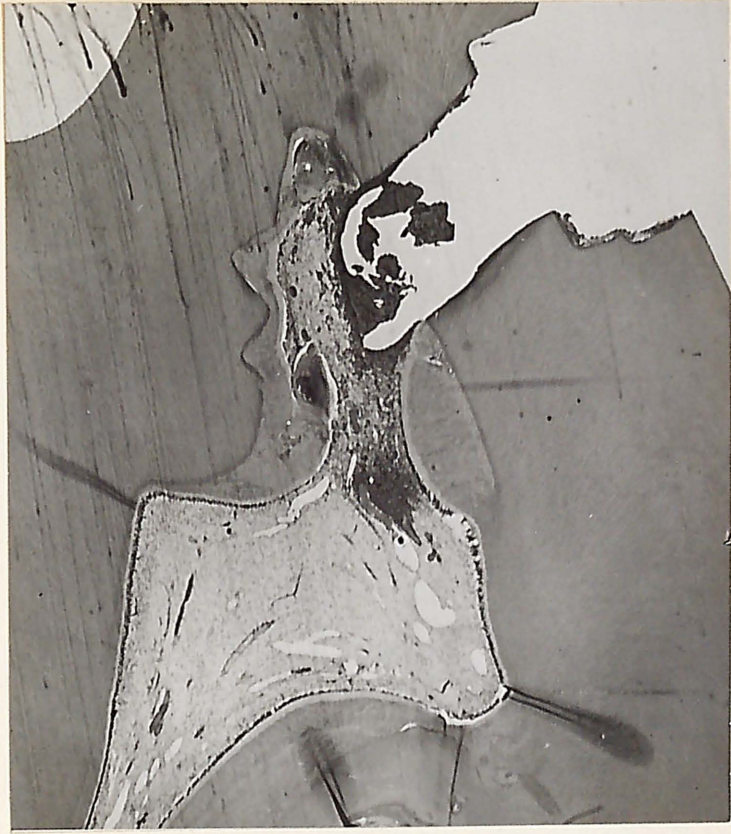
Figure 13. Microscopic section of a maxillary left central incisor treated with the starch control, 90 days postoperatively, showing a severe inflammatory response. The void at the exposure represents an artifact formed by a pulling away of the tissue and if pushed back would fit as in a jig saw puzzle. Hematoxylin and eosin X 28.

Figure 14. Microscopic section of a maxillary left second premolar treated with the starch control, 90 days postoperatively, showing a necrotic apex and a fistulous tract. Hematoxylin and eosin X 28.

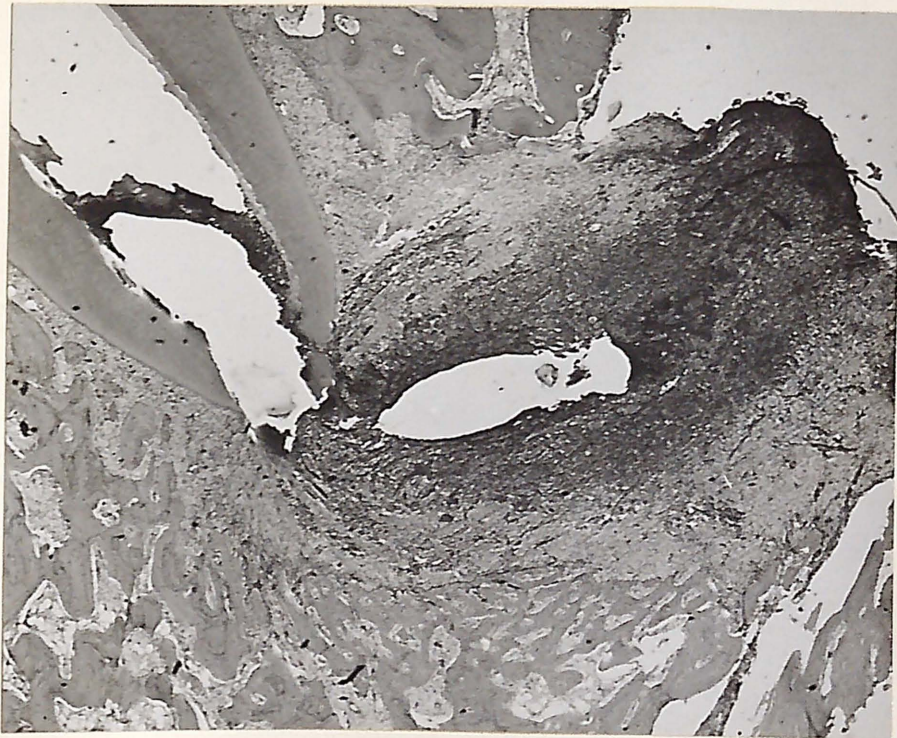

Figure 15. Microscopic section of a maxillary right second molar treated with the starch control, 90 days postoperatively, showing some vital tissue remaining and a pronounced calcific response at the apex. Hematoxylin and eosin X 28.

Figure 16. Photographs demonstrating intra oral palatal lesions, 90 days postoperatively, opposite the upper right second molar and the upper left second premolar.

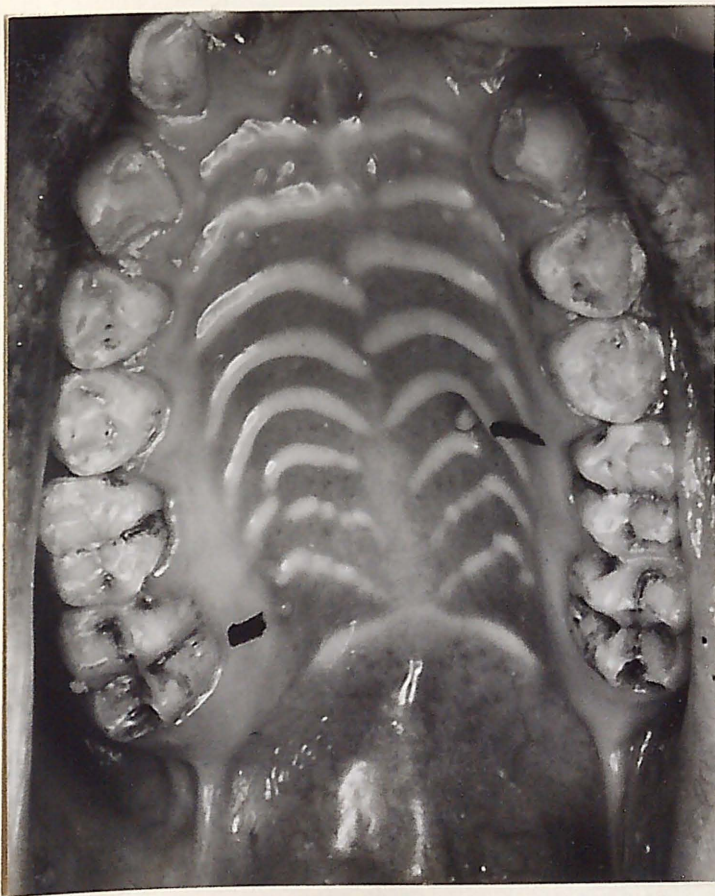
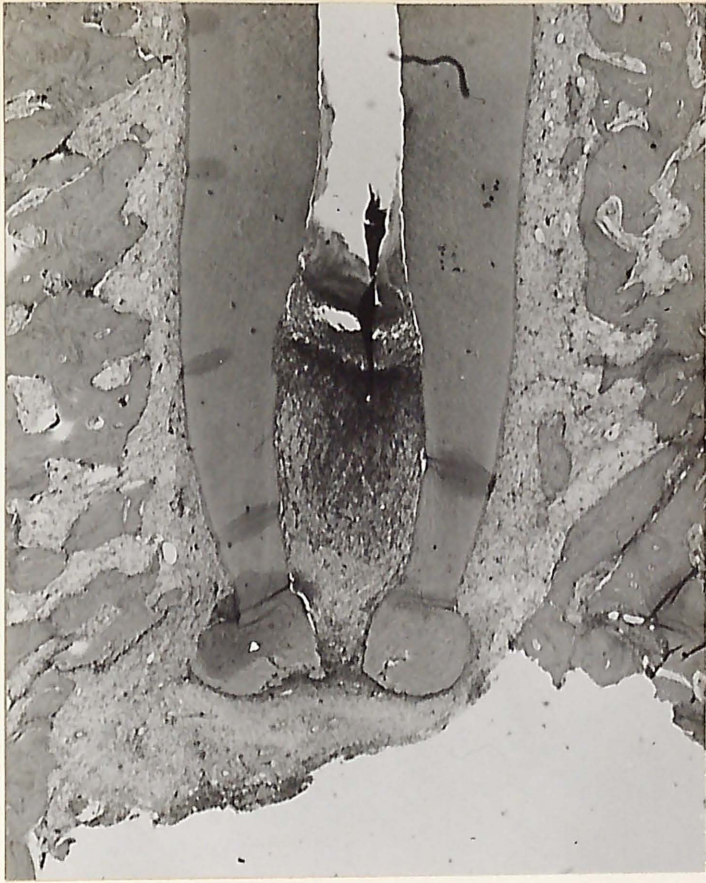
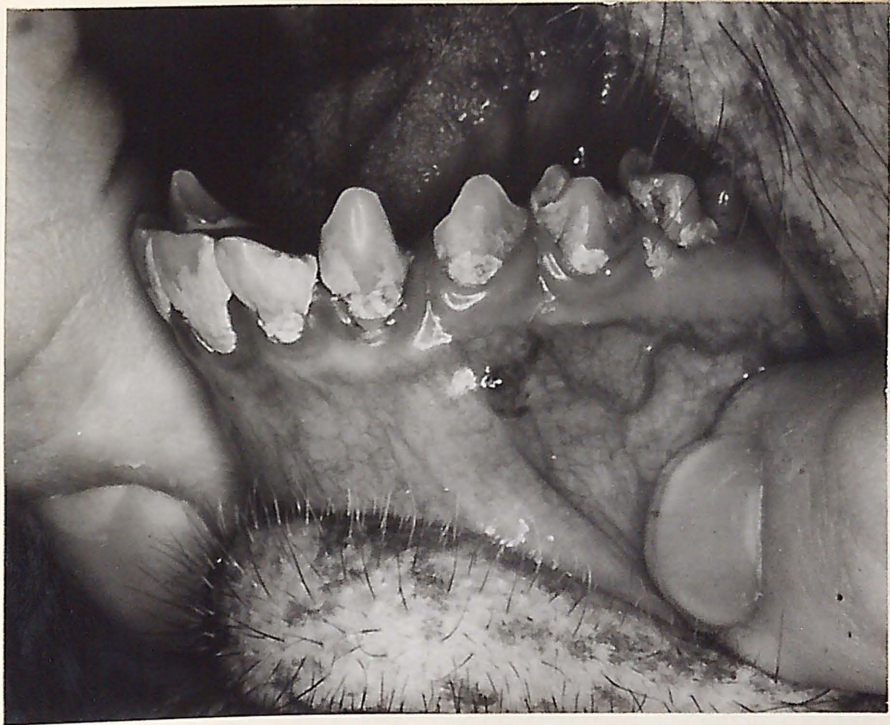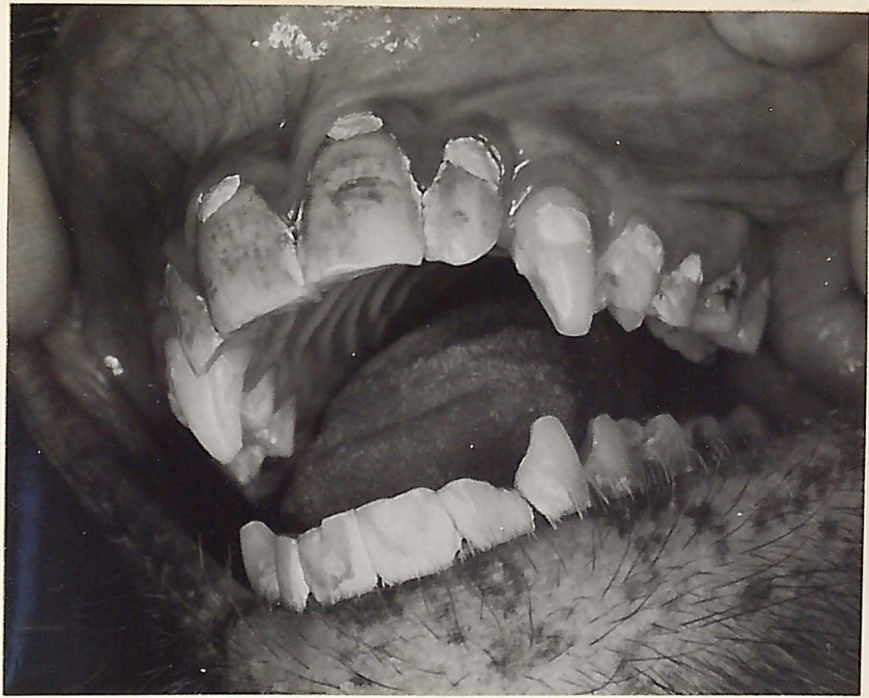Figure 17. Photograph demonstrating intact restorations 90 days postoperatively.

Figure 18. Photograph demonstrating an intra oral vestibular lesion, 90 days postoperatively, opposite the lower left first premolar.



DISCUSSION

It has been demonstrated in this study that the exposed pulps of monkey teeth became infected when left open to the oral environment for a period of 24 hours. The microorganisms appeared to be predominantly gram-positive cocci and they were concentrated primarily at the exposure site. They did not appear to have significantly penetrated the remaining intact pulp tissue very much. (Figure 2).

28

A study by Kiryati indicated that the severity of the infection was increased by leaving the pulps open for longer periods of time. Seltzer and Bender also support this observation by commenting that the longer the time of exposure, the greater is the likelihood that the microorganisms will gain a foothold in the injured tissue.

29

In an experiment by Kakehashi et al pulp exposures were made in the teeth of rat molars and left open to the oral environment for from 1 to 42 days. The sample consisted of germ-free and conventional rats. Eighteen of 21 teeth in the germ-free group survived the very traumatic operative procedure. In some instances the pulp chambers were perforated and yet the pulp survived. They showed calcific bridge formation of a varying degree and inflammation was minimal in all cases. All of the pulps exposed in the conventional rats terminated in pulpal death and abscess

formation was seen without exception when sections were taken from specimens after eight days. The results emphasize the important role that microorganisms play in pulpal pathosis and the evidence strongly suggests that they are the dominate etiological factor.

In this study a high priority must be given to the role of bacteria when one attempts to explain the marked difference in results of those pulps treated with the antibiotic preparation and those with the starch control. A logical assumption would be that the presence of microorganisms constituted one known common denominator which stood to be affected differently by the two experimental preparations. The results indicate that the antibiotic compound largely succeeded in suppressing bacterial activity whereas the control did not.

The starch control material used in this experiment was identical to that used by Mullaney et al.³⁸ In the latter study the pulps of monkey teeth were surgically exposed and incidentally were left open during the operation for about one-half hour. Microscopic evaluation showed the major portion of the pulp abnormal in only two of 14 specimens treated with the starch control. The results for the control treated teeth are strikingly different from those

of this study in which 21 of 26 pulps so treated exhibited severe inflammation, abscess formation, or necrosis. The major variation in the experimental procedure was the amount of time the pulp was left open to the oral environment, and the fact that salivary bacterial contamination was inevitable in this study, and unlikely in the former. In this study two teeth which were not to be used in the study were surgically exposed and left open for one-half and one hour respectively. Bacteria could not be demonstrated in either pulp when Brown and Brenn histologic sections were made, even though saliva was introduced into the pulp on the tip of an explorer. Thus, the magnitude of bacterial contamination appears to account for the significant disparity in results between the two studies.

A possible relationship is thought to exist between the inflammatory status of the pulp and the amount of reparative dentin deposited. Moderate to large amounts were consistently seen in mild to moderately inflamed pulps and negligible to small amounts found in severely inflamed or necrotic pulps (Figures 3 through 15). Others^{9,28,29} have made similar observations.

The amount of reparative dentin seen in necrotic pulps may be an indication of the time of pulpal degeneration and

death. A necrotic pulp with a negligible amount may have died rather soon after treatment whereas one exhibiting a large deposition possibly survived for a longer period of time. This was a fairly consistent pattern and three teeth which showed clinical evidence of necrosis when evaluated at 30 days presented a comparable histopathological picture at 90 days. Negligible amounts of reparative dentin were present suggesting that a correlation did exist between the time of death and the amount present (Figures 15, 16 and 17). This could be checked readily in future studies by using a vital dye marker to demarcate the reparative from primary dentin.

Dentin chips which had been introduced when the pulp was exposed contributed significantly to the degree of calcific bridging seen in the study. Large amounts of reparative dentin formed about them often coalescing with that around other chips and with depositions on the walls to create an attempt at bridging (Figure 6). This phenomena was frequently observed in the antibiotic treated pulps and rather infrequently in those treated with the starch control. The arrangement and alignment of the chips appeared to be quite important with regard to the degree of bridging.

Complete bridging was not seen in any specimen in this study. However it appeared that specimens demonstrating incomplete bridging, with vigorous calcific repair, would possibly proceed to completeness if the pulp were to survive for a longer indeterminate period of time. (Figure 3 - 6).

Although calcific bridging is not considered to be an absolute indication of success in pulp capping or pulpotomy it would appear to be a desirable feature in that it may serve to prevent ingress of oral fluids in the event of leakage around a restoration. Fiore-Donno and ³²Baume noted that lack of a solid barrier was a consistent finding in pulps treated with cortico antibiotic preparations and considered this to be an objectionable and undesirable trait. ³⁸Mullaney et al did not see complete bridging in specimens obtained after 90 or 180 days.

In this study there were deviations from normal established patterns. One such instance was the presence of a thin band of epithelium covering the exposure site (Figure 7). This possibly represents the same phenomena by which a pulp is epithelialized and protected. It is thought that in this case the epithelium was inadvertently introduced by the bur during the exposure procedure since proximity to the gingiva was very close.

Other factors which may have influenced results were considered to be leakage around restorations, resistive differences among the individual animals, a mix up resulting in the wrong medication being placed, excessive damage while exposing, and in placement of the medications.

The composition of the antibiotic compound used in this study was basically the same as that used in three other studies.^{36,38,39} The exception being that the glucocorticoid was omitted in this experiment. The drugs were chosen primarily for their mutual compatibility with one another and their broad spectrum coverage.

A study by Bowen⁴³ on the salivary flora of Macaca Irus and one by Kelly⁴⁴ on the Macaca Mulatta indicate that the oral flora in the monkey is quite similar to that of man. Thus it is reasonable to assume that they would be susceptible to antibiotic therapy employed for man.

Kane⁴⁵ states that the principles involved in the handling of any infection, whether present in the oral cavity or elsewhere, are very similar if one makes allowances for certain anatomic peculiarities. One of the principles that should be adhered to in antibiotic therapy is directed towards controlling the invasive features in an endeavor to limit

the infection to the area supporting the portal of entry. The author commented that success or failure will depend upon the attainment of an effective antibiotic level in the blood and area of infection. These principles would certainly be applicable to a pulp capping procedure and one can readily see the importance of an adequate application and proper placement of the medicament. It was often very difficult to do in this study, especially in the small lower incisors, and this may possibly be responsible for some of the failures seen in the antibiotic treated teeth. Such may have been the case in one instance in which it appeared histologically that the pulp was in direct contact with a material thought to be the zinc oxide and eugenol restoration indicating that placement was faulty (Figure 3). In others the quantity of the medication carried to place may have been insufficient.

Of note, is the fact that all of the severe inflammatory responses observed in teeth treated with the antibiotic preparation, occurred in the first animal operated. This could be the result of inadequate placement, as it was felt that proficiency in placing the materials increased as more teeth were treated.

⁴⁷
Kane also theorized that an adequate level should be attainable in any area by parenteral administration if

sufficiently high doses are employed and therapy continued for a prolonged period of time. It was pointed out that when local therapy is used, antibiotic solutions, in order to be effective, must be kept in contact with the infected tissue long enough to allow the antibacterial action to exert itself. When bacteria are exposed to antibiotic agents there is a lag period of several hours before bacteriostatic activity can be observed. Parenteral therapy is thought to be necessary when infection is present deep within the tissue.

The results of the present study are encouraging, however the possibility exists that we are witnessing only a partial realization of the maximum potential of antibiotic therapy.

It is doubtful that the procedure used in this experiment fully satisfies the principles of antibiotic therapy. This is particularly so with regard to the presence of an effective antibiotic level in the area of the infection.

It may well be that a frequent change of dressings and/or adjunctive administration of systemic antibiotics would prove to be beneficial in a future pulp capping study in which antibiotics were to be used.

In this study a mild or moderate degree of inflammation was evident in the great majority of the specimens treated

with the antibiotic preparation. Mild to moderate inflammation was also seen in five teeth treated with the starch control. Three teeth treated with the antibiotic preparation exhibited severe inflammation with abscess formation 90 days postoperatively, suggesting a slight trend towards a more severe inflammatory picture at 90 days postoperatively than at 30 days. However, the duration of this experiment is inadequate to evaluate success or failure and there are no indications at this time by which it can be accurately predicted that the treated pulps will proceed to degeneration and necrosis. Indeed, considering the extensive damage and bacterial contamination produced by the exposure the pulps have shown every indication of a robust attempt to survive.

SUMMARY AND CONCLUSIONS

Pathogenic microorganisms are considered to play a prominent role in the initiation of pulpal pathology when the vital dental pulp is exposed. There is evidence to indicate that the presence of bacteria is the most significant factor in prohibiting healing.

The histologic results of a pilot study indicated that infection of a significant degree occurred when the pulps of four central incisors of a Macaca mulata monkey were surgically exposed with a bur or an explorer and left open to the oral environment for a period of 24 hours. The teeth were then extracted, serially sectioned, and microscopically examined. Microorganisms were observed in the immediate vicinity of the exposure area and were identified by a Brown and Brenn stain which is a differential stain for demonstrating bacteria in tissue sections.

The review of the literature described many experiments in which antibiotics had been used to cap exposed pulps. It was felt that additional investigation into this area was warranted since the results tended to be conflicting and inconclusive.

This modified double-blind investigation was undertaken to examine the hypothesis that for any given species, the utilization of an antimicrobial agent, innocuous to healthy tissue, yet potent enough to destroy or control the invasive

pathogenic organisms, would allow the natural defense mechanism of a vital pulp to overcome the infection, repair the damage, and survive.

In the principal portion of the investigation the pulps of 57 permanent teeth from three monkeys were surgically exposed in essentially the same manner as in the pilot study.

After remaining open for 24 hours a modified double-blind procedure was used in which the exposed pulps were capped with the experimental antibiotic material or the pure starch control. The antibiotic preparation consisted of erythromycin estolate 10 percent, streptomycin sulfate 10 percent, and starch q.s. as the vehicle. A zinc oxide - eugenol restoration with zinc acetate crystals was inserted following placement of the capping material in order to seal the cavity.

It is very significant that all of the class V zinc oxide - eugenol restorations in the permanent teeth were in place and apparently intact when examined just prior to the sacrifice of each animal. However six of nine occlusal zinc oxide - eugenol restorations in the deciduous teeth had been lost and the other three had been dislodged and were loose. Twenty-nine permanent teeth and nine deciduous teeth were extracted for histological study 30 days following treatment.

The nine deciduous teeth were discarded from the study as it was felt that the lost and loose restorations would prevent an accurate histologic evaluation. Three permanent teeth were also considered unacceptable for the study. In two of these teeth the laboratory technician was unable to find the exposure entering the pulp chamber while sectioning. The other was discarded because the bur had perforated the lower portion of the pulp chamber during the exposure procedure.

Twenty-six of the 29 permanent teeth extracted 30 days following treatment were considered to be acceptable for the study. Thirteen had been treated with the antibiotic pulp capping material and thirteen with the starch control. All of the antibiotic treated teeth experienced a favorable pulp reaction with only a mild to moderate amount of inflammation present and moderate to large amounts of reparative dentin deposited.

In contrast nine of 13 teeth treated with the starch control exhibited a severe pulp reaction with severe inflammation present and only small to negligible amounts of reparative dentin deposited.

The histologic results at 30 days indicated that the pulp responded much more favorably to the antibiotic capping

material than to the starch control capping material

Twenty-eight permanent teeth were extracted for histological study 90 days following treatment. Two of this number were unacceptable for the study because the laboratory technician was unable to find the area of exposure between the preparation and the pulp while sectioning.

Twenty-six of the 28 permanent teeth were considered to be acceptable for the study. Thirteen had been treated with the antibiotic pulp capping material and 13 received the starch control. Ten of 13 teeth treated with the antibiotic preparation experienced a favorable pulp reaction, with mild to moderate inflammation and substantial amounts of reparative dentin present. The other three teeth treated with the antibiotic compound showed a severe inflammatory picture with abscess formation and small to large deposits of reparative dentin.

In sharp contrast, 12 of 13 teeth treated with the starch control exhibited a very unsatisfactory pulpal reaction. Eleven of 13 teeth demonstrated abscess formation or partial to complete necrosis. Small to negligible deposits of reparative dentin were usually seen in these teeth.

The histologic result at 90 days continue to indicate that the pulp experienced a much more favorable response

to the antibiotic capping material than to the starch capping agent.

There appeared to be a slight trend towards a more severe inflammatory picture 90 days postoperatively than at 30 days postoperatively in those teeth treated with the antibiotic capping material. However it would be hazardous to predict the fate of those teeth based on the histologic picture present at that time. The elements for repair were evident in most of the pulps and the potential for resolution of the insult appeared to be quite good. It was felt that a prediction of success or failure could not be justified.

There appeared to be a relationship between the extent of bridging and the arrangement of dentin chips around the exposure site. It was observed that a better alignment of dentin chips appeared to enhance bridging. Complete bridging was not seen in this study although it appeared to be still possible if the pulps survived for a longer period of time and reparative dentin continued to be deposited.

The results of this study would seem to corroborate
29
the findings of Kakehashi et al to a high degree in that they suggest that microorganisms do play a major role in preventing healing following vital pulp exposure.

The principles of antibiotic therapy should be given careful consideration in any future antibiotic pulp study,

especially with regard to the importance of achieving and maintaining a high concentration of the drug in the area of infection. It is questionable that this was accomplished to the highest possible degree in this study. It may prove beneficial in future studies to frequently replace the antibiotic capping material for the first few days of treatment or to administer the antibiotic systemically in order to achieve a high concentration of the drug within the pulp chamber.

A histological investigation of longer duration using this antibiotic capping material is warranted in view of the encouraging results obtained in this study.

REFERENCES

1. Quarterly Cumulative Index Medicus: 32: 589, 1942.
2. Index to Dental Literature: 1942-1944: 235-236.
3. Bonner, A. B.: Preserving vitality in pulp exposed teeth. D. Survey 23: 1069, 1947.
4. Kutscher, A. H.: Penicillin sodium capping of vital cariously exposed pulps in adults. D. Digest 56: 388-393, 1950.
5. Webb, C. S.: Control pulpal infection with penicillin. D. Survey 26: 343-344, 1950.
6. Gilberg, S. L.: Penicillin pulpal therapeutics. U. S. Armed Forces Med. J., 2: 203, 1951.
7. Rosen, L. J.: Deciduous pulp capping: its present status and a report on penicillin pulp therapeutics. J. Missouri D. A., 32: 11, 1952.
8. Amler, M. H.: Control of pulpitis by means of systemic antibiotic therapy. J. D. Res., 33: 737, 1954, Abstract.
9. James, V. E., Englander, H. R., and Massler, M.: Histologic response of amputated pulps to calcium compounds and antibiotics. Oral Surg., Oral Med., and Oral Path. 10: 975, 1957.
10. Kutscher, A. H. and Yigdall, Irene R.: Bacteriologic evaluation of the compatibility of antibiotics and other therapeutic agents. Oral Surg., Oral Med., and Oral Path. 5: 1096-1098, 1952.
11. Ramnarine, D. C.: Treatment of infected dentin and pulps of children's teeth with Terramycin. D. Survey 32: 1465-1466, 1956.
12. Seltzer, S. and Bender, I. B.: Some influences affecting repair of the exposed pulps of dog's teeth. J. D. Res. 37: 678-687, 1958.
13. Maeth, H.: Saving of dental pulps with oxytetracycline. D. Digest 65: 1921, 1959.

14. Burke, G. W. and Holmes, T. K.: Effect of local anti-bacterial agents on bacteria in dental pulps of rats. *J. D. Res.*, 41: 1105, 1962.
15. Burkman, N. Weir: A preliminary report of an investigation to study the effectiveness of certain drugs for sterilizing carious dentine. *Oral Surg., Oral Med., and Oral Path.* 7: 647-657, 1951.
16. Roth, L. H.: Aureomycin as applied to deciduous teeth. *New York J. Den.* 22: 213, 1952.
17. Lepine, P., Barskl, G., and Maurin, J.: Action of chloromycetin and of aureomycin on normal tissue cultures. *Proc. Soc. Exper. Biol. and Med.* 73: 252-255, 1950.
18. Roberts, R. M.: Adjunctive use of IM penicillin injections in treatment of exposed pulps. *J.A.D.A.*, 46: 171-173, 1953.
19. Seelig, Alex, Fowler, R. C. and Tanchester, D.: The effects of penicillin G potassium plus calcium carbonate on surgically exposed pulps of the Rhesus monkey. *J.A.D.A.*, 48: 532-537, 1954.
20. Via, W. F. Jr.: Barium sulfate and antibiotic mixture in pulpotomy. *J. Den. Children*, 22: 195, 1955.
21. Englander, H. R. Massler, M. and Carter, W. J.: Clinical evaluation of pulpotomy in young adults. *J. Den. Children*, 23: 48, 1956.
22. Feitelson, N.: Pulp capping with calcium hydroxide and penicillin. *J. Den. Children*, 23: 214, 1956.
23. Gollobin, A.: Antibiotic sedative base. *D. Survey*, 33: 1464, 1957.
24. Sanders, D. J.: Pulp conservation with an antibiotic agent. *J. Den. Children*, 26: 316-317, 1959, abstract.
25. Shay, D. E., Sarvbin, L. D., Spurrier, H. S. and Sanders, D. J.: Pulp conservation with an antibiotic agent. *J. Den. Children*, 27: 5, 1960.

26. Gardner, A. F., Thomson, J., Warren, G. and Young, D.: Preliminary report on high speed pulpal exposures capped with neosporin. *J.D.A. So. Africa.* 17: 248-259, 1962.
27. Sidky, E.: Combined hydrocortisone-omnacillin-calcium hydroxide therapy in pulpotomy. *Egyptian D. J.*, 3: 9, 1957.
28. Kiryati, A. A.: The effect of hydrocortisone plus polyantibiotics upon the damaged and infected dental pulp of rat molars. *J. D. Res.*, 37: 886, 1958.
29. Kakehashi, S., Stanley, H. R., and Fitzgerald, R. J.: The effects of surgical exposures of dental pulps in germ-free and conventional laboratory rats. *Oral Surg.*, *Oral Med.*, and *Oral Path.* 20: 340-349, Sept., 1965.
30. Kiryati, A. A.: Streptokinase in combination with antibiotics and cortisone in the treatment of exposed pulps of rat molars. *I.A.D.R.*, 40: 23, 1962, abstract.
31. Schroeder, A. and Triadan, H.: The pharmacotherapy of pulpitis. *Oral Surg.*, *Oral Med.*, and *Oral Path.*, 15: 345, 1962.
32. Fiore-Donno, G. and Baume, L. J.: Effects of capping compounds containing corticosteroids on the human dental pulp. *Helvetica Odont. Acta*, 6: 23, 1962.
33. Osen, Paul: Clinical experiences with a cortico-antibiotic preparation in conservative treatment of the pulp. *J. Canad. D. A.*, 30: 771-775, 1964.
34. Mager, M. E.: Treatment of pulpitis with synthetic steroids combined with antibiotics. A review and results of a pilot study. *D. Pract. and D. Record*, 14: 505, 1964.
35. Ehrman, E. H.: The effect of triamcinolone with tetracycline on the dental pulp and apical periodontium. *J. Pros. Dent.*, 15: 144-152, 1965.
36. Lawson, B. F. and Mitchell, D. F.: Pharmacologic treatment of painful pulpitis. *Oral. Surg.*, *Oral Med.* and *Oral Path.*, 17: 47, 1964.

37. Baume, L. J.: Möglichkeiten und grenzen der vitolerhaltung der entzündeten pulps. Schweizerische Monatsschrift für Zahnheilkunde, Band 75 NR 10: 1085, 1965.
38. Mullaney, T. P., Lawson, B. F., and Mitchell, D. F.: Pharmacologic treatment of pulpitis: A continuing investigation. Oral Surg., Oral Med. and Oral Path., 21: 479, 1966.
39. Schneider, H. S. and Lawson, B.: Corticoid antibiotic mixture compared to calcium hydroxide for capping exposed pulps in human primary teeth. IADR abstracts, No. 443, pg. 150, March 1966.
40. Brown, J. H. and Brenn, L.: A method for the differential staining of gram-positive and gram-negative bacteria in tissue sections. Bull. of John Hopkins Hosp. 48: 69, 1931.
41. Stanley, H. R.: Personal communication.
42. Seltzer, S. and Bender, I. B., editors: The Dental Pulp. Philadelphia and Montreal, J. B. Lippincott Company, 1965.
43. Bowen, W. H.: The salivary flora of Macaca Irus. British Dental Journal 115: 252-254, 1963.
44. Kelly, F. C.: Bacteriology of artificially produced necrotic lesions in the oropharynx of the monkey. J. Infect. Dis., 74: 93, 1944.
45. Kane, L. W.: Role of penicillin and streptomycin in oral infections. Am. J. Orthodont. and Oral Surg., 33: 395-400, 1947.

CURRICULUM VITAE

G. Richard Baker

July 1, 1931	Born in Covington, Kentucky
1951-1955	United States Navy
1956	Married Sydney Carolyn Fitch
1955-1958	B. S., University of Kentucky, Lexington, Kentucky
1958-1962	D. M. D., University of Louisville School of Dentistry, Louisville, Kentucky
1962-1964	General practice of dentistry
1963-1964	Instructor, University of Kentucky College of Dentistry, Lexington, Kentucky
1963-1964	President, Central Kentucky Study Group of Dentistry for Children
1964-1966	M. S. D., Graduate Program, Indiana School of Dentistry, Indianapolis, Indiana

Professional Societies

American Dental Association

American Association of Dentistry for Children

Kentucky Dental Association

Delta Sigma Delta Fraternity

ABSTRACT

Topical Antibiotic Treatment of Infected
Dental Pulps of Monkeys

By: G. Richard Baker

Indiana University School of Dentistry

Indianapolis, Indiana

A modified double-blind method of investigation was used in which the pulps of 52 monkey teeth were surgically exposed and left open to the oral environment for a period of 24 hours.

One-half of the exposed pulps were treated with an antibiotic preparation and one-half with a pure starch control. The antibiotic compound consisted of erythromycin estolate 10 percent, streptomycin sulfate 10 percent, and starch q. s. as the vehicle.

The teeth were extracted at 30 and 90 day intervals after treatment and histologically evaluated. Inflammation of a varying degree was observed in all of the teeth treated with either the antibiotic preparation or the starch control. However, those teeth treated with the antibiotic capping material exhibited much less inflammation than did the great majority of teeth treated with the starch control, in which abscess formation and necrosis were frequently

observed. The pulps of those teeth treated with the antibiotic capping material demonstrated a decidedly more favorable reaction than did those pulps treated with the starch capping material.

Calcific repair at the exposure site was not observed to be complete in any instance.

The histologic findings for the antibiotic treated teeth were encouraging and warrant additional investigations of longer duration.