

## Physeal Growth Plate Fractures: Implications for the Pediatric Athlete

Tara J. Clark, Lindsey E. Eberman, and Michelle A. Cleary

**Abstract:** Pediatric musculoskeletal trauma accounts for most childhood injuries. The anatomy and physiology of the pediatric skeleton is unique as is its response to trauma. The pediatric skeleton has periods of rapid growth; therefore the effect of trauma to the musculoskeletal system may have significant long-term complications.

Musculoskeletal trauma is the primary cause of emergency department care for children and adolescents (Perron, Miller, & Brady, 2002). Musculoskeletal injuries are a leading cause of long-term morbidity and disability in pediatric patients, and may lead to loss of limb, permanent neurological dysfunction, premature growth arrest, angular limb deformity, posttraumatic arthritis, joint stiffness, and chronic pain. Pediatric orthopedic trauma management should differ from that of an adult because of the physiological and anatomical differences among populations. Pediatric skeletal characteristics include persistent growth, bone remodeling potential, elastic bone, open growth plates, thick periosteum, and smaller anatomic structures (Musgrave & Mendleson, 2002). Appropriate and timely management of these musculoskeletal injuries, in coordination with the management of life threatening injuries, is vital in minimizing long-term morbidity and dysfunction in pediatric trauma patients.

The most important difference between an immature skeleton and a mature adult skeletal system is the presence of a physis. The physis, also known as the growth plate, is the region of long bones involved in Salter-Harris fractures, the physeal injury classification system. Physeal injuries account for 15 to 30% of all skeletal injuries in children, (Greenfield, 1996; Mann & Rajmaira, 1990) occurring most commonly after the age of 10 (Della-Giustina & Della-Giustina, 1999; Greenfield, 1996). Approximately 80% of physeal injuries occur between the ages of 10 and 16 years (Peterson & Peterson, 1972; Rogers, 1970; Musharafieh & Macari, 2000). Physeal injuries are more frequent in boys than girls secondary to an overall increased incidence of musculoskeletal injuries as well as the developmental age of skeletal maturity in boys (Musharafieh & Macari, 2000; Peterson & Peterson, 1972; Rogers, 1970). Injury to the physis may be due to chronic overuse or it may be the result of an acute traumatic event. When injury to the physis is overlooked or mismanaged, growth plate impairment can occur causing a bone growth deficit (Perron et al., 2002). Growth plate problems can lead to improper growth of the limb leading to limb length discrepancies and angular deformities which persist throughout the lifetime. The purpose of this clinical research paper was to present current evidence on pathophysiology, classification, diagnosis, treatment, and prognosis of physeal fractures upon which to base best clinical practice and minimize the potential adverse effects of misdiagnosis or mismanagement of these types of injuries.

### Methods

The clinical research model involved collecting data by searching the internet databases MEDLINE, PubMed, and MDConsult with the following keywords: adolescent injuries, physeal fractures, epiphyseal fracture, growth plate, orthopedic injuries. Content was analyzed, outcomes were synthesized, and findings were critically applied to current clinical practice in order to promote changes that will foster effective and efficient methods of providing athletic training services (Portney & Watkins, 2000).

## Results

### *Pathophysiology*

The anatomy of pediatric bone (Figure 1a) consists of a diaphysis, periosteum, epiphysis, physis (growth plate), and metaphysis. The diaphysis is the primary portion of the long bone and provides tubular strength and support in axial loading. The periosteum is the double layer of connective tissue that covers the outer surface of most bones. Ligaments and tendons are interwoven into the periosteum, which serves to stabilize joints, thus supporting the mechanical functions involving movements of the joints of the body. Nervous tissue innervates the periosteum and is responsible for the pain associated with bone injuries. The epiphysis is composed of the secondary centers of ossification (bone growth) in the bone, which allow for specialized bone formation of shape and function. The epiphyseal structure also allows for the hypertrophied (increase in size) vascular epiphysis arteries to provide nutritional blood supply for the mature hyaline cartilage cell. The metaphysis is the funnel-shaped end of the long bone where remodeling of bone after a fracture most prominently occurs (Calmer & Vinci, 2002).

The primary function of the physis is rapid, integrated longitudinal bone growth. The physis (Figure 1a) is composed of cartilage, bone, and fibrous connective tissue. The cartilaginous component of the growing physis consists of four distinct zones listed in order from the epiphysis to the metaphysis: resting (germinal) cells, proliferating cells, hypertrophic/maturing cells, and provisional calcification. Of these zones, the hypertrophic zone is the weakest link due to its limited amount of collagenous matrix and lack of significant calcification, and consequently the zone where a cleavage plane is most likely to pass as a result of trauma. Normal growth and maturation of the physis is dependent on the nutrient blood supply received from the epiphysis. When injury to the physis disrupts the vascular supply, physeal growth plate arrest and joint incongruity may occur (Perron et al., 2002).

### *Classification and Diagnosis*

The Salter-Harris classification system (Figure 1) is the most well known and widely used classification system for growth plate injuries (Musgrave & Mendelson, 2002; Perron et al., 2002; White & Sty, 2002). The Salter-Harris classification system, based on the extent of involvement of the physis, epiphysis, and the joint, describes five types of growth plate fractures with specific prognostic and treatment implications. It is imperative for allied health practitioners to know and understand the Salter-Harris classification system to render appropriate treatment of the injury. A greater Salter-Harris fracture classification indicates an increased risk of physeal arrest and joint incongruity, predominately attributed to vascular supply disruption (Robertson, 1990; Salter & Harris, 1963).

Salter-Harris type I (Figure 1b) fractures are most frequently observed in infants and toddlers and generally require a shearing, torsion, or avulsion mechanism of injury (Perron et al., 2002). In these injuries, which represent 5-6% of physeal injuries, the fracture line passes horizontally through the physis separating the epiphysis from the metaphysis (Perron et al., 2002; White & Sty, 2002). No indication of osseous fracture to either the epiphysis or metaphysis occurs, and the line of cleavage runs through the hypertrophic zone, with the growing cells remaining on the epiphysis.

A Salter-Harris type II (Figure 1c) fracture is the most common type encountered, accounting for 75% of physeal injuries (Della-Giustina & Della-Giustina, 1999; Norlock & Stower, 1986; Perron et al., 2002; Salter & Harris, 1963; White & Sty, 2002). The line of the fracture runs through the hypertrophic zone of the physis and then out through a segment of

metaphyseal bone (Perron et al., 2002; White & Sty, 2002) leaving a metaphyseal spike attached to the epiphyseal fragment (Musgrave & Mendelson, 2002).

Salter-Harris type III (Figure 1d) fractures are intra-articular fractures of the epiphysis with extension through the hypertrophic cell layer of the physis (Perron et al., 2002; Musgrave & Mendelson, 2002; Perron et al., 2002; White & Sty, 2002). The fracture line begins on the articular surface and courses vertically through to the epiphysis and then horizontally through the peripheral aspect of the physis. This intra-articular injury creates a separate epiphyseal fragment with no connection to the metaphysis (White & Sty, 2002). These injuries account for nearly 10% of physeal injuries (Salter & Harris, 1963; Norlock & Stower, 1986; Della-Giustina & Della-Giustina, 1999; White & Sty, 2002; Perron et al., 2002).

A Salter-Harris type IV (Figure 1e) fracture line originates at the articular surface, crosses the epiphysis, extends through the full thickness of the physis, and exits through a segment of the metaphysis (Musgrave & Mendelson, 2002; Perron et al., 2002; White & Sty, 2002). A single fragment consisting of both epiphysis and metaphysis is created and is usually separated from the parent bone. These injuries account for 10% of all physeal fractures (Salter & Harris, 1963; Norlock & Stower, 1986; Perron et al., 2002; White & Sty, 2002).

The Salter-Harris type IV (Figure 1f) fracture, the most rare fracture pattern, accounting for only 1% or less of physeal injuries, may result in focal bone growth arrest (Della-Giustina & Della-Giustina, 1999; Greenfield, 1996; Norlock & Stower, 1986; Ogden, 1982; Perron et al., 2002; Salter & Harris, 1963; White & Sty, 2002;). These injuries are most likely to occur at the knee or ankle, and are the result of a severe abduction or adduction injury transmitting profound compressive forces across the physis (Perron et al., 2002). This resultant axial compression crushes the physis, specifically injuring the cells of the resting and proliferative zones (Perron et al., 2002).

#### *Clinical Presentation and Evaluation*

Injury to the physis in children is common due to the inherent vulnerability of this structure. The physis is the part of the bone most vulnerable to failure and represents the weak link in this patient population (Musgrave & Mendelson, 2002; Perron et al., 2002). Children generally have increased ligamentous strength versus adults, resulting in mechanical forces stressing the integrity of the physis. Practitioners should recognize that a similar mechanism of injury resulting in a sprain or dislocation in an adult could cause physeal injuries in children (Perron et al., 2002).

Injury to the physis may be the result of an acute traumatic event or chronic overuse. The most common mechanisms for upper extremity injuries are a direct blow, collision, or falling on an outstretched arm (Gomez, 2002; Musharafieh & Macari, 2000; Perron, et al., 2002). Abduction, adduction, and torsion forces are frequently encountered with lower extremity physeal injuries (Gomez, 2002). Physical examination and history are central in diagnosing this injury. Due to occasionally insignificant findings on x-ray film, it is vital that practitioners obtain a thorough history and physical examination for a proper diagnosis. Upon physical examination, signs and symptoms range from subtle to obvious (Perron et al., 2002). Inspection for signs of deformity and swelling, palpation for deformity and crepitus, evaluation of range of motion, stability testing, neurovascular evaluation and performance tests such as impingement signs should be performed (Gomez, 2002; Wasserlauf & Paletta, 2003). Neurovascular complications are not often common in physis injuries, but any neural or vascular complications must be ruled out. Patients with humeral physeal plate fractures present with limited active abduction secondary to the orientation of the fracture in association with the deltoid tuberosity (Gomez,

2002). Point tenderness superficial to the physis is often reason enough to suspect a growth plate injury (Perron et al., 2002; White & Sty, 2002).

#### *Radiographic Findings*

Obtaining the appropriate imaging study is the first and most important step in the radiological evaluation of pediatric musculoskeletal injuries. Radiographic evaluation is the mainstay of imaging in the evaluation of the skeletally immature population (Wasserlauf & Paletta, 2003). Detection of physis injuries is difficult because of the radiolucent properties (Perron et al., 2002). Acute physis fractures may occur without any radiographic abnormalities, or may appear as a widened physis. Correlating clinical findings and selective use of contralateral comparison films to minimize diagnostic errors serve in appropriate diagnosis (Perron et al., 2002). Radiographic (X-ray) findings of Salter-Harris I fractures may reveal a physeal widening and epiphyseal displacement, but more frequently appear normal (Musgrave & Mendelson, 2002; White & Sty, 2002). In this case, diagnosis is made clinically by demonstrating tenderness over the area of the growth plate.

Salter-Harris fractures II, III, and IV are usually evident on plain X-ray film, but types I and V can be radiographically occult in the acute setting often leading to misdiagnosis (Perron et al., 2002; White & Sty, 2002). Judicious use of stress radiography (an X-ray while stress is applied to the joint) frequently performed under orthopedist supervision can be helpful in acute conditions (Perron et al., 2002). Ultrasonography, bone scintigraphy, and magnetic resonance imaging (MRI) have all been advocated for the assessment of these injuries as well (Naranja, Gregg, Dormans, Drummond, Davidson, & Hahn, 1997; Perron et al., 2002; Rizzo, Bould, Lyden, & Asnis, 1993). MRI scans performed within 10 days of fracture may change the Salter-Harris classification, especially in confusing fracture patterns that are difficult to interpret on radiographs. MRI performed early (between 3 and 17 weeks after fracture) can demonstrate transphyseal bridging or altered growth lines in physeal fractures before these become apparent on plain radiographs (Canale, 1998).

#### *Treatment and Prognosis*

Education for parents and patients regarding treatment and potential growth abnormalities is an important aspect of care. Although, negative radiographs are common, X-rays with point tenderness over a physis indicates a Salter-Harris type I injury and should be treated as such. Treatment for type I injuries consists of splint immobilization, intermittent icing, and referral to an orthopedic surgeon for re-evaluation and follow-up (Perron et al., 2002). Due to the continuity with nutrient blood supply, Salter-Harris type I fractures carry an optimistic prognosis and infrequently result in any growth disturbances. However, possible exceptions occur at the proximal radius, proximal and distal femur, and proximal tibia due to premature physeal closure and posttraumatic growth arrest due to repetitive compressive stress at these locations (Hogan & Gross, 2003; Howald, Weiss, & Sizonenko, 1993; White & Sty, 2002).

Type II injuries can be similarly managed with splinting and outpatient follow-up as long as there is no angulation or significant displacement of the fracture segment (Perron et al., 2002). As with type I fractures, growth is usually preserved since the reproductive layers of the physis remains connected to the epiphysis and blood supply, making for a favorable prognosis (Perron et al., 2002; White & Sty, 2002).

Type III fractures frequently require open reduction and internal fixation surgical techniques. Anatomic alignment of the epiphyseal fracture fragment for both blood supply maintenance and joint congruity must be achieved for appropriate bone growth (Perron et al., 2002). Near perfect alignment of the articular surface is critical for successful outcomes. The

prognosis for normal bone growth is generally positive, but more guarded than with type I or II injuries (Perron et al., 2002; White & Sty, 2002). Anatomical position must be reestablished to restore normal joint function and prevent growth arrest (White & Sty, 2002). With greater displacement and/or fragmentation, the risk for blood supply disruption, and subsequent growth disturbances increases (Della-Giustina & Della-Giustina, 1999; Kaedin & Whitehead, 1998; Norlock & Stower, 1986; Perron et al., 2002; Salter & Harris, 1963).

Type IV injuries have an increased likelihood of operative intervention to achieve anatomic reduction, and even with good reduction carry a significant risk of growth disturbances (Norlock & Stower, 1986; Perron et al., 2002; Salter & Harris, 1963). Open reduction and internal fixation are sometimes necessary (White & Sty, 2002). Growth arrest and joint deformities are higher risks depending on the degree of blood supply disruption from the epiphysis (Perron et al., 2002; White & Sty, 2002).

Type V injuries typically affect the lower extremity, and patients with type V injuries are usually casted and endure prolonged non-weight-bearing (Perron et al., 2002). With this type of fracture, there is no or minimal displacement, and diagnosis is often made in retrospect once a bone growth abnormality has been identified (Canale, 1998; Musgrave & Mendelson, 2002; Perron et al., 2002; White & Sty, 2002).

### **Clinical Implications**

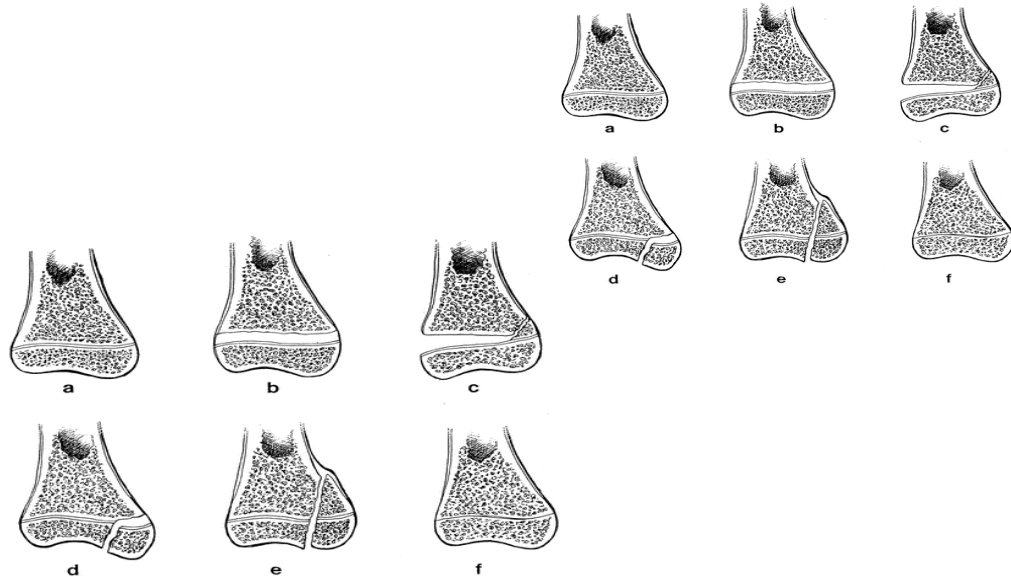
It is imperative for health practitioners that work with children sport participants to remain current on the evidence upon which they base their clinical practice. Practitioners must understand that the anatomical and physiological characteristics of the adolescent musculoskeletal system differ from that of an adult and therefore should be treated differently. With nearly 15-30% of all pediatric skeletal injuries involving injury to the physis, it is vital for practitioners to be able to properly evaluate and recognize these injuries. Understanding the mechanism of injury, obtaining a thorough history, and a proper physical examination are key components of correctly diagnosing physeal injuries. The presence of open physes results in the ability to remodel certain angular deformities that would be intolerable in adults. The desire to avoid iatrogenic or unwanted results of treatment for physeal injuries can limit the options for rigidly stabilizing pediatric fractures. Clinical evidence supports acknowledging that differences exist in the appropriate management of pediatric trauma compared to adults. Appropriate recognition and orthopedic treatment of injuries such as physeal fractures will allow the avoidance of potential long-term disabilities as a result of mismanagement. As health care practitioners, athletic trainers must constantly remain informed of the current standard of care and correctly recognize physeal fractures for appropriate management and to minimize potential long-term disability and dysfunction caused by these orthopedic injuries.

### **References**

- Calmar, A., & Vinci, R. (2002). The anatomy and physiology of bone fracture and healing. *Clinical Pediatric Emergency Medicine*, 3(2), 85-93.
- Canale, T. (1998). Physeal injuries. In T. S. Canale & W. C. Campbell (Eds.), *Campbell's operative orthopedics* (9<sup>th</sup> ed., pp. 2364-2367). St. Louis, MO: Mosby.
- Della-Giustina, K., & Della-Giustina, D. (1999). Emergency department evaluation and treatment of pediatric orthopedic injuries. *Emergency Medicine Clinical*, 17, 895-922.
- Gomez, J. (2002). Upper extremity injuries in youth sports. *Pediatric Clinics of North America*, 49(3).
- Greenfield, R. (1996). Orthopedic injuries: Pediatric emergency medicine. In G. Strange & W. Ahrens (Eds.), *Pediatric emergency medicine* (pp. 113-118). New York: McGraw-Hill.

- Hogan, K., & Gross, R. (2003). Overuse injuries in pediatric athletes. *Orthopedic Clinics of North America*, 34(3).
- Kaeding, C., & Whitehead, R. (1998). Musculoskeletal injuries in adolescents. *Primary Care Clinical Office Practice*, 25, 211-223.
- Mann, D. C., & Rajmaira, S. (1990). Distribution of physeal and nonphyseal fractures in 2,650 long bone fractures in children aged 0-16 years. *Journal of Pediatric Orthopedics*, 10, 713 - 716.
- Musgrave, D., & Mendelson, S. (2002). Pediatric orthopedic trauma: Principles in management. *Critical Care Medicine*, 30(11).
- Musharafieh, R., & Macari, G. (2000). Salter-Harris I fractures of the distal radius misdiagnosed as wrist sprain. *Journal of Emergency Medicine*, 19, 265-270.
- Naranja, R., Gregg, J., Dormans, J., Drummond, D., Davidson, R., & Hahn, M. (1997). Pediatric fracture without radiographic abnormality: Description and significance. *Clinical Orthopedic Related Research*, 342, 141-146.
- Norlock, P., & Stower, M. (1986). Fracture patterns in Nottingham children. *Journal of Pediatric Orthopedics*, 6, 656-660.
- Ogden, J. (1982). Skeletal growth mechanism injury patterns. *Journal of Pediatric Orthopedics*, 2, 371-377.
- Perron, A., Miller, M., & Brady, M. (2002). Orthopedic pitfalls in the emergency department: Pediatric growth plate injuries. *American Journal of Emergency Medicine*, 20, 50-54.
- Peterson, C., & Peterson, H. (1972). Analysis of the incidence of injuries to the epiphyseal growth plate. *Journal of Trauma*, 12, 275-281.
- Portney L. G., & Watkins, M. P. (2000). *Foundations of clinical research*. Upper Saddle River, NJ: Prentice Hall Health.
- Rizzo, P., Gould, E., Lyden, J., & Asnis, S. E. (1993). Diagnosis of occult fractures about the hip: Magnetic resonance imaging compared with bone scanning. *Journal of Bone Joint Surgery America*, 75, 395-401.
- Salter, R., & Harris, W. (1963). Injuries involving the epiphyseal plate. *Journal of Bone Joint Surgery*, 45, 587-622.
- White, N., & Sty, J. (2002). Radiological evaluation and classification of pediatric fractures. *Clinical Pediatric Emergency Medicine*, 3(2), 94-105.

*Figure 1. a, the distal end of a long bone consists of the metaphysis, physis, and epiphysis; b, a Salter-Harris type I fracture involves the physis only; c, a Salter-Harris type II fracture includes a metaphyseal spike attached to the epiphyseal fragment; d, a Salter-Harris type III fracture propagates across the physis and then across the epiphysis, exiting the joint surface; e, a Salter-Harris type IV fracture transverses the metaphysis, physis, and epiphysis; f, a Salter-Harris type V fracture is a physeal torus fracture resulting from axial compression.*



From: Musgrave, D., & Mendelson, S. (2002). Pediatric orthopedic trauma: Principles in management. *Critical Care Medicine*, 30(11).