

EXCLI Journal 2006;5:93-102 – ISSN 1611-2156

Received: 30. July 2006, accepted: 18. August 2006, published: 4. September 2006

Original article:

Bite mark analysis in forensic routine case work*

Lessig R*, Wenzel V, Weber M

Institute of Legal Medicine of the University of Leipzig, Johannisallee 28, D-04103 Leipzig, Germany, phone: +49 341 9715118 fax: +49 341 9715109, e-mail: Ruediger.Lessig@medizin.uni-leipzig.de (*corresponding author)

*This paper is dedicated to Prof. Dr. W. J. Kleemann, the former director of the Institute of Legal Medicine of the University of Leipzig, who died at the 22nd of February 2006.

ABSTRACT

The individuality of the human dentition frequently allows the Forensic Odonto-Stomatologist (FOS) to reach a strong opinion of association in cases of identification and bite mark analysis. Such analysis can often be useful during the investigation of violent crimes, especially those involving sexual assault. Bites from animals are rarely the object of bite mark analysis. The teeth of animals leave patterned injuries that appear quite different from those created by human teeth. This is especially true with dogs, which are predominant culprits in bites to humans. Dogs bite humans at a rate eight times more frequently than humans bite each other. However, such bites may need to be analyzed in order to distinguish what species of animal may have been the attacker, or exclude one or more animals when there is more than one possible offender.

Typical cases of routine bite mark analysis encountered by the FOS are presented. Two cases of dog bites appearing as possible accidents and two human bites report about this spectrum. In another case, a child abuse with several specific bite marks shows the potential to detect the perpetrator. The last case representing a bite mark in a fruit is obtained from criminal routine case work.

It is hoped that these cases will demonstrate the significant role the analysis of bite marks might play alongside other criminalistic routines. The FOS is often involved in a late stage of the investigation. This is one reason for the problems associated with the bite mark analysis in the cases presented. Additionally, the quality of the documentation of patterned injuries is often incomplete.

Keywords: forensic odonto-stomatology, bite mark, digital analysis

INTRODUCTION

The forensic odonto-stomatological investigation of bite marks is rare among the routine casework in forensic sciences. The term 'bite mark' is used in this field knowing that the marks are the result of the tooth impression in different materials. So in the literature bite mark is mostly used as description (Barbenel and Evans 1977,

Aboshi et al. 1994, Ligthelm and van Niekerk 1994, Saglam et al. 1998, Bernitz et al. 2000, McKenna et al. 2000, Sakoda et al. 2000, Pretty and Sweet 2001a, Pretty and Sweet 2001b, Pretty and Turnbull 2001, Sheasby and MacDonald 2001, Wright and Dailey 2001, Röttscher et al. 2003, Thali et al. 2003). The state of the dentition, the degree of breakdown and/or repair of the teeth may create a bite mark with a high level

of individuality. In some cases, bite marks may allow an identification of the biter (Ligthelm and van Niekerk 1994, Saglam et al. 1998, Lessig and Benthaus 2003). Most bite marks are obtained from cases of sexual violence. Some may be defensive bites placed on the attacker by the victim, and, though rarely seen, some bite marks may be self-inflicted.

Generally, bite marks consist of superficial abrasion, and/or sub-surface haemorrhage, or bruising of the skin because of the bite (Endris 1979). Though the mechanism is not clearly understood, the pattern of the injury is affected by the force and length in time of the bite, in combination with other mechanical and physiologic factors. Barbenel and Evans (1977) have discussed the influence of the lineages of the skin.

Bite marks can be found in cases of sexual violence in typical areas of the human body – genitals and breasts -, but also in cases of child abuse. In such cases the number of the bites obtained can be very high. Trube-Becker (1973) reported a case with 17 bite marks.

Occasionally bite marks are obtained in various types of food like chocolate, chewing gum, fruits, vegetables and similar (Endris 1979, Saglam et al. 1998, McKenna et al. 2000). Solid food has an advantage in such cases. Aboshi et al. (1994) reported the identification of a suspect arsonist by means of bite marks in cakes which were found at the scene of the crime. A missing upper right central incisor was proved to be in the patterned injury. Bernitz et al. (2000) reported a case of murder with a bite mark in a piece of cheese which was recorded. The pattern-associated comparison between the impression and a study model of the suspect was able to identify the perpetrator. Fingerprints and DNA evidence were not found at the crime scene. The court was reluctant to accept the validity of the method of the investigation. For this reason the FOS controlled the method with several bite

marks in cheese, butter and cooked potato. Pair-wise comparisons were made by two odontologists. The examiners correctly identified all the true matches as well as selecting the dental models for which there were no corresponding impressions.

The characteristics of human bites are superficial abrasion and/or sub-surface haemorrhage looking like an arch. They are caused by the incisors, canine and premolars. The abrasions and/or haemorrhage caused by the canine are in a shape of points. If the perpetrator has dentures additional specific marks can be expected. They differ between bridges, crowns and dentures. Crowns and bridges may have a ceramic surface and partial dentures braces to fix at the teeth. These peculiarities can be responsible for specific wounds and additional markers for identification.

Depending on the part of the body and the constitution of the skin the bite mark can be distorted. Frequently this can be the reason for problems when analysing bite marks. To prevent mistakes by the pattern-associated comparison it is recommended to simulate bites at similar body parts using the study casts of the suspect (Lessig 2001, Lessig and Benthaus 2003) or using digital technique for a stepwise dynamic comparison (Sakoda et al. 2000, Thali et al. 2003). Sheasby und MacDonald (2001) recommend a classification to emphasize the need of a scientific approach for the interpretation of the types of distortion. They introduce the terms of primary and secondary distortion. Primary distortion is defined by the dynamics of the bite. Secondary distortions have three categories: time-related distortion when a bite changes with time elapsed subsequent to the bite being made, posture distortion and photographic distortion.

Important is the differentiation of human and animal bites as well as to identify the kind of the human bite. Human bites may be classified in different ways for example

being defensive or offensive (Röttscher et al. 2003).

To record a bite mark an exact photographic documentation and a one-to-one transfer to transparent paper or acetate sheet are indispensable (Fig. 1a). Swabbing of the bite injury is important to recover trace evidence. Stains of saliva or human cells for a DNA analysis should be collected whenever possible (Wright and Dailey 2001, Lessig and Benthaus 2003).

Bite marks are often difficult to notice and may be overlooked. Sometimes it is problematical to detect and secure these patterns. The aim of the study was to present different examples of the forensic routine casework which demonstrate that an examination should be tried even in cases with patterned injuries of low quality or poor documentation.

MATERIAL AND METHODS

The photographs were taken using the scale ABFO No.2 (Fig. 1b). Given photographs were scanned using a flatbed scanner (Expression 1680, Seiko Epson Corp.). The photos were processed using Adobe Photoshop 7.0 (Adobe Systems Inc., USA).

From suspects study casts of the upper and lower jaw were taken. The registration of articulation was done with the help of an articulator (Fig. 1c). Subsequently, impressions on transparency for pattern-associated comparison were done. The bite marks and photographs were digitised as described. The digitised bite marks and the scanned photographs were compared using the Software Microsoft® PowerPoint® 2000 (Microsoft Corporation, USA) and superimposition as method.

Bite marks in foodstuffs were investigated making a positive model of the impressions using plaster. Study casts of suspects were used for pattern-associated comparison of the bite marks.




Figure 1a: Copy of bite mark from victim transferred to acetate sheet




Figure 1b: Scale recommended by the ABFO

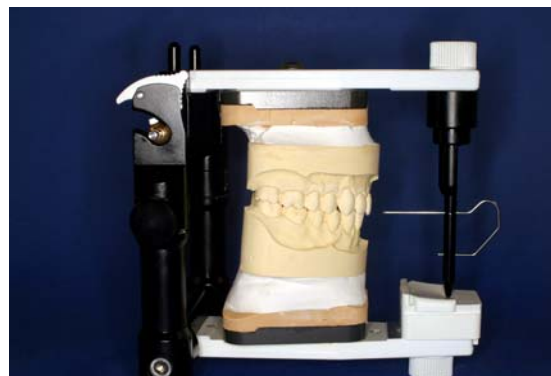

Figure 1c: Articulator with study casts

CASE REPORTS

CASE 1

In a late stage of the criminal investigations we got photographs of a child. The patterned injuries on the photos looked similar to bite marks. The photos were obtained during a forensic medical investigation. Unfortunately, they were taken without measurement. However, typical arches of superficial abrasions on different regions of the body were found. In these arches conspicuous points of abrasions were located. They were regularly arranged and had equal distances in the pattern. The localization and the appearance are specific for the biter. Study casts of the parents were available. Using these casts impressions were produced and compared to the bite marks (Fig. 2a). One of the parents, the father, wore dentures, which had specific clamps for fixation on the teeth. Comparing these with the bite marks it was possible to identify the clamps as cause of the specific injuries (Fig. 2b). Thus, the father was not excluded as perpetrator (Fig. 2c).




Figure 2a: Acetate sheets with transferred marks of the study casts of the suspect (upper jaw left and lower jaw right figure)

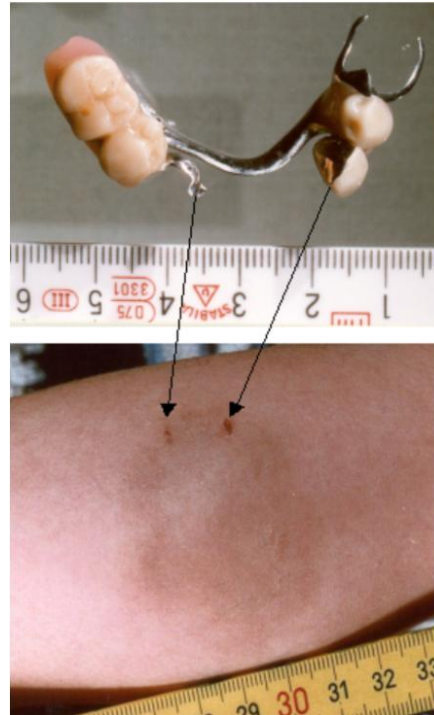


Figure 2b: Specific injuries on the arm of the victim

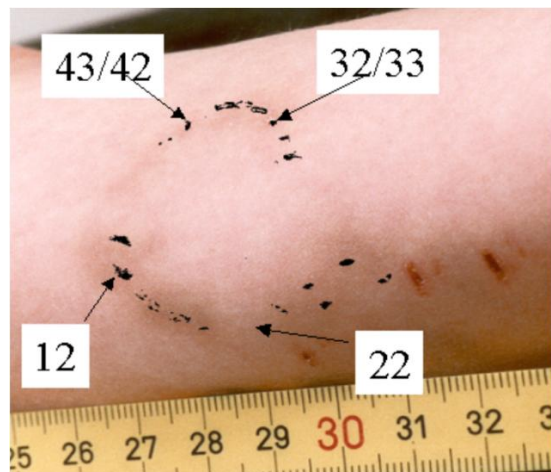


Figure 2c: Bite mark with overlaid acetate sheet of the mark from the study casts of the putative perpetrator (Numbers represent the specific teeth which could be identified as (12) second incisor of the right upper jaw, (22) second incisor of the left upper jaw, (32) second incisor and (33) eye tooth of the left lower jaw, (42) second incisor and (43) eye tooth of the right lower jaw)

CASE 2

From a civil court we got files concerning an ongoing quarrel between neighbours. The files contained photos (Polaroid) from different dates depicting injuries of a woman taken by her husband after a dog attack. The victim and her husband reported that the

German shepherd of their neighbours had bitten her on the street. The woman contacted a doctor after the attack. The wound was documented with a short medical expertise in the files reporting about the wounds. A long time after the incident had been reported to the police the court sent us the files and the skull of the German shepherd who had died. The Polaroid photos had a bad quality and were taken without a scale. The recorded wounds were located at the hip and looked like a dog bite. The maxilla of the German shepherd showed a missing canine (Fig. 3a). The question of the court was whether it would be possible to identify the German shepherd by the missing canine as the biter. A dog has three incisors, one canine, four premolars and two molars (three molars on the mandible) on every side of the jaw (Pollak und Mortinger 1989). Patterns from the jaws of the dog were taken. So it was possible to identify the injuries on the photos as a typical result of a snapping dog. Wounds due to snapping by a dog usually show parallel abrasions of the third incisors. In this case the canines were not involved. The overlay of the digitised photos and patterns was analyzed. The pattern taken from the jaw could be projected on the bite mark without problems (Fig. 3c). The tooth marks between the arches could be explained as a result of the snap. The right upper third incisor left three marks during the snap. It was possible to show that the German shepherd could have been the perpetrator, but it was impossible to identify this particular dog as the biter by the missing canine.

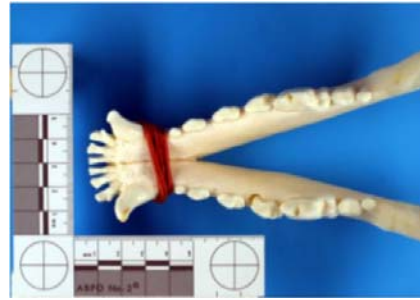


Figure 3b: Lower jaw of the German shepherd

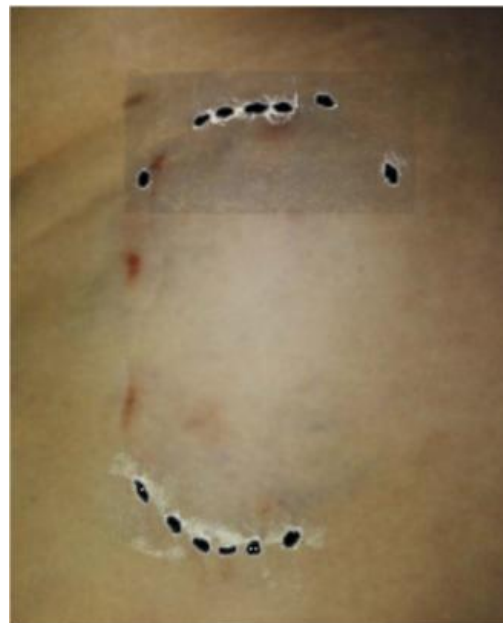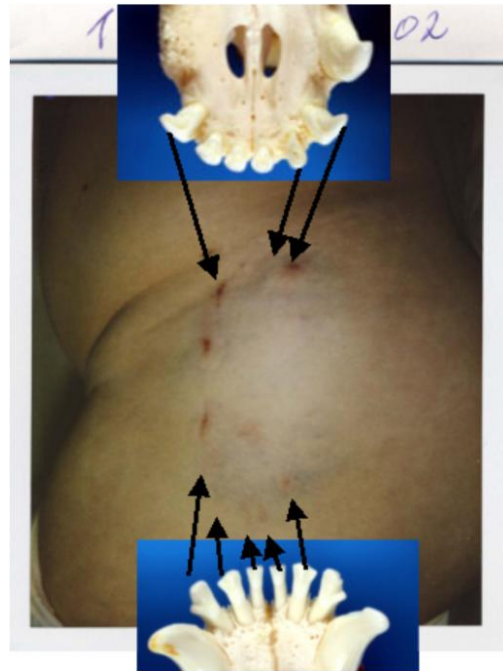


Figure 3c: Allocation of the teeth to the pattern of the bite mark using photos of the jaws (top) and a transparent paper of marks taken from the jaws (bottom)

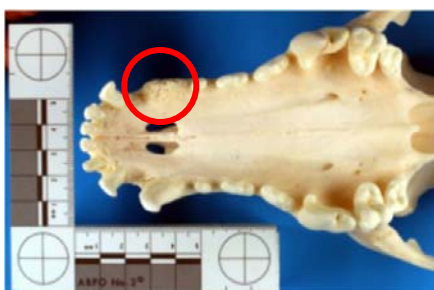

Figure 3a: Upper jaw of the German shepherd (red mark indicates missing canine of left upper jaw)

CASE 3

A young girl (5 years old) played on a toboggan run during a winter afternoon. When she wanted to caress a Rottweiler, she was bitten as reported by her mother to the police. However, the owner of the dog said that the child had fallen down near the dog and was injured by the necklace which had spikes. More than one year after the accident has occurred we got the file. The photos, which were taken by the family of the girl, have no scale and show patterned injuries on the right side of the girl's face. A cut in the right angle of the mouth, which had been treated by surgery, was documented in the medical report. Additionally, a region of superficial abrasions was shown on the cheek. The court asked whether the injuries were caused by contact with the necklace or by a dog bite. The investigations identified the injuries on the right side of the face of the child caused by a dog bite. The overlay with pattern, taken from a skull of a Rottweiler, can be clearly adapted to the patterned injuries (Fig. 4a, 4b and 4c). Additionally, the injuries appeared like a typical bite mark, indicating the injuries being caused by a dog bite.

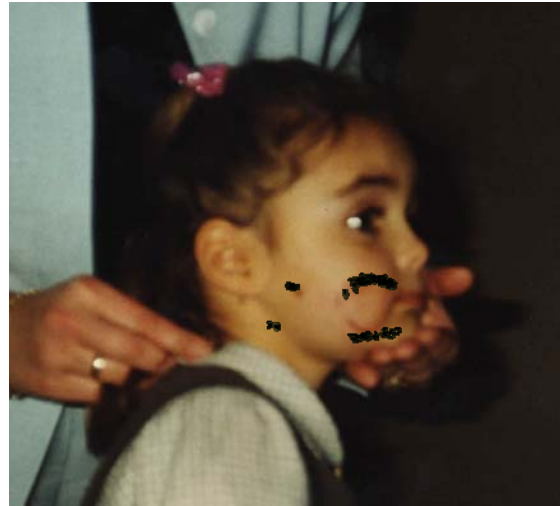

Figure 4b: Superimposition of the marks taken from the jaws of a Rottweiler to the pattern of the bite mark



Figure 4c: Necklace of the dog, presented by the owner as cause of the injury

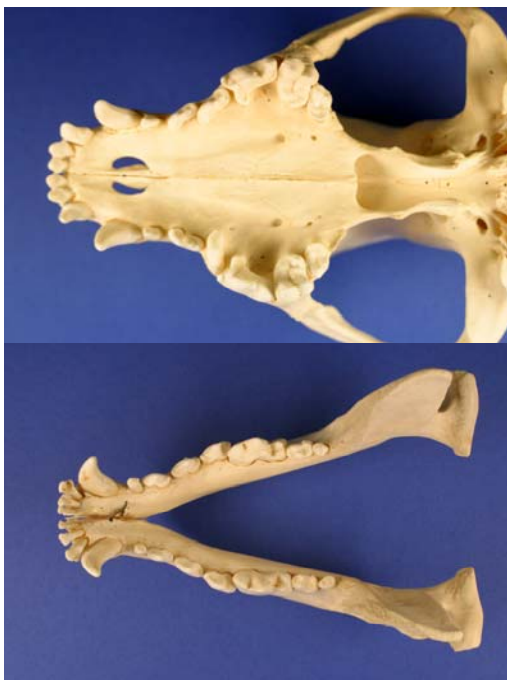

Figure 4a: Upper and lower jaw of a Rottweiler

CASE 4

A negative impression of a bite mark from an apple was taken by the state police of Saxony and sent to our institute (Fig. 5a). The apple was found during criminal investigations after a burglary. Initially, DNA analysis was performed. However, inconclusive results were obtained. Study casts of the suspect were taken. A duplicate of the bite mark using plaster was done (Fig. 5b) and showed the specific arch of the teeth. The teeth of the casts taken from the suspect show an identical arch. So the suspect was not excluded as perpetrator (Fig. 5c).

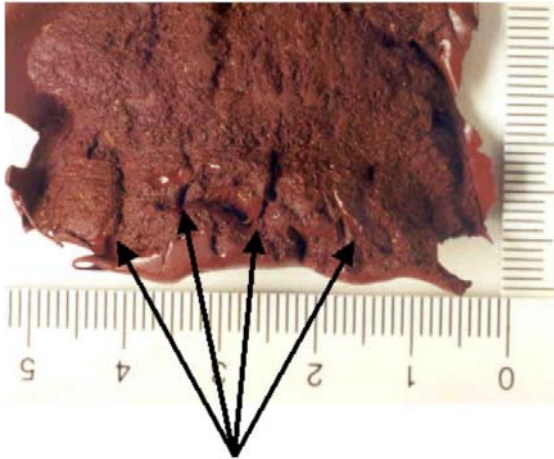


Figure 5a: Negative impressions of the bite mark taken from the apple



Figure 5b: Positive impressions of the bite mark taken with plaster from the negative

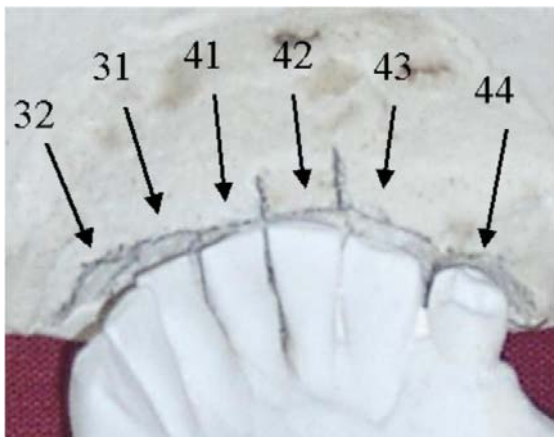


Figure 5c: Comparison of the bite mark and the teeth of a study cast of the lower jaw of the suspect

DISCUSSION

The presented cases illustrate the high potential of bite mark analysis in forensic investigations. Despite the insufficiently

recorded patterned injuries, the bad quality of photos, the lack of scales on photos, and the contact with a forensic odonto-stomatologist in a late stage of the investigations, successful analyses of the bite marks were possible. The uniqueness of the human dentition and analytical techniques usually allow an exact identification of the perpetrator (Pretty and Sweet 2001a, Friedrich et al. 2005). But the better way of interpretation should be the statement that there is a possibility to exclude the suspect, or a high probability that the suspect is the cause of the bite mark. The quality of the bite mark is an important factor. New approaches with digital techniques overlaying the bite mark and patterns of a suspect facilitate an exact investigation. Bite mark and study casts can be compared using three-dimensional pictures (Thali et al. 2003). However, it is important to ensure a high level of quality regarding the documentation of offender traces, which should be secured by specialists only (Pretty and Sweet 2001b). Due to the strategy to get DNA evidence first, opportunities for forensic odonto-stomatological investigations are often used at a later stage, and experts are usually not involved recording the bite marks. Thus, the documentation of patterned injuries is often based on recommendations for DNA analysis. Thus guidelines for other forensic investigations for proper photographic documentation are forgotten as shown in the presented cases. With respect to possible failures of DNA identification, forensic odonto-stomatological investigations should be considered routinely in all cases of bite injuries.

Concerning dog bites, a differentiation between dogs of the same race is normally not possible but the analysis can be helpful to identify the dog (de Munnynck and van de Verde 2002). Bites by animals are rare in the forensic routine casework and obtained post mortem mostly. Sometimes these injuries are documented by medico-legal investigations of victims after violence. Recently, some cases of dog attacks were reported. These

cases are much more often under examination than attacks of other animals. Traditionally some professions are more at risk, e.g. postmen and veterinarians. In the USA, in every year 12 of 1000 postmen are bitten by a dog (Landercaasper et al. 1988).

Children are often victims of dog attacks. In the years 1979 to 1988, 157 deaths by dog bites of children younger than 10 years were reported in the USA (Pollak and Mortinger 1989, Lauridson and Myers 1993). The anatomic situation normally allows a correct differentiation between a human and an animal bite. Especially dog bites are easy to identify. As a matter of course, the differentiation of dog races is problematic. Inhülsen (1991) reported a case of murder with patterned injuries of a dog. It was impossible to differentiate between a Rottweiler and a German shepherd. Ligthelm und van Niekerk (1994) presented two cases of dog bites. They had the distinction of being spread over the entire body which is rather unusual in cases of human bite marks. Guidelines for the analysis of bite marks are important for the investigation and should be respected. To standardize the analysis of bite marks the American Board of Forensic Odontostomatology (ABFO) established the following guidelines in 1986:

1. History – Obtain a thorough history of any dental treatment carried out after the suspected date of the bite mark.
2. Photography – Extra-oral photographs including full face and profile views, intra-orals should include frontal views, two lateral views and an occlusal view of each arch. Often it's useful to include a photograph of maximal mouth opening. If inanimate materials, such as foodstuffs, are used for test bites the results should be preserved photographically.
3. Extra-oral examination – Record and observe soft tissue and hard tissue

factors that may influence biting dynamics. Measurements of maximal opening and any deviations on opening or closing should be made.

4. Intra-oral examination – Salivary swabs should be taken. The tongue should be examined to assess size and function. The periodontal status should be noted with particular reference to mobility. Prepare a dental chart if possible.
5. Impressions – Take two impressions of each arch using material that meet the American Dental Association specifications. The occlusal relationship should be recorded.
6. Sample bites – Whenever possible, sample bites should be made into an appropriate material, simulating the type of bite under study.
7. Study casts – Casts should be prepared using Type II stone. Additional casts should be made by duplicating the master casts.

These guidelines should be obeyed in routine case work. Pretty and Sweet (2001c) sent out a questionnaire to 69 American odontologists examining bite marks. The purpose was to examine the adherence to the guidelines. 28 (41%) of the odontologists were members of the ASFO (American Society of Forensic Odontology). The authors found that the methods differ between the examiners. However, in general the odontologists adhere to the guidelines. The materials employed by the odontologists were acceptable and defensible in court. Forensic dentists who neglect the guidelines could face harsh criticism when testifying in court (Pretty and Sweet 2001d). Pretty and Turnbull (2001) reported about a lack of dental uniqueness between two suspects. The dental arrangement of the suspects was similar and it was impossible to determine the biter positively. Thus, the central dogma

that every bite mark is unique, was disproved.

In another study the effectiveness of digital bite mark overlays was verified. Different examiners were asked to compare scanned photos of bite marks with impressions of suspects. Pretty and Sweet (2001b) found that the experience of the examiners has an influence on the results, however, the method has a high level of reliability.

Using patterns of the study casts of a suspect and fixation of the bite registration are the basis for a successful analysis (Endris 1979). Impressions in similar material produced with study casts of the suspect could be associated with patterns from the case. The cases show that it is worth trying bite mark analysis even in cases of bad documentation.

ACKNOWLEDGEMENTS

We gratefully thank J. Curtis Dailey, DDS Diplomate, ABFO for his helpful review and comments.

REFERENCES

- Aboshi H, Taylor JA, Takei T, Brown KA. Comparison of bitemarks in foodstuffs by computer imaging: a case report. *J Forensic Odontostomatol* 1994; 12: 41-44
- American Board of Forensic Odontology (ABFO), Inc: Guidelines for bite mark analysis. *J Am Dent Ass* 1986; 112: 383-386
- Barbenel JC, Evans JH. Bite marks in skin – mechanical factors. *Int J Forens Dent* 1977; 4: 6
- Bernitz H, Piper SE, Solheim T, van Niekerk PJ, Swart TJP. Comparison of bitemarks left in foodstuffs with models of the suspects dentitions as a means of identifying a perpetrator. *J Forensic Odontostomatol* 2000; 18: 27-31
- Endris R. Praktische Forensische Odontostomatologie. *Heidelberg: Kriminalistik Verlag*, 1979
- Friedrich RE, Scheuer HA, Schulz F. Zuordnung einer Bissmarke an der Haut des Opfers zum Gebiss des Täters durch Nachweis von Anomalien der Stellung und Zahl der Frontzähne. *Arch Kriminol* 2005; 215: 11-17
- Inhülsen D. Identifizierung von Hundebissen mit Hilfe einer Video-Vergleichsanlage. *Arch Kriminol* 1991; 187: 111-118
- McKenna CJ, Haron MI, Brown KA, Jones AJ. Bitemarks in chocolate: a case report. *J Forensic Odontostomatol* 2000; 18: 10-14
- Lessig R. Die forensische Stomatologie als Teil der rechtsmedizinischen Praxis. In: Oehmichen M, Geserick, G (Eds.) Osteologische Altersschätzung und Identifikation. *Research in Legal Medicine Vol 26*. Lübeck/Germany: Schmidt-Römhild, 2001: 67-74
- Lessig R, Benthaus S. Forensische Odontostomatologie. *Rechtsmedizin* 2003; 13: 161-168
- Ligthelm AJ, van Niekerk PJ. Comparative review of bitemark cases from Pretoria, South Africa. *J Forensic Odontostomatol* 1994; 12: 23-29
- de Munnynck K, van de Verde W. Forensic approach of fatal dog attacks: a case report and literature review. *Int J Leg Med* 2002; 116: 295-300
- Landercasper J, Cogbill TH, Strutt PJ, Landercasper BO. Trauma and the veterinarian. *J Trauma* 1988; 28: 1255-1259
- Lauridson JR, Myers L. Evaluation of Fatal Dog Bites: The View of the Medical Examiner and Animal Behaviorist. *J Forensic Sci* 1993; 38: 726-731
- Pollak S, Mortinger H. Tödliche Hundebissverletzungen. *Beitr Gerichtl Med* 1989; 47: 487-495
- Pretty IA, Sweet D. The scientific basis for human bite mark analyses – a critical review. *Science & Justice* 2001a; 41: 85-92
- Pretty IA, Sweet D. Digital bite mark overlays – an analysis of effectiveness. *J Forensic Sci* 2001b; 46: 1385-1391

- Pretty IA, Turnbull MD. Lack of dental uniqueness between two bite mark suspects. *J Forensic Sci* 2001c; 46: 1487-1491
- Pretty IA, Sweet D. Adherence of forensic odontologists to the ABFO bite mark guidelines for suspect evidence collection. *J Forensic Sci* 2001d; 46: 1152-1158
- Rötzscher K, Pilz W, Solheim T. Bissspur – Zahns spur. In: B. Madea, B. Brinkmann (Eds) *Handbuch gerichtliche Medizin Vol 2*. Springer Berlin-Heidelberg-New York, 2003: 1699-1728
- Saglam Atsü S, Gökdemir K, Kedici PS, Ikyaz YY. Bitemarks in forensic odontology. *J Forensic Odontostomatol* 1998; 16: 30-34
- Sakoda S, Fujita MW, Zhu BL, Oritani S, Ishida K. Wounding dynamics in distorted bitemarks: two case reports. *J Forensic Odontostomatol* 2000; 18: 46-51
- Sheasby DR, MacDonald DG. A forensic classification of distortion in human bite marks. *For Sci Int* 2001; 122: 75-78
- Thali MJ, Braun M, Markwalder TH, Brueschweiler W, Zollinger U, Malik NJ, Yen K, Dirnhofer R. Bite mark documentation and analysis: the forensic 3D/CAD supported photogrammetry approach. *For Sci Int* 2003; 135: 115-121
- Trube-Becker E. Bißspuren bei Kindesmißhandlungen. *Beitr Gerichtl Med* 1973; 31: 115-123
- Wright FD, Dailey JC. Human bite marks in forensic dentistry. *Dental Clinics of North America* 2001; 45: 365-397