



NIH PUBLIC ACCESS

Author Manuscript

Anesthesiology. Author manuscript; available in PMC 2009 October 1.

Published in final edited form as:

Anesthesiology. 2008 October ; 109(4): 605–612. doi:10.1097/ALN.0b013e31818709fa.

Effect of Progressive Mandibular Advancement on Pharyngeal Airway Size in Anesthetized Adults

Samuel T. Kuna, M.D.[†], Lee C. Woodson, M.D.[‡], Daneshvari R. Solanki, M.D.[‡], Oliver Esch, M.D.^{*}, Donald E. Frantz, D.D.S.[§], and Mali Mathru, M.D.[±]

[†]Associate Professor of Medicine, Department of Medicine, University of Pennsylvania and Pulmonary, Critical Care and Sleep Section, Philadelphia Veterans Administration Medical Center, Philadelphia, Pennsylvania

[‡]Professor of Anesthesiology, Department of Anesthesiology, University of Texas Medical Branch, Galveston, Texas

^{*}Adjunct Associate Professor, The University of Texas School of Health Information Sciences at Houston, University Center Tower, Houston, Texas

[§]Owner, Frantz Design, Incorporated, Austin, Texas

[±]Professor of Anesthesiology, Department of Anesthesiology, University of Alabama School of Medicine, Birmingham, Alabama

Abstract

Background—General anesthesia in adult humans is associated with narrowing or complete closure of the pharyngeal airway. The purpose of this study was to determine the effect of progressive mandibular advancement on pharyngeal airway size in normal adults during intravenous infusion of propofol for anesthesia.

Methods—Magnetic resonance imaging was performed in 9 normal adults during wakefulness and propofol anesthesia. A commercially available intra-oral appliance was used to manually advance the mandible. Images were obtained during wakefulness without the appliance and during anesthesia with the participants wearing the appliance under three conditions: without mandibular advancement, advancement to 50% maximum voluntary advancement, and maximum advancement. Using computer software, airway area and maximum anteroposterior and lateral airway diameters were measured on the axial images at the level of the soft palate, uvula, tip of the epiglottis and base of the epiglottis.

Results—Airway area across all four airway levels decreased during anesthesia without mandibular advancement compared to airway area during wakefulness ($p < 0.007$). Across all levels, airway area at 50% advancement during anesthesia was less than that at centric occlusion during wakefulness ($p = 0.06$), but airway area with maximum advancement during anesthesia was similar to that in

Corresponding Author: Samuel T. Kuna, M.D., Department of Medicine, University of Pennsylvania and Pulmonary, Critical Care and Sleep Section, Philadelphia Veterans Administration Medical Center (111P), 3900 Woodland Ave., Philadelphia, PA 19104, Tel: 215-823-4400, Fax: 215-823-5876, E-mail: skuna@mail.med.upenn.edu.

Department/Institution to which the work is attributed: Departments of Medicine and Anesthesiology, University of Texas Medical Branch, Galveston, Texas

Summary Statement: Maximum mandibular advancement using an intraoral device is required to restore the decreased pharyngeal airway size in normal adults during propofol anesthesia to that during wakefulness.

Conflict of Interest: Donald Frantz is president of Frantz Design Inc., Austin, Texas, and has a financial interest in the EMA-T appliance. Dr. Frantz's role in the project was to assist in the study design and provide advice regarding the use of the EMA-T appliances used in the study. He also supplied the EMA-T appliances used in the study. He had no involvement with the data collection or analysis.

wakefulness ($p = 0.64$). In general, anteroposterior and lateral airway diameters during anesthesia without mandibular advancement were decreased compared to wakefulness and restored to their wakefulness values with 50% and/or maximal advancement.

Conclusions—Maximum mandibular advancement during propofol anesthesia is required to restore the pharyngeal airway to its size during wakefulness in normal adults.

Introduction

General anesthesia and intravenous sedation reduce pharyngeal airway size and increase collapsibility of pharyngeal airway.^{1–6} Under these conditions, jaw thrust maneuver or anterior displacement of the mandible is commonly employed to relieve the airway obstruction. Previous studies in anesthetized patients with and without obstructive sleep apnea have demonstrated that manual anterior displacement of the mandible dilates and stiffens the pharyngeal airway.^{3,4,7,8} However, due to the techniques employed, similar measures could not be obtained during wakefulness to compare with the results during anesthesia. The purpose of this study was to determine the effect of progressive mandibular advancement on the size of the pharyngeal airway in spontaneously breathing, normal adults during intravenous propofol anesthesia compared to measurements obtained at centric occlusion during wakefulness.

Magnetic resonance imaging (MRI) was performed during wakefulness and intravenous propofol anesthesia to document the effects of mandibular advancement on airway morphology. The subjects were fitted with a customized, manually adjustable oral mandibular advancement appliance to progressively advance the mandible. Our first hypothesis was that mandibular advancement would increase airway area at all levels of the pharyngeal airway and that airway area with maximum mandibular advancement during anesthesia would be the same as, or greater than that during wakefulness without mandibular advancement. Our second hypothesis was that the increase in airway area would be in both the anteroposterior and lateral direction.

Materials and Methods

The protocol was performed in 9 healthy, adult human volunteers (5 men and 4 women). Mean age was 25 ± 4 (SD) yr, mean height 172 ± 13 cm, and mean weight 67 ± 15 kg. Each subject provided written informed consent and the study was approved by the Institutional Review Board at the University of Texas Medical Branch, Galveston, Texas. The subjects had no medical problems, were not allergic to any medications, and were not taking any medications. The subjects denied any signs or symptoms suggestive of obstructive sleep apnea including daytime hypersomnolence, frequent awakenings from sleep, morning headaches, or being told by a bed partner or family member of snoring, gasping, or cessation of breathing during sleep. A commercially available oral mandibular advancement appliance (EMA-T, Frantz Design Inc., Austin, TX) was used to manually advance the mandible during anesthesia (fig. 1).⁹ The device is designed for universal application in adults and can be rapidly constructed using inexpensive materials. Just prior to starting the MRI scans, impressions of the maxillary and mandibular dental arches were made by placing a fast setting dental silicone putty material (Kerr Corp., Orange, CA) into one-size-fits-all maxillary and mandibular hard plastic trays (0.06" thickness) and pushing the trays onto the subject's teeth. Serrations in the trays secured the impression material in the trays. The position of the appliance's locking mechanism at centric occlusion and at maximum voluntary mandibular advancement were marked on the pull tab extending from the mandibular tray. The appliance was then removed. Following the MRI scan during wakefulness without the appliance, and just prior to administration of propofol anesthesia, a liquid, fast setting dental silicone (Kerr Corp.) was applied to the impressions

which were then placed on the maxillary and mandibular arches for the duration of the study. This silicone held the trays firmly on the subject's teeth and prevented dislodgement during imaging. The mandible was advanced manually by pulling forward the pull tab extending from the mandibular tray and inserting a midline peg attached to the anterior of the maxillary tray into one of the holes on the pull tab. The mandible was thereby held in an advanced position by the stationary maxilla.

The subjects lay supine on a sliding platform that could be moved in and out of the MRI scanner. An intravenous line was placed in an arm vein for infusion of Ringer's lactate. Throughout the experiments, the subjects breathed 4 L/min supplemental oxygen via nasal cannula and blood pressure, respiratory rate, pulse oximetry (Datex-Ohmeda Inc., Madison, WI), and end-tidal carbon dioxide at the nares were monitored. Oxygen saturation readings remained above 97% in all subjects. Just prior to MRI scanning, the subject's head was placed in the neutral position with the scanner's positioning light located at the sagittal midline of the head. The neutral position was chosen to standardize head position across subjects and conditions. Head position was stabilized with a circular pillow, and head movement was minimized by securing the forehead to the edges of the sliding table with an adhesive strap.

Anesthesia was induced by intravenous injection of propofol in increments of 50 mg until the eyelash reflex was lost or to a maximum dose of 300 mg. Airway obstruction was judged to be present if breathing became noisy, breathing pattern became irregular, or end-tidal carbon dioxide dropped below 4%. When one of these end points for airway obstruction became apparent, propofol administration was discontinued for the next 2 min. When respiration and vital signs were stable following induction, a continuous propofol infusion was started at a rate of $75 \mu\text{g}\cdot\text{kg}^{-1}\cdot\text{min}^{-1}$. Subjects were observed for at least 5 min at this continuous infusion rate before being returned into the scanner.

MRI scans of the upper airway were obtained in each subject under four consecutive conditions: wakefulness with the teeth in centric occlusion without the oral appliance, intravenous propofol anesthesia with the oral appliance but without mandibular advancement, intravenous propofol anesthesia with the appliance advancing the mandible to 50% of maximum voluntary advancement, and intravenous propofol anesthesia with the appliance maximally advancing the mandible. The 50% mandibular advancement was achieved by advancing the mandible to one half the distance between centric occlusion and maximum voluntary advancement. Maximum mandibular advancement during propofol anesthesia was performed by forcefully pulling the tab on the oral appliance to advance the mandible to its maximum extent which in some cases was greater than that achieved by the subjects during maximum voluntary advancement during wakefulness. The advancements of the mandible with the appliance were performed in all subjects by one investigator (DEF). During the scans obtained during wakefulness, the subjects were instructed to breathe normally with the mouth closed. During the scans obtained under propofol anesthesia with the appliance in place but without mandibular advancement, the mandibular strap was not locked to the maxillary tray. Therefore, under this condition, the mandible was not held in a fixed position.

Subjects were moved out of the scanner transiently to insert and adjust the appliance. Once their respiratory status and other vital signs were documented to be stable on the constant dose of anesthetic, they were moved back into the scanner for further imaging. At the end of MRI scanning, the propofol infusion was discontinued. Once the subjects were awake, the oral appliance was removed. The subjects were transferred to a stretcher and observed for at least one hour or until full recovery. They were escorted home by an adult companion and instructed not to drive a motor vehicle or operate machinery for another 24 hours.

Imaging of the upper airway was performed on a 1.5-T magnet, using an anterior surface coil (General Electric Medical Systems, Milwaukee, WI). T1-weighted images (repetition time 500 ms; echo time 25 ms) were obtained in all three planes with a slice thickness of 5 mm or less (sagittal and axial: 5 mm/no skip; coronal: 3 mm/no skip) and a matrix of 256×192 ; total acquisition time for each of the four conditions was 7 min. No attempt was made to obtain images at a fixed time in the respiratory cycle.

Axial images obtained during the four conditions in each of the 9 subjects were analyzed using computer software. Measurements of airway area and maximum anteroposterior and lateral airway dimensions were made at the levels of the body of the soft palate, tip of the uvula, tip of the epiglottis and base of the epiglottis. These levels were chosen to match those used in a previous pharyngeal imaging study.¹⁰ The body of the soft palate level was half the rostral to caudal distance between the level of the hard palate and the tip of the uvula. The position of the genu of the mandible and hyoid bone on the midline sagittal MRI scan in each condition was measured as the distance from each of these structures to the anterior surface of the vertebral column in a plane parallel to that of the hard palate.

Statistical Analysis

Mixed model analyses of variance for repeated measures were used to test hypotheses of interest and to construct linear contrasts that compared mean values of primary and supporting outcomes observed under experimental conditions during anesthesia (no mandibular advancement, 50% mandibular advancement, and maximum mandibular advancement) to outcomes observed during wakefulness. Three measures reflecting the size of the airway (airway area, anterior-posterior airway diameter and lateral airway diameter) were considered the primary outcomes and were the dependent variables in the models using mixed model analysis of variance. These models included fixed effects for anatomical location, experimental condition, and location by treatment interaction. Subject was included as a random effect to account for biological variability among subjects. The primary null hypothesis defined to control experiment-wise Type I error was that there were no significant differences in mean airway area, mean anteroposterior diameter, and mean lateral diameter among the experimental conditions (i.e., wakefulness versus the 3 conditions during anesthesia). Adjusted mean values were determined through main effects in a mixed model analysis of variance that included repeated measures over the four anatomical levels (in descending order: soft palate, uvula, tip of the epiglottis, and base of the epiglottis). The three components of the primary null hypothesis were each tested using a Bonferroni corrected Type I error rate of $0.05/3 = 0.017$ in order to account for multiple primary endpoints.

After rejecting the primary null hypothesis, the analysis focused on the magnitude of the differences in airway size observed under anesthesia with no mandibular advancement, anesthesia with 50% advancement, and anesthesia with maximum advancement, each compared to the 'control' condition of wakefulness. Standard errors were determined for each least squares estimated linear contrast of interest as well as contrast specific significance levels in order to assess the degree to which differences relative to wakefulness were or were not larger than could reasonably be attributed to chance alone. In addition to main effects, supporting analyses were performed that compared the airway area measures during anesthesia relative to wakefulness separately at each of the four anatomical levels. For these analyses, statistical significance of the anatomical level by experimental condition interaction was determined as well as anatomical level specific linear contrasts and standard errors. Analogous analyses were performed for vertebral distances of the genu of the mandible and hyoid bone. These variables are hypothesized to mediate the associations between mandibular advancement and airway size and therefore were not considered outcome variables per se.

The normal distribution assumptions of the mixed model analysis of variance were assessed by examining histograms of paired differences of mean airway size variables (over anatomical levels) and by comparing non-parametric significance levels (using Wilcoxon signed-rank tests) to significance levels of linear contrasts determined using the parametric model. Similarity between parametric and non-parametric significance levels was taken as evidence that results were not overly sensitive to the normal assumptions. All mixed model results were obtained using the SAS procedure Proc Mixed (SAS Institute Inc., Cary, NC). The percent change in airway variables from wakefulness to each of the 3 conditions during anesthesia was calculated as the adjusted mean change from wakefulness divided by the unadjusted mean during wakefulness, pooled over subjects and anatomic levels.

Results

Transient upper airway occlusion occurred immediately following intravenous induction with propofol in 5 of the 9 subjects. In these subjects, the airway was opened by using the oral appliance to advance the mandible to 50% or maximum advancement. Once the subjects were on a maintenance dose of intravenous propofol, the appliance was unlocked so the mandible could return to its resting position. In two of the subjects (one male and one female), pharyngeal airway closure without mandibular advancement persisted even while on a maintenance dose of propofol, and the MRI scans during propofol anesthesia without advancement could not be obtained. However, advancement of the mandible with the oral appliance reestablished airway patency and the scans at 50% and maximum advancement were successfully obtained. Even in retrospect, it was not possible to determine why the response of these two subjects was different from the other subjects. The mean voluntary mandibular advancement from centric occlusion in all subjects was 15 ± 4 (SD) mm. The mean 50% mandibular advancement during propofol anesthesia from centric occlusion was 7.7 ± 2.0 mm and the maximum mandibular advancement was 16.8 ± 3.2 mm.

A midline sagittal image of the pharyngeal airway with and without maximum mandibular advancement during propofol anesthesia in one of the subjects is shown in figure 2. The pharyngeal airway measurements during wakefulness and propofol anesthesia with and without mandibular advancement are provided in table 1. Table 2 provides a summary of preliminary mixed model analysis of variance that allowed for anatomical level by experimental condition interaction. There was no evidence that differences in airway area among conditions (wakefulness versus the three levels of mandibular advancement during anesthesia: no advancement, 50% advancement, and maximum advancement) varied by anatomical level [$F(9,90)=0.7$, $p=0.74$]. In contrast, for both anteroposterior airway diameter [$F(9,90)=2.0$, $p=0.05$] and lateral airway diameter [$F(9,90)=2.0$, $p=0.05$], there was consistent evidence that anesthesia caused greater diameter reduction at the levels of the uvula and tip of the epiglottis compared to the reductions at the levels of the soft palate and base of the epiglottis. The estimated differences in lateral airway diameter between the maximum advancement and wakefulness conditions were positive at all levels, with the largest increase at the level of the soft palate. At the soft palate location, the adjusted mean difference in lateral airway diameter relative to wakefulness changed from -0.6 ± 2.5 (SE) mm during anesthesia without mandibular advancement to 4.3 ± 2.4 mm during anesthesia with maximum advancement. Generally speaking, location by condition interaction was quantitative (differences were in the same direction but varied in magnitude) and not qualitative permitting interpretation of the *a priori* defined primary main effects across experimental conditions.

Table 3 provides a summary of the least squares estimated mean differences between each experimental condition relative to wakefulness from the primary mixed model analysis of variance after eliminating the interaction effects. These estimates reflect the total (or alternatively, the average) differences between experimental conditions across anatomical

levels and provide a more parsimonious and easier to interpret summary of the main findings from this study. Overall, the main effects of experimental condition on (mean) airway area [$F(3,30)=5.1, p=0.006$], anteroposterior airway diameter [$F(3,30)=5.5, p=0.005$], and lateral airway diameter [$F(3,30)=4.1, p=0.015$] were all significant based on the Bonferroni multiplicity adjusted criterion of $\alpha=0.017$.

Anesthesia without mandibular advancement reduced airway area relative to that in wakefulness by 93.3 ± 31.9 (SE) mm^2 ($p=0.007$). During anesthesia with 50% mandibular advancement, the mean reduction in airway area relative to that in wakefulness was 58.3 ± 29.9 mm^2 ($p=0.06$). Compared to its size during wakefulness, airway area was reduced 43% during anesthesia without advancement and 27% during anesthesia with 50% advancement. In contrast, airway area was increased by 6% during anesthesia with maximum mandibular advancement compared to wakefulness (estimated mean difference = 13.9 ± 29.9 mm^2) but this difference was not significant ($p=0.64$).

Similarly, anteroposterior airway diameter was reduced during anesthesia without mandibular advancement relative to that in wakefulness by 4.3 ± 1.2 (SE) mm ($p=0.001$). The mean reduction in anteroposterior airway diameter during anesthesia with 50% mandibular advancement relative to that in wakefulness was 2.9 ± 1.1 mm and this difference remained significant ($p=0.01$). Similar results were observed for lateral airway diameter. During anesthesia with no advancement, anteroposterior and lateral diameter were reduced, relative to their values in wakefulness, by 38% and 15% respectively. With 50% advancement during anesthesia, anteroposterior and lateral diameter were reduced, relative to their values in wakefulness, by 26% and 10% respectively. Although anteroposterior diameter during anesthesia with maximum mandibular advancement was reduced by 10% compared to its value during wakefulness (estimated mean difference = 1.1 ± 1.1 mm), the difference was not significant ($p=0.32$). As with airway area, estimated mean lateral airway diameter during anesthesia with maximum mandibular advancement was increased by 6% compared to that in wakefulness but was not significant ($p=0.33$).

To further understand the mechanism through which maximum mandibular advancement obliterates anesthesia related reductions in airway size, nominal paired t-tests were used to compare the distances of the genu of the mandible and hyoid bone from the vertebral spine and the hard palate during the three anesthesia conditions to their respective values in wakefulness (table 4). Compared to results during wakefulness, the distance of the genu of the mandible from the vertebral spine during anesthesia was significantly reduced without mandibular advancement ($p=0.05$) and significantly increased with maximum advancement ($p=0.04$). Although the mean distance of the hyoid from the vertebral spine was reduced during anesthesia without advancement compared to wakefulness, these differences were not significant ($p=0.13$). Nonetheless, with 50% mandibular advancement, the reduction in vertebral distance relative to wakefulness was reduced by 77% for genu but only 46% for the hyoid bone and, with maximum mandibular advancement, the mean distance of the hyoid from the vertebral spine was similar in magnitude to that during wakefulness. Finally, there were no significant differences between the three anesthesia conditions and wakefulness for distance of either the genu of the mandible or hyoid bone from the hard palate.

Discussion

The results indicate that propofol anesthesia in normal adults decreases pharyngeal airway size over the entire rostral-caudal extent of the pharynx and that maximum advancement of the mandible during propofol anesthesia is required to restore pharyngeal airway size to that during wakefulness. Compared to images in wakefulness, the decrease in airway area with propofol anesthesia without mandibular advancement was accompanied by decreases in both

anteroposterior and lateral airway diameters. In general, maximal advancement of the mandible during propofol anesthesia returned anteroposterior and lateral airway diameters to their respective values in wakefulness. Referencing the position of the genu of the mandible and the hyoid bone to the spine on the midline sagittal scan, anesthesia without advancement was associated with a retraction of the mandible that may have contributed to the reduction in airway size.

Previous studies report that mandibular advancement increases pharyngeal airway size and decreases pharyngeal airway collapsibility in sedated and anesthetized adult humans.^{3,4,6-8} Isono et al.⁷ performed fiberoptic imaging of the pharyngeal airway over a range of applied airway pressures in anesthetized, paralyzed patients with obstructive sleep apnea with and without manual, maximal mandibular advancement. The resulting pressure-area relationships for both the retropalatal and retroglossal segments of the oropharyngeal airway revealed that mandibular advancement reduced the pressure at which the airway closed and increased airway area at any intraluminal pressure. A subsequent study by these investigators compared the responses in non-obese and obese individuals and found that mandibular advancement increased both retropalatal and retroglossal airway area in their non-obese (body mass index $21.1 \pm 2.0 \text{ kg/m}^2$) participants but did not change retropalatal airway area in the obese subjects (body mass index $31.3 \pm 2.5 \text{ kg/m}^2$).⁸ Our results suggest that we might have found different results in our current study if we had studied obese subjects. Kato et al.⁴ further extended these findings by showing that progressive mandibular advancement using a custom fitted oral appliance caused a dose-dependent reduction in the airway pressure required to close the retropalatal and retroglossal oropharynx. Supporting the studies of Isono and his colleagues, Inazawa et al.³ reported that mandibular advancement stiffens the pharyngeal airway, as indicated by a decrease in critical airway pressure, in normal adult humans during moderate sedation with midazolam. The authors concluded that upper airway collapsibility during moderate sedation decreases with increasing mandibular advancement and, in contrast to the current findings, suggest that maximal mandibular advancement may not be necessary for the preservation of upper airway patency.

The precise mechanism by which advancement of the mandible improves pharyngeal patency is unclear. Previous studies suggest that mandibular advancement generates tension on the suprahyoid muscles resulting in anterior displacement of the hyoid apparatus. Mandibular advancement would thereby enlarge the pharyngeal airway by anterior displacement of the hyoid bone and its muscular attachments and lifting the epiglottis away from the posterior pharyngeal wall, reversing the narrowing of the laryngeal inlet.¹¹⁻¹⁴ The results of the current and previous studies, however, suggest that the mechanism of action is more complex than simply an action on the hyoid apparatus since this cannot easily explain the enlargement of the retropalatal pharyngeal airway with mandibular advancement or the lateral widening of the airway reported in the current and previous studies. Advancement of the mandible may impose traction on the anterior and posterior tonsillar pillars pulling the soft palate into the oral cavity and opening the retropalatal airway. Furthermore, mandibular advancement may lead to an unfolding of soft tissue structures leading to the lateral widening of the airway.

Our study was performed with the subject's head in a neutral position in order to standardize head and neck position across conditions and subjects. It is possible that different results would have been obtained with the neck in flexion and upper cervical extension, the sniffing position recommended for induction of general anesthesia and mask ventilation.¹⁵ Isono et al.¹⁶ found increased maximum pharyngeal airway area and decreased pharyngeal closing pressure, i.e., a stiffer airway, with the neck in the sniffing position compared to a head neutral position during propofol anesthesia in 12 paralyzed patients with obstructive sleep apnea. Head and neck position can also influence the effect of anesthesia on the position of the hyoid bone. Comparing hyoid position during general anesthesia in paralyzed adults to that in wakefulness,

Sivarajan and colleagues report no change in hyoid position with the head in a neutral or flexed position but anterior hyoid displacement with head in extension.^{17,18} In contrast, with the head in a neutral position, our study found no change in hyoid position during anesthesia without mandibular advancement compared to wakefulness but posterior movement of the genu of the mandible. Retraction of the mandible may have contributed to the reduced airway size observed during anesthesia without mandibular advancement. Changes in the position of the genu of the mandible relative to that of the hyoid bone during anesthesia may alter the mechanical characteristics of the hyoid apparatus thereby changing the effect of mandibular advancement on pharyngeal airway size.

In addition to head and neck position, the selection of propofol for anesthesia and the depth of anesthesia could possibly have influenced the results. Evidence that similar results would have been obtained with other anesthetics is provided by Norton et al.¹⁹ who found that propofol and midazolam, at equivalent levels of sedation, have similar but variable propensities for upper airway obstruction across subjects. Crawford and colleagues report a progressive decrease in pharyngeal airway caliber with increasing depth of propofol anesthesia in infants and sevoflurane anesthesia in children.^{20,21} Eastwood et al.²² report that increasing depth of propofol anesthesia is associated with increased collapsibility of the upper airway as measured by critical airway pressure. However, the increase in critical airway pressure found by these latter investigators, from 0.3 ± 3.5 cm H₂O at the lowest propofol concentration used to 1.4 ± 3.5 cm H₂O at the highest concentration, although statistically significant, may not be clinically significant.²³ In the current study, we did not assess depth of anesthesia by measuring blood propofol concentration or using clinical measures other than absence of eye lash reflex. However, we believe that the depth of anesthesia was relatively uniform across our subjects since all received the same continuous infusion dose ($75 \mu\text{g}\cdot\text{kg}^{-1}\cdot\text{min}^{-1}$) of this rapidly acting anesthetic.

Unlike many previous studies, our subjects were young normal adults. Different results might have been obtained in obese subjects with sleep apnea who are known to be at increased risk of difficult mask ventilation.²⁴ In addition, our subjects were not paralyzed during propofol anesthesia. Pharyngeal muscle activity plays an important role in maintenance of airway patency. Even though our subjects were not paralyzed, it is known that general anesthesia suppresses motor output to upper airway muscles.²⁵⁻²⁸ The resulting greater compliance of pharyngeal soft tissues, i.e., the muscles surrounding the airway and those attached to the hyoid arch, may explain the failure of maximal mandibular advancement to increase airway size during propofol anesthesia beyond that in wakefulness. However, Eastwood et al.²² demonstrated continued tonic and phasic inspiratory genioglossus activity in adults during propofol anesthesia. Their findings suggest that some pharyngeal muscle activity may still have been present in our anesthetized, non-paralyzed subjects.

Our findings may have relevance in the clinical practice of anesthesia. Manual manipulation of head and jaw position is commonly performed to restore pharyngeal airway patency in anesthetized or deeply sedated, non-intubated patients.^{1,15} The custom made oral appliance described here is not equivalent to the manual technique used to maintain airway patency during general anesthesia, which includes more than mandibular advancement. However, the ability of the oral appliance to restore the pharyngeal airway during the anesthetized state to its size during wakefulness raises the possibility of its potential role in clinical practice. Use of this device in spontaneously breathing patients during anesthesia or deep sedation might allow the anesthesiologist to have “free hands” to attend to other tasks. Furthermore, given the increasing use of agents such as propofol during invasive procedures outside the operating room without an anesthesiologist in attendance, the quickly constructed oral appliance described here might be a particularly useful method to maintain pharyngeal patency. However, the oral appliance

might increase the risk of regurgitation and aspiration and make it more difficult to access and intubate the airway in these situations.

In summary, this MRI study reveals that pharyngeal airway narrowing occurs in normal, spontaneously breathing adult subjects during propofol anesthesia. Mandibular advancement with an adjustable intra-oral device increases airway size when the mandible was advanced from centric occlusion to 50% of its maximum voluntary advancement, however, airway area at this advancement was still decreased compared to that in wakefulness. Airway area during anesthesia was restored to that in wakefulness with maximum mandibular advancement. The increase in airway area was due to enlargement in the lateral and anteroposterior dimensions. The role of such an oral appliance in upper airway management during conscious sedation, monitored anesthesia care, and general anesthesia with mask ventilation needs further evaluation before clinical application.

Acknowledgements

Greg Maislin and Laura Venditti (Consultants, Biomedical Statistical Consulting, Wynnewood, Pennsylvania) performed the statistical analyses

Financial Support: This work was supported by funds from the National Institutes of Health, Bethesda, Maryland (NIH HL-61272)

References

1. Safar P, Escarraga LA, Chang F. Upper airway obstruction in the unconscious patient. *J Appl Physiol* 1959;14:760–764. [PubMed: 14440737]
2. Eastwood PR, Szollosi I, Platt PR, Hillman DR. Collapsibility of the upper airway during anesthesia with isoflurane. *Anesthesiology* 2002;97:786–793. [PubMed: 12357141]
3. Inazawa T, Ayuse T, Kurata S, Okayasu I, Sakamoto E, Oi K, Schneider H, Schwartz AR. Effect of mandibular position on upper airway collapsibility and resistance. *J Dent Res* 2005;84:554–558. [PubMed: 15914594]
4. Kato J, Isono S, Tanaka A, Watanabe T, Araki D, Tanzawa H, Nishino T. Dose-dependent effects of mandibular advancement on pharyngeal mechanics and nocturnal oxygenation in patients with sleep-disordered breathing. *Chest* 2000;117:1065–1072. [PubMed: 10767241]
5. Litman RS, Hayes JL, Basco MG, Schwartz AR, Bailey PL, Ward DS. Use of dynamic negative airway pressure (DNAP) to assess sedative-induced upper airway obstruction. *Anesthesiology* 2002;96:342–345. [PubMed: 11818766]
6. Mathru M, Esch O, Lang J, Herbert ME, Chaljub G, Goodacre B, vanSonnenberg E. Magnetic resonance imaging of the upper airway; Effects of propofol anesthesia and nasal continuous positive airway pressure in humans. *Anesthesiology* 1996;84:273–279. [PubMed: 8602656]
7. Isono S, Tanaka A, Sho Y, Konno A, Nishino T. Advancement of the mandible improves velopharyngeal airway patency. *J Appl Physiol* 1995;79:2132–2138. [PubMed: 8847283]
8. Isono S, Tanaka A, Tagaito Y, Sho Y, Nishino T. Pharyngeal patency in response to advancement of the mandible in obese anesthetized persons. *Anesthesiology* 1997;87:1055–1062. [PubMed: 9366456]
9. Kuna ST, Giarraputo PC, Stanton DC, Levin LM, Frantz D. Evaluation of an oral 22 mandibular advancement titration appliance. *Oral Surg Oral Med Oral Pathol Oral Radiol Endod* 2006;101:593–603. [PubMed: 16632270]
10. Kuna ST, Bedi DG, Ryckman C. Effect of nasal airway positive pressure on upper airway size and configuration. *Am Rev Respir Dis* 1988;138:969–975. [PubMed: 3059886]
11. Murashima K, Fukutome T. Effect of jaw-thrust manoeuvre on the laryngeal inlet. *Anaesthesia* 1998;53:203–204. [PubMed: 9534652]
12. Nandi PR, Charlesworth CH, Taylor SJ, Ninn JF, Dore CJ. Effect of general anesthesia on the pharynx. *Br J Anaesth* 1991;66:157–162. [PubMed: 1817614]

13. Reber A, Paganoni R, Frei FJ. Effect of common airway manoeuvres on upper airway dimensions and clinical signs in anaesthetized, spontaneously breathing children. *Br J Anaesth* 2001;86:217–222. [PubMed: 11573663]
14. Reed WR, Roberts JL, Thach BT. Factors influencing regional patency and configuration of the human infant upper airway. *J Appl Physiol* 1985;58:635–644. [PubMed: 3980366]
15. Morikawa S, Safar P, De Carlo J. Influence of headjaw position upon upper airway patency. *Anesthesiology* 1961;22:265–270. [PubMed: 13772661]
16. Isono S, Tanaka A, Ishikawa T, Tagaito Y, Nishino T. Sniffing position improves pharyngeal airway patency in anesthetized patients with obstructive sleep apnea. *Anesthesiology* 2005;103:489–494. [PubMed: 16129972]
17. Sivarajan M, Joy JV. Effects of general anesthesia and paralysis on upper airway changes due to head position in humans. *Anesthesiology* 1996;85:787–793. [PubMed: 8873549]
18. Sivarajan M, Fink BR. The position and the state of the larynx during general anesthesia and muscle paralysis. *Anesthesiology* 1990;72:439–442. [PubMed: 2310023]
19. Norton JR, Ward DS, Karan S, Voter WA, Palmer L, Varlese A, Rackovsky O, Bailey P. Differences between midazolam and propofol sedation on upper airway collapsibility using dynamic negative airway pressure. *Anesthesiology* 2006;104:1155–1164. [PubMed: 16732085]
20. Crawford MW, Arrica M, Macgowan CK, Yoo SJ. Extent and localization of changes in upper airway caliber with varying concentrations of sevoflurane in children. *Anesthesiology* 2006;105:1147–1152. [PubMed: 17122577]
21. Crawford MW, Rohan D, Macgowan CK, Yoo SJ, Macpherson BA. Effect of propofol anesthesia and continuous positive airway pressure on upper airway size and configuration in infants. *Anesthesiology* 2006;105:45–50. [PubMed: 16809993]
22. Eastwood PR, Platt PR, Shepard K, Maddison K, Hillman DR. Collapsibility of the upper airway at different concentrations of propofol anesthesia. *Anesthesiology* 2005;103:470–477. [PubMed: 16129969]
23. Litman RS. Upper airway collapsibility: an emerging paradigm for measuring the safety of anesthetic and sedative agents. *Anesthesiology* 2005;103:453–454. [PubMed: 16129966]
24. Kheterpal S, Han R, Tremper KK, Shanks A, Tait AR, O'Reilly M, Ludwig TA. Incidence and predictors of difficult and impossible mask ventilation. *Anesthesiology* 2006;105:885–891. [PubMed: 17065880]
25. Drummond GB. Influence of thiopentone on upper airway muscles. *Br J Anaesth* 1989;63:12–21. [PubMed: 2765337]
26. Hwang JC St, John WM, Bartlett D. Respiratory-related hypoglossal nerve activity: influence of anaesthetics. *J Appl Physiol* 1983;55:785–792. [PubMed: 6629915]
27. Nishino T, Shirahata M, Yonezawa T, Honda Y. Comparison of changes in the hypoglossal and phrenic nerve activity in response to increasing depth of anesthesia in cats. *Anesthesiology* 1984;60:19–24. [PubMed: 6691591]
28. Ochiai R, Guthrie RD, Motoyama EK. Effects of varying concentrations of halothane on the activity of the genioglossus, intercostals and diaphragm in cats: An electromyographic study. *Anesthesiology* 1989;70:812–816. [PubMed: 2719316]



Fig. 1. Diagram of the intraoral device (EMA-T) used to advance the mandible
The appliance consists of plastic trays for the upper and lower dental arches. A custom-fitted appliance was constructed for each participant by placing fast-setting dental impression materials in the troughs of the trays. When the appliance was in place, the mandible was manually advanced by securing a peg in the projection from the upper tray into one of the holes in the projection from the lower tray.

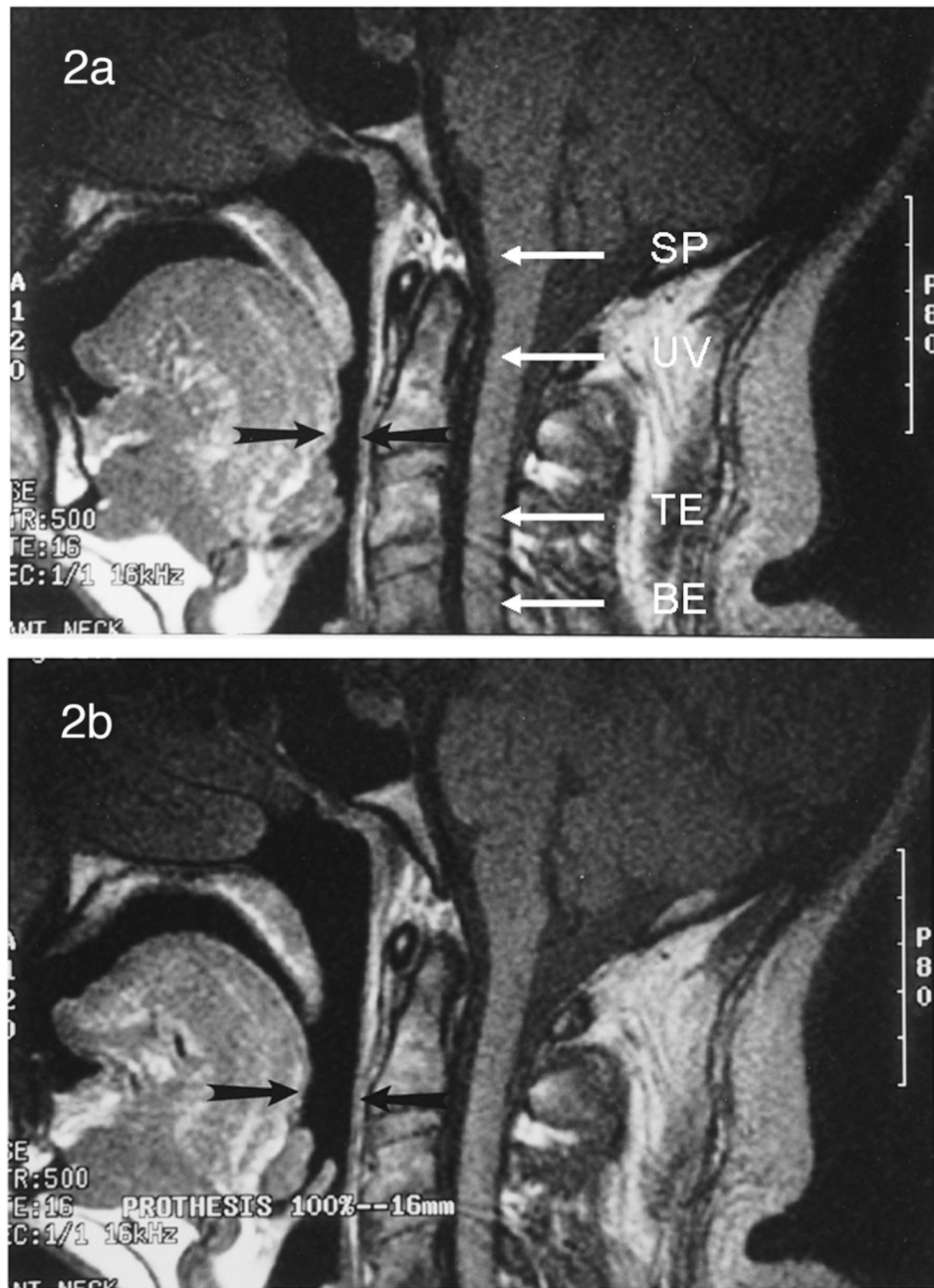


Fig. 2. Midline sagittal MRI of the pharyngeal airway in one subject during propofol anesthesia without (A) and with maximum (B) mandibular advancement

Panel A indicates the location of the four pharyngeal levels examined on the axial images: soft palate (SP), uvula (UV), tip of epiglottis (TE), and base of epiglottis (BE). Note the increase in pharyngeal airway size at all 4 pharyngeal levels with maximum advancement.

Table 1

Mean \pm SD of Pharyngeal Airway Measurements during Wakefulness and Propofol Anesthesia with and without Mandibular Advancement

	Awake	Anesthesia No Advancement*	Anesthesia 50% advancement	Anesthesia Max advancement
Airway Area (mm²)				
Soft Palate	193.1 \pm 76.4	141.9 \pm 71.9	164.1 \pm 84.9	223.9 \pm 103.2
Uvula	185.3 \pm 60.1	64.0 \pm 44.5	106.3 \pm 74.5	193.9 \pm 98.6
Tip of Epiglottis	203.8 \pm 88.6	76.0 \pm 40.6	119.9 \pm 63.0	212.9 \pm 107.9
Base of Epiglottis	292.4 \pm 103.4	219.6 \pm 47.1	251.1 \pm 85.4	299.8 \pm 104.0
Lateral Diameter (mm)				
Soft Palate	21.0 \pm 3.1	20.4 \pm 3.2	21.1 \pm 5.7	25.3 \pm 5.4
Uvula	20.1 \pm 3.6	13.9 \pm 7.0	15.2 \pm 4.5	21.6 \pm 5.6
Tip of Epiglottis	25.2 \pm 4.7	18.0 \pm 8.7	19.1 \pm 5.3	25.4 \pm 4.2
Base of Epiglottis	32.6 \pm 3.7	32.3 \pm 3.7	33.6 \pm 3.4	32.8 \pm 5.8
Anteroposterior Diameter (mm)				
Soft Palate	10.0 \pm 2.9	7.9 \pm 3.1	8.4 \pm 2.6	9.6 \pm 3.0
Uvula	11.8 \pm 4.7	5.1 \pm 2.3	7.9 \pm 2.3	11.0 \pm 3.7
Tip of Epiglottis	11.6 \pm 4.4	5.4 \pm 2.8	7.3 \pm 2.3	9.3 \pm 2.8
Base of Epiglottis	11.9 \pm 3.1	9.6 \pm 1.9	9.9 \pm 2.2	10.9 \pm 2.2

* n = 7; data for other 3 conditions from 9 individuals

Table 2

Summary of Mixed Model¹ Results Allowing for Anatomic Level by Experimental Condition Interaction

Variable	Location/Level	Anesthesia No Advancement vs. Awake		Anesthesia 50% Advancement vs. Awake		Anesthesia Max Advancement vs. Awake		Location by Treatment Interaction ²	p-value
		Est. Diff. LS Means	(SE)	Est. Diff. LS Means	(SE)	Est. Diff. LS Means	(SE)		
Airway Area	Soft Palate	-51.3	41.8	-29.0	39.1	30.8	39.1	0.74	
	Uvula	-121.3	41.8	-79.0	39.1	8.6	39.1		
	Tip of the Epiglottis	-127.8	41.8	-83.9	39.1	9.1	39.1		
AP Diameter	Base of the Epiglottis	-72.9	41.8	-41.3	39.1	7.3	39.1	0.05	
	Soft Palate	-2.1	1.5	-1.6	1.4	-0.4	1.4		
	Uvula	-6.6	1.5	-3.9	1.4	-0.8	1.4		
LAT Diameter	Tip of the Epiglottis	-6.1	1.5	-4.2	1.4	-2.2	1.4	0.05	
	Base of the Epiglottis	-2.3	1.5	-2.0	1.4	-1.0	1.4		
	Soft Palate	-0.6	2.5	0.1	2.4	4.3	2.4		
Lateral Airway Area	Uvula	-6.3	2.5	-4.9	2.4	1.4	2.4	0.05	
	Tip of the Epiglottis	-7.2	2.5	-6.1	2.4	0.2	2.4		
	Base of the Epiglottis	-0.3	2.5	1.0	2.4	0.2	2.4		

¹ Notes: The mixed model analysis of variance included fixed effects for anatomic location, experimental treatment, and location by treatment interaction. Subject was included as a random effect to account for biological variability among subjects.

² Results for interaction tests were F(9,90)=0.7, p=0.74; F(9,90)=2.0, and p=0.05; F(9,90)=2.0, p=0.05 for airway area, anteroposterior (AP) airway diameter, and lateral (LAT) airway diameter, respectively. Est. Diff LS Means = estimated difference of least square means

Table 3
 Summary of Least Squares Estimates of Differences Relative to Wakefulness from Main Effects Mixed Model Analysis of Variance
 (averaging over anatomic levels)¹

Condition => Variable	Anesthesia No Advancement vs. Awake		Anesthesia 50% Advancement vs. Awake		Anesthesia Max Advancement vs. Awake	
	Est. Diff. LS Means	(SE)	Est. Diff. LS Means	(SE)	Est. Diff. LS Means	(SE)
Airway Area (mm ²)	-93.3	31.9	-58.3	29.9	13.9	29.9
AP Diameter (mm)	-4.3	1.2	-2.9	1.1	-1.1	1.1
LAT Diameter (mm)	-3.6	1.7	-2.5	1.6	1.6	1.6

¹Notes: Overall differences among conditions were significant for airway area [F(3,30)=5.1, p=0.006], anteroposterior (AP) diameter [F(3,30)=5.5, p=0.004], and lateral (LAT) diameter [F(3,30)=4.1, p=0.015], respectively.

² p-values reflect statistical significance of linear contrasts relative to wakefulness.

Est. Diff. LS Means = least squares estimated mean differences

Table 4
 Distance of Genu of Mandible and Hyoid Bone from the Vertebral Bodies and Hard Palate on Midline Sagittal MRI

	Awake	Anesthesia No Advancement	Anesthesia 50% Advancement	Anesthesia Max Advancement
Distance to Vertebral Bodies (mm)				
Genu of Mandible	66.3 ± 8.9	60.9 ± 8.5*	65.0 ± 9.8	70.9 ± 9.5*
Hyoid Bone	35.9 ± 7.2	30.6 ± 5.9	33.0 ± 4.9	35.7 ± 4.8
Distance to Hard Palate (mm)				
Genu of Mandible	67.6 ± 6.0	67.0 ± 7.8	67.8 ± 5.8	68.9 ± 6.1
Hyoid Bone	71.9 ± 6.7	74.7 ± 8.9	71.8 ± 6.0	73.4 ± 4.4

Data are mean ± SD; MRI = magnetic resonance imaging.

* paired t-test versus awake $p \leq 0.05$