



The University of  
**Nottingham**

UNITED KINGDOM · CHINA · MALAYSIA

Ghoz, Noha (2020) Ocular neovascularization. PhD thesis, University of Nottingham.

**Access from the University of Nottingham repository:**

<http://eprints.nottingham.ac.uk/60563/1/Thesis.pdf>

**Copyright and reuse:**

The Nottingham ePrints service makes this work by researchers of the University of Nottingham available open access under the following conditions.

This article is made available under the University of Nottingham End User licence and may be reused according to the conditions of the licence. For more details see: [http://eprints.nottingham.ac.uk/end\\_user\\_agreement.pdf](http://eprints.nottingham.ac.uk/end_user_agreement.pdf)

For more information, please contact [eprints@nottingham.ac.uk](mailto:eprints@nottingham.ac.uk)



**University of  
Nottingham**  
UK | CHINA | MALAYSIA

**Ocular neovascularization:  
Pathological changes in cornea, conjunctiva and retina**

**Noha Mohamed Ghaz M.B,Ch.B, MSc**

Thesis submitted to the University of Nottingham for the degree of doctor of Philosophy (Phd)

August 2019

Ophthalmology, Division of Clinical Neuroscience, School of Medicine

**Supervisors**

Professor Harminder S Dua

Mr. Winfried MK Amoaku

وَقُلِّبْ رِزْقِي عِلْمًا

“Allah, advance me in knowledge”

The Holy Quran

## ACKNOWLEDGMENT

Undertaking this PhD has been a truly life changing experience for me and it is my pleasure to acknowledge the roles of all those people who helped and guided me for completion of my journey.

First of all, I would like to acknowledge my supervisors, Professor Harminder S Dua and Mr. Winfried M Amoaku. I was very privileged to work under their supervision. I greatly appreciate their skillful guidance, innovative ideas and patience. Professor Dua created a research environment that stimulated original thinking and initiative. His clinical and scientific knowledge were invaluable to my PhD work. Mr. Amoaku always motivated me and was very helpful with his extensive knowledge. His continuous support and guidance were essential to complete my work. I must also thank Emily Hodgins for her great guidance with the imaging process and Mr. Tahseen for his invaluable statistical input in my studies. I would also like to acknowledge the valuable input of my dear friend and colleague Mrs Dalia Said for her contribution with her knowledge, immense support and precious advice. I would like to express my gratitude to my colleagues: Andrew Ross, Mouhamed Al-Aqaba and Imran Mohammed. It was a great pleasure working with them and I appreciate their help, advice, ideas and good humor.

My deepest appreciation goes to my husband Mohamed for his love and continuous support through this long journey and my two beautiful children; Alia and Ali whose presence always motivated me to continue this journey.

Finally, but by no means least, thanks go to my two lifelines; mum and dad for their unbelievable love, moral support and encouragement. They are the most important people in my world and I dedicate this thesis to them.

# Abstract

This thesis is about neovascularization in the eye including neovascularization on the ocular surface and the retina. The pathogenesis of the neovascularization is similar in different tissues of the eye. Ischaemia of tissues results in production of vascular endothelial growth factor (VEGF) which in turn leads to growth of abnormal neovessels which can lead to complications by leakage or bleeding.

Chapter one discusses in details the anatomy of the ocular surface and retina and the pathogenesis of neovascularization as well as the mediators involved in the complex process of neovascularization.

Chapter two discusses a clinical trial that studies the effect of combined Anti-VEGF injection (Avastin) and Anti-fibrosis injection (5 Fluorouracil) on pterygium. Pterygium is a condition that affects the conjunctiva due to degenerative changes and can affect vision by causing astigmatism and blocking the visual axis. Pterygium has both vascular and fibrous elements and hence the idea of injecting it with 2 agents. It was found via previous studies that the release of several mediators is responsible for the formation and growth of pterygium. Of these mediators, VEGF is the main inducer of the vascular component of the pterygium and its receptors are blocked by Avastin while the fibrotic component is blocked by 5 fluorouracil (5 FU) injections. Pterygium is mainly treated by surgical excision with the draw back of recurrence. Several studies were conducted and investigated the use of Avastin and 5FU separately but never combined. This clinical trial was designed to evaluate the effect of combined injections of 5FU and bevaciazumab in patients presenting with pterygium. This approach resulted in reduction in the clinical grade, thickness and vascularity of the pterygium. This two pronged approach addressing both the main pathological processes may work synergistically affecting thickness and vascularity of the pterygium. This medical approach will also reduce the need for surgery in many patients in whom injections alone might be an option to stop the progression of pterygium.

Chapter three is an observational study to observe the healing of grafts in patients who underwent surgical excision of pterygium and had autologous conjunctival grafts to cover the defect. The healing of the donor site was also observed. Such an observational study monitoring the graft and donor site was never carried out before. The results were very

interesting as it was found that the graft showed signs of reperfusion injury during the early stages of healing, a phenomenon which also occurs in organs like kidneys during renal transplantation surgery. Reperfusion injury happens due to sudden ischaemia caused by severed blood supply but is essential as it induces healing to start in the tissue which in this study was the autoconjunctival graft. These findings are specifically useful for clinical follow up and differentiation from early signs of recurrence of pterygium which may clinically look very similar to the normal healing signs of the graft.

Chapter four studies a different component of the ocular surface which is the cornea. The cornea is responsible for the major proportion of refraction. A retrospective study was conducted to evaluate the effect of different techniques to treat active and established corneal neovessels which can cause inflammation and severe visual impairment. The techniques used were fine needle diathermy, Anti-VEGF injections or both. All patients who received both fine needle diathermy and injections had complete regression of the corneal neovessels for the whole study period.

Chapter five was about the HOLOCORE study, a multi-center prospective study across several centers in Europe for ex vivo limbal stem cell expansion. It involved evaluating the results of Holoclar product- a small limbal biopsy specimen from the unaffected eye or from a normal limbal zone in case of bilateral burns, followed by in vitro expansion to generate a sheet of corneal epithelial cells including both differentiated and stem cells resting on a supportive fibrin layer and kept in a nutrient transport medium- on the corneal neovessels regression and epithelial defect healing in patients with unilateral or bilateral partial chemical or physical burn. Two patients were recruited after meeting the eligibility criteria of the clinical trial. According to the outcome measures of the trial, one patient was considered a success as there was complete regression of the corneal neovessels and healing of the epithelial defect. The second patient failed as the vessels have failed to regress and the epithelial defect failed to heal. The patient underwent other different procedures for treating the neovessels and the defect.

Finally, chapter six was about retinal neovascularization. It was a single centre prospective cross-sectional study to investigate corneal neuropathy in the different stages of diabetes with and without retinopathy and the effect of anti-VEGF and PASCAL laser photocoagulation on corneal nerves in eyes with diabetic macular oedema in non-proliferative diabetic retinopathy and proliferative diabetic retinopathy. This was the first study that has evaluated corneal innervation following anti-VEGF

therapy in a large number of diabetic eyes at different stages of diabetic retinopathy. The results showed that PASCAL is a safe modality of treatment for patients who need focal, macular grid or PRP laser treatment. It also showed that anti-VEGF injections might be implicated in the damage of corneal nerves seen in diabetic eyes especially at the non-proliferative diabetic retinopathy stage. In eyes with proliferative diabetic retinopathy, it is most probable that the long-standing diabetes rather than the laser treatment or anti-VEGF injections are responsible for reduced corneal nerve parameters. However, higher numbers of anti-VEGF injections might play role in the extent of corneal nerve damage.

# CONTENTS

ACKNOWLEDGMENT.....	ii
LIST OF PUBLICATIONS.....	v
LIST OF FIGURES.....	vi
LIST OF TABLES.....	ix
CHAPTER 1: GENERAL INTRODUCTION.....	1
1.1 Ocular surface anatomy.....	1
1.1.1 Corneal layers.....	1
1.1.2 Limbal structure.....	2
1.1.3 Conjunctiva.....	4
1.1.4 Blood supply and lymphatics.....	4
1.1.5 Corneal innervation.....	5
1.2 Corneal angiogenesis.....	5
1.2.1 Epidemiology and risk factors.....	6
1.2.2 Causes.....	6
1.2.3 Mechanism of angiogenesis.....	6
1.2.4 Suppressors of corneal angiogenesis.....	7
1.2.5 Stimulators of corneal angiogenesis.....	9
1.3 Management of corneal vascularisation.....	12
1.3.1 Medical therapy.....	12
1.3.2 Surgical treatment.....	16
1.4 Consequences of corneal vascularization.....	18
1.5 Pterygium: demographics, role of vessels and vascular factors.....	19
1.6 Pterygium recurrence.....	20
1.7 Management of primary pterygium.....	21
1.7.1 Medical.....	21
1.7.2 Surgical excision.....	22
1.8 Management of recurrent pterygium.....	24
1.8.1 Medical.....	24
1.8.2 Surgical excision.....	25
1.8.3 Anti-VEGF as Adjuvant to surgery.....	26
1.9 Limbal stem cell deficiency.....	26
1.10 Retinal anatomy.....	28



1.10.1 Retinal layers .....	28
1.11 Retinal vascular structure and blood supply.....	31
1.12 Retinal neovascularisation .....	31
1.13 Diabetic retinopathy (DR) .....	32
1.13.1 Epidemiology and risk factors.....	32
1.13.2 DR forms.....	32
1.13.3 Pathophysiology of DR .....	32
1.13.4 Consequences of PDR .....	34
1.14 Aims and objectives	
CHAPTER 2: MANAGEMENT OF PRIMARY PTERYGIUM WITH INTRA-LESIONAL INJECTION OF 5 FLUROURACIL AND BEVACIZUMAB (AVASTIN), A CLINICAL TRIAL (REPEAT) .....	35
2.1 Introduction .....	35
2.2 Methods.....	36
2.2.1 Ethical issues .....	36
2.2.2 Patient recruitment.....	37
2.2.3 Clinical intervention and follow up .....	38
2.2.4 Laboratory study method .....	40
2.2.5 Outcome measurements .....	41
2.2.6 Statistics and Data analysis .....	42
2.3 Results.....	42
2.3.1 Recruitment .....	42
2.3.2 Cases .....	43
2.3.3 Laboratory study results .....	47
2.4 Discussion.....	51
CHAPTER 3: HEALING OF AUTOLOGOUS CONJUNCTIVAL GRAFTS IN PTERYGIUM SURGERY.....	54
3.1 Introduction .....	54
3.2 Methods.....	55
3.2.1 Ethical issues .....	55
3.2.2 Patient recruitment.....	55
3.2.3 Clinical intervention and follow up .....	55
3.3 Results.....	58
3.3.1 Cases .....	58
3.3.2 Conjunctival autograft angiography.....	70
3.4 Discussion.....	74
CHAPTER 4: MANAGEMENT OF ACTIVE AND ESTABLISHED CORNEAL NEOVASCULARISATION TO PREVENT VISUAL IMPAIRMENT .....	77

4.1 Introduction .....	77
4.2 Methods.....	78
4.2.1 Ethical issues .....	78
4.2.2 Patients .....	78
4.2.3 Clinical intervention and follow up .....	79
4.2.4 Outcome measurements .....	83
4.2.5 Statistics and data analysis.....	83
4.3 Results.....	83
4.4 Discussion.....	90
CHAPTER 5: AUTOLOGOUS CULTIVATED LIMBAL STEM CELLS TRANSPLANTATION FOR RESTORATION OF CORNEAL EPITHELIUM IN PATIENTS WITH LIMBAL STEM CELL DEFICIENCY DUE TO OCULAR BURNS (HOLOCORE Study).....	93
5.1 Introduction .....	93
5.2 Methods.....	95
5.2.1 Ethical issues .....	95
5.2.2 Patient recruitment.....	95
5.2.3 Clinical Intervention and follow up .....	98
5.2.4 Outcome measurements .....	112
5.3 Results.....	112
5.3.1 Recruitment .....	112
5.3.2 Cases .....	113
5.4 Discussion.....	124
CHAPTER 6: CORRELATION BETWEEN DIABETIC CORNEAL NEUROPATHY AND DIFFERENT STAGES OF DIABETIC RETINOPATHY.....	126
6.1 Introduction .....	126
6.2 Methods.....	128
6.2.1 Ethical issues .....	128
6.2.2 Patient recruitment.....	128
6.2.3 Clinical intervention and follow up .....	130
6.2.4 Outcome measurements .....	131
6.2.5 Statistics and data analysis.....	131
6.3 Results.....	132
6.3.1 Recruitment and Cases .....	132
6.4 Discussion.....	145
CHAPTER 7: SUMMARY AND CONCLUSIONS .....	149
BIBLIOGRAPHY .....	154

## LIST OF PUBLICATIONS

List of publication related to work conducted in this thesis:

1. Ghoz N, Elalfy M, Said D, Dua H. Healing of autologous conjunctival grafts in pterygium surgery. *Acta Ophthalmol.* 2018 Dec;96(8):e979-e988. doi: 10.1111/aos.13794. Epub 2018 Aug 29. PMID: 30156059
2. Ghoz N, Britton J, Ross AR, Mohammed I, Hogan E, Said DG, Dua HS. Management of primary pterygium with intra-lesional injection of 5 fluorouracil and bevacizumab (Avastin). *Eye (Lond).* 2019 Nov;33(11):1776-1783. doi: 10.1038/s41433-019-0493-0. Epub 2019 Jun 19.

## **LIST OF ABBREVIATIONS**

<b>ACER</b>	<b>Amnion assisted conjunctival epithelial redirection</b>
<b>ACLSC</b>	<b>Autologous Cultivated Limbal Stem Cell</b>
<b>ACLSCT</b>	<b>Autologous Cultivated Limbal Stem Cell Transplantation</b>
<b>AL</b>	<b>Autolimbal transplantation</b>
<b>AMT</b>	<b>Aminiotic membrane graft transplantation</b>
<b>Ang 1,2.</b>	<b>Angiopoietins 1,2.</b>
<b>APCs</b>	<b>Antigen presenting cells</b>
<b>bFGF</b>	<b>Basic fibroblast growth Factor</b>
<b>CD</b>	<b>Cadaver donor</b>
<b>CHMP</b>	<b>Committee for Medicinal Products for Human use</b>
<b>CNV</b>	<b>Choroidal neovascularization</b>
<b>COMET</b>	<b>Cultivated Oral Mucosal Epithelial Transplantation.</b>
<b>DM</b>	<b>Diabetes Mellitus</b>
<b>DME</b>	<b>Diabetic macular edema</b>
<b>DR</b>	<b>Diabetic retinopathy</b>
<b>EGF</b>	<b>Epidermal growth factor</b>
<b>EMA</b>	<b>European medicines agency</b>
<b>ERG</b>	<b>Electroretinography</b>
<b>FGFs</b>	<b>Fibroblast growth factors</b>
<b>FND</b>	<b>Fine needle diathermy</b>
<b>HRA</b>	<b>Health research authority</b>
<b>IPL</b>	<b>Inner plexiform layer</b>
<b>IVCM</b>	<b>Invivo confocal microscopy</b>
<b>LEC</b>	<b>Limbal epithelial crypts</b>
<b>LRD</b>	<b>Living donor</b>
<b>LSCD</b>	<b>Limbal stem cell deficiency</b>
<b>MHRA</b>	<b>Medicines and healthcare products regulatory agency</b>
<b>MMC</b>	<b>Mitomycin C</b>
<b>MMPs</b>	<b>Matrix metalloproteinases</b>

<b>NV</b>	<b>Corneal neovascularization</b>
<b>NVAMD</b>	<b>Neovascular age related macular degeneration.</b>
<b>OCT</b>	<b>Optical coherence tomography</b>
<b>OPL</b>	<b>Outer plexiform layer</b>
<b>PASCAL</b>	<b>Pattern scanning laser</b>
<b>PEDF</b>	<b>Pigment epithelium derived factor</b>
<b>PDGFs</b>	<b>Platelet derived growth factors</b>
<b>R&amp;I</b>	<b>Research and innovation</b>
<b>RPE</b>	<b>Retinal pigment epithelium</b>
<b>SC</b>	<b>Stem cells</b>
<b>SSCE</b>	<b>Sequential sectoral conjunctival epitheliectomy</b>
<b>VEGF</b>	<b>Vascular endothelial growth factor</b>
<b>5FU</b>	<b>5 fluorouracil</b>

## LIST OF FIGURES

<b>Figure 1.1: A composite image illustrating different corneal layers adapted from Dua et al 2013. ....</b>	<b>2</b>
<b>Figure 1.2: A cross-sectional diagram of the human corneal limbus.....</b>	<b>4</b>
<b>Figure 1.3: A three-dimensional section of the human cornea showing the corneal nerves distribution and their density and width at different layers adapted from Mansoor et al .....</b>	<b>7</b>
<b>Figure 1.4: Slit-lamp anterior segment photograph of a primary pterygium.....</b>	<b>23</b>
<b>Figure 1.5: Slit-lamp anterior segment photograph of a recurrent pterugium.....</b>	<b>24</b>
<b>Figure 1.6: Illustration of retinal layers .....</b>	<b>36</b>
<b>Figure 1.7: Anatomy of ocular circulation.....</b>	<b>38</b>
<b>Figure 2.1: Slit lamp anterior segment photograph of a pterygium post injection .....</b>	<b>52</b>
<b>Figure 2.2: Slit-lamp anterior segment photograph of REPEAT09 before and after 5 injections..</b>	<b>53</b>
<b>Figure 2.3: Slit lamp anterior segment photographs of REPEAT14 before and after 3 injections..</b>	<b>54</b>
<b>Figure 2.4: Slit lamp anterior segment photographs images of REPEAT16 before and after 5 injections.....</b>	<b>54</b>
<b>Figure 2.5: Immunofluorescence analysis of control and injected pterygium samples... </b>	<b>56</b>
<b>Figure 2.6: Representative sections of sample from control (n=3) and injected (n=4) groups (Double labeling of bFGF and SPARC) .....</b>	<b>57</b>
<b>Figure 2.7: Representative micrographs of control (n=3) and injected (n=4) samples. (Co- localization of vWF (vascular) and LVYE-1 (lymphatic) channels).....</b>	<b>58</b>
<b>Figure 3.1: Slit lamp anterior segment photographs of the conjunctival autograft within 1 week of transplant.....</b>	<b>69</b>
<b>Figure 3.2: Slit lamp anterior segment photographs of the conjunctival autograft within 1 week of transplant.....</b>	<b>70</b>
<b>Figure 3.3: Slit lamp anterior segment photographs of the conjunctival autograft within 1 week of transplant (without and with fluorescein staining (2% eye drops).....</b>	<b>71</b>
<b>Figure 3.4: Slit lamp anterior segment photographs of the conjunctival autograft within 1 week of transplant (without and with fluorescein 2% eye drops) .....</b>	<b>71</b>

<b>Figure 3.5: Slit lamp anterior segment photographs images of the conjunctival autograft of a patient from 1 week of surgery to 6 months (without and with fluorescein 2% eye drops).....</b>	<b>72</b>
<b>Figure 3.6: Slit lamp anterior segment images of the conjunctival autograft of a patient from 1 week of transplant to 6 months (without and with fluorescein 2% eye drops).....</b>	<b>73</b>
<b>Figure 3.7: Representative image of the conjunctival autograft of a patient at 1 month postoperative (slit lamp image, diffuse illumination).....</b>	<b>75</b>
<b>Figure 3.8: Slit lamp anterior segment photograph of the donor site of a patient at 1 week postoperative.....</b>	<b>76</b>
<b>Figure 3.9: Slit lamp anterior segment photograph of the donor site of a patient at 3 months postoperative .....</b>	<b>77</b>
<b>Figure 3.10: Slit lamp anterior segment photograph of the donor site of a patient at 2 weeks postoperative .....</b>	<b>78</b>
<b>Figure 3.11: Image of the conjunctival autograft of a patient at 1 day postoperative (A) Slit lamp diffuse anterior segment photograph of conjunctival autograft (B) Anterior segment fluorescein angiogram at 1 minute and 45 seconds.....</b>	<b>78</b>
<b>Figure 3.12: Anterior segment fluorescein angiogram at 4 min and 10 seconds of the conjunctival autograft of a patient at 3 months postoperative .....</b>	<b>79</b>
<b>Figure 3.13: Image of the conjunctival autograft of a patient at 3 days postoperative (A) Slit lamp diffuse anterior segment photograph of conjunctival autograft (B) Anterior segment fluorescein angiogram at 56 seconds .....</b>	<b>80</b>
<b>Figure 3.14: Anterior segment fluorescein angiogram at 10 seconds of the conjunctival autograft of a patient at 2 days postoperative .....</b>	<b>81</b>
<b>Figure 4.1: Classification of corneal vessels.....</b>	<b>88</b>
<b>Figure 4.2: Slit lamp anterior segment photographs of a patient before treatment (top image) and after treatment with FND, Avastin and PK (bottom image).....</b>	<b>95</b>
<b>Figure 4.3: Slit lamp anterior segment photographs of a patient before treatment (top image) and after treatment with FND, Avastin (bottom image).....</b>	<b>96</b>

<b>Figure 4.4: Slit lamp anterior segment photographs of a patient with lipid keratopathy before treatment (top image) and after treatment with FND (bottom image) .....</b>	<b>97</b>
<b>Figure 5.1: Slit lamp anterior segment photographs of Case 1 on V1.....</b>	<b>115</b>
<b>Figure 5.2: Cobalt blue filter image with fluorescein sodium 2% eye drops of Case 1 on V10...118</b>	
<b>Figure 5.3: Cobalt blue filter image with fluorescein sodium 2% eye drops of Case 1 2 weeks after V10 .....</b>	<b>119</b>
<b>Figure 5.4: Slit lamp anterior segment photographs of Case 1 9 months on V1 .....</b>	<b>120</b>
<b>Figure 5.5: Slit-lamp anterior segment photograph of Case 2 at V1.....</b>	<b>122</b>
<b>Figure 5.6: Slit-lamp anterior segment photograph of Case 2 at V10.....</b>	<b>123</b>
<b>Figure 5.7: Slit-lamp anterior segment photograph of Case 2 at V11.....</b>	<b>124</b>
<b>Figure 5.8: Slit-lamp anterior segment photograph of Case 2 two weeks after V11 ....</b>	<b>125</b>
<b>Figure 5.9: Slit-lamp anterior segment photograph of Case 2 at V12.....</b>	<b>126</b>
<b>Figure 6.1: IVCN image of a left eye of a patient showing sub-basal corneal nerves (depth 167 microns) of normal length and density.....</b>	<b>133</b>
<b>Figure 6.2: IVCN image of a left eye of a patient showing sub-basal corneal nerves (depth 62 microns) of reduced length and density.....</b>	<b>134</b>
<b>Figure 6.3: Box plot showing insignificant difference in nerve length between NPDR eyes that did not receive laser treatment and NPDR eyes that received laser treatment .....</b>	<b>139</b>
<b>Figure 6.4: Box plot showing insignificant difference in nerve density between NPDR eyes that did not receive laser treatment and NPDR eyes have received laser treatment.....</b>	<b>140</b>
<b>Figure 6.5: Box plot showing significant difference in nerve length between NPDR eyes that did not receive injections and NPDR eyes that received injection.....</b>	<b>140</b>
<b>Figure 6.6: Box plot showing significant difference in nerve density between NPDR eyes that did not receive injections and NPDR eyes that received injection.....</b>	<b>141</b>



**Figure 6.7: Box plot showing insignificant difference in nerve length between NDR eyes that did not receive laser treatment and NPDR eyes that received laser treatment .....142**

**Figure 6.8: Box plot showing insignificant difference in nerve density between PDR eyes that did not receive injections and PDR eyes that received injections ..... 142**

**Figure 6.9: Box plot showing insignificant difference in nerve length between PDR eyes that did not receive injections and PDR eyes that received injections ..... 143**

**Figure 6.10: Box plot showing insignificant difference in nerve density between PDR eyes that did not receive injections and PDR eyes that received injections ..... 144**

## LIST OF TABLES

<b>Table 2.1: Follow up scheme of REPEAT .....</b>	<b>48</b>
<b>Table 2.2. Primary antibodies used for immunofluorescence .....</b>	<b>49</b>
<b>Table 2.3: Demographic data of REPEAT cases .....</b>	<b>51</b>
<b>Table 2.4: Marked reduction in average number of vWF and LYVE-1 positive vessels ..</b>	<b>58</b>
<b>Table 3.1: Age and sex of patients and laterality of the pterygium .....</b>	<b>66</b>
<b>Table 4.1 Demographic data and procedures done for each case.....</b>	<b>91</b>
<b>Table 4.2: End stage of NV in each of the 3 treatment regimens.....</b>	<b>93</b>
<b>Table 5.1: Details of patient’s visits during the study course.....</b>	<b>106</b>
<b>Table 5.2: Details of procedures carried out in each visit during the study course.....</b>	<b>111</b>
<b>Table 5.3: Demographic data of HOLOCORE cases .....</b>	<b>115</b>
<b>Table 6.1: Demographics of study participants .....</b>	<b>136</b>
<b>Table 6.2: p-value of statistical test for combining nerve length and nerve density for both eyes in in Control, NPDR, PDR and diabetics with no retinopathy groups.....</b>	<b>137</b>
<b>Table 6.3: Normality of distribution testing of each group. Non-parametric Kolmogorov Smirnov test was used.....</b>	<b>137</b>
<b>Table 6.4: p-value of statistical test for combining nerve length and nerve density for both eyes in in Control, NPDR, PDR and diabetics with no retinopathy groups.....</b>	<b>138</b>

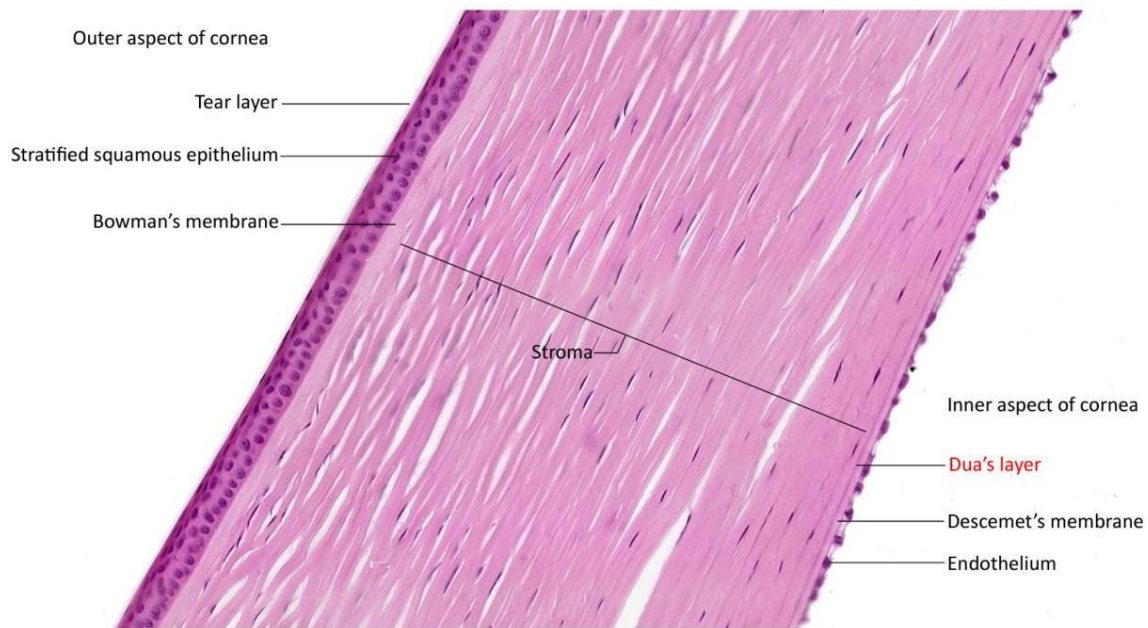
# CHAPTER 1: GENERAL INTRODUCTION

## 1.1 Ocular surface anatomy

The ocular surface consists of the corneal epithelium, the limbal epithelium and the epithelial lining of the conjunctiva and lid margins. The transparent cornea is the part of the ocular surface that is responsible for 65% of refraction in the eye allowing the light to pass and focus on its way to the retina.

### 1.1.1 Corneal layers

The cornea consists of 6 layers: epithelium which is the outer most layer with its basement membrane. Posterior to the epithelial basement membrane lies the Bowman's membrane which is a condensation of types 1 and 4 and proteoglycans. The stroma which forms 90% of the corneal thickness is formed of stromal fibers, extracellular matrix and keratocytes. The stromal fibers are mainly made of collagen type 1 but also contain types 4 and 12 collagen. Pre- Descemet's layer (Dua's layer) lies posterior to the stroma and is formed of collagen fibers(1). Descemet's membrane lies posterior to Dua's layer and contains type 4 collagen and laminin and is acellular. The endothelium which is the inner most layer is a single layer of hexagonal cells (Figure 1.1). The corneal epithelium is a uniform non-keratinised stratified squamous epithelium extending from limbus to limbus and is continuous with the limbal epithelium. It is made of 4 to 6 layers and has 3 types of cells which are the superficial flat cells, wing cells and basal cells. The transparency of the cornea is attributed to the extremely well organised epithelium and organisation of the collagen fibres which lie parallel to each other and to the plane of the cornea within the stroma as well as corneal lack of vascularity (2). The basement membrane is secreted by the basal epithelial cells and is made of different proteins mainly type IV collagen, fibrin, fibronectin and laminin. It acts as a foundation for the epithelial cells (3).



*Figure 1.1: A composite image illustrating different corneal layers (adapted from Dua et al 2013, 1).*

### 1.1.2 Limbal structure

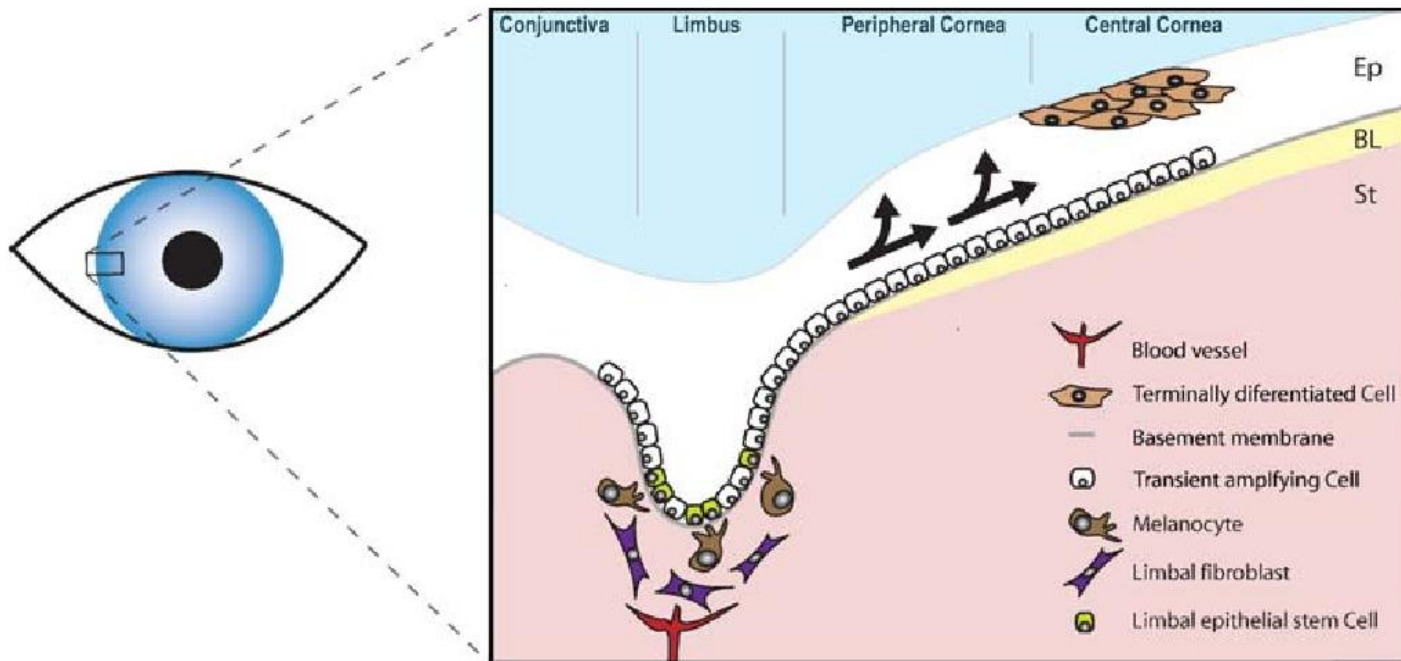
The palisades of Vogt with their interpalisade rete ridges, the specialized connective tissue architecture, the various epithelial immunophenotypes and the limbal epithelial crypts; as well as a highly organized vascular and nervous supply provide the physiological microenvironment and the anatomical support for the limbus (corneoscleral junction) to maintain and sustain the limbal epithelial stem cells. Stem cells (SC) are progenitor cells with the role of tissue regeneration and cells replacement. SC are slow cycling and live as long as the organ they serve and constitute a very small part of the total cell mass of the organ. They are the source from which almost all other cells arise that constitute a given organ served by the SC. Corneal epithelial stem cells are committed progenitors and their physiological role is to only differentiate to corneal epithelial phenotype, though in experimental conditions can be made to transdifferentiate to hair follicles (4, 5). SC play a major role in healing and regeneration of epithelium after injury but have a minimal role in physiological homeostasis of the corneal epithelium (6, 7). Limbal stem cells reside in a well-

protected microenvironment called the niche. The niche surrounds stem cells and modulates their function and fate through internal and external factors. They are protected from Ultraviolet radiation by melanocytes that reside in the basal layers of the limbal epithelium and by the upper and lower eyelid that act as a protective cover to the superior and inferior limbus (8-10). It acquires its oxygen supply, cytokines, growth factors and other several nutrients from the limbal stromal blood vessels and mesenchymal cells (2, 11-13). The niche also regulates the limbal stem cell cycle to keep them in an undifferentiated resting state (11, 14). The inter palisade rete ridges of the palisades of Vogt constitute the limbal SC niche (4, 5, 15, 16).

The palisades of Vogt are radially oriented fibrovascular ridges and are very prominent along the upper and lower limbus. They are visible in pigmented individuals due to the high melanin content of the epithelial cells. The 'valley' between the adjacent palisades is packed with epithelial cells that form the interpalisade (epithelial) rete ridge. Impression cytology studies show that the limbal epithelial cells are smaller, with a higher cell density and a greater nucleus to cytoplasm ratio compared to central corneal epithelial cells (17, 18). The connective tissue of the palisade is rich in arteries, veins, nerves and lymphatics. The arterial supply is from the anterior ciliary arteries derived from arteries of the rectus muscles. The epithelium covering the palisade is 2 to 3 cells thick. The epithelial cells in inter palisade rete ridges are 10 to 15 cells thick (19).

Limbal epithelial crypts (LEC) are solid cords of epithelial cells that arise from the posterior end of the inter palisade rete ridge and extend into the surrounding substantia propria peripherally, centrally towards the cornea or circumferentially in a clockwise or anticlockwise direction (18, 20). LEC could be minor and major, with the major ones ranging from 40 to over 200 microns. The average number of LEC is 9 per eye. LEC are packed with epithelial phenotype of cells, basal, suprabasal and central. The cell membrane of the basal cells in contact with the basement membrane have complex finger-like processes with special hemidesmosomes, allowing for a strong attachment between these putative SC and the substrate. The peripheral corneal basal cell attachments are also firmer than the central epithelial attachments. Hence following injury, a peripheral rim of corneal epithelium (and the limbal epithelium) remain attached even when a large area of the central cornea is lost. Cells from this rim migrate centripetally as convex sheets that close the defect and restore

epithelial integrity. Lines of contact between these sheets stain with fluorescein and appear as the pseudo dendrites seen during healing of corneal epithelial defects (21).



*Figure 1.2: A cross-sectional diagram of the human corneal limbus. (corneal epithelial stem cells, deficiency and regulations (adapted from G.Secker,et al,21)*

### 1.1.3 Conjunctiva

The conjunctiva is the highly specialised mucosal lining of the ocular surface and it extends from the lid margin, posterior to the grey line and lines the posterior aspect of the lids forming the palpebral or tarsal conjunctiva. It then folds over to cover the eye ball as the bulbar conjunctiva. The folds between the bulbar and palpebral conjunctiva are called superior, inferior, lateral and medial fornices. The conjunctiva is made of epithelial cells and substantia propria which is loose connective tissue underlying the epithelium. The conjunctival epithelium is squamous, non-keratinized, with goblet cells which are found all over the conjunctiva especially in the nasal palpebral and forniceal areas. The conjunctival cells are rich in cytoplasmic organelles. The substantia propria is very rich in blood vessels and contains lymphoid tissue made of plasma cells, lymphocytes, neutrophils and mast cells (22-24).

### 1.1.4 Blood supply and lymphatics

The cornea is an avascular structure and acquires nutrients from the peri-corneal limbal vasculature, the aqueous humour and the tear film (25-27).

Limbal vessels consist of basement membrane and endothelial cell lining. The basement membrane is made of fine filaments with embedded collagen fibrils. The filaments are arranged in alternating layers, each layer is less than 0.1 microns thick. The endothelial cells form the vessel wall and are organised in a single layer attached to their basement membrane (28).

Two types of capillaries have been described in the limbus; muscle type capillaries with thick endothelium and fenestrated visceral type capillaries. There is no gap between the endothelial cells in most of the capillaries. However, a thin membrane covering this gap was described in some localised areas where the vessel appears to be fenestrated. Pericytes were seen on the outer surface of the arterial capillaries and in proximity to the endothelial cells (29). Pericytes have similar structure to the endothelial cells but are functionally

different (30). It is commonly believed that pericytes are one major source of mesenchymal stem cells (31-34).

Pericytes also lead to specific induction of fibronectin and nidogen-1 (i.e., matrix-bridging proteins that link together basement membrane components) as well as perlecan and laminin isoforms (35).

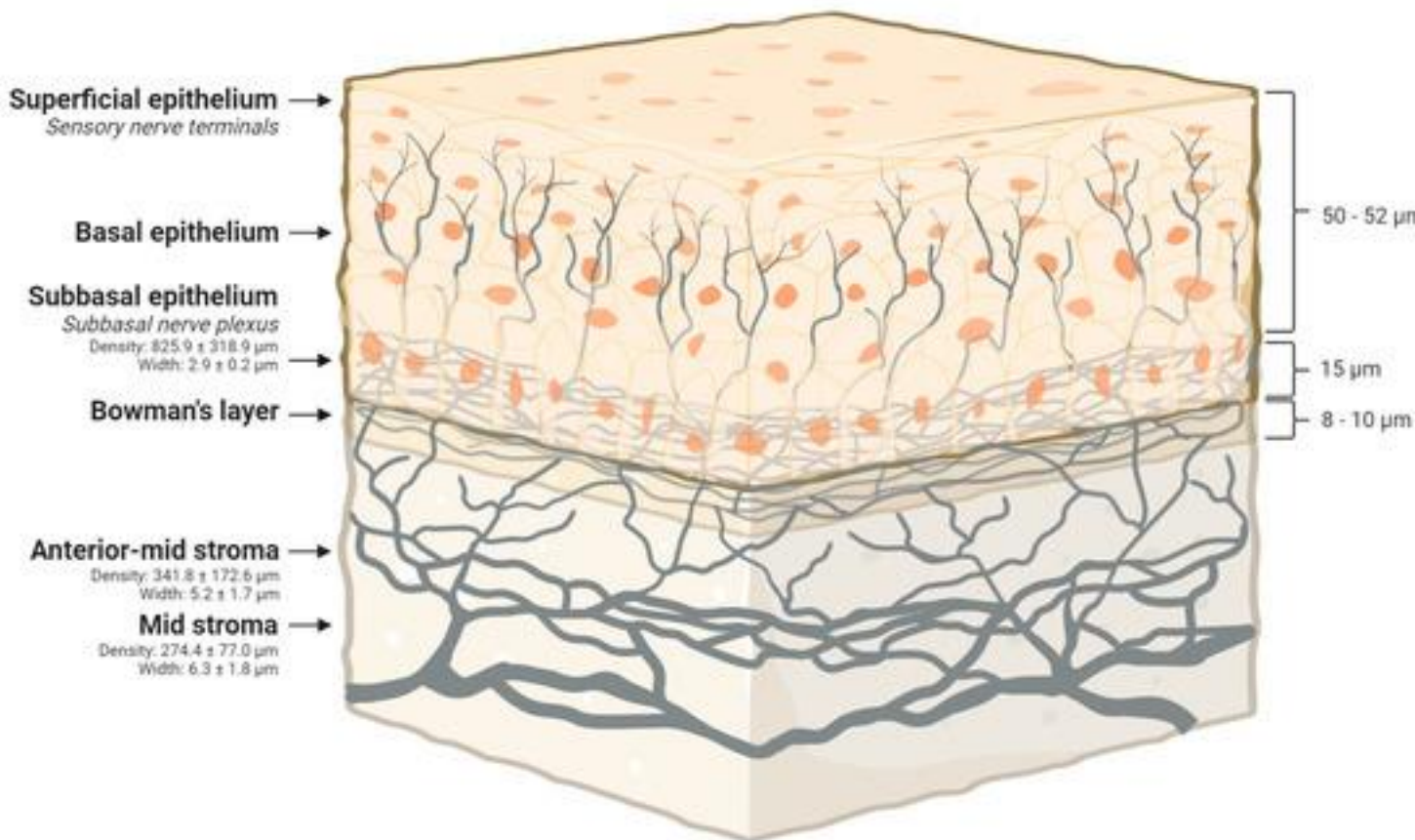
The cornea is normally devoid of lymphatic vessels thus allowing for its unique immune privileged status. Corneal neovascularisation is usually associated with lymphatics- subsequent studies of vascularised corneas supported the presence of lymphatic vessels in the cornea using lymphatic specific markers which augment the afferent arc of the immune response and is related to the abrogation of the immune privileged status of the cornea (36, 37).

### **1.1.5 Corneal innervation**

The cornea is a highly innervated structure and has both sensory and autonomic nerves and is mainly vasomotor in function (38). Corneal innervation is mainly sensory from the ophthalmic division of the trigeminal nerve via the long posterior ciliary nerves. These nerves branch forming the peri-limbal plexus(39).

The autonomic nerve fibers have sympathetic fibers that originate from the superior cervical ganglion as well as parasympathetic fibers that come from the ciliary ganglion. Demyelinated radial nerves emerge from the peri-limbal plexus and enter the cornea at mid stromal level. There are about 11 radial nerves in each quadrant. They run towards the centre and superficially to form the Bowmans plexus. Smaller branches penetrate Bowmans membrane ending in the sub-basal plane of the epithelium, in terminal bulbs which are 20 to 40 microns in diameter. The penetration sites are mainly situated in the mid-peripheral cornea. Finer neurites arise from the bulbs as naked endings (without Schwann cells) forming the sub-basal plexus (40). Terminal nerves from the sub-basal nerve plexus enter the epithelium and end inter and intra-cellularly (41).





*Figure 1.3: A three-dimensional section of the human cornea showing the corneal nerves distribution and their density and width at different layers. Diabetic corneal neuropathy (adapted from Hassan Mansoor et al, 39)*

## 1.2 Corneal angiogenesis

### 1.2.1 Epidemiology and risk factors

Corneal neovascularization (NV) is a condition that can result in severe visual impairment and represents a major public health problem (42). It is estimated that for a given year, 1.4 million patients in the US may develop corneal NV; and 20% of corneal samples taken during corneal transplantation revealed histopathologic evidence of vascularization (43). Recently, it was found to affect up to 4.14% of patients coming for eye care (44). The rate of corneal NV may be as high as 60% in patients with inflammatory disorders such as atopic

keratoconjunctivitis (45). A study was performed to assess corneal NV after penetrating keratoplasty in patients without active inflammation, previous corneal NV or persistent epithelial defects. The study reported a remarkably higher risk of corneal NV when suture knots were buried in the host stroma, when a large recipient was used or when active blepharitis was present. They also reported that 41% of eyes receiving corneal grafts developed corneal NV 6 to 9 months after the corneal transplant (46). The most common cause for corneal neovascularisation was found to be herpes simplex keratitis and it remains to be the most common cause of recurrence of NV after corneal grafting (47, 48).

### **1.2.2 Causes**

Corneal neovascularisation could occur due to the following disorders (44, 49, 50):

1. Hypoxia due to contact lens wear
2. Infectious keratitis due to viral, bacterial, fungal and parasitic infections
3. Limbal stem cell deficiency
4. Trauma
5. Ocular surface neoplasia such as conjunctival, corneal intraepithelial neoplasia and papilloma.
6. Inflammatory ocular surface disorders such as Steven-Johnson syndrome, atopic conjunctivitis, Rosacea and Mucous membrane pemphigoid.

### **1.2.3 Mechanism of angiogenesis**

In corneal angiogenesis, corneal NV sprout mainly from the venules and capillaries of the limbal plexus. Depending on the underlying pathology, corneal NV are present clinically in three different forms (1) stromal NV mainly correlated with stromal keratitis, (2) deep NV overlying Descemet's membrane in herpetic keratitis and (3) vascular pannus which is associated with connective tissue growing in the superficial periphery of the cornea and is seen mainly in ocular surface disorders (46, 51).

Insults to the cornea activate inflammatory and immune-mediated pathways leading to an imbalance between angiogenic and antiangiogenic factors and this balance may be tilted in favour of NV due to the upregulation of angiogenic factors and/or the downregulation of antiangiogenic factors (52-55). The angiogenic factors include vascular endothelial growth factor (VEGF), fibroblast growth factor, platelet derived growth factor, inflammatory mediators and angiopoietins with VEGF being the most prominent molecule involved in the promotion of NV. Antiangiogenic factors are pigment epithelium-derived factor, VEGF Receptor-2, endostatin and angiostatin (56). MMPs can act as a stimulator or inhibitor of angiogenesis in different circumstances (57, 58).

The antiangiogenic molecules were found to work together to maintain the cornea in an avascular state. Alternatively, it was mentioned that molecules can act individually to suppress corneal vascularisation.

Corneal NV can be superficial or deep. Superficial NV is either localized or diffuse (pannus). Pannus is fibrovascular tissue that separates the epithelium from Bowman's membrane, occasionally extending than Bowman's membrane. With trachoma it tends to involve the upper part of the cornea while in in exposure or bullous keratopathy it involves the lower part of the cornea. In chemical burns, it is massive and covers the whole cornea. Each vessel of a pannus consists of a small arteriole forming a loop with one large venule or more via a small capillary bed. The vessels move by simple migration of the loop. On the other hand, localized superficial NV consists of a layer of vessels that includes interstitial and superficial vessels. These vessels are directed towards a specific lesion and is most commonly seen in recurrent herpetic keratitis. Histologically, superficial NV are located under the epithelium and are associated with inflammatory cells during their active progression. Pannus will be associated with plenty of connective tissue. Deep NV tends to occur between the corneal stroma and Descemet's membrane. They tend to occur following interstitial keratitis (Corneal vascularization, David G.

## **1.2.4 Suppressors of corneal angiogenesis**

### **A) VEGF Receptors**

Multiple VEGF receptors are expressed by the cornea and these act as “decoy” receptors for the proangiogenic VEGF molecules. These receptors are soluble VEGF-1 and soluble VEGF-2. Soluble VEGF-1 suppresses angiogenesis via sequestration of VEGF-A molecules (56, 59). The corneal epithelium is responsible for expressing membrane bound VEGF-3 which in turn sequesters VEGF-C and VEGF-D (60). This leads to indirect suppression of angiogenesis by inhibiting the recruitment of VEGF secreting macrophages (61).

### **B) Pigment epithelium–derived factor (PEDF)**

PEDF is thought to act individually to maintain the cornea in an avascular state (62). PEDF is found in large amounts in the corneal stroma, iris and retinal pigment epithelium (63, 64). When an antibody that suppresses the action of PEDF was delivered to the cornea, it was found that the cornea became invaded with blood vessels. On delivery of large amounts PEDF to the corneal stroma the blood vessels showed reduction (65).

### **C) Angiostatin**

Angiostatin is present in the tear fluid and the corneal epithelium (66). Angiostatin suppresses corneal NV via binding to integrin  $\alpha v \beta 3$  (67), vascular endothelial cell surface-expressed F1-F0 ATP synthase R (68, 69) and hepatocyte growth factor receptor (c-met) (70-72) resulting in suppression of cell migration and proliferation (68, 73).

### **D) Angiogenin**

Angiogenin is present in tears and reduces the inflammation caused by tumour necrosis factor-alpha or lipopolysaccharide in human corneal fibroblasts by suppressing I $\kappa$ B kinase-epsilon mediated activation of nuclear factor-kappaB (74),

### **E) Matrix metalloproteinases (MMPs)**

MMPs play a query role in corneal vascularization as the same molecule is capable of being a stimulator or inhibitor of angiogenesis in different circumstances (57, 58). MMP-7 (matrilysin) promotes vascularization by stimulating the production of VEGF and promoting proliferation of vascular endothelial cells (75, 76). MMP-7 produced by the corneal basal epithelial layer is believed to play a role in suppressing angiogenesis and this is evidenced by the massive increase of the angiogenic response to corneal trauma when MMP-7 becomes deficient (77, 78). This may be a function of the MMP-7-mediated cleavage of type XVIII collagen, the precursor of antiangiogenic endostatin (79) (80).

#### **F) Endostatin**

Endostatin is a proteolytic portion of collagen XVIII and suppresses angiogenesis by inhibiting the VEGF and fibroblast growth factor (81, 82). Collagen XVIII is present in lens capsule, lens and cornea (50).

### **1.2.5 Stimulators of corneal angiogenesis**

#### **A) Vascular Endothelial Growth Factors (VEGF)**

VEGF are secreted growth factor peptides generated by alternative splicing in five isoforms (VEGF 115, VEGF 121, VEGF 165, VEGF 189 and VEGF 206). The members of the VEGF family are VEGF-A, VEGF-B, VEGF-C, VEGF-D and placental growth factor (PlGF) (83). VEGFs bind to tyrosine kinase receptor VEGF-1, VEGF-2 and VEGF-3 (83, 84).

VEGF is produced by T cells, pericytes, smooth muscle cells, astrocytes, retinal pigment epithelial cells and macrophages secondary to inflammation and hypoxia. Hypoxia is the main regulator of VEGF gene expression. VEGF expression is also regulated by several cytokines such as epidermal growth factor, prostaglandin E2, interleukin 1a, interleukin 6 and transforming growth factor-B (85, 86).

VEGF is a peptide present massively in the epithelium of vascularized corneas secondary to inflammation(87)and is a strong promoter of corneal inflammation induced by hypoxia and angiogenesis(88). VEGF is also produced in the stromal keratocytes and endothelium (89).

VEGF-A is the most important member of VEGF family regarding angiogenesis (90, 91).VEGF-A binds to VEGF-2(92) resulting in vascular endothelial cell proliferation, migration and increased vascular permeability and dilation (86, 93, 94). Moreover, VEGF attracts inflammatory cells (e.g. macrophages) chemically leading to production of more proangiogenic molecules(95).When VEGF-C or VEGF-D bind to VEGF-2 or -3 lymphangiogenesis is stimulated in a similar way (96, 97).

#### **B) Inflammatory Mediators**

All causes of corneal angiogenesis result from inflammation. Inflammatory cells are abundant in VEGF molecules and thus encourage angiogenesis (98).

Inflammatory mediators such as chemokines can promote angiogenesis either directly or by recruiting inflammatory cells (99). Integrins help with the migration of vascular endothelial cells and inflammatory cells (100). Interleukin 6, transforming growth factor and tumour necrosis factor organize the process of VEGF production and activate inflammatory cells (101-104).

### **C) Fibroblast Growth Factors (FGFs)**

There are 18 types of FGs that bind to FGF receptors (105, 106). FGF1 and FGF 2 are strong stimulators of angiogenesis (107, 108). FGF2 is produced by corneal epithelial cells and released as a result to injury to the epithelium (50, 109) and binds to receptors on the epithelial basement membrane, Bowman membrane and Descemet membrane (110, 111) thus promoting vascular endothelial cell proliferation and migration (112, 113).

### **D) Platelet-derived growth factors (PDGFs)**

PDGF and VEGF are related both in structure and function (114). Humans have four PDGF chains (PDGF-A, -B, -C, and -D) that bind to tyrosine kinase receptor complexes of PDGFR- $\alpha$  or PDGFR- $\beta$ (115). PDGF-A and -B are present in corneal endothelial cells, epithelial cells and stromal fibroblasts (116). PDGFR- $\alpha$  and PDGFR- $\beta$  are expressed by corneal epithelial cells, stromal fibroblasts, and endothelial cells (116) (117).

### **E) Angiopoietins (Ang)**

Once vessels are formed, Ang family including Ang1, 2, and 4 ((118) come into place in the process of angiogenesis. Ang-1 induces maturation of blood vessels and this is evidenced by an increase in vessels perfusion and density. The role of Ang-2 has remained controversial, however, with recent reports suggest that in some circumstances, it may be pro-angiogenic via promoting a rapid increase in capillary diameter, remodelling of the basal lamina, proliferation and migration of endothelial cells and stimulating the sprouting of new blood vessels (119).

## **1.2.3 Quantification of Corneal NV**

Faraj et al. (47) have recently carried out a study with the aim of clinically characterizing the corneal NV in 165 patients with various causes of corneal pathologies. They assessed the vessels location, depth, length, branching pattern, colour, lipid leakage, blood flow and presence or absence of haemorrhage and developed a clinical grading system for corneal NV. They staged the vessels into five categories based on their morphological characteristics and created a system for the quantification of NV as follows (Please see Chapter 4, figure 4.1):

1. Active young vessels: Newly formed vessels that contain a lot of blood, bright red with minimal fibrous tissue layering . They are seen to be actively progressing in the cornea and a well- defined network of fine capillary vessels. The corneal stroma surrounding the vessels shows signs of leakage
2. Active old vessels: These are vessels that reach and surround or cover the lesion in the cornea. Their progression stops but the fibrosis will keep progressing. They are less bright than the young vessels and still have an active circulation
3. Partially regressed: These vessels are present when corneal pathology has stopped due to therapy or the arrival of corneal vessels or following fine needle diathermy of corneal vessels. The blood circulation is slow, the vessels are less dilated and some parts of the complex become less visible or reduced. Both active old vessels and partly regressed vessels show arborizing pattern from the limbus towards the centre, with the vessels becoming narrower towards the centre
4. Mature: These are larger vessels, with less branching and regressed or absent capillary networks, seen to persist in scar tissue or in the corneal stroma after the corneal pathology has abated. These vessels maintain a blood circulation
5. Regressed (ghost vessels): These can be seen as fine white lines mirroring the morphology of the original vessels and are seen as 'ghost vessels'. These do not contain a circulation and the surrounding cornea is not swollen. Ghost vessels are situated in the stroma



## **1.3 Management of corneal vascularisation**

Choosing the appropriate method for managing the corneal neovascularisation is dependent on the state of maturity of these vessels. Mature vessels are not dependent on angiogenic mediators and thus surgical interventions such as fine needle diathermy are the most effective method for treating them, while actively growing vessels indicate an underlying ongoing pathology which is best treated by anti-VEGF in the form of drops or subconjunctival injections (120).

### **1.3.1 Medical therapy**

#### **A) Steroids**

The impact of corticosteroids in inhibiting the corneal vessels both in clinical and experimental conditions is well documented especially topical and subconjunctival Triamcinolone (121, 122) . Their anti-angiogenic effect is a result of their anti-inflammatory properties, which includes the suppression of inflammatory cellular chemotaxis, the inhibition of synthesis of pro-inflammatory cytokines as well as direct suppression of vascular endothelial cell migration and proliferation (122-124) . Ashton N et al reported that moderate doses of systemic (IM) and subconjunctival steroids have remarkably decreased the corneal NV in rabbits and that subconjunctival injection was found to be more superior than systemic treatment, They also found that subconjunctival steroid injection has caused a remarkable reduction in the corneal opacity(125). Another study has shown that adding heparin to steroid can greatly improve its efficacy in reduction of corneal NV (126). However, the long term use of steroids can result in several complications such as posterior subcapsular cataracts, glaucoma and enhancement of infection especially herpes simplex and its inhibitory effect is incomplete (127).

#### **B) Anti VEGFs**

VEGF is the most fundamental molecule that promotes and controls major steps in the process of corneal angiogenesis. When hypoxia or inflammation occur, endothelial cells lining the limbal vessels together with corneal epithelial and endothelial cells release VEGF

(60). Anti-VEGFs will suppress the process of angiogenesis thus preventing and reducing the corneal NV formation.

**Ranibizumab (Lucentis®)** is a recombinant humanized monoclonal antibody directed against human VEGF-A. It is produced in *Escherichia coli* using recombinant DNA technology and has a molecular mass of 48 kDa and a single antigen binding site. Ranibizumab neutralizes all active forms of VEGF-A. It has been genetically engineered via a process of selective mutation to increase its affinity for binding and suppressing the growth factor (128). Ranibizumab was developed specifically for intraocular use and was approved by the FDA in 2006 for the treatment of neovascular age related macular degeneration (NVAMD) (129). The indications for ranibizumab have expanded to include macular oedema following retinal vein occlusion and diabetic macular oedema. Ranibizumab has greater pharmacokinetic properties than bevacizumab as it is a smaller molecule and hence has better corneal bioavailability (89).

A combined in vivo and in vitro study showed that ranibizumab had dual antiangiogenic mechanisms via simultaneous inhibition of blood and lymphatic vessels, highlighting its therapeutic role in corneal NV. A study in rabbits was conducted and showed a reduction of VEGF concentration in the bulbar conjunctiva, cornea, aqueous humor and iris following subconjunctival ranibizumab injections indicating high bioavailability (130).

Several studies were conducted for the clinical evaluation of ranibizumab. One study used topical ranibizumab as 1% solution, 4 times a day in eyes with stable NV. The results showed that ranibizumab is effective in controlling stable NV by narrowing of vessels but not by reduction of the corneal area invaded by NV (131).

Another randomized clinical trial compared subconjunctival and intrastromal injections of bevacizumab and ranibizumab. It was suggested that corneal NV management was better in the bevacizumab group than in those treated with ranibizumab (132). This was contradicted by another study which showed that subconjunctival and intrastromal ranibizumab injections were successful in treating a case with NV due to herpetic keratoconjunctivitis after failure to treat her with bevacizumab injections by the same route of delivery (133).

**Bevacizumab (Avastin®)** is a full-length humanized monoclonal anti-VEGF antibody that binds all VEGF-A isoforms thus blocking the VEGF-/VEGF receptor interaction thereby suppressing the role of VEGF in angiogenesis. It is a recombinant IgG1 antibody that is produced in Chinese Hamster Ovary mammalian cell expression system and its molecular weight is 149kD. It was initially designed as an anti-angiogenic therapy to treat solid tumours (134). In 1997, phase 1 trials of bevacizumab for the treatment of cancer was started and it was established that it had minimal toxicity (135). Phase 2 and 3 trials were carried out later and their results led to the approval of the U.S. Food and Drug Administration (FDA) of bevacizumab as therapy of colon cancer along with chemotherapy (136, 137).

Although bevacizumab was initially approved for treating colorectal cancer, it has been used off-label to treat several ophthalmic conditions (138, 139). It has been first introduced as an intravitreal injection for treating ocular diseases in July 2005 (140).

Several clinical cases have been published showing dramatic resolution of macular fluid in central retinal vein occlusion and NVAMD (140). Other studies showed the ability of bevacizumab to penetrate the retina after being injected intravitreally (141, 142). Bevacizumab has also been used for the treatment of other ophthalmological conditions such as juxtafoveal telengectasia (142-144), myopic choroidal neovascularization (CNV) (145, 146) and CNV secondary to angioid streaks (147, 148) and has shown promising results. Many retina specialists have also noted impressive results in the setting of CNV, proliferative diabetic retinopathy, neovascular glaucoma, diabetic macular oedema, retinopathy of prematurity and macular oedema secondary to retinal vein occlusions (149).

The comparison of Age related Macular Degeneration Treatments Trials is one of the largest studies that has been conducted with the aim of evaluating the relative efficacy and safety of treatment of NVAMD. It was concluded that Avastin and Lucentis had the same effect on visual acuity over a 5 year period. There were no differences between the 2 drugs in rates of death or arteriothrombotic events (150).

A systematic review and meta-analysis was done with the objective of evaluating the efficacy and safety in treatment of ocular neovascularization by bevacizumab versus ranibizumab. The results showed that bevacizumab has equal efficacy and safety to ranibizumab in treatment of ocular neovascularization (151).

Anti-VEGFs have been first used to treat corneal neovascularization in a rat model. Corneal injury was induced in order to stimulate VEGF release, and the resulting NV were subsequently blocked by anti-VEGF antibodies (85). Another animal trial conducted later demonstrated that corneal vessels secondary to herpes simplex virus were reduced by suppressing VEGF via the delivery of a murine soluble VEGF receptor protein, mFlt (1–3)-immunoglobulin G (152). These studies led to the hypothesis that anti-VEGFs might be an effective treatment option for active corneal NV (153).

Several studies have been conducted to evaluate the efficacy and safety of bevacizumab when used as subconjunctival injections to treat corneal NV. They showed that the treatment of active corneal NV with subconjunctival injections of bevacizumab could be of great benefit as they noted either a regression or stabilization of the corneal NV and this effect was also associated with improved lipid deposition in cases with lipid keratopathy. The intervention was well tolerated without adverse ocular or systemic effects (154-158). However, there has been reports that it could delay epithelial wound healing (159). This was contradicted by another group who used similar doses of bevacizumab (1%, twice daily for 2 months) but instilled the drops in the reservoir of a Boston Ocular Surface Prosthesis. This indirect drug application may have resulted in quite low drug concentrations at the corneal surface (160).

Other studies also reported improved mean visual acuity at the final follow up and also reported that the injections were beneficial and effective in high-risk keratoplasty, with regards to preventing corneal NV after keratoplasty with improvement of graft survival (161-164).

Bevacizumab 1% eye drops used 4 times/day showed remarkable decrease in superficial and deep stromal neovascularization in a number of pilot studies (165, 166) (167).

## **Q) Topical therapeutics**

New topical therapeutics are being developed and might be used clinically in the future for treatment of corneal NV (168). These are protein phosphatase magnesium dependent-1, melatonin, omentum, 0.5% ketorolac tromethamine, Rho-associated protein kinase inhibitors (AMA0526), prospero homeobox 1 and aloe vera (169-176).

## **1.3.2 Surgical treatment**

### **A) Laser photocoagulation**

Argon laser has been first described by Cherry PM in treating corneal NV on 4 human patients. There was 1 success, one partial regression of NV and two failures (177). In 1976 Cherry and Garner used 11 rabbits to test the impact of argon laser in obliterating corneal vessels. They concluded that the obliteration of corneal vessels by argon laser was successful as long as there was no stimulus for vascularisation. There was slight iris damage in their experiment but they did not think that this could necessarily contradict the laser usage on humans (178). The argon laser was used further in treatment of lipid keratopathy by Marsh RJ. The lipid deposition was reduced in more than half of the cases, however there were complications such as iris damage, peaking of pupil and corneal thinning (179). Yellow dye laser 577 nm was used by Baer and Foster to treat corneal NV in 25 eyes of 23 patients (180). They reported a significant decrease in the vascularised region from 46.4% to 27.3% in 9 patients who had lipid keratopathy. They also reported reversal of graft rejection and a marked reduction in the vascularisation area (68% decrease in the vascularised area). However, patients with severe corneal neovascularisation did not show improvement.

### **B) Photodynamic Therapy (PDT)**

PDT is a potential treatment for the management of corneal NV. The idea of PDT is to administer systemic porphyrin derivatives which will build up in the replicating endothelial cells. This is followed by laser energy application which will activate those derivatives resulting in the release of cytotoxic oxygen free radicals leading to corneal vessels obliteration (181-184). Several porphyrin derivatives were used such as verteporfin (185) and diheamtoporphyrin ether (182). A clinical trial was carried out using PDT with

verteporfin to treat corneal neovascularisation and showed that it is a safe and effective method of reducing corneal neovascularization (186) . Other trials used a combination of PDT and subconjunctival bevacizumab and showed that this combination can effectively inhibit corneal neovascularization (187, 188).

### **C) Fine needle diathermy (FND)**

Fine needle diathermy(FND) is a method for occluding corneal vessels that has been developed by Professor Harminder Dua (189). FND was found to be superior to the methods mentioned earlier in terms of being an effective, simple and inexpensive method of occluding mature vessels. FND can be used as a preconditioning and/or post-conditioning treatment of high-risk corneal grafts (190). It can be one element of an overall plan to reduce the risk of graft rejection or deal with refractory episodes of rejection (120).

The procedure involves the insertion of stainless steel 3/8 needle attached to a 10–0 monofilament black nylon suture close to the limbus, parallel to and at approximately the same depth as the blood vessel(s) to be occluded than the needle is touched with a monopolar cautery at low power (Covidien Force X) to produce the coagulation (120).

Several studies were carried out to evaluate the safety and efficacy FND for occlusion of corneal vessels (189, 191). They concluded that FND is a safe, inexpensive and effective treatment option for the occlusion of corneal blood vessels both before and after penetrating keratoplasty. It can be done repeatedly and is also beneficial in stopping the progress of lipid keratopathy. However, it was noted that the deposited lipids did not regress any faster by the occlusion of the corneal vessels (189).

In 2014, a study was carried out by Faraj et al in the same centre where FND technique was first described more than a decade ago(120).

The study has shown that FND was the method of choice in occlusion of active old and mature vessels. It was also found that FND was very effective in treating lipid keratopathy.

Another important conclusion that was drawn out from the study, was that active young vessels were usually a sign of underlying continuous pathology which keeps on inducing more vascularisation. It was pointed out that such eyes will require treatment with anti-

VEGF subconjunctival injections or eye drops and several studies have been conducted to assess the efficacy and safety of combined FND with adjuvant anti-VEGF bevacizumab eye drops, subconjunctival or intrastromal injections in both adults and children (192, 193).

The studies concluded that applying combined FND and bevacizumab is both successful and safe and that it improves the corneal transparency as well as prepares the cornea for future keratoplasty.

## **1.4 Consequences of corneal vascularization**

In the presence of corneal pathology, NV's are necessary to mount a host defence reaction, promote healing of the cornea, get rid of toxic material and transfer medications to the inflammation site(194, 195). However, when the pathology is no longer active, the blood vessels formed may remain in the cornea and the vessels are tortuous, leaky and wide resulting in infiltration of corneal stroma with inflammatory cells and cytokines due to loss of pericytes and separation of endothelial cells. Keratocytes proliferate and transform into fibroblasts which secrete fibrin leading to scarring. All these events will eventually lead to corneal opacity and haze which will consequently reduce vision. This opacification is a result of circulation of blood cells in the blood vessels, changes in the spaces between stromal collagen, chronic or recurrent inflammation, scarring, higher order aberrations caused by irregular vessel wall and lipid leakage and deposition in the cornea (50),(49, 196). Lipid keratopathy was related to mature and partially regressed vessels. The most common aetiology of lipid keratopathy was found to be secondary to viral keratitis (47).

Corneal vessels promote easy lipid access to the cornea(197). Lipids become deposited by lipid overloaded fibroblasts in the corneal stroma in the form of droplets of cholesterol crystals(198). Corneal NV may as well cause bleeding intraoperatively and hyphema. Corneal NV affect the corneal immunological privilege which may eventually lead to graft rejection (199, 200)as it provides an efferent arm in the immune reflex arc and accelerates immune reaction by facilitating access for immune effector cells to the graft and thereby resulting in corneal rejection(49, 50). Lymphatic vessels that are microscopically undetectable have been detected with blood vessels in high-risk vascularized corneas (201). These lymphatic

vessels facilitate the access of host and donor antigen-presenting cells (APCs) to regional lymph nodes thereby accelerating sensitization to the graft antigens and causing further disruption of the immune privilege status of the cornea. Lymphatics represent the afferent arm of the immune reflex arc (201-203). A meta-analysis of 19 studies reporting on a total of 24,944 grafts undergoing keratoplasty was done. It was found that the chances of graft failure due to rejection becomes higher with increasing number of corneal quadrants that contain corneal NV before keratoplasty (44).

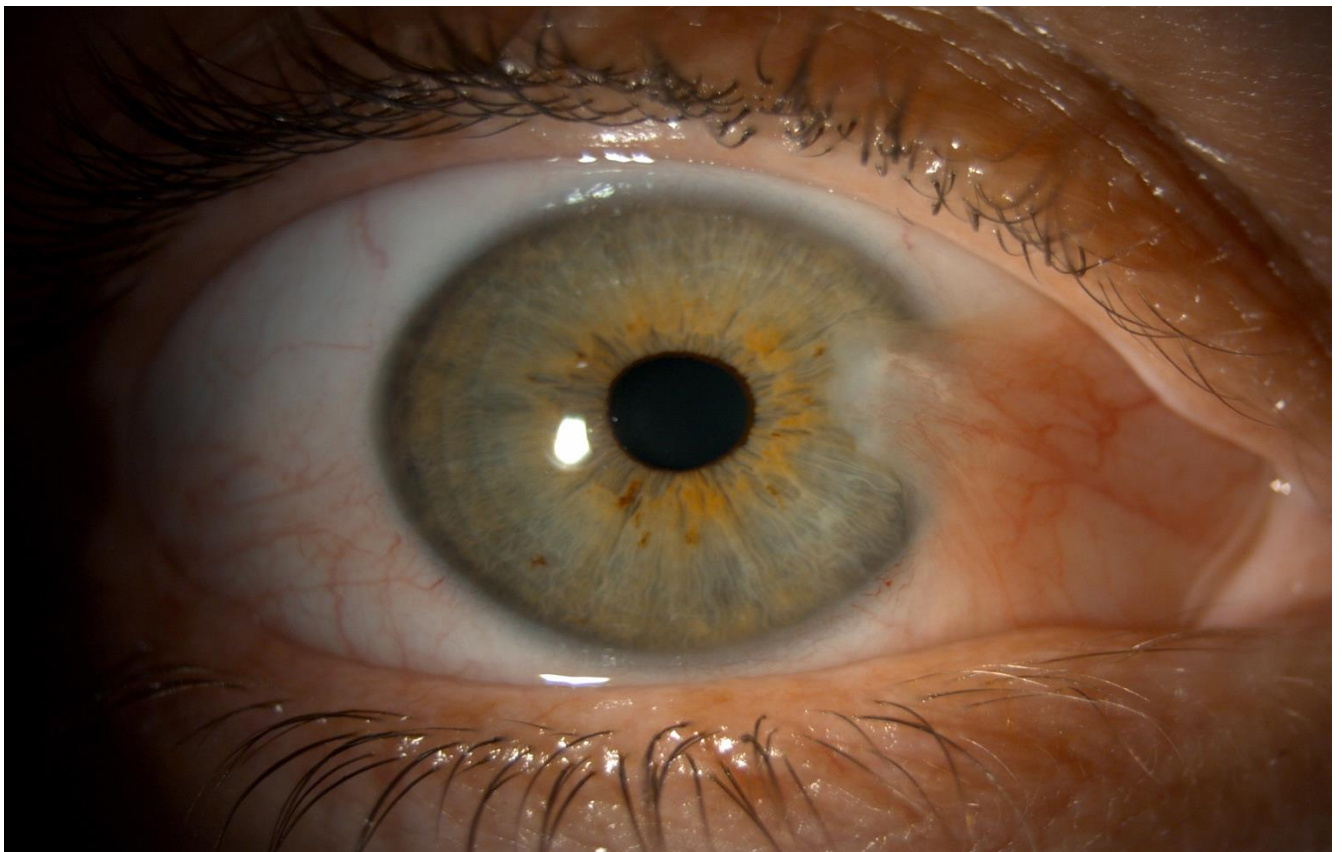
## **1.5 Pterygium: demographics, role of vessels and vascular factors**

Pterygium is a potentially sight threatening condition that originates from the bulbar conjunctiva as fleshy fibrovascular tissue and grows centripetally most often from the nasal conjunctiva although it can occur temporally. It can be bilateral and asymmetric with one eye affected by a larger pterygium, encroaching on the cornea which could result in corneal scarring, chronic ocular surface inflammation, irregular astigmatism as well as restriction of ocular motility (204-206). Although the etiology of pterygium remains an enigma and is so complex, environmental factors such as chronic exposure to ultraviolet light, dryness, genetic and immunological factors play a big role in its formation (207-209). It is more prevalent within the peri-equatorial latitudes” 37 degrees north and south”, where the ultraviolet radiation intensity is strongest. Recently, other important factors such as fibrovascular proliferation, inflammation and vascularisation and localised stem cell deficiency have been implicated in the pterygium pathogenesis and progression (210, 211). Pterygium can be classified as quiescent or progressing and active (212, 213).

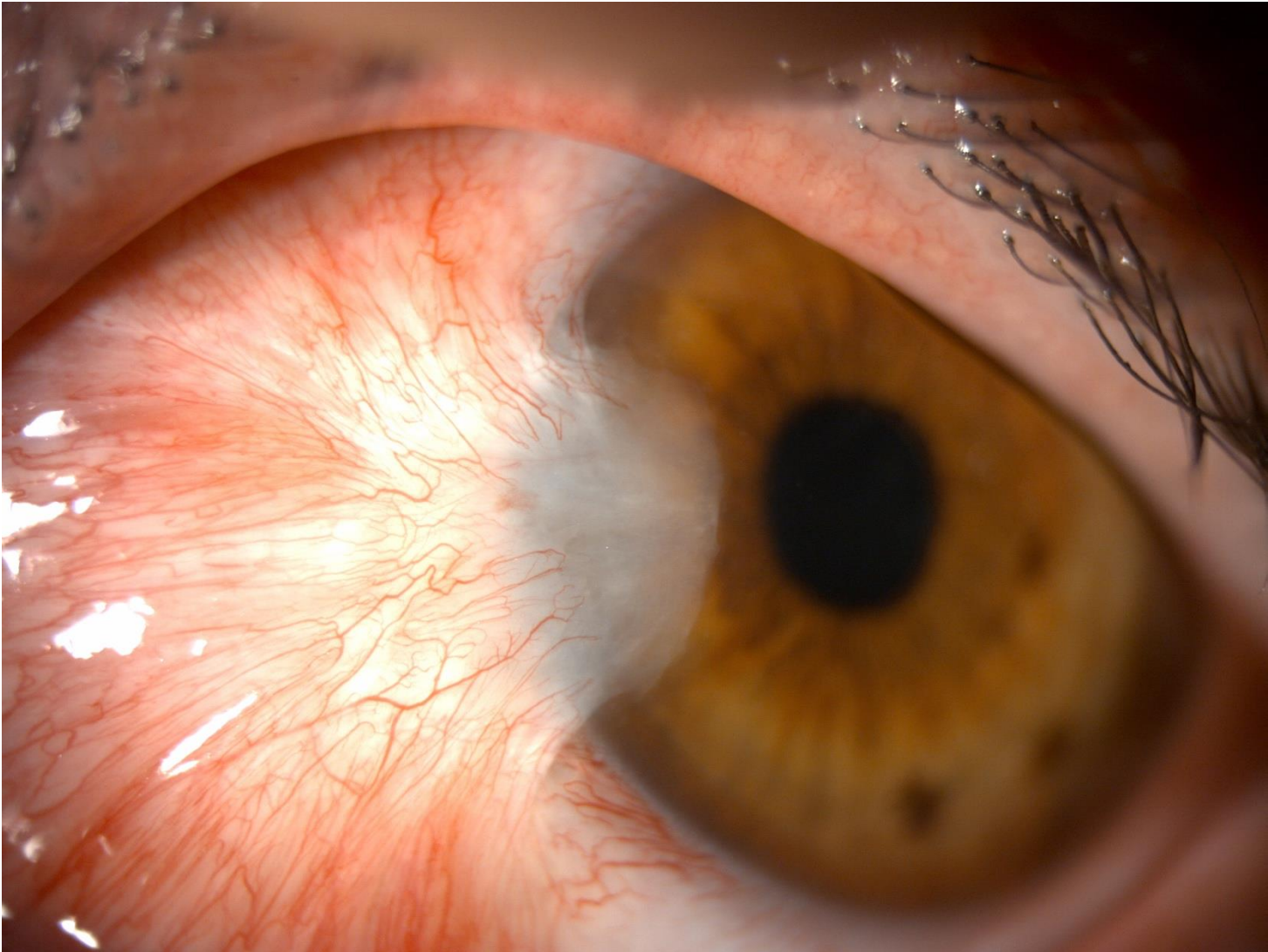
Many studies have also demonstrated that the pathogenesis and recurrence of pterygia is highly attributed to the increased expression of molecules such as vascular endothelial growth factor (VEGF), transforming growth factor, platelet derived growth factor and basic fibroblast growth factor(214-216). The most prominent of these was found to be VEGF molecule and it was found to be highly increased in pterygia as well as being involved directly or indirectly in formation of pterygia by inducing the formation of blood vessels. It has also been postulated that the development of pterygia depends on a disturbed



angiogenic stimulator to inhibitor ratio (216-219). Moreover, further immunochemistry studies have shown that immunostaining of VEGF in pterygial sections was much stronger than normal conjunctival sections(216). Based on these findings, several clinical studies aimed to reduce the vascular density and prevent its recurrence using anti-VEGFs (207, 210). In many of these cases, there was a brisk reduction of inflammation and vascularization when pterygia were injected subconjunctivally with anti-VEGF which gives more evidence of the role of VEGF in pterygium angiogenesis(208, 210); (216);(219). Studies have also shown that in anti-VEGFs suppress fibroblast proliferation and induce fibroblast apoptosis in addition to its effect on angiogenesis. In one study, injection of bevacizumab with a concentration greater than 7.5 mg/ml had a remarkable effect on the anti-fibrotic effect, changes in morphology, and reduction in the collagenase activity of human Tenons' fibroblasts cultured from both primary and recurrent pterygia (220, 221)(Figures 1.4, 1.5).



*Figure 1.4: Slit-lamp anterior segment photograph of a primary pterygium*



*Figure 1.5: Slit-lamp anterior segment photograph of a recurrent pterygium*

## **1.6 Pterygium recurrence**

Recurrence of pterygium is the most common complication after surgical excision and it has been found that recurrent pterygia are more difficult to manage than primary ones as the underlying cornea could be thinner(222). Several factors raise the chances of recurrences after surgery such as young age, family history and concurrent ocular surface inflammation (223, 224). According to a grading system developed by Tan et al, a fleshy-like aspect of the pterygium is correlated with high recurrence rates, especially after bare sclera excision (223). Race plays an important role as well in defining the recurrence rates. Hispanic and black race have a higher rate of recurrence compared to white (225). 50% of the

recurrences appear in the first 4 months while 97% appear within the first 12 months (226).

Surgical technique of pterygium excision also attributes to the rate of recurrence. High recurrences rates were reported in patients who had pterygium excision by bare sclera technique with no adjuvants or radiotherapy alone and this was attributed to the fact that small tissue residues may be left in the scleral bed leading to higher recurrence rates which ranged from 38 and 88 % in many publications (227-229). Adjuvant amniotic membrane transplantation has also high rate of recurrence which can be up to 28.1 % but no postulations were given regarding the high recurrence rate (230).

The recurrence of pterygium has been also attributed to fibroblast migration and proliferation, therefore 5 fluorouracil is being injected subconjunctivally in the recurrent pterygium body to reduce or inhibit the activity of fibroblasts (231).

## **1.7 Management of primary pterygium**

### **1.7.1 Medical**

#### **A) 5 Fluorouracil (5 FU)**

5 fluorouracil (5FU) is a pyrimidine analogue that inhibits thymidylate synthetase and hence DNA and RNA synthesis, suppresses proliferating fibroblasts and promotes apoptosis of Tenon's fibroblasts. It is widely used in ophthalmology especially in glaucoma surgery with favourable outcomes due to its anti-fibrotic characteristics.(232, 233). A number of pilot studies were conducted to study the efficacy of intra-lesional injection of 5FU in primary pterygium. They reported cosmetic and clinical improvement. One study reported no statistically significant changes of corneal astigmatism after the injections (234, 235).

#### **B) Anti-VEGF alone (no surgery)**

### **Injections**

Several studies demonstrated that vascularization and inflammation were rapidly controlled by subconjunctival bevacizumab injections in many patients, and this provided more

evidence for the role of increased VEGF in pterygium (153, 208, 215, 216, 219, 236-238). However, some reported that the changes were clinically insignificant as they were clinically not obvious with no beneficial effect on the regression of the vessels (239, 240) and one study reported transient regression and irritation for only one week (209).

## **Topical**

One study used 2 different doses of topical bevacizumab and compared them to a control group and reported good results in the group with higher bevacizumab dose. They had recurrences in both the lower dose group and the control group (241).

### **1.7.2 Surgical excision**

There are several techniques for surgical management of primary pterygium.

**Bare sclera technique:** This technique involves complete excision of the pterygium head, removal of some of the surrounding nasal bulbar conjunctiva as well as excision of Tenon's capsule resulting in a bare sclera. The recurrence rate for this method is quite high (30% to 80%). That is why some of the surgeons will combine this technique with other adjunctive therapies to reduce the recurrence rate (229, 242, 243).

**Aminiotic membrane graft Transplantation (AMT):** Human aminiotic membrane inhibits inflammation and formation of fibrovascular tissues, provides numerous growth factors and promotes proliferation of epithelial cells without the risk of immunological reactions (244, 245). Due to these properties, it has been used as a graft to cover the bare sclera after pterygium excision, typically with the basement membrane facing up and the stroma facing. It has the advantage of short surgical time, fast recovery, less post-operative pain and better cosmetic outcome following surgery (as no donor site is injured)(246). However, it has higher recurrence rates when compared to the conjunctival autograft technique (247, 248). AMT effectiveness is improved by using fibrin glue to promote aminiotic membrane graft fixation to the underlying sclera. It is useful in situations such as covering large conjunctival

defects after pterygium excision and to preserve conjunctiva in glaucomatous patients. Combining AMT with intra-operative Mitomycin-C improves the outcome of the surgery and reduces the recurrence rate (249) . AMT has been used in combination with conjunctival autograft to reduce the recurrence rate especially in cases with large or severely inflamed pterygia or persistent recurrence (250).

**Conjunctival autograft:** This technique involves covering the bare sclera by using autologous conjunctival tissue. The free graft is obtained from the superior bulbar conjunctiva and sutured or more preferably, glued to the bare scleral defect after pterygium excision. Additional use of intra-operative Mitomycin-C reduces the recurrence rate (251). Recurrence rates range from 3.3% to 13.5% (252-255). Higher recurrence rates have been reported in cases of recurrent pterygium (31.3% to 33.3%) (253). It is considered to be one of the most effective method for management of pterygium (256). Conjunctival autografts can be fixed to the scleral bed using sutures or fibrin glue. Sutures are associated with inflammation, discomfort and granuloma formation (257). Fibrin glue is used as an alternative and remains the most effective method for conjunctival autograft fixation in pterygium surgery due to reduced operative time, reduced postoperative discomfort and lower recurrence rate (258).

### **Conjunctival transpositional flap**

Rotational conjunctival flaps have been employed since the 40's to cover the pterygium excision site with different recurrence rates ranging from 3.2% as reported by McCoombes et al. (259) to 33.33% as reported by Alpay (227). Bilge compared this technique to conjunctival autografting and reported that both procedures had low recurrence rates without severe complications (253). This procedure is useful in patients with insufficient conjunctiva (260).

Mitomycin C (MMC) is an antineoplastic drug that has been suggested as an adjuvant for pterygium surgery in the 60's (261). Intraoperative application of 0.02% MMC had a positive outcome as it has been reported that recurrence in primary pterygium was as low as 7% after use of MMC while rates after recurrent pterygia were reduced to 9%. When applied for 5 minutes with bare sclera technique, the recurrence rate was as low as 5% (262). When

combined with rotational conjunctival flap approach, no differences have been noted between postoperative 0.02% MMC drops for 5 days or intraoperative MMC at different dosages (263-268). However, it has been shown that combining intraoperative MMC with conjunctival autografting is associated with remarkably lower recurrence rates regardless of the application technique or dosage (269-271). The most common used concentration of MMC is 0.02% (0.2 mg/ml) and the most common application time length is three minutes (229).

### **1.7.1.3 Anti-VEGF as Adjuvant to surgery**

Numerous clinical trials studied the effect of bevacizumab as an adjunct to surgery, however the trials employed different surgical techniques.

Two studies were conducted using bevacizumab as an adjunct to pterygium excision using bare sclera technique. One reported that subconjunctival bevacizumab injections before and after surgical excision, were a safe and valid option in preventing recurrence after bare scleral procedures (272), however the other study showed no changes and that was attributed to the low dose of bevacizumab injected.

Trials have demonstrated reduced vascularity of pterygium as well as reduced recurrence rate after using subconjunctival bevacizumab injections with conjunctival autografts for primary pterygium (273-275).

Karlezli et al. (276) used topical bevacizumab after pterygium excision with conjunctival autografting for 1 month after surgery and compared to them to a control group who were only given steroids and antibiotics and reported no significant difference in the recurrence rate between the two groups after a follow-up of at least 2 years. Kasetuwan et al. (277) had similar results.

## **1.8 Management of recurrent pterygium**

### **1.8.1 Medical**

## A) Steroids

Local subconjunctival steroid injections have shown efficacy in about 50% of the cases of recurrence but no large randomized controlled clinical trials have been carried out to confirm their efficacy (278) .

### **B) 5 fluorouracil**

The effective role of 5FU in halting pterygium recurrence and further progression has been studied by many (279, 280).

Pherwani at al. (281) reported a single case of multiple post-surgical recurrences of pterygium in an Afro-Caribbean lady who was successfully treated with intra-lesional 5FU injections following the fourth operation. Other studies have also reported the safety and efficacy of 5FU in limiting the progression and inducing the regression of recurrent pterygium and that the number of injections can be tailored according to clinical need. They have also shown that by avoiding repeated surgery for recurrent pterygium by injecting 5FU, less fibrosis occurred and the risk of intra and post-operative complications has decreased (231, 282, 283).

### **C) Anti-VEGF (no surgery)**

Subconjunctival injections of bevacizumab were used safely and effectively for treatment of recurrent pterygia (207, 236, 284, 285).

## **1.8.2 Surgical excision**

Recurrent pterygia are more difficult and challenging to excise due to the scarring already present which increases the risk of damage to the extraocular muscles and obliterates the tissue planes. In cases of extensive scarring, primary closure techniques are unreliable. Pedicle or sliding flaps can be used (278).

Surgical management is the first line management for aggressive pterygium recurrences or recurrent pterygia that extend more centrally than the initial pterygia, with 4 to 6 months



form the primary surgery. Conjunctival flaps, conjunctival or limbal autograft transplantation have been used for management of recurrent pterygium (286).

### **1.8.3 Anti-VEGF as Adjuvant to surgery**

In 2013, Ozgurhan et al. used topical application of bevacizumab 4 times daily for 2 months after excision of recurrent pterygium. This technique had less recurrence rate compared to the control group (287). Similarly, Nava Castaneda et al. (275) reported reduced vascularized area as well as reduced corneal opacification area in all recurrent pterygia and the effect remained until the end of the study.

## **1.9 Limbal stem cell deficiency**

Limbal stem cell deficiency (LSCD) could be congenital as in cases of aniridia or acquired secondary to ocular burns (chemical and thermal), chronic immune-mediated inflammatory diseases (Ocular cicatricial pemphigoid and Stevens Johnson syndrome), contact lens related pathology and ocular surface malignancy. Ocular burns have the most devastating impact in relation to visual impairment, quality of life and ability to work. LSCD has several sequelae which include superficial and deep corneal neovascularisation, recurrent and /or persistent epithelial defects, development of fibrovascular pannus, stromal scarring, conjunctivalization of the cornea, symblepharon formation and ultimately corneal melting (288, 289).

There are several management options for LSCD and it all begins with a thorough assessment of the diagnosis, patient factors and the extent of deficiency. The diagnosis depends mainly on the history and the clinical signs of which conjunctivalization of the cornea is the hallmark. Impression cytology and/or biopsy and *in vivo* confocal microscopy are done to demonstrate the conjunctival epithelial cells and goblet cells on the cornea and these procedures can be performed to complement the clinical diagnosis (6, 288-291). LSCD can be partial or total, unilateral or bilateral (290).

Ideally all abnormalities related to the lids and fornices should be addressed and intraocular pressure should be controlled before considering limbal transplantation.

Partial SC deficiency with conjunctivalized epithelium on the cornea; where the visual axis is not involved, requires no surgical intervention. When the visual axis is involved and vision is affected, the first line of management should be Sequential Sector Conjunctival Epitheliectomy (SSCE). SSCE involves brushing off the conjunctival epithelium away from the corneal surface so that the healthy corneal epithelium from the surviving limbus can repopulate the denuded area. As the cells derived from the corneal epithelium cover the denuded area, the conjunctival epithelial cells will be also invading the corneal surface, usually faster than the corneal epithelial cells. That is why brushing should be repeated every 24 to 48 hours as often as required to keep the advancing conjunctival sheet in check and to allow the corneal surface to be covered by cells migrating from the remaining intact limbal epithelium.

Partial SC deficiency with fibrovascular pannus over the cornea may require sector limbal transplant, although SSCE could help (292, 293).

For cases with total unilateral SC deficiency, the procedure of choice is auto limbal transplantation (AL) (17, 294). In total bilateral SC deficiency, the only treatment option would be the use of allografts from a living donor (LRD) or a cadaver donor (CD). Living non-related donor tissue can be potentially used as well. The advantage of using autologous and LRD tissue is that they are very fresh and of younger age, on the other hand CD is available in abundance but is usually between 24 to 48 hours old (post death). Screening tests for HIV, HTLV, syphilis and Hepatitis B and C must be done for all donors (294-296). Both AL and LRD should not be considered in the acute stage of the disease as there is ongoing inflammation. CD is associated with very high failure rate, systemic immunosuppression is required in LRD and CD transplantation for at least 18 months after the transplantation or from the last rejection episode (297-299).

SSCE can also be applied in association with AL transplants and LRD transplants as often the conjunctival epithelium from the peritomised conjunctiva migrates at a rapid pace and crosses the limbus to cover the corneal surface resulting in conjunctivalisation of the cornea. SSCE is used successfully to prevent this from occurring (293, 294, 300). However there are limitations in these circumstances which are bleeding from surface vessels, pain and multiple visits required for treatment and observation. Based on that Dua et al. (301) have devised an approach, using amniotic membrane, to redirect conjunctival epithelium on

to the membrane allowing the corneal surface to be covered by explant-derived epithelium, thus completely avoiding admixture of limbal/corneal and conjunctival epithelium and avoiding the need for SSCE. This procedure has been termed amnion-assisted conjunctival epithelial redirection (ACER) and is a useful adjuvant in the management of patients undergoing limbal transplantation for LSCD.

Exvivo expansion of limbus derived cells methods are an essential option in the surgical management of total LSCD whether unilateral or bilateral. These methods will be discussed in details in Chapter 5.

## **1.10 Retinal anatomy**

### **1.10.1 Retinal layers**

The retina is the neurosensory part of the eye. It is formed of multiple layers of photoreceptors and neuronal cells with a complex structure. The adult posterior pole, also known as the anatomical macula, is about 4.5 to 6 mm in diameter and lies between the superior and inferior temporal arcades and the fovea lies in its center . The macula, also known as the anatomical fovea centralis, is located approximately 3 mm temporal to the optic disc and is about 1.5 mm in diameter. The macula has a disproportionately big density of cones which are responsible for hyperacuity and colour differentiation. The fovea represents the retinal region of greatest visual acuity. It is thinner than the rest of the retina and is seen as a dip (foveal pit) in cross sectional view. The central 500 µm of the fovea contains no retinal capillaries (the foveal avascular zone) and the fovea receives its blood supply from the choriocapillaris. The foveola has the highest density of cone photoreceptors (199,000/mm<sup>2</sup>). The foveola consists of cone photoreceptors and some Muller cells (302, 303).

The peripheral retina is the part of the retina that lies outside the temporal retinal arteries. The peripheral retina is made of one layer of ganglion cells. The long posterior ciliary arteries and nerves mark the horizontal meridian, while the ampullae of the vortex are located posterior to the equator (Figure 1.6).

## **Retinal Pigment Epithelium (RPE)**

There are about 3.5 million RPE cells and they interdigitate with the outer segments of the photoreceptors (304). The density of RPE cells is greater in the fovea (5000 cells/ mm<sup>2</sup>) than in the periphery (2000 cells/ mm<sup>2</sup>) RPE cells contain melanin and that is the reason they are pigmented. RPE cells are essential for recycling of the visual pigments necessary for the photoreceptor to function normally as well as removing the debris from the degenerating photoreceptors, pumping fluid out of the retina, forming the outer blood retinal barrier due to the tight junctions between adjacent RPE cells (preventing flow of fluid out of choroidal blood vessels into the retina) and secretion of anti-angiogenic factors. RPE cells lie on a thick basement membrane called Bruchs membrane. Bruchs membrane contains collagen 5 and probably originates from the overlying RPE cells and the underlying choriocapillaris. It acts as a water impermeable membrane between the overlying RPE and retina and the underlying vascular choroid (303).

## **Photoreceptor layer**

Photoreceptors act as the sensors of the visual system and are responsible for converting photons to a nerve signal in a process called phototransduction (305). It is the only light sensitive part of the neuroretina. The nerve signals generated will be transmitted by all the other layers of the neuroretina. There are approximately 4 to 5 million cones and 77 to 107 million rods in the human retina (305-307). The foveola contains only cones, whereas rods are dominant in the rest of the fovea and the peripheral retina. Each photoreceptor is made of an outer segment, inner segment, a nucleus, an inner fibre and a synaptic terminal (308). The outer segment contains photopigment that captures the photon. The outer and inner segments are connected by non-mobile cilia. The inner segment is full of mitochondria that produces ATP and rough endoplasmic reticulum for synthetic activity as well as microtubules for transport within the cell. The nucleus contains nonmitochondrial DNA. The inner fibre acts as the axon of the photoreceptor cell and is responsible for the transmission of photoreceptors signals to the outer plexiform layer via its synaptic terminals.

## **External Limiting Membrane**

The external limiting membrane is not a real membrane, it is made of junctional complexes between adjacent Muller cells as well as between Muller cells and photoreceptor cells. The subretinal space is a potential space between the outer blood retina barrier and the external limiting membrane (309, 310).

### **Outer Nuclear Layer**

The outer nuclear layer is made of the nuclei of the photoreceptor cells and is thickest in the foveolar area (305-307).

### **Outer Plexiform Layer (OPL)**

In the OPL, photoreceptor cells of the outer nuclear layer form connections with the horizontal and bipolar cells of the inner nuclear layers. The OPL consists of 2 parts: the axons of photoreceptor, bipolar and horizontal cells and their synaptic connections (307, 311).

### **Inner Nuclear Layer**

This layer contains the nuclei of five different types of cells: the bipolar, the amacrine, the horizontal, the interplexiform and Muller cells. The amacrine cells face the inner plexiform layer while the horizontal cells are situated along the outer limit of the inner nuclear layer facing the OPL (307, 311, 312).

### **Inner Plexiform Layer (IPL)**

The IPL contains the connections between amacrine, bipolar and ganglion cells. The IPL is further divided into six layers which is imperative for the processing of the photoreceptor input through highly specialized interactions between the bipolar, amacrine, and ganglion cells in each of the six layers of the IPL (313).

### **Ganglion cell Layer**

There are 1.2 million ganglion cells in in the ganglion cell layer in addition to other cells including astrocytes, pericytes and endothelial cells. The ganglion cell layer is thickest in the perifoveal macula where it is made of 8 to 10 rows of nuclei and becomes only one raw

outside the macular area. It is not present in the foveola. The small midget and larger parasol cells make up 80% of the ganglion cell layer (306, 307, 313).

### Nerve Fibre Layer

The nerve fibre layer has the ganglion cell axons travelling within it towards the optic nerve head. The nerve fibre layer is thick towards the disc due to the convergence of all retinal ganglion axon fibres on the optic disc and becomes thinner towards the periphery. The axons are associated with astrocytes and are separated into small bundles by the cellular processes of Müller cells and the internal limiting membrane (314, 315).

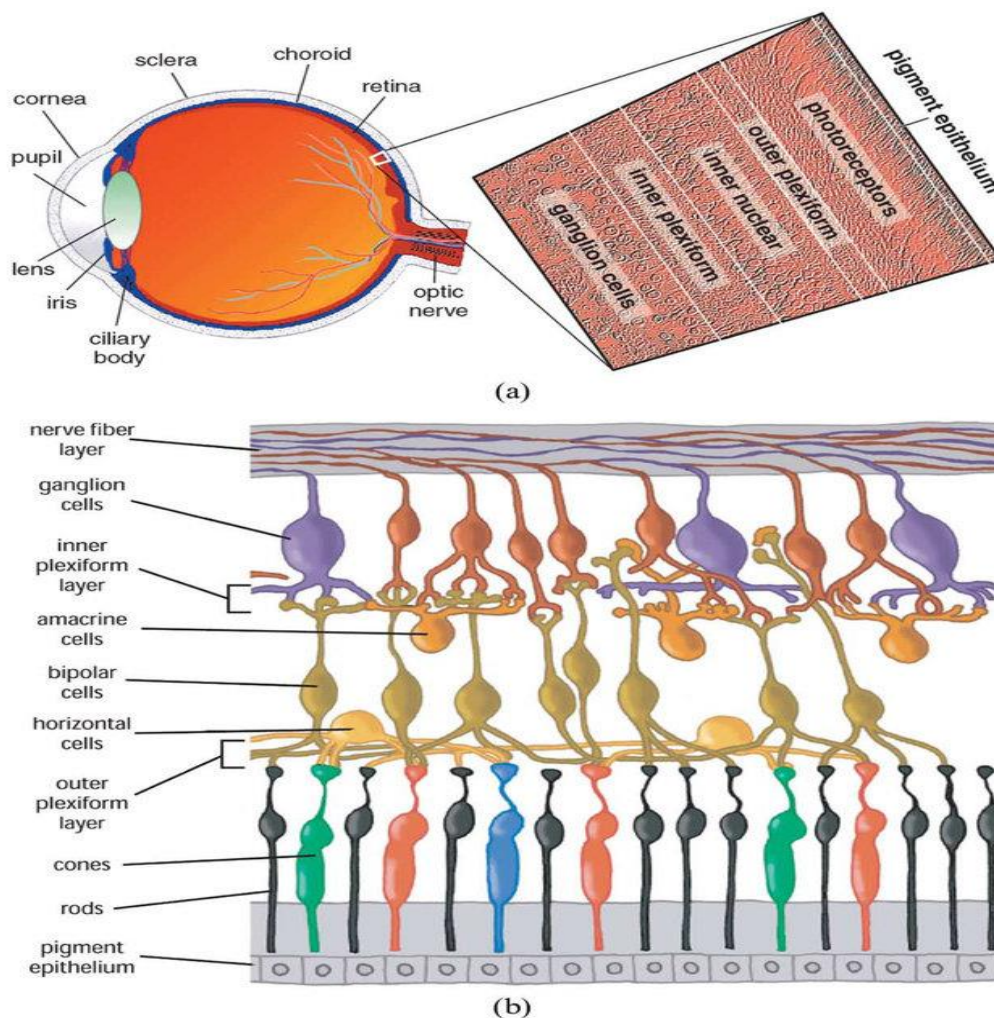
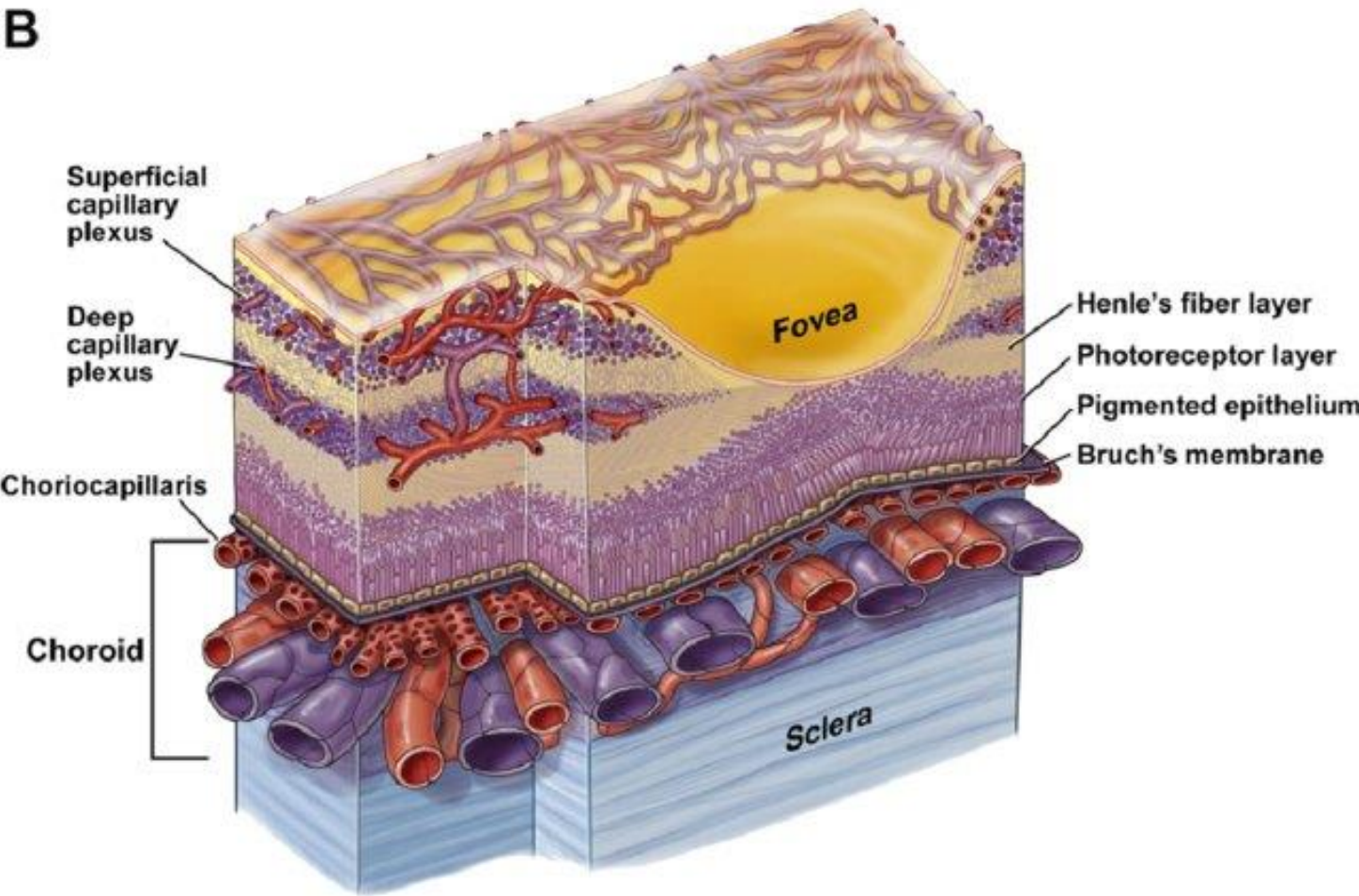
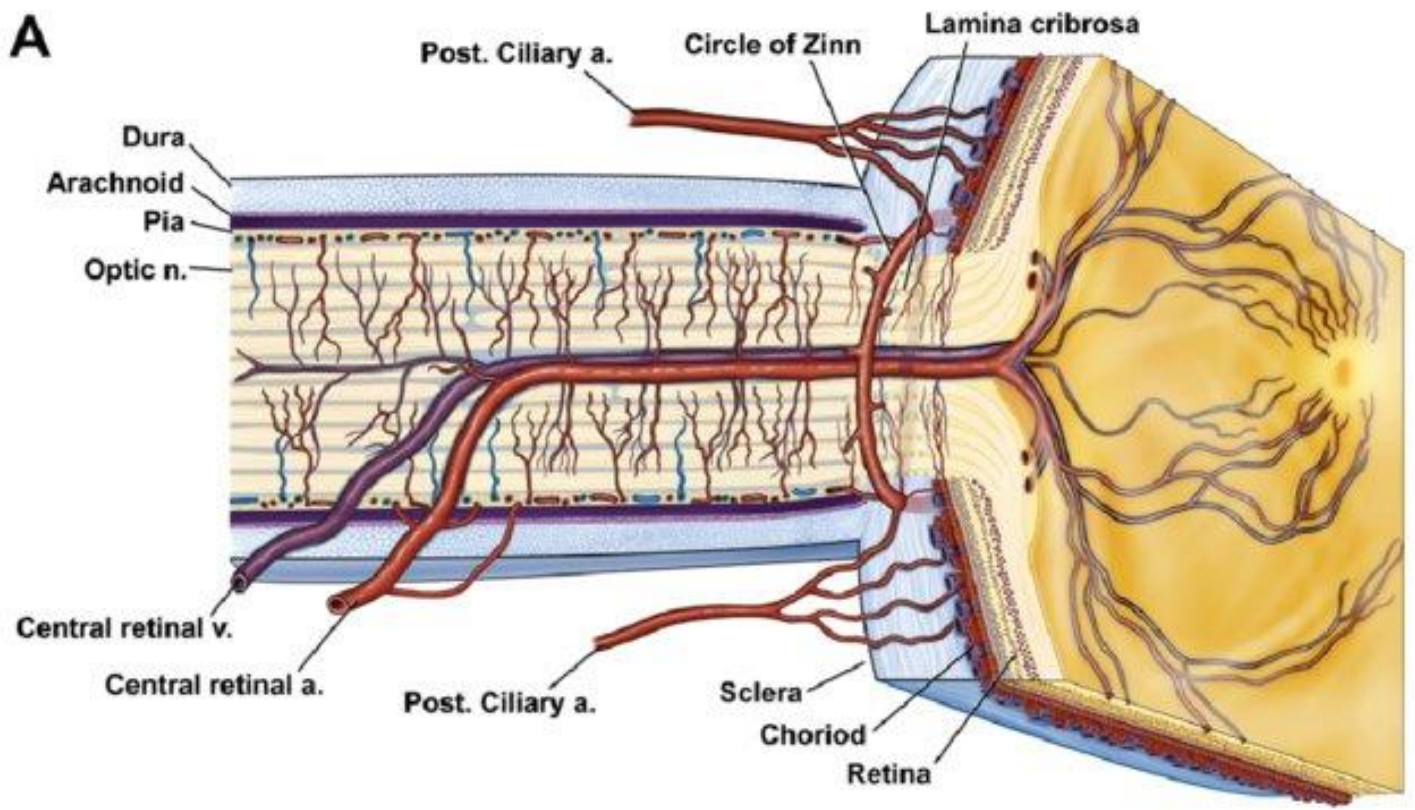


Figure 1.6: Illustration of retinal layers(adapted from retinal imaging and image analysis, biomedical engineering, Michael Abramoff et al, 315)

## 1.11 Retinal vascular structure and blood supply

The inner two thirds of the retina receives its oxygen supply and nutrients from the retinal vascular circulation via a network of blood vessels that emanates from the central retinal artery at the optic nerve head. The central retinal artery is a branch from the ophthalmic artery which is ultimately a branch of the internal carotid artery. The central retinal artery branches into four arterioles at the optic nerve head which further subdivide to supply each retinal quadrant via a network of capillaries. Each arteriole is associated with a corresponding venule which carries deoxygenated blood back to the optic nerve head and into the central retinal vein. The choroidal circulation supplies the outer one third of the retina (photoreceptor cell bodies, photoreceptor inner segments, and photoreceptor outer segments). Each person's retinal vasculature is said to be unique and may provide a form of finger print because of the multiple subdivisions of each retinal vessel (316)(Figure 1.7).







*Figure 1.7: Anatomy of ocular circulation (a-artery, b-vein, n-nerve). A, Cut away drawing along the superioinferior axis of the human eye through the optic nerve, showing the vascular supply to the retina and choroid. B, Drawing showing vasculature of the retina and choroid. (adapted from Dave Schmick et al, 317 )*

## **1.12 Retinal neovascularisation**

Retinal neovascularization occurs due to ischemic retinopathy changes in which damage to retinal vessels leads to retinal ischemia. In diabetic retinas, leukocytes form adhesions and infiltrations causing physical occlusion of capillaries and hence damage to the vascular endothelial cells and neuroglial cells. There is also release of inflammatory mediators and superoxide in diabetic retinas hence leading to more retinal ischemia. Severe retinal ischemia results in retinal neovascularization which might bleed leading to pre-retinal or vitreous hemorrhage and /or grow into the vitreous cavity causing tractional retinal detachment. There are several ischemic retinopathies that lead to retinal neovascularization and the most prevalent of these are diabetic retinopathy and retinal vein occlusions (317).

## **1.13 Diabetic retinopathy (DR)**

### **1.13.1 Epidemiology and risk factors**

Diabetic retinopathy (DR) is the most common microvascular complication in diabetic patients, with a higher incidence in type 1 compared with type 2 diabetes mellitus (318). DR is the fundamental cause of loss of vision globally in working middle aged adults which is consistent with the increasing prevalence of diabetes in developing and developed countries. Diabetic macular edema (DME) affects central vision at any stage of DR. Among the diabetic populations, the estimated prevalence of any type of DR is 34.6% and those of PDR and DME are 6.96% and 6.81%, respectively (318). A major risk factor for DR is sustained hyperglycemia but dyslipidemia, hypertension and pregnancy have also been implicated (318-320).

### **1.13.2 DR forms**

Diabetic retinopathy is divided clinically into non-proliferative (NPDR) and proliferative

(PDR) forms (319, 320). NPDR is classified into mild, moderate or severe based on the severity of the retinal vascular lesions. Severe NPDR is associated with more distinct features of retinal ischaemia such as intra-retinal microvascular abnormalities and venous beading that are adjacent to non-perfusion areas. PDR has the defining features of neovascularization of optic disc or elsewhere, pre-retinal hemorrhage or vitreous hemorrhage (319, 320).

### **1.13.3 Pathophysiology of DR**

Diabetic mouse models were frequently employed to gain insights into the molecular and cellular mechanisms that underlie the pathophysiology of DR. Optical coherence tomography (OCT), Optical coherence tomography angiography (OCTA) and electroretinography (ERG) have been used to monitor the structure and function of mouse retinas (321-323). In vivo imaging of retinal cell dynamics of anesthetized diabetic mice has been made possible using 2-photon and confocal laser scanning fluorescence microscopy, combined with a cataract-preventing contact lens (324). The metabolic changes caused by diabetes induce excessive production of mitochondrial superoxide in vascular endothelial cells which results in activation of protein kinase C pathway and over activity of the hexosamine pathway. These pathways increase the levels of intracellular reactive oxygen species leading to irreversible cell destruction through epigenetic changes such as DNA methylation, non-coding RNAs and histone changes (325, 326).

Continuous hyperglycemia and oxidative stress induce inflammation (325-327). The levels of pro-inflammatory cytokines and chemokines, such as monocyte chemoattractant protein 1, interleukin1B, interleukin 6 and tumor necrosis factor are increased in eyes with DR (328). In diabetic retinas, the infiltration and adhesion of leukocytes might destruct the vascular endothelial cells and neuroglial cells via obstruction of capillaries and release of inflammatory mediators and superoxide (329). Although it is still not known why retinal microvascular abnormalities occur over years of hyperglycemic periods (more than five years in type 2 diabetes mellitus), experimental and clinical evidence has shown irreversible loss of neurons preceding the vascular damage in diabetic retinas (330-333).

After the discovery of VEGF in the 1980s (334, 335), elevated VEGF levels were reported in eyes with PDR (336). Following that, VEGF injections were used in monkeys' eyes and led to

the formation of retinal vascular abnormalities that were seen in NPDR and PDR (337). During ischemic conditions, several VEGFA isoforms are generated such as VEGFA121, VEGFA165, VEGFA189 in humans (338-340). VEGFA isoforms have binding affinities to extracellular matrices, VEGFR2 co-receptor and neuropilin-1. VEGFA in vascular endothelial cells bind to VEGFR2, activating several signal transduction cascades, as well as the phosphatidylinositol 3-kinase (PI3K)/Akt pathway and the mitogen-activated protein kinase pathway, thereby inducing cell proliferation and migration and the subsequent formation of new blood vessels (338, 339). Moreover, VEGFA-VEGFR2 signal damages the endothelial cells' tight junctions resulting in fluid extravasation and vascular hyperpermeability (338, 339). Thus, VEGF-VEGFR2 signal is essential in vascular leakage and retinal angiogenesis in DR (340, 341). Angiopoietin 1 (Ang1) stabilizes vessels integrity by promoting endothelial cells survival, inhibiting inflammatory pathways and preventing vascular permeability (342). Angiopoietin 2 (Ang2) renders the vascular endothelial cells more sensitive to pro-inflammatory, pro-angiogenic and pro-permeable stimuli such as VEGFA. Further, Ang2 is upregulated by ischemia, hyperglycemia and VEGFA. These findings signify that Ang2 facilitates vascular permeability, inflammation and retinal angiogenesis under specific disease conditions. Ang2 is upregulated in eyes with ischemic conditions such as DR, retinal vein occlusion and age related macular degeneration (343).

#### **1.13.4 Consequences of PDR**

New blood vessels that protrude from the ischemic retina cause vitreous hemorrhages (344). 8% of PDR patients will have a fibrovascular membrane growth accompanying the aberrant neoangiogenesis, inducing retinal detachment (345). Retinal ischemia persistence results in neovascularization of the iris and refractory glaucoma (344).

### **1.14 Aims and Objectives**

This thesis contains several studies to evaluate the effect of different modalities of treatment on ocular neovessels in the ocular surface which includes the cornea and conjunctiva as well as observational studies that observe the effect of treatment modalities such as surgery, laser and injections on ocular surface

neovascularization and retinal neovascularization secondary to proliferative diabetic retinopathy.

Chapter's 2 aim was to evaluate the effect of combined injections of 5FU and bevacizumab in patients presenting with pterygium which is a condition that is mainly treated surgically. This would reduce the need to perform surgery for excision of the pterugium.

Chapter's 3 aim was to study of the healing of conjunctival autograft and the donor site after pterygium excision surgery. This would have implications for clinical follow-up and differentiation from signs of early recurrence of pterygium.

Chapter's 4 aim was to compare the effects of FND alone, subconjunctival bevacizumab alone and the combined FND and subconjunctival bevacizumab injections on the corneal NV.

Chapter's 5 aim was to evaluate the effect of LSCT using an exvivo method for patients who had extensive LSCD and NV. This was done as as part of a multi-center study (HOLOCORE). The success was measured by reduction of corneal NV and healing of corneal epithelial defect.

Chapter's 6 aim was to investigate corneal neuropathy in the different stages of diabetes with and without retinopathy and the effect of anti-VEGF and Pattern Scanning Laser photocoagulation on corneal nerves in eyes with different stages of diabetic retinopathy.

## **CHAPTER 2: MANAGEMENT OF PRIMARY PTERYGIUM WITH INTRA-LESIONAL INJECTION OF 5 FLUOROURACIL AND BEVACIZUMAB (AVASTIN), A CLINICAL TRIAL (REPEAT)**

### **2.1 Introduction**

Pterygium is an elastotic degeneration of the subconjunctival tissue that affects the exposed bulbar conjunctiva, nasally more than temporally. It affects sight when the fleshy fibrovascular tissue advances across the limbus and encroaches on to the visual axis of the cornea. It may result in corneal scarring, chronic ocular surface inflammation and irregular astigmatism and can restrict ocular movement (204). Although the aetiology of the pterygium remains an enigma, environmental factors such as ultraviolet light, dryness, genetic and immunological factors play a big role in its occurrence (209). Other important factors such as fibrovascular proliferation, inflammation and angiogenesis have been implicated in the pathogenesis and progression of pterygium (211). Increased expression of several growth factors, such as epidermal growth factor (EGF), vascular endothelial growth factor (VEGF), basic fibroblast growth factor (bFGF), transforming growth factor-beta, connective tissue growth factor, insulin-like growth factor and nerve growth factor has been reported in primary and recurrent pterygia (346). VEGF, VEGF receptors and other molecules that play a role in angiogenesis are particularly expressed in pterygium (347-349).

The gold standard for treatment of primary pterygium is surgical excision with an autoconjunctival graft (350). Recurrence rates of 0 to 14.29 % have been reported (351). Recently Said et al (282) emphasised the importance of recognising conjunctival recurrence of pterygium and demonstrated that intralesional 5 fluorouracil (5FU) could arrest progression of pterygium avoiding need for surgery. This has also been the experience of others (235). Studies have also shown that intralesional injection of bevacizumab can treat

recurrent pterygium (275, 352).

Taking a cue from the above reports, investigators looked at treating primary pterygium in a similar manner. Two studies were carried out in 2016 to study the effect of intralesional 5FU injection in primary pterygium and reported good results (234, 235). Further studies were carried out on the use of bevacizumab in primary pterygium and also reported good results (273, 352).

We conducted a clinical trial to evaluate the effect of combined injections of 5FU and bevaciazumab in patients presenting with primary pterygium. Immunohistology for different growth factors and markers for blood vessels and lymphatics was carried out in tissue samples obtained after excision of injected pterygia. Our results have implications for clinical application of these injections to arrest progression and reduce vascularity of pterygium as the only treatment or prior to surgical excision. This chapter has been published by Dr Ghazizadeh et al and is her own work (Please refer to list of publications).

## **2.2 Methods**

### **2.2.1 Ethical issues**

The study adhered to the tenets of the Declaration of Helsinki. The study proposal with the relevant forms and documents were approved by the Nottingham research ethics service committee II, Medicines & Healthcare products Regulatory Agency MHRA, the Health Research Authority HRA and local NHS Research and Innovation authorities (Eudract Number: 2015-003217-20), (REC reference Number: 16/EM/0002). It was registered online and adopted by National Institute for Health Research.

The ethical approval application process involved the submission of the project proposal and completed IRAS form to all parties (Research ethics committee, MHRA, NUH NHS trust R&I and HRA), the ethics committee reviewed the application on 22<sup>nd</sup> February 2016 and was approved on 14<sup>th</sup> March 2016. MHRA approved the study on 23<sup>rd</sup> March 2016. Four substantial amendments were applied for and they were all approved. The first patient was recruited on 10<sup>th</sup> January 2017.

## **2.2.2 Patient recruitment**

Whilst the recruitment target was extended to 40 participants, the decision was taken to complete recruitment at 20 as we have collected sufficient data to achieve the protocol objectives. Participants were recruited from specialist cornea and ocular surface clinics at the Queen's Medical Centre, Nottingham University Hospitals NHS Trust under the supervision of Professor Harminder Dua (Consultant Ophthalmologist). 11 patients were retrospectively recruited into the study.

### **Inclusion criteria**

- Patients over the age of 18.
- Patients able to give informed consent.
- Patients with progressive primary pterygium.
- Patients with early recurrent pterygium within 6 months of original excision (conjunctival recurrence or recurrence extending just across the limbus).

Recurrence will be defined as follows:

1. Increased vascularity of the conjunctiva at the site of original excision and autologous conjunctival grafting, showing tortuous and dilated vessels associated with thickening/oedema of the conjunctiva appearing after the initial redness and swelling related to surgery had settled.
2. Clinically documented progression of fibrovascular tissue over two or more follow-up visits with or without frank encroachment on to the cornea, which did not settle with increased doses of topical steroids

-Use of effective contraception in females of childbearing age.

### **Exclusion criteria**

- Patients under 18 years of age.
- Patients unable or refusing to provide informed consent.
- Patients who are needle phobic.
- Pregnant women, women aiming for conception and breastfeeding women.

- Patients with hypersensitivity to the active substance or to any of the excipients.
- Patients with active or suspected ocular or periocular infections.
- Patients with active severe intraocular inflammation.
- Patients with raised intraocular pressure or on glaucoma medication.

### **2.2.3 Clinical intervention and follow up**

A complete eye examination at base line and after injections was carried. Visual acuity was assessed using LogMAR charts followed by pupil reaction, anterior segment biomicroscopic examination, corneal topography (Oculus Pentacam HR, Oculus Optikgerate GmbH, Wetzlar, Germany) to assess corneal astigmatism, Optical coherence tomography (OCT) (Spectralis Heidelberg engineering, Heidelberg, Germany) to assess thickness, intraocular pressure measurement and fundal examination. Demographic data were documented. A standardised protocol was followed for anterior segment photography. The patient was asked to look straight and  $\times 10$  and  $\times 16$  images were taken. Brightness, colour and background illumination were always set at the standard chosen for the study for all patients at all time-points. The  $\times 10$  magnification image was used for length measurement. Images were imported to a PC and measurements were taken with the Neuron J software (ImageJ V.1.31, Maryland, USA) that was calibrated in accordance with the pixel resolution of the images as detailed in instructions. The pterygium length, from limbus to apex was measured before and after injections. A standardised protocol was followed for optical coherence tomography. The Spectralis Heidelberg OCT was used in all patients at all time-points. The patient was asked to look at a predefined fixation target (looking straight) and a vertical scan was performed at two pre-determined points corresponding to anatomical landmarks in the body of the pterygium. The landmark corresponded to the bifurcation of a major vessel. From previous validation studies it was noted that this landmark did not shift in position with treatment though the 'redness' and thickness of the vessels changed. The thickness was measured from the epithelial surface to the surface of the underlying scleral reflection on OCT. The Spectralis Heidelberg software was used to measure the thickness in microns. Any complications and adverse events were noted and recorded. Anterior segment photographs were taken at every follow up visit to assess response to treatment in terms of



redness and progression. The pterygium was graded as severe (red areas more than white (heavily vascularized with dilated and full vessels and fleshy); moderate (more white areas than red, (intermediate vascularization with thin and narrow vessels and not fleshy), and mild (atrophic and thin with minimal vasculature). A score of 3, 2 and 1 was ascribed to the three grades respectively. Astigmatic changes were analysed using Vector Analyzer software (VectorAnalyzer 1.2, Dr.Peyman) and the magnitude of difference vector was measured.

Injections were administered every 2 weeks for a maximum of 5 injections or until the desired endpoint was achieved (atrophic pterygium, mild grade). Further follow up was at monthly intervals for three months (Table 2.1).

### **Injection method**

All injections were given in the outpatient clinic using a slit lamp. Topical anaesthesia (tetracaine minims 1% w/v, Bausch & Lomb, UK) and Povidone iodine (5% w/v, Bausch & Lomb, UK) eye drops were instilled in the eye 10 minutes prior to the injection. With a pre-loaded 1 ml syringe of 5FU (0.3 ml of 2.5mg 5FU per 0.1ml) 0.1 to 0.2 ml of 5FU (2.5 to 5 mg) was injected into the body of the pterygium using a 30 gauge needle (Sterican, B. Braun, Hessen, Germany). Formation of a bleb indicated intra-lesional injection of drug (Fig. 1). This was followed by injection of bevacizumab, which too was delivered in a pre-loaded 1 ml syringe containing 0.2 ml of 5 mg bevacizumab. 0.1 to 0.2 ml of bevacizumab (2.5mg to 5mg) was injected in the body of the pterygium. Post-injection, 1–2 drops of chloramphenicol 0.5% (preservative free minims, Bausch and Lomb, UK) were instilled topically and continued four times a day for 3 days after each injection. All patients had the ability to access the 24 hour on call emergency eye service and contact the investigators for any queries during the study period.

*Table 2.1: Follow up scheme of REPEAT.*

**Table giving details of the follow up scheme of recruited patients.**

<b>Name and code of visit</b>	<b>Interpretation</b>
Visit 01	Date of recruitment
Visit 02	Date of first treatment
Visit 03	Two weeks from first treatment and possibly date of second treatment
Visit 04	Two weeks from second treatment and possibly date of third treatment
Visit 05	Two weeks from third treatment and possibly date of fourth treatment
Visit 06	Two weeks from fourth treatment and possibly date of fifth treatment
Post-injection visit 01	1 month from last treatment
Post-injection visit 02	2 months from last treatment
Post-injection visit 03	3 months from last treatment

#### **2.2.4 Laboratory study method**

The laboratory part complements the clinical study. This clinical study was published and I contributed for three-quarters of the work. The cases in the study were my patients and I was the first author on the publication. The laboratory team carried out the laboratory part of the study.

Four patients returned for excision of pterygium for cosmetic reasons, 5 months after last injection. Pterygium tissue from these patients and from three non-injected controls matched for severity (controls) were subjected to immunohistological examination.

Pterygium tissue was fixed in 4% paraformaldehyde for 2 hours and embedded in paraffin. Thin sections (4 um) were cut, deparaffinized and antigen retrieval carried out by incubating slides in 10mM sodium citrate solution, pH 6.0 (IHC antigen retrieval solution – low pH; Thermofisher Scientific, UK) for 15 minutes at 60°C. The slides were then incubated with 5% normal donkey serum in 0.03% Triton-X100 for 1 hour to block any non-specific binding

sites. Sections were stained with specific primary antibodies (Table 1) or negative control (no primary or normal mouse IgG1) overnight at 4°C followed by secondary antibody staining (alexa fluor 488 or 594 conjugated donkey anti rabbit IgG or donkey anti mouse IgG, Thermofisher scientific) at room temperature for 1 hour. The stained sections were mounted in DAKO fluorescent mounting media and examined using fluorescent microscope (B51X Olympus, Japan) and processed with Adobe Photoshop CS4 (Adobe Systems, CA). Histological sections in duplicate, from each of the three control samples and four injected pterygia were used for each of the seven antibodies indicated in table 2.2.

*Table 2.2. Primary antibodies used for immunofluorescence.*

Target	Antibody type	Host	Clone	Supplier	Catalog no.	Dilution
bFGF	IgG	Goat	Polyclonal	R&D Systems	AF-233-NA	1 in 200
VEGF-189	IgG1	Mouse	VG1	Thermofisher Scientific	MA5-12184	1 in 100
EGF	IgG1	Mouse	10825	R&D Systems	MAB236	1 in 100
Collagen-I	IgG	Rabbit	Polyclonal	Abcam	AB34710	1 in 200
vWF	IgG	Rabbit	Polyclonal	Dako	A0082	1 in 400
LYVE-1	IgG	Goat	Polyclonal	R&D Systems	AF2089	1 in 200
Isotype	IgG1	Mouse	11711	R&D Systems	MAB002	1 in 100

### 2.2.5 Outcome measurements

The primary efficacy measures were arrest of progression and reduction of vascularity (redness) of lesion. The secondary efficacy measures were cosmetic improvement as perceived by the patient, improvement in symptoms of irritation, reduction in thickness and effect on astigmatism. All patients were clearly informed that the treatment would not cause the lesion to disappear and that for cosmetic or other reasons surgery to remove the lesion might still be required.

Safety measurements were specifically investigated with reporting any adverse events related to the injections. Patients had the ability to access the 24 hour on call emergency eye service, and at the same time were provided with contact numbers for investigators for any queries during the study period.

## 2.2.6 Statistics and Data analysis

Statistical analysis was performed by using GraphPad Prism 7.03 (GraphPad Software La Jolla, CA, USA). Wilcoxon adhoc test was used to analyse the data for pterygium length and OCT thickness while Paired t test was used to analyse data for clinical grading.

## 2.3 Results

### 2.3.1 Recruitment

We were able to recruit 20 patients to the study (study is completed). The demographic data for the recruited patients is listed in table 2.3.

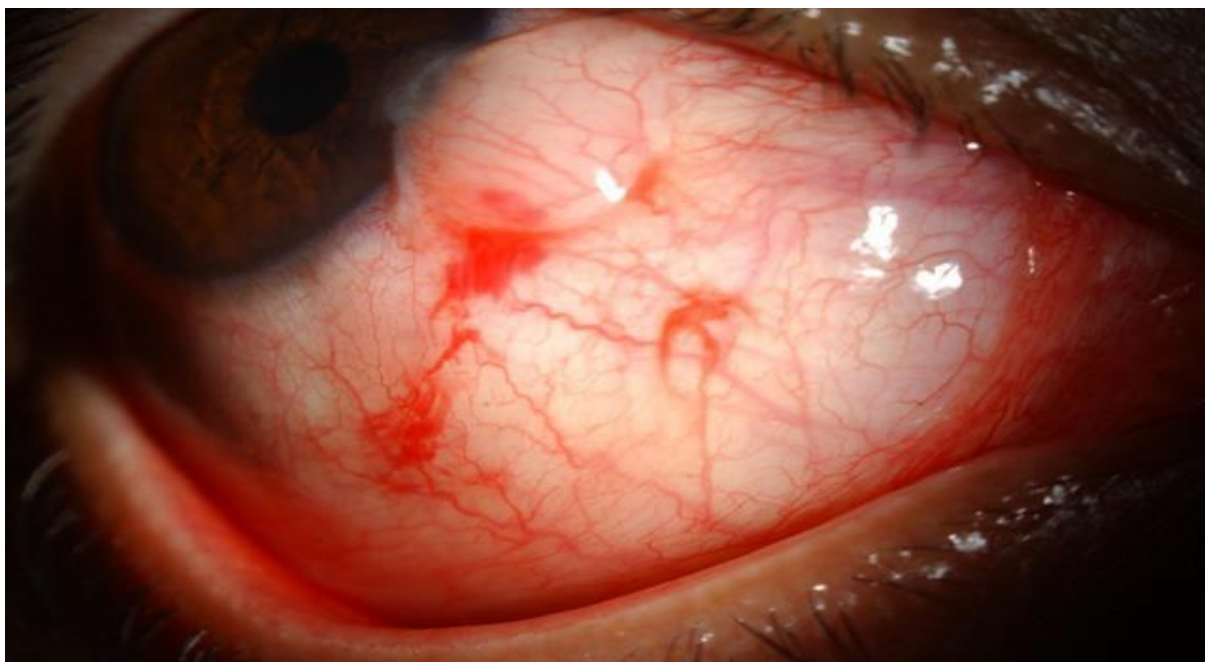
	Participant Trial Code	Age Years (M/F)	Type of pterygium	Date of recruitment	Eye treated	Number of injections	Last follow up visit
1	REPEAT01	64 (M)	Primary	10.01.2017	Left	5	11.04.2017
2	REPEAT02	72 (M)	Primary	12.01.2017	Right	5	09.05.2017
3	REPEAT03	64 (F)	Primary	24.01.2017	Right	2	07.02.2017
4	REPEAT04	34 (M)	Recurrent	05.03.2017	Left	5	30.01.2018
5	REPEAT05	38 (M)	Primary	14.03.2017	Left	5	17.10.2017
6	REPEAT06	55 (M)	Primary	23.03.2017	Left	5	25.10.2016
7	REPEAT07	63 (F)	Primary	28.03.2017	Left	5	09.11.2016
8	REPEAT08	57 (M)	Primary	11.04.2017	Left	5	17.10.2017
9	REPEAT09	22 (M)	Primary	11.04.2017	Left	5	09.11.2017
10	REPEAT11	56 (F)	Primary	24.05.2017	Right	5	28.12.2016
11	REPEAT13	83 (M)	Recurrent	07.06.2017	Left	5	20.03.2018
12	REPEAT14	37 (F)	Primary	21.06.2017	Right	3	06.12.2016
13	REPEAT15	63 (F)	Primary	22.06.2017	Left	5	23.01.2018

14	REPEAT16	49 (M)	Primary	28.06.2017	Left	5	17.01.2017
15	REPEAT17	54 (M)	Primary	05.07.2017	Left	5	21.02.2017
16	REPEAT18	53 (F)	Recurrent	15.08.2017	Left	2	15.08.2017
17	REPEAT19	70 (M)	Primary	29.08.2017	Right	5	16.01.2018
18	REPEAT20	42 (F)	Primary	11.10.2017	Left	4	27.02.2018
19	REPEAT22	37 (F)	Primary	03.11.2017	Right	5	10.04.2018
20	REPEAT23	69 (M)	Recurrent	09.11.2017	Left	5	09.11.2017

**Table 2.3 Demographic data of REPEAT cases**

### **2.3.2 Cases**

16 patients had primary pterygium and 4 patients had recurrent pterygium. A total of 20 eyes of 20 patients received 5 FU and bevacizumab injections. Of the twenty patients, 8 were females (40%), and 12 were males (60%). Mean age was 54 years (range was from 22-83 years). Sixteen patients received 5 injections, 1 received 4 injections, 1 received 3 injections and 2 received 2 injections. All patients experienced stinging during injection of bevacizumab but not with 5FU. All patients showed subconjunctival and/or intra-lesional haemorrhage after injection (Figure 2.1), which resolved in two weeks. All patients showed arrest of progression over the follow up period.



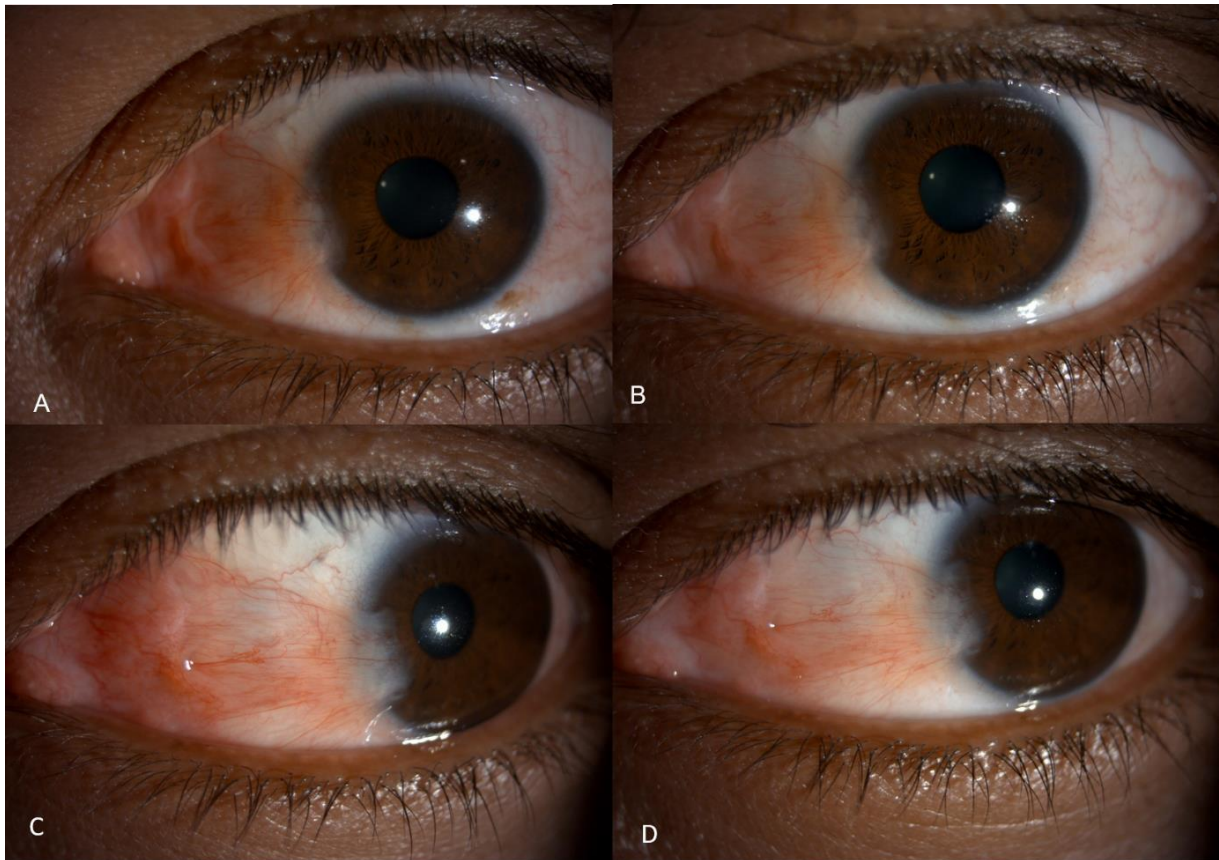
*Figure 2.1: Slit lamp anterior segment photograph of a pterygium post injection.*

**The bleb created by the injection is visible with some conjunctival haemorrhage at the site of needle entry.**

There was a mean reduction of  $0.10 \text{ mm} \pm 0.1$  in pterygium length in 56% of the patients while the rest did not show any change ( $p=0.0039$ , Wilcoxon test, median=  $0.041$ , 95% confidence interval (CI) =  $0.024-0.177$ ). Twenty two percent of the patients showed a reduction in astigmatism (mean magnitude of difference vector was  $10.1$ ), 11% showed no difference (mean magnitude of difference vector was  $1$ ) while 67% had increased astigmatism (mean magnitude of difference vector was  $5$ ) following the injections. The mean magnitude of difference vector was  $5.7$  and the range of astigmatic change was from  $0.8-19.4$ . Eighty nine percent of patients had reduced thickness of pterygium as evidenced by difference in OCT measurements while the rest had no change. The mean reduction in thickness was  $35.8 \mu\text{m} \pm 31.29$ , ( $p=0.0078$ , Wilcoxon test, median=  $29 \mu\text{m}$ , 95% CI=  $11.7-59.9$ ).

The clinical grade of the pterygium had significantly reduced in 62.5 % while it remained the same in 37.5%. No patient showed an increase in clinical grade of pterygium. Ninety percent of the patients who showed reduction of clinical grade had one clinical grade improvement while 10% had a 2 clinical grades improvement (Figures 2.2-2.4) (Mean pre-injection grade was  $2.313$ , mean post-injection grade was  $1.625$ ,  $p=0.0004$ , paired-test, 95% CI=  $0.367$  to

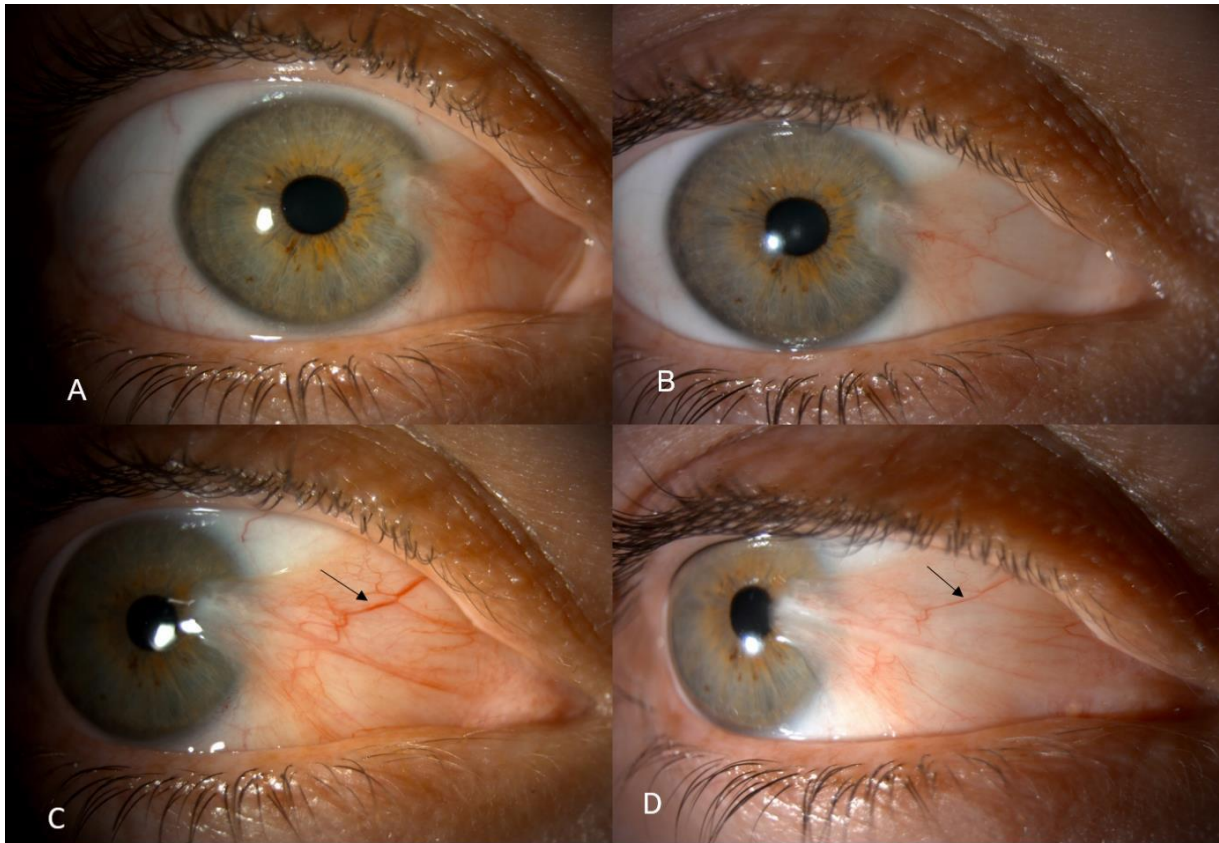
1.008). Two patients developed superficial punctate keratitis after the 4<sup>th</sup> and 5<sup>th</sup> injection. This resolved on cessation of injection.



*Figure 2.2: Slit-lamp anterior segment photograph of REPEAT09 before and after 5 injections.*

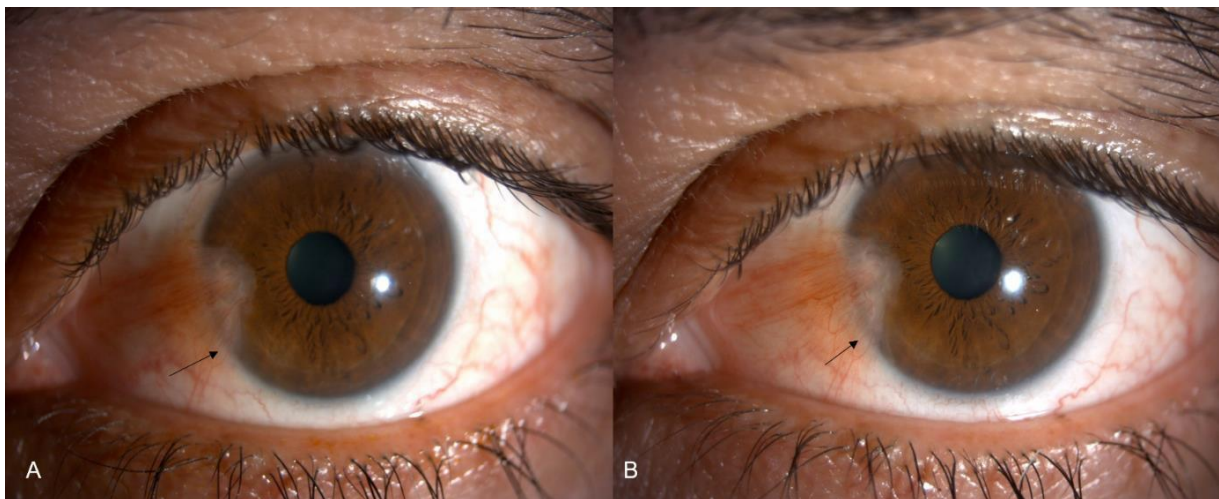
**A, C:** Pre-injection image of pterygium with patient looking straight (A) and temporally (C). The lesion appears fleshy with dilated and full vessels. **B, D:** Post-injection images with patient looking straight (B) and temporally (D) show reduction in vascularity.





*Figure 2.3: Slit lamp anterior segment photographs of REPEAT14 before and after 3 injections.*

**A, C:** Pre-injection images of pterygium with patient looking straight (A) and temporally (C). The lesion appears fleshy with dilated and full vessels (arrow). **B, D:** Post-injection images show reduction in vascularity with patient looking straight (B) and temporally (D). The arrow in (D) points to a vessel that has attenuated with barely visible branches.



*Figure 2.4: Slit lamp anterior segment photographs images of REPEAT16 before and after 5 injections.*

**A:** The pterygium before injections is fleshy and vascular obscuring the underlying limbus (arrow). **B:** The pterygium after injections is atrophic as evidenced by increased visibility of the outline of the underlying limbus especially inferiorly (arrow).



### 2.3.3 Laboratory study results

Atypical fibroblast cells and vascular endothelium showed positive staining for bFGF in control pterygium samples (Figure 2.5A), whereas in injected pterygium (Figure 2.5B) weak bFGF immunoreactivity was noted only at the basal aspect of vascular endothelium. Monoclonal antibody against VEGF showed positive immunoreactivity in control pterygium samples (Figure 2.5C) and a significantly reduced staining in injected samples (Figure 2.5D). EGF (epidermal growth factor) was abundantly present in pterygium epithelium and around basal aspects of vascular endothelium of control samples (Figure 2.5E), but in injected samples it was only detected at low levels around basal aspect of vascular endothelium (Figure 2.5F). Reactivity of collagen-I was moderately reduced in injected samples (Fig. 5H) compared to control samples (Figure 2.5G). SPARC (secreted protein acidic and cysteine rich) was shown to be positively expressed in all control samples but unlike bFGF, it remained unchanged in sections of injected samples (Figure 2.6). Antibodies against von-Willebrand factor (vWF) were used to detect blood vessels, and against lymphatic vessel endothelial hyaluronan receptor (LYVE-1) to detect lymphatic vessels. Some vascular structures showed dual staining for both vWF and LYVE-1 in sections of control samples (Figure 2.7) whereas reduced expression was noted in injected samples. This amounted to 64.3% reduction in vWF staining and 61.9% in LYVE-1 stained vasculature after injection (Table 2.4).

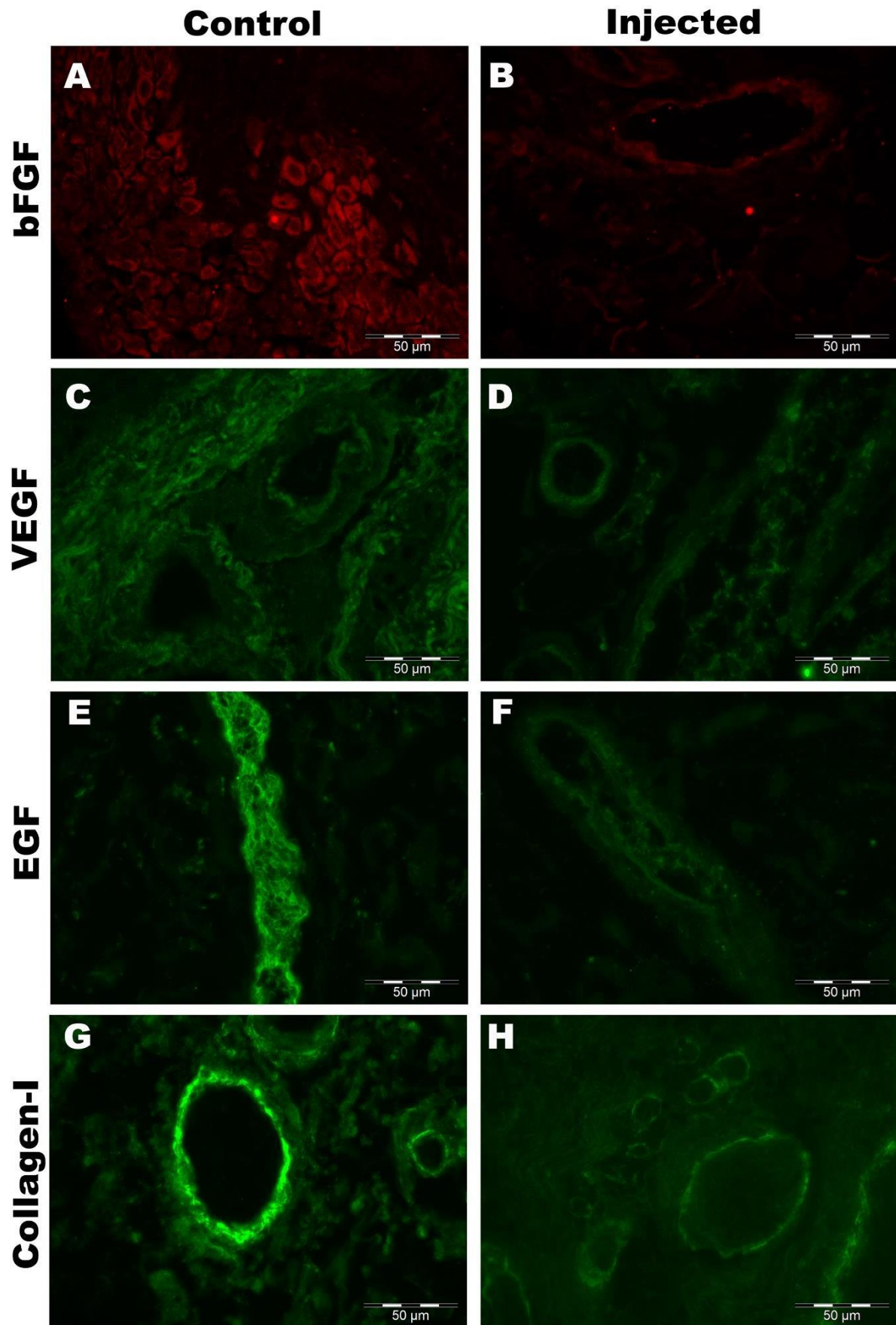
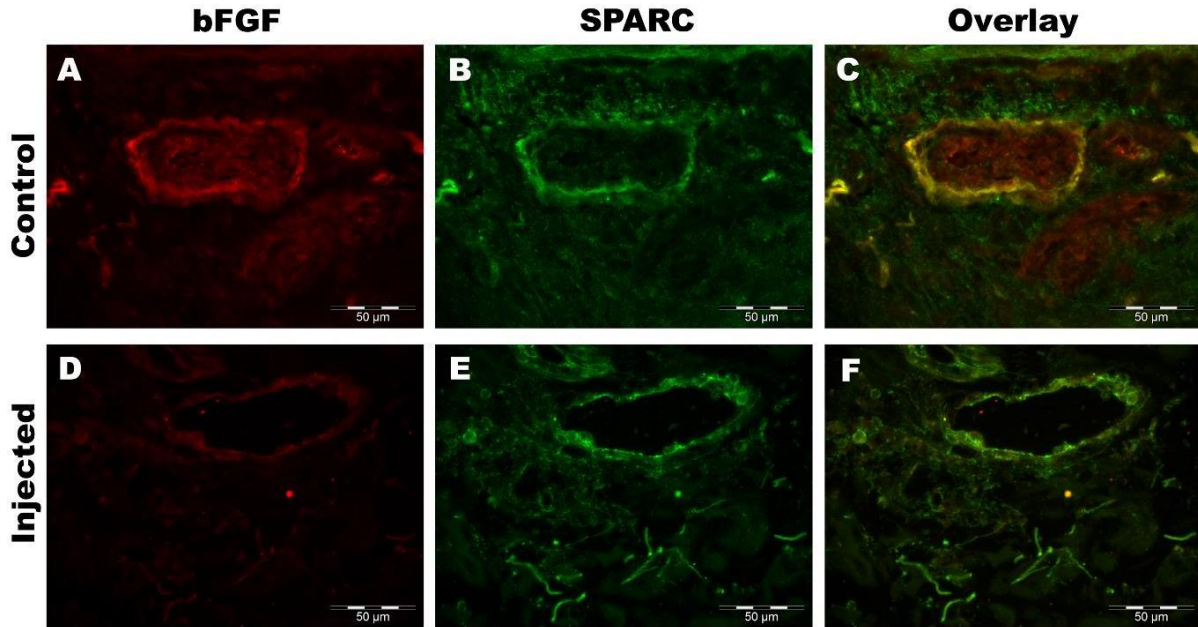


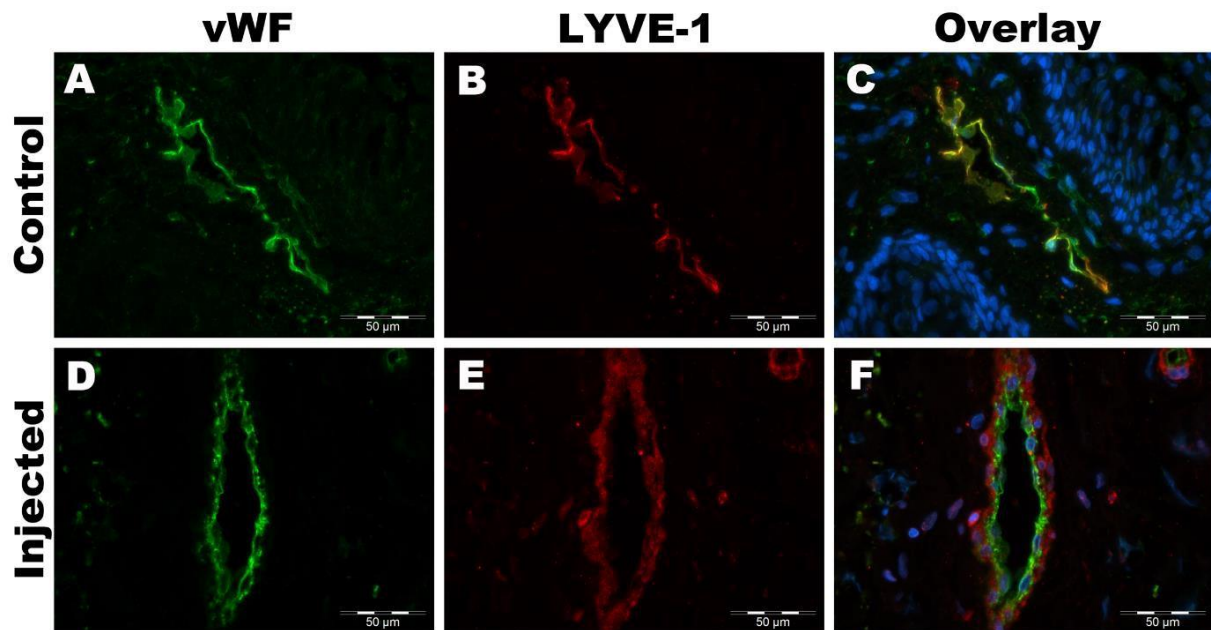
Figure 2.5: Immunofluorescence analysis of control and injected pterygium samples.

Representative sections of sample from control (A, C, E, G; n=3) and injected (B, D, F, H; n=4) groups. Positive immunoreactivity for bFGF in fibroblast cells (A); VEGF in vascular endothelium and extracellular matrix (C), EGF in epithelial cells (E) and Collagen-I in vascular basement membrane (G) are demonstrated in the control sections. Reduced or weakened staining for these proteins is seen in corresponding images post injection (B, D, F, H). Scale bar = 50 microns (x400).



*Figure 2.6: Representative sections of sample from control (n=3) and injected (n=4) groups (Double labeling of bFGF and SPARC).*

Labeling for bFGF is demonstrated by red fluorescence (A and D) and SPARC by green fluorescence (B and E) in multiple sections of the same pterygium vessel in control and injected samples. Overlay micrographs indicate double labeling for bFGF and SPARC (orange/yellow fluorescence; C and F). The staining for bFGF is markedly reduced in the injected sample but that of SPARC is unchanged. Scale bar = 50 microns (x400).



**Figure 2.7:** Representative micrographs of control ( $n=3$ ) and injected ( $n=4$ ) samples. (Co-localization of vWF (vascular) and LYVE-1 (lymphatic) channels).

vWF is indicated in green (A and D) and LYVE-1 in red (B and E). Overlay micrograph of control section (C) indicates co-localisation of vWF and LYVE-1. In injected sample (F), LYVE-1 stained cells surround vWF stained endothelium.

**Table 2.4** Marked reduction in average number of vWF and LYVE-1 positive vessels.

	vWF	LYVE-1
Control ( $n=3$ )	28	21
Injected ( $n=4$ )	10	8
% reduction	64.3	61.9

## 2.4 Discussion

Recurrence of pterygium is the major complication after surgical excision of the lesion. The two main pathological processes in pterygium are fibroblast proliferation and angiogenesis. Many studies have demonstrated that the pathogenesis and recurrence of pterygia can be attributed to the increased expression of molecules such as VEGF, transforming growth factor, platelet derived growth factor and bFGF (236). VEGF was found to be highly increased in pterygia and is believed to be involved directly or indirectly in formation of pterygia (215).

Intervention to reduce incidence of recurrence following surgery for primary or recurrent pterygia include the use of autologous conjunctival graft and application of antimetabolites either 5FU or MMC intraoperatively. Intra lesion injection of antimetabolites and anti-VEGF drugs have also been used to treat recurrent pterygium (235, 275, 282, 352). Encouraged by the beneficial effects of treating recurrence, both agents have also been used individually in treatment of primary pterygium with considerable success (349). 5FU inhibits DNA synthesis and proliferation of fibroblast (353). Anti-VEGF antibodies bind to isoforms of VEGF and inhibit the VEGF-receptor interaction preventing angiogenesis (352).

In our study we injected both agents together, for the treatment of primary pterygium. We found that this approach resulted in reduction in the clinical grade, thickness and vascularity of the pterygium. This two pronged approach addressing both the main pathological processes may work synergistically affecting thickness and vascularity of the pterygium. Some patients also showed a slight reduction in the length of the pterygium. This is most likely due to the reduction in thickness at the apex, but in any case was less than 0.2mm and clinically insignificant. Significantly, the progression of pterygium was arrested in all cases and the cosmesis too had improved in 62.5% with 56% of the concerned patients noticing the difference subjectively. Some of these individuals are unlikely to proceed to surgery making the study clinically more relevant. Interestingly however, the astigmatism increased in 67% of patients post-injection. This could be related to the retraction of the fibrotic tissue post-injection exerting a greater force on the cornea inducing further deformation. Malik et

al (235) compared the mean change in corneal astigmatism and clinical appearance after intralesional injection of 5FU in primary and recurrent pterygia. They treated all patients with 0.1 ml of 5FU (5mg) weekly injections for four weeks and demonstrated a reduction of the astigmatism. However, Singh et al (273) use only bevacizumab injection and showed not difference in astigmatism. Unlike these studies, we injected both 5FU and bevacizumab, which could account for the increased astigmatism we noted, probably as a consequence of fibrous tissue contraction. Most studies that have used either 5FU or bevacizumab (234, 236, 273) concluded that improvements in appearance, colour and surface area of pterygium could be safely achieved.

Despite anaesthesia, all patients complained of a stinging sensation during injection of bevacizumab but not with 5FU. Hence we injected the latter before the former.

Bevacizumab solution is acidic (pH 6.13) and 5FU is alkaline (pH 8.89), which could explain the difference in patient experience. Apart from mild punctate keratitis, no adverse events were recorded. Post-injection, four patients requested surgery to remove the residual pterygium. Intraoperative bleeding was much less compared to previous experience with un-injected lesions. This is an anecdotal observation as the study was not designed to pick up this difference. These four samples were examined by immunohistology.

### **Immunohistology:**

Immunohistochemical studies have shown increased expression of VEGF in pterygium compared to normal conjunctiva (215, 349). VEGF receptors 2 and 3 are also increased in pterygium (349). Mohamed et al (353) conducted a randomised control study with one group receiving a single bevacizumab injection while the other did not receive any. Similar to our results, they found a reduced mean vessel count and a significant reduction in VEGF expression in injected pterygium samples. vWF is one of the proteins involved in blood vessel function. It has been demonstrated in the pterygial blood vessel walls and could be involved in pterygial angiogenesis (354). Lymphatic vessel endothelial cells express specific proteins including LYVE-1 (201). Our study demonstrated that there was a reduction in both vWF and LYVE-1 in the injected samples indicating decreased angiogenesis and lymphangiogenesis, which is a novel finding. Interestingly, in control pterygium samples

there was a close localisation of both vWF and LYVE-1 in relation some vessels, which could be related to immature vessels or proximity of mononuclear cells (355).

Detorakis et al (356) found that levels of bFGF were higher in pterygium than normal conjunctiva. Collagen types I, III and IV were found in normal conjunctiva and pterygium (357). In our injected samples both bFGF and Collagen I were reduced, which is more likely to be due to the effect of 5FU as it primarily targets the proliferation of fibroblasts. SPARC, is a matrix protein which has several roles in wound remodelling and modification of collagen production as well as in angiogenesis and high levels have been reported in pterygium (349). We were not able to demonstrate any effect of our injections on the SPARC expression despite reduction in vascularity and collagen suggesting that bFGF plays a greater role in the pathophysiology of pterygium. Pterygium epithelium and fibroblasts derived from pterygia also express epidermal growth factor receptors (EGFR) (358). We detected EGF at the basal aspect of pterygium vascular endothelium, which was reduced after injections suggesting that EGF also contributed to angiogenesis in pterygium.

This study demonstrates that proliferative activity in pterygium and its progression can be modified by drugs targeting the various growth factors and cells involved in the pathogenesis of pterygium. Such a medical approach in the management of pterygium, the treatment of which is essentially surgical, is a viable option to consider for both recurrent and primary pterygia.

The strong point in this clinical study is using 2 different types of combined injections to determine their effect on the arrest of pterygium progression as all previous studies investigated one type of injection only. The limitation in this study was the sample size. In the future, a bigger sample size would give more data and also another clinical study could be carried out to follow up the patients who required surgery despite of injections to look into the rate of recurrence to determine whether the multiple combined injections reduced the recurrences rates or not .

## **CHAPTER 3: HEALING OF AUTOLOGOUS CONJUNCTIVAL GRAFTS IN PTERYGIUM SURGERY**

### **3.1 Introduction**

Pterygium is a common ocular disorder which presents as a progressive triangular growth encroaching on the cornea from the bulbar conjunctiva. It consists of fibrovascular subconjunctival tissue with elastotic degeneration and conjunctival epithelial hypertrophy(359). It typically affects inter-palpebral conjunctiva, nasal more than temporal. It can affect vision by direct obstruction of the passage of light or induce corneal distortion and irregular astigmatism. In advanced cases, it can affect ocular movements with symptoms of diplopia. For many patients, it is a cosmetic blemish (204, 360-363). There is no medical therapy for pterygium. When indicated for the above reasons, surgical excision with autologous conjunctival graft is the intervention of choice with intraoperative use of an anti-metabolite such as Mitomycin-C (MMC) as an adjunct, especially in recurrent cases. Traditionally the autologous graft was secured in place with sutures but in many parts of the world sutures have been replaced with tissue glue (fibrin glue) or its variations such as autologous blood (364-366).

Both occurrence and recurrence of pterygium after surgery are related to race, skin colour and geographic location (207-209). The surgical success rate (lack of recurrence) following excision and conjunctival autograft is reported to be between 0 and 14.29% (228, 351, 367-370). Use of fibrin glue instead of sutures is reported to favourably influence the recurrence rate. Although much has been studied and reported in relation to use of autologous grafts and fibrin glue (254, 368, 371-379), there is no information on the fate or healing of the grafted conjunctival tissue and the changes associated with the donor site. We undertook a temporal observational study of the healing of conjunctival autograft and the donor site in 28 consecutive patients and report our results herein that have implications for clinical follow-up and differentiation from signs of early recurrence.

This chapter has been published by Dr Ghazizadeh et al and is her own work (Please refer to list of publications).



## **3.2 Methods**

### **3.2.1 Ethical issues**

The study was conducted in accordance to the declaration of Helsinki. The study was classed as a 'healthcare evaluation project' and approved by the Clinical Quality, Risk and Safety directorate, Nottingham University Hospitals, NHS Trust (project number: 17-206c).

### **3.2.2 Patient recruitment**

Thirty-two eyes of 28 consecutive patients attending the cornea and ocular surface clinic of the Queens Medical Centre, Nottingham were included. All patients had visually or cosmetically significant pterygium requiring surgery.

### **3.2.3 Clinical intervention and follow up**

All thirty two eyes of the 28 patients underwent surgical excision of pterygium using the conjunctival autograft technique.

#### **Surgical procedure**

After due consent, surgery was carried out under regional anaesthesia (sub-Tenon's block) or general anaesthesia. A blunt scissors was inserted through the conjunctiva at the neck of the pterygium (at limbus) and the head peeled off the corneal surface. The head and neck were excised and the corneal surface polished. The conjunctiva covering the body of the pterygium was carefully dissected off the underlying fibrovascular tissue and the latter off the sclera, up to the medial fornix but anterior to the caruncle. The fibrovascular tissue was excised and bleeding points cauterized with a bipolar cautery (Force EZ, Valleylab, USA).

Donor site: the superior bulbar conjunctiva of the same eye was exposed with a superior rectus suture (4/0 silk). The donor conjunctiva, corresponding to the size of the defect

created by pterygium excision, was marked with ink (4–6 mm vertically and 5–15 mm horizontally) preserving 2 mm of peri-limbal conjunctiva of the donor site. The donor conjunctiva, sparing Tenon's capsule, was undermined with a blunt scissors and excised such that the ink marks were included on the epithelial surface. The donor conjunctiva was spread epithelial side down, on the cornea and covered with a layer of the thick component (fibrinogen, aprotinin, coagulation factor 13) of (Tisseel<sup>®</sup>, Baxter Healthcare Corporation, Berkshire, UK) in a double barrel syringe. The thawed components of each barrel were withdrawn separately into 2 ml syringes and glue applied via a Rycroft cannula (Sterimedix, Redditch, Worcestershire, UK). The recipient bed was covered with a layer of the thin component (thrombin and calcium chloride) of Tisseel<sup>®</sup>. The donor conjunctiva was flipped across to cover the recipient bed and smoothed such that the edges were not rolled. Gentle pressure was applied with a dry surgical sponge to approximate the conjunctival autograft with the underlying episclera/sclera (scleral bed). Further glue, each component sequentially, was applied under the edge of the recipient site conjunctival edges (conjunctival bed), and it was approximated to the donor conjunctiva edge as the glue set. The posterior part of the conjunctiva at the donor site was undermined, both components of glue applied to the surface of exposed Tenon's, and the conjunctiva pulled down to cover the defect and approximated to the rim of peri-limbal conjunctiva.

Mitomycin-C was applied as an adjunct in 25 eyes using sponge pieces soaked in 0.04% solution and placed between sclera and overlying conjunctiva of the pterygium for 5 min, and on the exposed sclera for 2 min. Mitomycin-C (MMC) was used intraoperatively in all patients with recurrent pterygium and patients with Middle-Eastern and Afro-Caribbean origin undergoing excision of primary pterygium. The eye was then washed with 20 ml of balanced salt solution before affixing the donor conjunctiva.

### **Postoperative management**

All patients were prescribed chloramphenicol eye drops 0.5% (Chloramphenicol minims, Bausch & Lomb/Chauvain), instilled four times a day for 2 weeks and prednisolone acetate eye drops 0.5% (Predsol minims, Bausch & Lomb/Chauvain), instilled four times a day for 1 week then tapered to three times a day for 1 week, twice a day for 1 week and then once a day for another week.

Patients were followed up within the first week and then at weeks 2, 4, and 8. Sixteen patients were followed up to 6 months postoperatively. Slit lamp images were taken with a Topcon camera SLD701 preoperatively and at each visit. Patients were examined, without and with fluorescein staining, for presence of graft, for graft haemorrhage, swelling, vascularity/ischaemia and retraction of edges. The graft beds (scleral and conjunctival) and the conjunctiva at the donor site were also similarly examined. Fluorescein angiography (FA) was performed in four patients within the first week and in one patient 3 months after the surgery.

### **Anterior segment fluorescein angiography**

Anterior segment fluorescein angiography (FA) was performed on five eyes of five patients who had pterygium excision and conjunctival autografts. The terms of the study approval required that only one angiogram be performed per patient and for five patients only as part of an angiography pilot study. Hence, FA was performed at 1 day postoperative for two patients, 2 days postoperative for one patient, 3 days postoperative for one patient and at 3 months postoperative for one patient.

### **Procedure of angiography**

The angiograms were obtained using the Heidelberg Retina Angiograph, and the degree of field of view was chosen according to the size of the conjunctival autograft/vessels. The focus was set on +32.00. An initial infrared image of the selected area was taken as baseline. Five millilitres of 10% sodium fluorescein were then injected intravenously by cannulating the antecubital vein at a rate of 1 millilitre per second. Two single images of the selected area were taken at the start and end of the injection. A video recording of 35 seconds duration was initiated with the first appearance of the dye, which was usually 12 seconds after the start of the injection. After 35 seconds, no images were taken till 1 min elapsed from the start of the injection and then a single image was captured every second till 2 min elapsed from the start of the injection. At minute 2 from the start of the injection, two single images of the selected eye were taken and another two single images were captured between minutes 4 and 5 from the start of the injection.

### 3.3 Results

#### 3.3.1 Cases

A total of thirty-two eyes of 28 patients underwent pterygium excision with autologous conjunctival graft affixed with fibrin glue. Patient demographics are shown in Table 3.1. The age range was 33–78 years with a mean of 50.8 years and there were 17 males and 11 females. Twenty-four cases were unilateral and four were bilateral. Mitomycin-C (MMC) was applied to 25 eyes of 22 patients. Twenty-seven eyes of 24 patients had primary pterygium while five eyes of four patients had recurrent pterygium. None of the primary pterygium cases that underwent surgery developed recurrence over the study period.

	Age	Sex	Eye
1	54	M	L
2	41	M	L
3	72	F	R
4	39	M	R
5	51	M	L
6	45	M	R
7	33	M	L
8	78	F	L
9	61	M	BE

	Age	Sex	Eye
10	70	F	R
11	39	M	L
12	46	M	R
13	45	M	R
14	54	M	L
15	46	M	BE
16	50	F	BE
17	50	M	R
18	45	F	R
19	64	F	BE
20	36	F	R
21	64	F	L
22	56	M	L
23	51	F	L
24	39	F	L
25	34	M	L
26	57	F	R

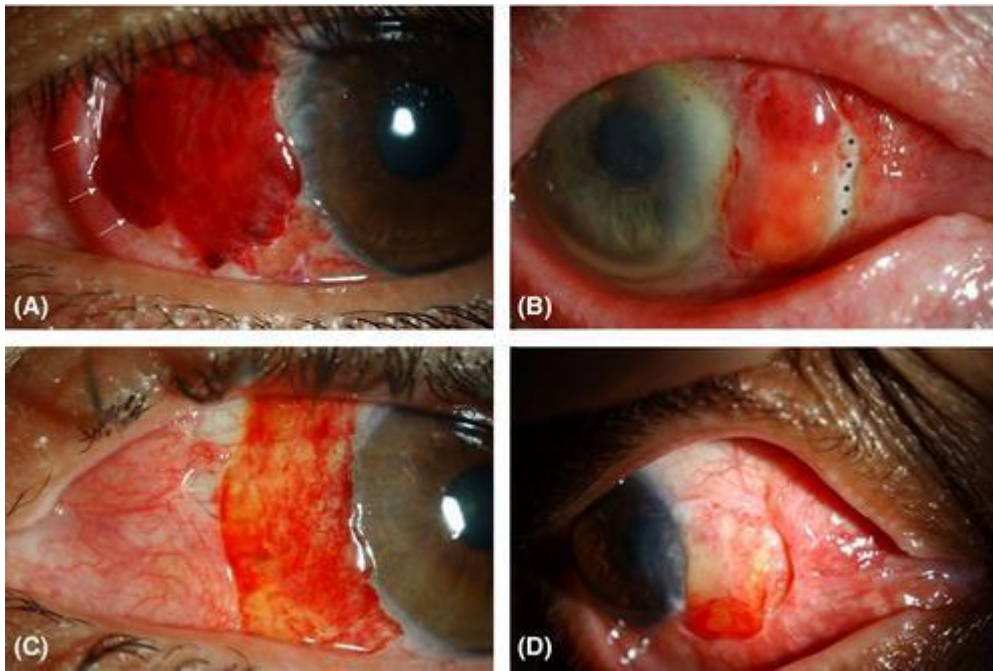
	Ag	Se	Eye
27	37	M	L
28	66	M	R

*Table 3.1: Age and sex of patients and laterality of the pterygium.*

**BE = both eyes; F = female; L = left; M = male; R = right.**

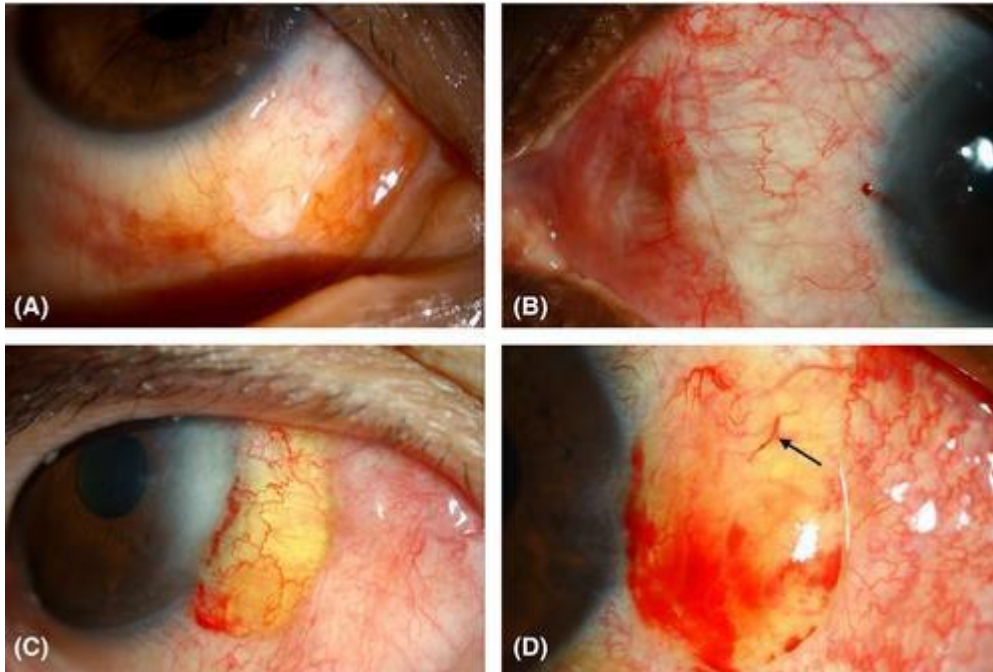
### **Within 1 week**

The conjunctival autograft was not lost in any eye. About 94% of conjunctival autografts showed diffuse or patchy intra-graft haemorrhage (Figure 3.1). Haemorrhage started as early as 1 day postoperative. Blood vessels were obscured by the diffuse haemorrhage (Figure 3.1). In grafts with patchy haemorrhage, the visible vessels were narrow and/or dilated (Figure 3.1). Vascular connections between graft and host bed were not clearly visible. All grafts showed variable amount of swelling. The swelling was either due to oedema and/or transudation, which appeared as a straw-coloured accumulation of fluid (Figure 3.2). The corneal edge of the conjunctival autograft was overlapping the limbus in all patients. About 11% conjunctival autografts showed areas of localized under-perfusion (areas devoid of blood vessels compared to the surrounding perfused conjunctiva in the autograft) (Figure 3.3). The episclera under the conjunctival bed of 17% conjunctival autografts showed engorged vessels. The conjunctival beds of 89% of conjunctival autografts showed congestion and 33% showed haemorrhage (Fig. 3A). The edge of the conjunctival beds were swollen with oedema causing the edge to form a narrow hump giving it a 'rolled' appearance in some sectors as illustrated (Figures 3.1A and 3.1D). Fluorescein staining showed no loss of epithelium in any conjunctival autograft. Residual fibrin glue at the junction of conjunctival autograft and conjunctival bed, stained brightly with fluorescein (Figure 3.4). A separation or gap between the edges of the conjunctival autograft and conjunctival bed was seen in 33% of patients. This gap was fully epithelialized as evidenced by fluorescein staining. About 12.5% of the patients with a gap showed under-perfusion of the scleral bed (Figures 3.5 and 3.6).



*Figure 3.1: Slit lamp anterior segment photographs of the conjunctival autograft within 1 week of transplant.*

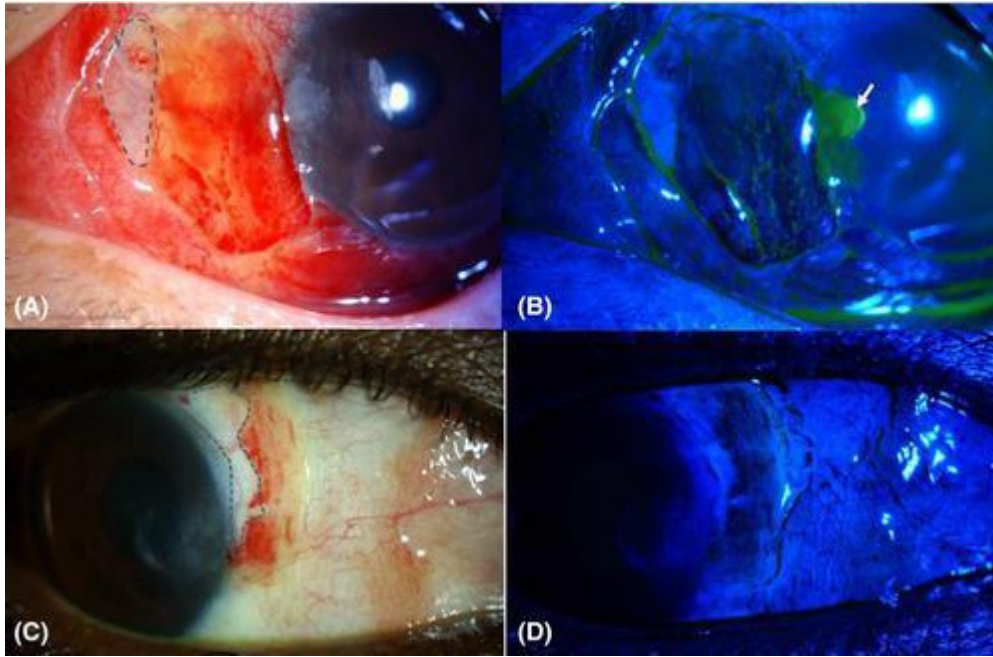
(A) The conjunctival autograft shows diffuse haemorrhage covering the entire conjunctival autograft and obscuring all details posterior to it. The rolled edge of the conjunctival bed is seen closely applied to the conjunctival autograft (arrows). (B) The conjunctival autograft shows diffuse haemorrhage, which is denser superiorly. The vasculature of the conjunctival autograft is not visible. Inferiorly, accumulation of serous (yellowy) fluid is seen. The corneal edge of the conjunctival autograft is encroaching on the limbus. The edge of the conjunctival bed is thickened, rolled and also shows patches of haemorrhage. The edges of the conjunctival autograft and conjunctival bed have retracted to expose the underlying sclera, with sparse episcleral vessels (\*). (C) The conjunctival autograft shows patchy haemorrhage and transudation. The vasculature of the conjunctival autograft is visible. The conjunctival bed shows retraction. Good episcleral vasculature is visible. The corneal edge of the conjunctival autograft is encroaching on the limbus. (D) The conjunctival autograft shows a patch of haemorrhage with transudation, inferiorly. The conjunctival autograft vasculature is clearly visible. The rolled edge of the conjunctival bed is prominent.



*Figure 3.2: Slit lamp anterior segment photographs of the conjunctival autograft within 1 week of transplant.*

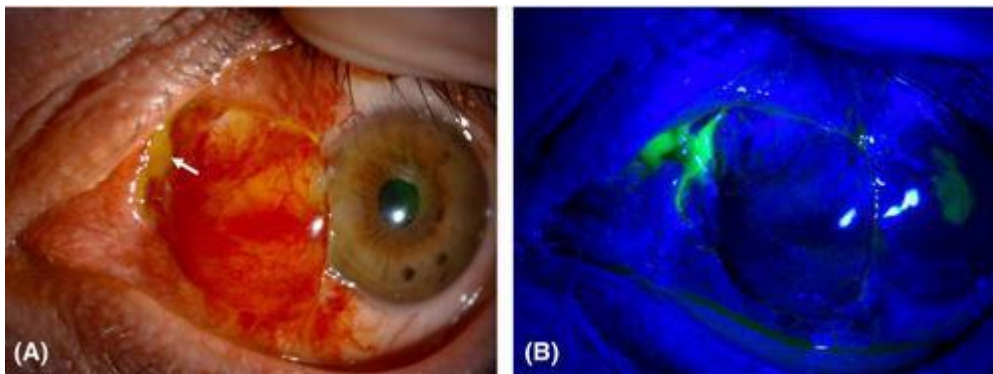
The vasculature of the conjunctival autograft is visible in all photographs. The vessels are of variable thickness and some show stagnant columns of blood (arrow). The nasal edge of the conjunctival autograft is in close apposition with the conjunctival bed, with no gap in all four cases. (A) The conjunctival autograft shows swelling due to oedema. (B) The conjunctival autograft shows swelling due to oedema. The conjunctival bed is congested and shows an elevated fold where it apposes the edge of the conjunctival autograft. (C) The conjunctival autograft shows patchy haemorrhage and diffuse transudation of straw-coloured fluid which contrasts with the appearance of oedema seen in (A) and (B) above. The corneal edge of the conjunctival autograft is encroaching on the limbus. The conjunctival bed is not congested but is thickened. (D) The conjunctival autograft shows haemorrhage inferiorly with diffuse transudation of straw-coloured fluid.





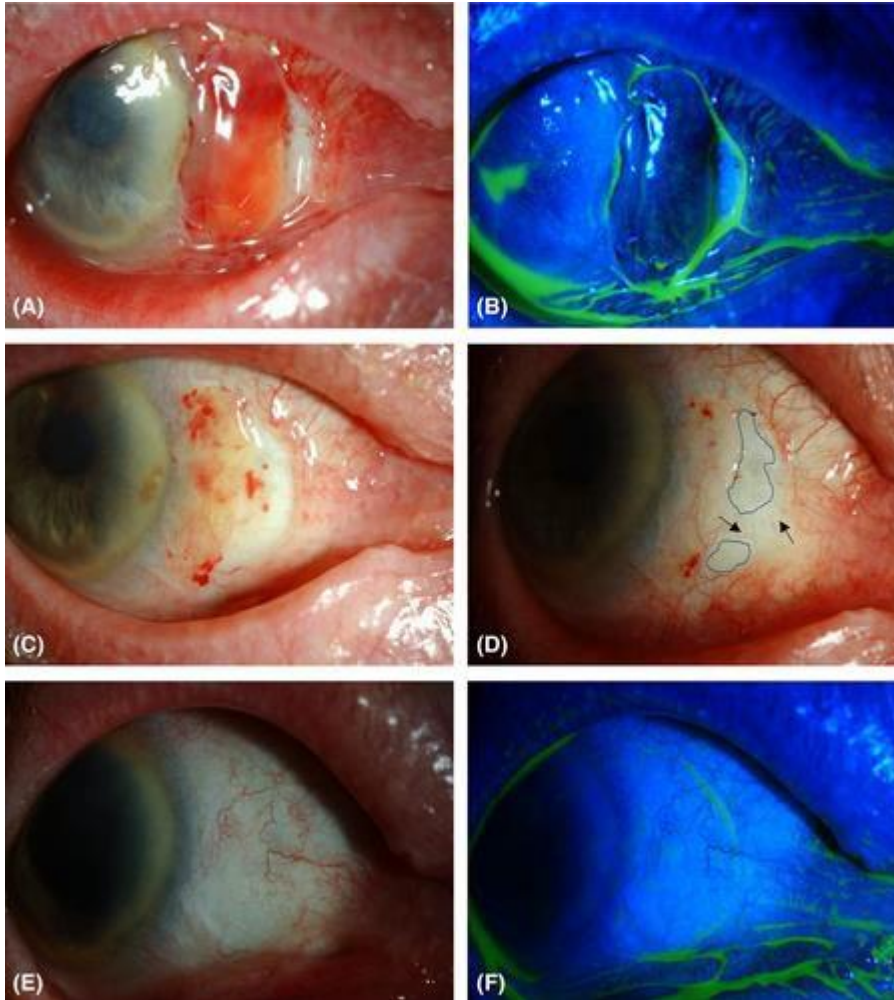
**Figure 3.3:** Slit lamp anterior segment photographs of the conjunctival autograft within 1 week of transplant (without and with fluorescein staining (2% eye drops).

(A) The conjunctival autograft shows localized under-perfused area (outlined), patchy haemorrhage with minimal transudation. The conjunctival bed shows areas of congestion. (B) Cobalt blue filter image with fluorescein sodium 2% eye drops of (A) showing the outline of conjunctival autograft where pooling of dye occurs. The cornea shows an epithelial defect (arrow). (C) The conjunctival autograft shows patchy haemorrhage and a localized area of under-perfusion (outlined). (D) Cobalt blue filter image with fluorescein sodium 2% eye drops of (C) showing the outline of conjunctival autograft.



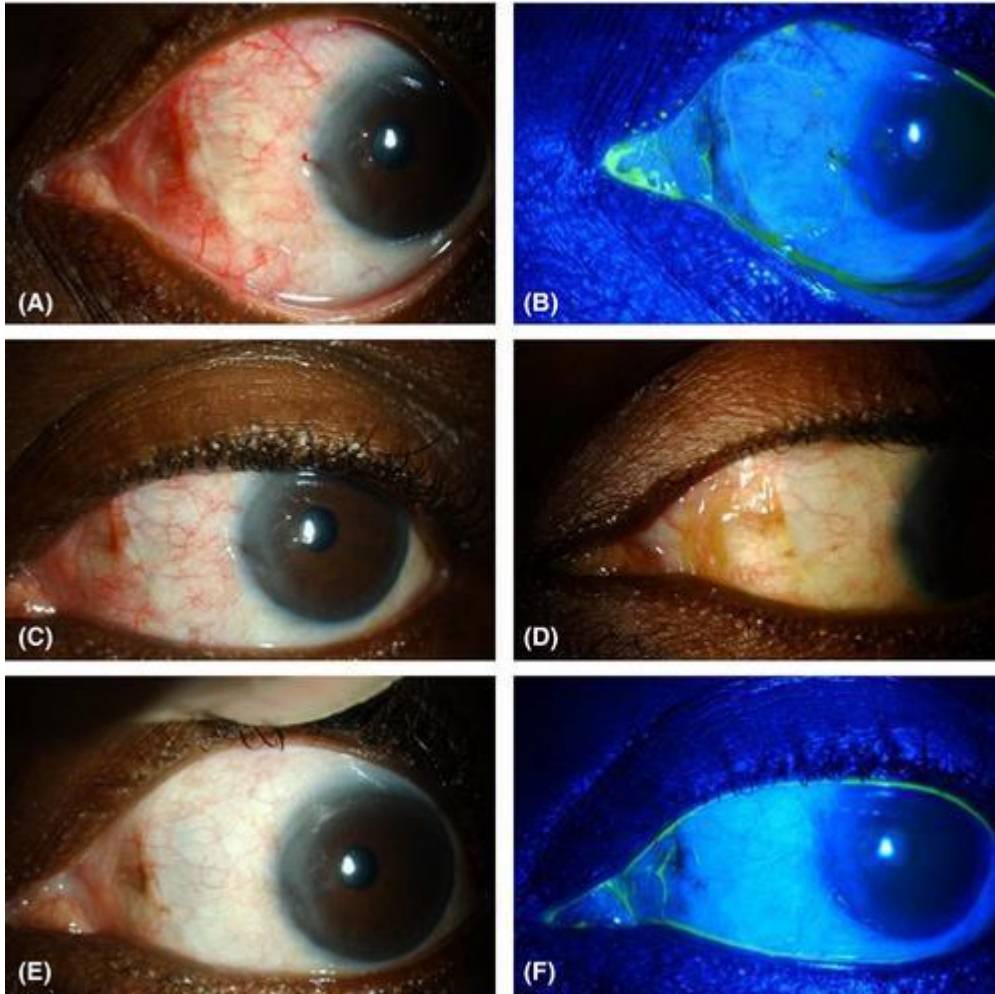
**Figure 3.4:** Slit lamp anterior segment photographs of the conjunctival autograft within 1 week of transplant (without and with fluorescein 2% eye drops).

(A) The conjunctival autograft is swollen and shows patchy haemorrhage and transudation. There is residual fibrin glue at the junction of the conjunctival autograft and the conjunctival bed (arrow). The corneal edge of the conjunctival autograft is encroaching on the limbus. (B) Cobalt blue filter image with fluorescein sodium 2% eye drops of (A) showing fibrin glue staining brightly with fluorescein.



*Figure 3.5: Slit lamp anterior segment photographs images of the conjunctival autograft of a patient from 1 week of surgery to 6 months (without and with fluorescein 2% eye drops).*

(A) The conjunctival autograft is swollen, haemorrhagic and its nasal edge has retracted from the conjunctival bed. The underlying sclera has sparse vessels. (B) Cobalt blue filter image with fluorescein sodium 2% eye drops of (A) showing the outline of conjunctival autograft. The exposed underlying sclera is epithelialized. A small defect in the healing corneal epithelium is seen. (C) The conjunctival autograft showed less swelling, haemorrhage and transudation at 2 weeks postoperative. The corneal edge of the conjunctival autograft has retracted from the limbus. (D) The conjunctival autograft swelling has resolved, and there is minimal haemorrhage at 1 month postoperative. There is a well-established network of vessels in the conjunctival autograft. Some under-perfused areas persisted (outlined) but small vessels (arrows) are seen to migrate into this area. (E) The conjunctival autograft and conjunctival bed have settled completely at 6 months postoperative. The under-perfusion of the scleral bed has resolved. The conjunctival autograft shows multiple reconnections with the bed. (F) Cobalt blue filter image with fluorescein sodium 2% eye drops of (E) showing the outline of conjunctival autograft although it seems to have imperceptibly merged with the conjunctival bed in (E).



*Figure 3.6: Slit lamp anterior segment images of the conjunctival autograft of a patient from 1 week of transplant to 6 months (without and with fluorescein 2% eye drops).*

(A) (As in Fig. 2B) The conjunctival autograft shows swelling due to oedema. The conjunctival bed is congested and shows an elevated fold where it apposes the edge of the conjunctival autograft. (B) Cobalt blue filter image with fluorescein sodium 2% eye drops of (A) showing the outline of conjunctival autograft. The conjunctival autograft is well apposed to the conjunctival bed. (C) The conjunctival autograft shows less swelling and oedema at 2 weeks postoperative. The conjunctival bed shows less congestion. (D) The conjunctival autograft shows less swelling at 1 month postoperative. The oedema has resolved. (E) The conjunctival autograft and conjunctival bed have settled completely at 2 months postoperative. The conjunctival autograft vasculature shows reconnections with the bed (arrows). The conjunctival bed fold is less prominent. (F) Cobalt blue filter image with fluorescein sodium 2% eye drops of (E) showing that the conjunctival autograft and conjunctival bed have blended almost imperceptibly although the outline of the conjunctival autograft is still visible.

### One to two weeks

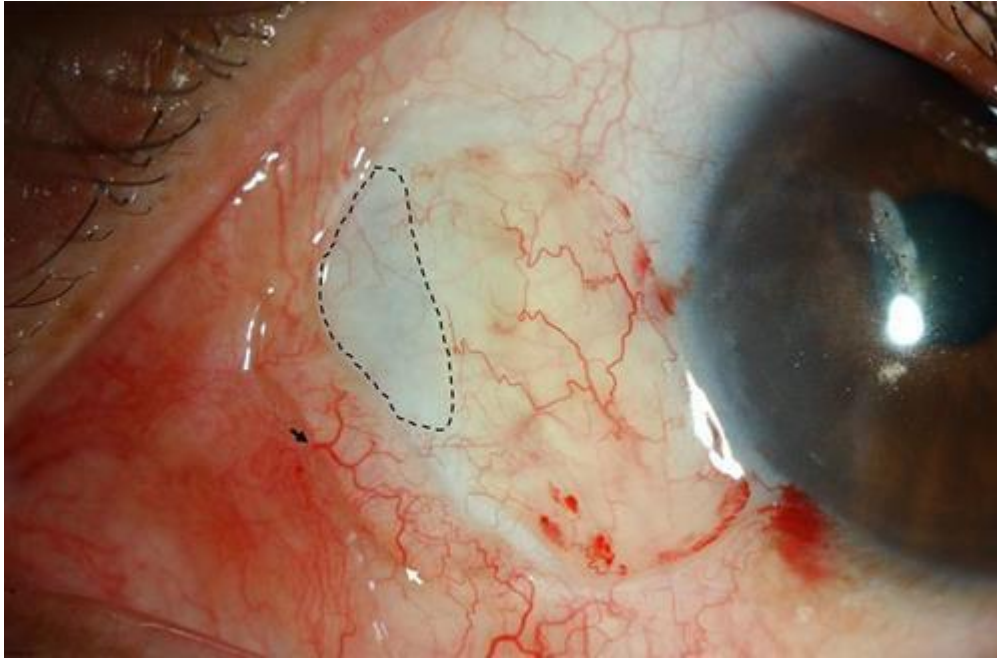
The haemorrhage was less in all conjunctival autografts and in 13.5% cases had completely resolved. This also enabled better visualization of the vessels. The vessels morphology was

more varied, being tortuous or straight, narrow or dilated. Vascular connections were clearly seen between the conjunctival autograft and conjunctival bed in all patients. About 60% conjunctival autografts were less swollen while 40% showed no improvement in swelling. The corneal edge of 93% had retracted from the limbus, which was now clearly visible. The under-perfused area had not resolved in any of the cases. The episcleral vessels (scleral bed) were less engorged. About 80% of conjunctival beds still showed congestion but the degree of congestion was less than week one in all congested eyes while the rest of the congested eyes has resolved and residual minimal haemorrhage was seen in 27% of cases. All beds had several tortuous, straight, narrow or dilated blood vessels (Figures 3.5 and 3.6).

### **Two to four weeks**

About 70.5% of conjunctival autografts continued to show minimal haemorrhage, which had completely resolved in the rest. All conjunctival autografts demonstrated a well-formed network of blood vessels with well-established connections with the conjunctival bed. Approximately half (47%) showed complete resolution of swelling. Under-perfusion of conjunctival autograft was persistent. The congestion in all conjunctival beds had resolved and only 10% showed minimal haemorrhage. At this time point, 'shunt vessels' were clearly seen in the conjunctival bed (Figure 3.7). The scleral bed in the gap between conjunctival autograft and conjunctival bed continued to show under-perfusion although small vessels were seen to migrate into the under-perfused area (Figure 3.5D).





*Figure 3.7: Representative image of the conjunctival autograft of a patient at 1 month postoperative (slit lamp image, diffuse illumination).*

The conjunctival autograft shows swelling due to oedema and patchy haemorrhages. There is a localized area of under-perfusion (outlined). The conjunctival bed shows a shunt vessel, the afferent starting at the black arrow and forming a loop to the efferent (white arrow). No terminal branches are seen from the distal part of the loop. The conjunctival bed is congested.

#### **Four to eight weeks**

About 16% conjunctival autografts had some remaining haemorrhage. Multiple reconnections with the bed were seen in all patients. About 21% conjunctival autografts continued to show residual swelling. The under-perfused areas in the conjunctival autografts persisted. Clinically, the junction of the edge of the conjunctival autografts and the conjunctival bed was difficult to discern except in those who had developed a gap in one or more sector. Under-perfusion of the scleral bed in the gap persisted. With fluorescein staining, the conjunctival autograft-conjunctival bed junction was clearly outlined with pooling of fluorescein in 80% and in cases where there was a gap, the pooling was more obvious as a broader outline. About 10% of the conjunctival beds continued to show minimal haemorrhage (Figures 3.5 and 3.6).

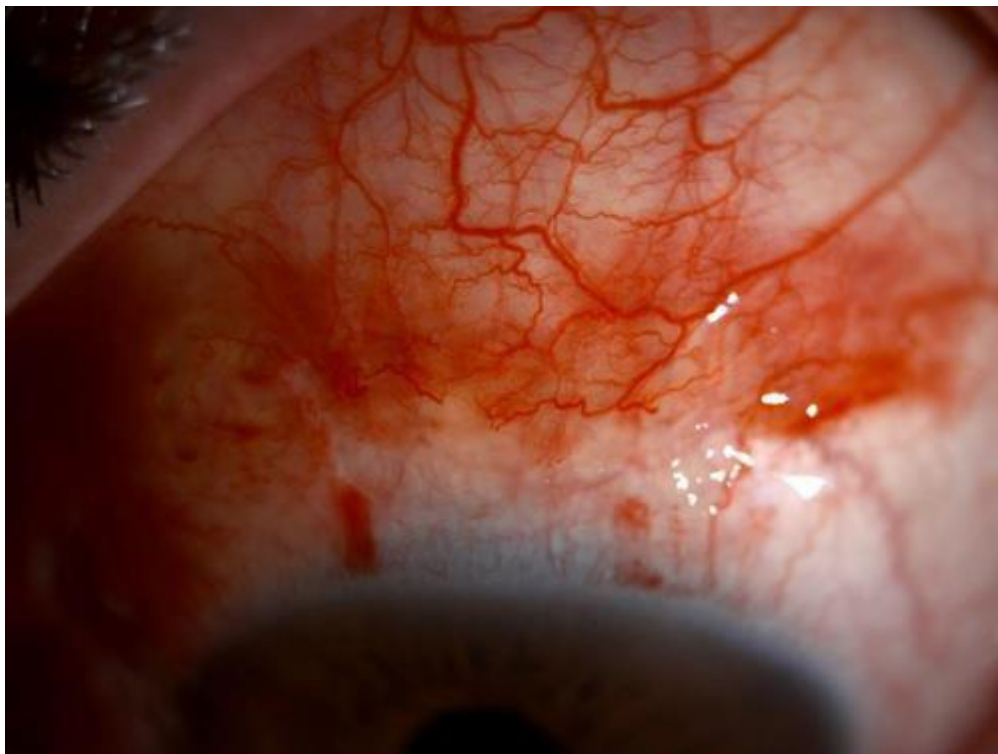#### **Eight weeks up to 6 months**

All patients had completely settled grafts and beds (Figures 3.5 and 3.6). The conjunctival autografts showed no haemorrhage or swelling and all of them had a well-formed network of vessels connected with the beds. Some shunt vessels persisted. The under-perfusion of scleral beds had completely resolved.

The findings from our temporal observation of ischaemia/under-perfusion, haemorrhage, swelling or gaping at the edge between the conjunctival autograft and conjunctival bed were consistent, with no variation in eyes which received adjunct MMC during pterygium surgery from those which did not have MMC application.

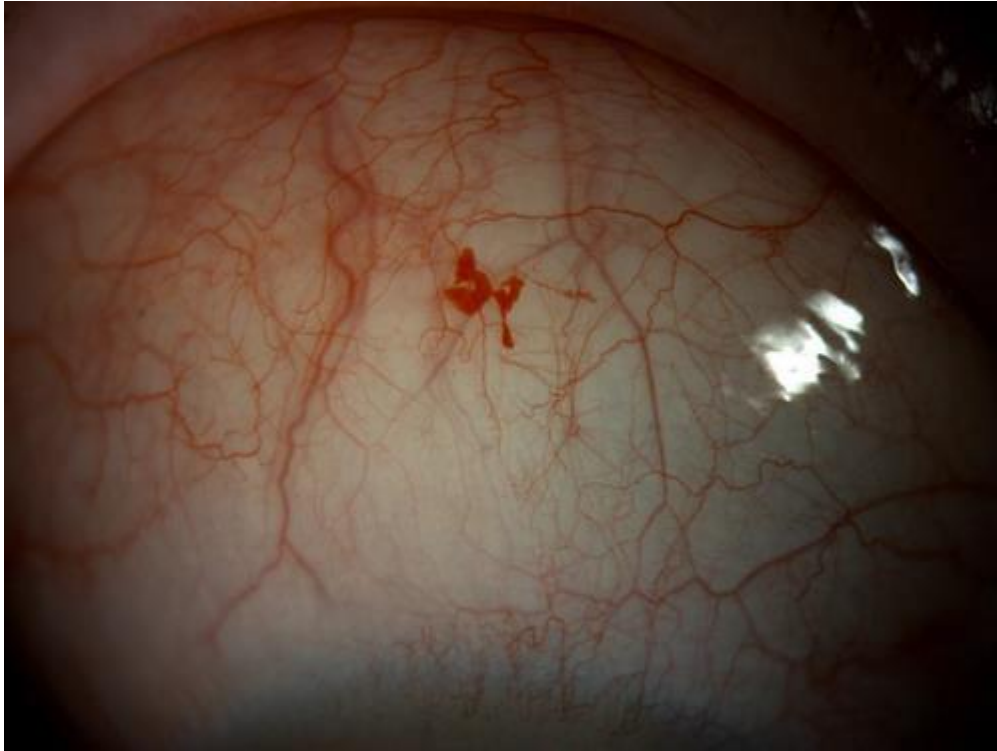### **Donor site**

About 27% of donor sites showed haemorrhage and congestion in the first week, which had completely resolved within 8 weeks (Figure 3.8). One patient had telangiectasia, which developed at 1 week and persisted thereafter (Figure 3.9). One patient had retraction of the conjunctival edge from the limbus with exposed Tenon's capsule, which developed a pyogenic granuloma (Figure 3.10). This had settled and epithelialized by the week eight follow-up visit. No other complications were noted.



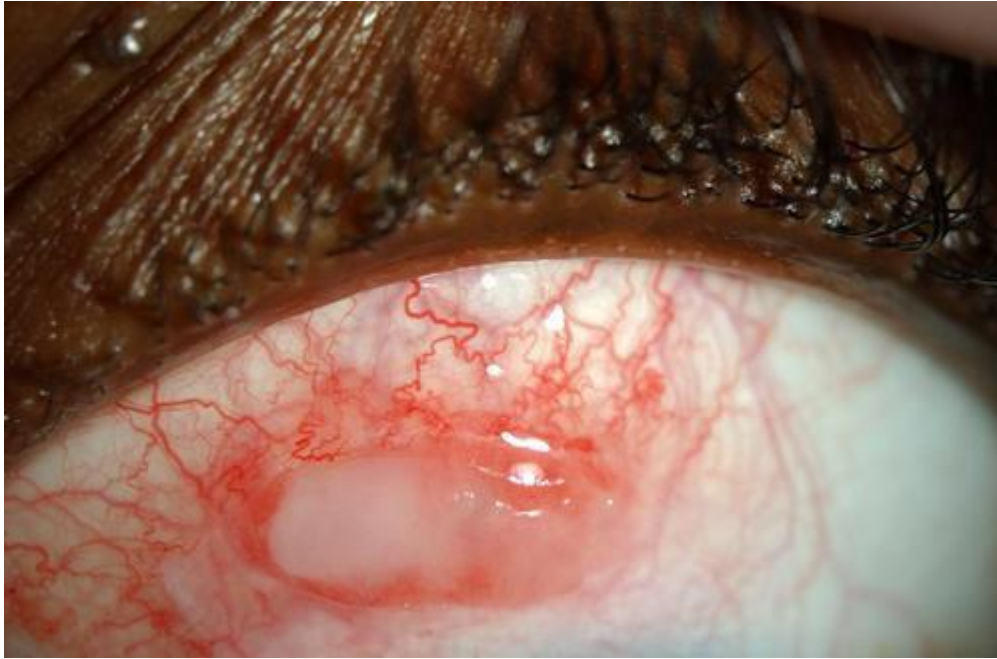*Figure 3.8: Slit lamp anterior segment photograph of the donor site of a patient at 1 week postoperative.*

**The donor site is congested and shows multiple areas of haemorrhages. The superior conjunctiva that was pulled towards the limbus and glued to cover the defect has remained in situ without any retraction.**



*Figure 3.9: Slit lamp anterior segment photograph of the donor site of a patient at 3 months postoperative.*

**The donor site shows an area of aneurysmal/telangiectatic dilation of the vasculature. The lesion was noted at 2 weeks postoperative and changed minimally over the follow-up period. The margins remained well- defined and the colour did not fade. The probability of this lesion being an intraconjunctival haemorrhage could not be ruled out.**

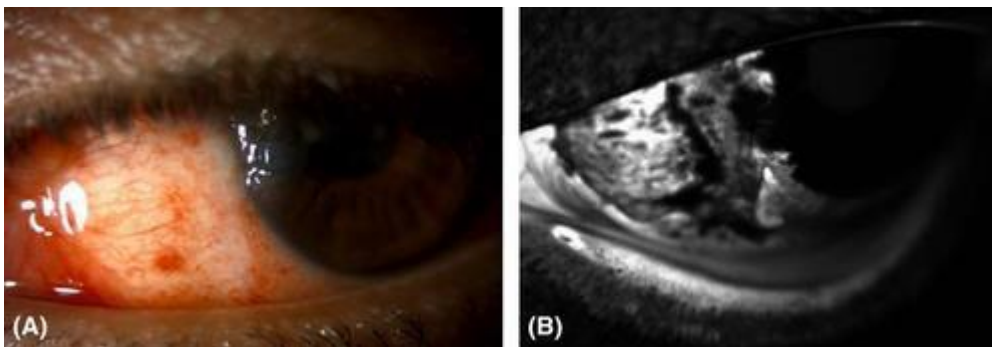


*Figure 3.10: Slit lamp anterior segment photograph of the donor site of a patient at 2 weeks postoperative.*

The donor site shows pyogenic granuloma associated with an area of conjunctival retraction and exposure of Tenon's capsule.

### **3.3.2 Conjunctival autograft angiography**

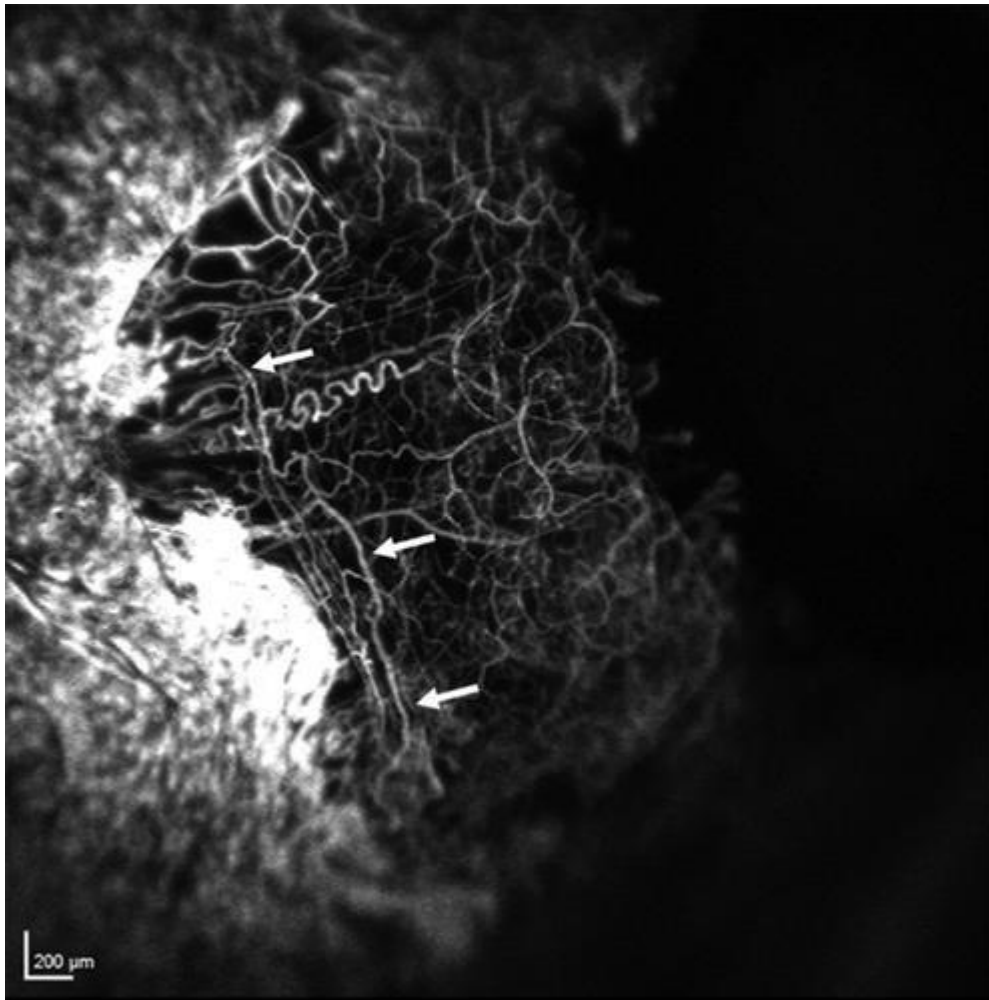
Of the five FA performed, four were within the first 3 days (early FA). All these patients had demonstrated graft swelling and haemorrhage at the time of FA (Figure 3.11). At the 3-month time-point (late FA), when FA was performed in the fifth patient, the conjunctival autograft showed normal-looking conjunctival appearance and vasculature (Figure 3.12).



*Figure 3.11: Slit lamp anterior segment photograph and fluorescein angiogram of a conjunctival graft at 1 day postoperative.*



(A) Slit lamp anterior segment photograph of the conjunctival autograft of a patient at 1 day postoperative. Swelling due to oedema and patchy haemorrhages is seen. (B) Anterior segment fluorescein angiogram at 1 min and 45 seconds. There is hyperfluorescence along the conjunctival bed. Areas of hyperfluorescence are also seen on the conjunctival autograft. The dark band does not correspond to the haemorrhage seen in (A) and is likely to represent an area of non-perfusion with some masking.

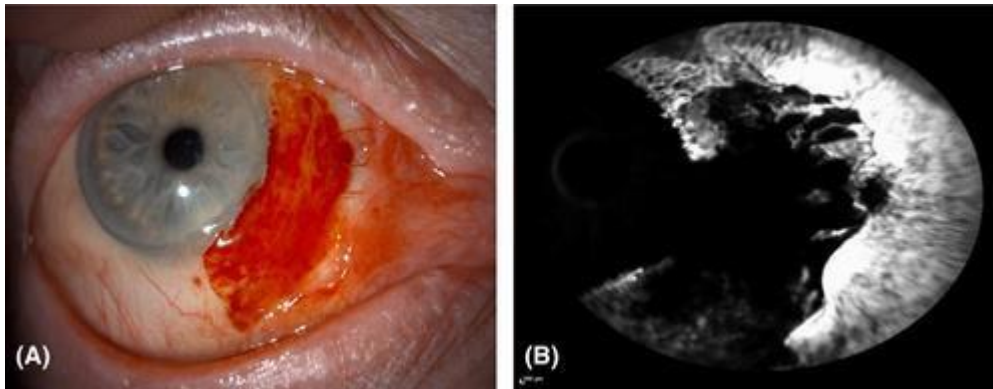


*Figure 3.12: Anterior segment fluorescein angiogram at 4 min and 10 seconds of the conjunctival autograft of a patient at 3 months postoperative.*

A normal vasculature network is clearly visible in the conjunctival autograft. There is no leakage in the conjunctival autograft but areas of hyperfluorescence persist along the edge of conjunctival bed which is accentuated by light reflection. Long loops of shunt vessels, running parallel to the limbus (arrows) are seen at the junction of the conjunctival autograft and the conjunctival bed.

All early FA showed intense fluorescence along the conjunctival bed early in the passage of dye (Figure 3.11). The conjunctival autograft appeared largely non-perfused or under-perfused in three of the four grafts. In conjunctival autograft where there was haemorrhage, the area of haemorrhage obscured the fluorescence (Figures 3.11 and 3.13) but in these conjunctival autografts even areas where there was no haemorrhage showed the absence of fluorescence indicating poor or absent circulation (Figure 3.11). In all these

early FAs, 0–2 small vascular twigs were seen at some point along the edge of the conjunctival bed and multiple fluorescent spots were seen in the underlying scleral bed. One of the four early FAs (one-day postop) showed an extensive network of vessels in the conjunctival autograft, unlike the other three (Figure 3.11). Tissue leakage of dye was evident as late hyperfluorescence in all conjunctival autografts with early FA indicating a persistent breach in the blood–tissue barrier (Figure 3.11).



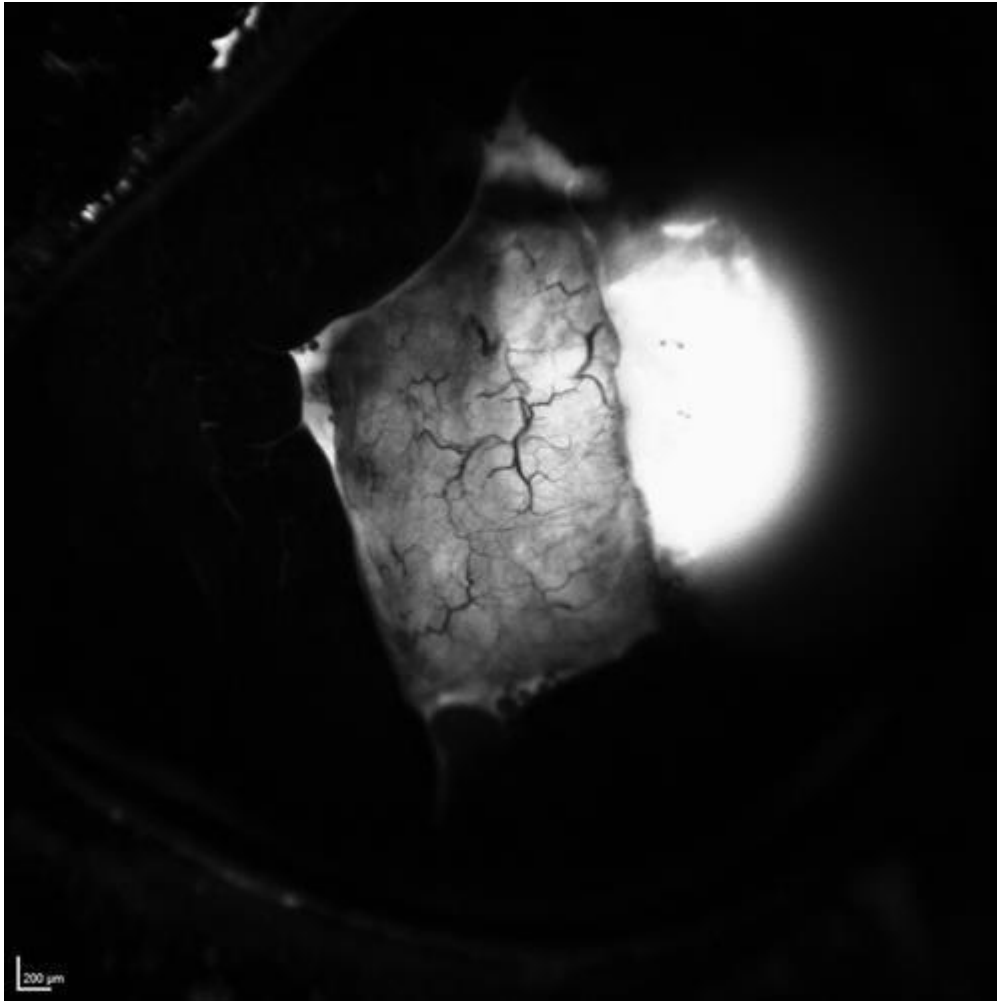
*Figure 3.13: Image of the conjunctival autograft of a patient at 3 days postoperative (A) Slit lamp diffuse anterior segment photograph of conjunctival autograft (B) Anterior segment fluorescein angiogram at 56 seconds.*

**(A) There is an area of diffuse haemorrhage involving almost the entire conjunctival autograft. (B) The conjunctival autograft shows a large area of masking corresponding to the diffuse haemorrhage seen in (A) obscuring the underlying fluorescence. The conjunctival bed shows intense fluorescence (accentuated by the light reflection) due congestion of the conjunctival bed.**

In the only late FA, the conjunctival bed showed three sites from which feeder vessels connected to a well-established network of vessels in the conjunctival autograft. Some of these vessels filled early in the sequence (afferents) and others late (efferents). Two areas in the conjunctival autograft remained hypo-fluorescent for 7 seconds, compared to other areas, before the vascular network became visible, suggesting a degree of residual ‘relative under-perfusion’. This conjunctival autograft did not demonstrate any leakage/persistent fluorescence, indicating re-establishment of the blood–tissue barrier.

Disappearance of dye (drainage) from conjunctival bed was earlier than from the conjunctival autograft in all cases. One conjunctival autograft showed increased fluorescence of the underlying scleral bed rather than of the conjunctival autograft itself. Here stagnant columns of blood were seen in the conjunctival autograft at this time-point

(Figure 3.14).



*Figure 3.14: Anterior segment fluorescein angiogram at 10 seconds of the conjunctival autograft of a patient at 2 days postoperative.*

**The conjunctival autograft shows increased fluorescence of the underlying scleral bed rather than of the conjunctival autograft itself. It also shows stagnant columns of blood.**

### 3.4 Discussion

Reperfusion injury is a well-known pathological condition that is characterized by initial phase of ischaemia to an organ or tissue which is then followed by restoration of blood supply and simultaneous re-oxygenation. Early reperfusion is essential for the rescue of tissue or organ suffering from ischaemia but chronic reperfusion injury can be detrimental to the function of the organ (380). The classic example of this is organ transplantation such as renal and liver (381). With autologous conjunctival transplants, reperfusion injury was clearly manifest but functional implications were less important.

Our sequential observation of the conjunctival autograft confirmed that the changes occurring in the conjunctival autograft were part of the reperfusion injury process. Reperfusion injury can start as early as 1 day postoperative in the form of haemorrhage and swelling of the graft. Further evidence of this is provided by the FA where the day-1 angiogram showed hyperfluorescence of the conjunctival autograft suggesting leakage. Harvesting of the free conjunctival autograft severs all vascular and lymphatic connections rendering the tissue, including the vessel trunks in it, ischaemic. When the conjunctival autograft vessels establish connections with the vessels in the new bed, from both surrounding conjunctiva and the episclera, blood flows into the ischaemic vessels of the conjunctival autograft. These vessels swell, leak or haemorrhage to give the dramatic clinical features seen in the first few postoperative days. Reconnection between the graft and the bed starts during the first week. This study indicates that all patients having conjunctival autograft will demonstrate patchy or diffuse haemorrhage in the first week and swollen grafts due to oedema and/or transudation from the blood vessels. These changes do not displace the graft or cause it to fall off; nor do they lead to sloughing of the conjunctival autograft epithelium, which remained intact in all cases at all time-points. By 2 months, most of the swelling and haemorrhage had resolved but the conjunctival autograft demonstrated under-perfused areas where the vascular network was poor or ill-defined. However, no necrotic area was noted in any conjunctival autograft suggesting that the areas with poorly defined vasculature were receiving adequate oxygen.

Changes were also seen in the conjunctival bed surrounding the conjunctival autograft. The edge of the conjunctiva was hyperaemic and swollen and haemorrhage was also seen in some places. Fibrin glue is known to 'seal' vessels and is used for haemostasis (382).

As fibrin glue was also used to attach the conjunctival bed, it is likely that the clinical picture seen, both in the conjunctival bed and the conjunctival autograft was influenced by its presence. Fibrin glue has been shown to mechanically interfere with epithelial cell migration which proceeds normally once the glue dissolves in 10–14 days (383). The physical presence of the glue at the site between the conjunctival autograft and the conjunctival bed could also have influenced the re-establishment of vascular connections. Resolution of the oedema of the conjunctival bed corresponded to the appearance of 'shunt' vessels that were noted to connect severed vessels in the bed. These shunt vessels were seen clinically in the conjunctival bed of two eyes. A continuous remodelling of the vasculature occurs in the postoperative period as new connections appear and some disappear. Eventually a mature vasculature is established which remains permanent. The scleral bed also contributes to the re-vascularization of the conjunctival autograft. These vessels were seen as large (relatively thicker) trunks but were sparse and not seen in every case.

Although the edges of the conjunctival autograft were closely approximated to the conjunctival bed intraoperatively, gaps were noted between the edges at places, in some cases, in the postoperative period. This represented a retraction of the tissue, exposing the sclera/episclera. This exposed area initially stained with fluorescein but was rapidly covered by migration of epithelial cells from the conjunctival bed. It is possible that the epithelium on the 'ischaemic' graft is less likely to respond by proliferation and migration compared to the epithelium on the conjunctival bed. These epithelized gaps persisted as thin furrows that showed pooling of fluorescein dye. The epithelial migration too could have been influenced by the fibrin glue applied (383).

At 6 months postoperative, all grafts and beds had settled completely and all haemorrhage and swelling had resolved indicating complete re-establishment of vascular and lymphatic connections.

The donor site changes all resolved satisfactorily although complications of telangiectasia and pyogenic granuloma were seen in one patient each. In the majority, the donor site

conjunctiva settled satisfactorily indicating that covering the donor site with conjunctiva and use of fibrin glue, restores conjunctival integrity. Exposed tenons can cause pyogenic granuloma formation and adequate cover should be ensured to avoid this complication. The changes described in the conjunctival autograft are not be confused with conjunctival recurrence of pterygium (282). Most recurrence occurs in the first 6 months, which is the maximum time taken for all changes in conjunctival autograft to completely resolve. Conjunctival recurrence of pterygium precedes corneal involvement and appears as an area of focal vascularity and swelling that increases over time as it progresses towards the limbus. Re-perfusion injury on the other hand, although also associated with vascularity and swelling, is more diffuse, usually is associated with conjunctival haemorrhage and the changes regress with time.

Fluorescein angiography data were limited on account of the single time-point and small number of patients studied thus no definitive conclusions could be drawn from these findings. However, some observations were made that helped to corroborate the clinical inferences made above. Reperfusion from the conjunctival and scleral beds was evident. Early clearance of dye from the conjunctival bed compared to the conjunctival autograft suggests that the lymphatic and efferent vasculature was more efficient in the bed than in the conjunctival autograft, which took longer to re-establish.

The small number of patients available to do FFA was a limitation in this study. The unique thing about this study is that it offers explanations to several clinical findings during the healing process of conjunctival autografts and the donor bed after pterygium surgical excision which is something that was not fully understood before. In the future, more FFAs can be done for a bigger number of patients at more time points after the surgery.

# CHAPTER 4: MANAGEMENT OF ACTIVE AND ESTABLISHED CORNEAL NEOVASCULARISATION TO PREVENT VISUAL IMPAIRMENT

## 4.1 Introduction

Corneal neovascularization (NV) is a condition that can result in severe visual impairment (42). The normally avascular cornea may vascularize in situations in which a disequilibrium between angiogenic and antiangiogenic stimuli leads to a surplus of pro-angiogenic factors (such as vascular endothelial growth factor [VEGF], basic fibroblast growth factor [bFGF], and matrix metalloproteinases) and a deficiency in antiangiogenic angiostatin, and endostatin (56). Corneal NV could occur due to a wide range of infectious, inflammatory, degenerative, or traumatic disorders as well as chemical burns, limbal stem cell deficiency and prolonged contact lens wear (50, 384). Corneal vascularity is the single most important risk factor for graft rejection (200). Grafting onto vascularized corneal beds, which by definition are corneas that have NV in 2 or more quadrants or history of previous graft rejection, is known as high-risk transplantation because of the frequent occurrence of immune rejection (385). Deep vascularisation of the recipient may more than double the risk of graft rejection (44) (53).

Fine needle diathermy (FND) is a surgical procedure that is used in the treatment of corneal NV. It is a safe and effective method for corneal vessels occlusion (191). It was described by Harminder S Dua in Nottingham (120, 189). Faraj et al, 2014 (120), evaluated the efficacy of FND in occlusion of corneal vessels and they concluded that FND was most suitable for active old and mature vessels. This has also been confirmed by others (386). In 2015, Vita et al and Spiteri N (195) et al did FND successfully under angiographic guidance as they believe selective targeting of the afferent vessels is effective in reducing the area of NV while applying minimal thermal energy to the limbus.

It has been shown that vascular endothelial growth factor (VEGF) plays a crucial role in corneal NV in different pathological conditions (44). Anti-VEGF agents such as bevacizumab—a recombinant humanised monoclonal antibody that binds human VEGF-A isoforms and

prevents activation of VEGF receptors-were found to be beneficial in treating corneal vessels when injected (167). Anti-VEGF injections are indicated for active young vessels (189). Several studies have been conducted to evaluate the efficacy and safety of Avastin when used as subconjunctival injections to treat corneal NV (154, 161, 164, 193, 207, 387-392). Some of these studies have used Avastin injections as preconditioning treatment before keratoplasty to promote corneal graft survival and improve their prognosis.

It became later known that applying FND can lead to release of endothelial growth factors and those will be inhibited from causing further NV by the anti-VEGF agents that will be injected subconjunctivally (393). Based on that, several trials were conducted using combined FND and bevacizumab (192, 193, 394) and Koenig et al, Elbaz et al and Hussein et al showed that this combination is a well-tolerated and effective option to regress corneal NV as well as giving good results in patients with lipid deposition, children and preconditions the cornea for future keratoplasty.

We retrospectively reviewed 15 patients to compare the effects of FND alone, subconjunctival bevacizumab alone and the combined FND and subconjunctival bevacizumab injections on the NV and rejection rates in patients who had keratoplasty following treatment with any of the 3 treatment regimens.

## **4.2 Methods**

### **4.2.1 Ethical issues**

The work was conducted in accordance to the declaration of Helsinki. The work was classed as a 'healthcare evaluation project' and approved by the Clinical Quality, Risk and Safety directorate, Nottingham University Hospitals, NHS Trust (project number: 17-205c).

### **4.2.2 Patients**

Patients were seen in routine specialist corneal clinics under the supervision of Professor H Dua (consultant ophthalmologist) at a single centre based within the outpatients' clinic in the Ophthalmology department at Queen's Medical Centre, Nottingham University

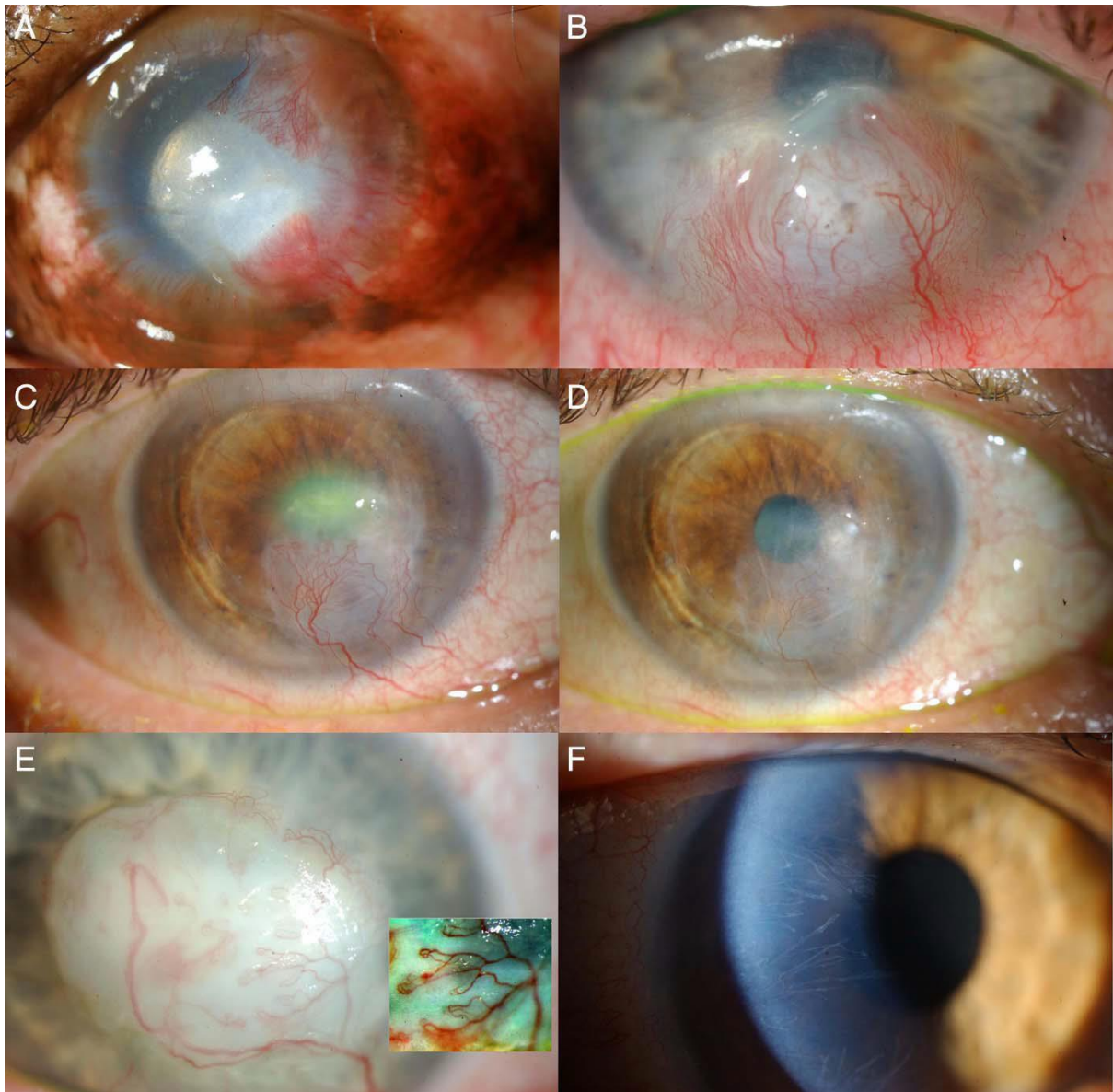


Hospitals NHS Trust. Patients were consented in theatre prior to the FND and subconjunctival procedures.

### **4.2.3 Clinical intervention and follow up**

The medical notes of 15 patients from Feb 2014 till July 2018 were reviewed and clinical and surgical information were extracted from the notes. As part of the standard protocol for managing patients with corneal NV in the department; visual acuity, pupillary reaction, intraocular pressure measurement, anterior segment bio-microscopic examination and fundus examination were performed at the first visit. High quality diffuse digital standardised imaging of the cornea and vessels were taken with a standard anterior segment camera at the first three visits and at the final visit. Visual acuity and intraocular pressure were measured at each visit.

Corneal vessels were examined with respect to stage; number in each quadrant, depth, superficial or deep and extent in to the cornea from periphery to centre. Grading of corneal vascularisation was performed using the corneal NV scoring method that was published by Faraj et al (please look page 11 chapter 1). Stages of NV were classified into five categories based on their clinical grades (Figure 4.1).



**Figure 4.1: Classification of corneal vessels (47).**

**(A) Active young: bright red, brush-like vessels invading in to the cornea with interstitial keratitis;(B) Active young: bright red vessels emerging from previously mature corneal vessels and invading a recurrent herpetic keratitis lesion;(C) Active old: dull red vessels with an active circulation of blood and surrounding oedema of the cornea.;(D) Partially regressed: The vessels are dull red with a slow circulation and some parts of the complex are less visible or have undergone attrition;(E) Mature, relatively large vessels with blood circulation but no established fine network (capillary) of vessels;(F) Regressed: Vessels appearing as fine white lines (ghost vessels) displaying the outline of the original vessels. The above figures were used as a guideline for the study.**

Severity of vascularisation was ascertained according to their scoring system (Faraj et al, 47) which included number of quadrants involved (1–4), depth of involvement (superficial=anterior one-third of corneal thickness or deep=posterior two-thirds) and location of vessels (peripheral=outer one-third, mid-peripheral=middle third and central=central third). A score of 1 was given for each quadrant affected; a score of 1 for

superficial vessels and 2 for deep vessels; and a score of 1 for peripheral vessels, 2 for mid-peripheral vessels and 3 for central vessels. When one quadrant had more than one vessel, the score attributed to the worst vessel(s) was counted for that quadrant. Thus, the maximum score for any quadrant would be 6 and for the whole cornea 24 (47).

Patients had 3 different treatment regimens. Group 1 had FND (n=3), group 2 had subconjunctival bevacizumab injections (n=4) and group 3 had combined FND and subconjunctival bevacizumab (n=8).

Six patients had corneal transplant surgery. As part of the standard protocol for management of patients with corneal NV in the department; all patients were given chloramphenicol 0.5% eye drops QID for one month, dexamethasone 0.1% eye drops QID for 2 months, then TID for two months and then OD for two months. At 6 months the drops were reduced to OD and continued for another six months.

As part of the standard protocol for management of patients with corneal NV in the department; patients were followed up at two weeks post-treatment and then at 1 month, two months and every 3 months till the end of one year.

### **FND technique and injection method**

Patients received subconjunctival injections of Avastin® around the limbus in the quadrant(s) affected (total dose of between 0.2 ml-0.3ml of the 5 mg/0.2 ml solution). The subconjunctival injections were administered in a clean room under topical anaesthesia. The subconjunctival injections were administered after FND in the same treated quadrants, close to the limbus. For fine needle diathermy, the eye was prepared as for extraocular surgery and draped. The ground electrode of a monopolar cautery (Covidien Force X) was attached to the patient's leg or abdomen. With topical anaesthesia under an operating microscope, a spatulated needle attached to a 10/0 monofilament nylon suture was inserted radially at the limbus in the vicinity of the vessel(s) to be cauterised. At a very low setting of 1 on the dial, the diathermy probe was brought in contact with the corneal needle and switched on until mild blanching of the stroma occurred. Further cautery central to the initial application was carried out to occlude the length of the vessel. When several vessels

were present close to each other, the needle was inserted into the stroma tangential to the limbus and the vessels cauterised in a single pass of the needle.

Adverse events, epithelial defects and haemorrhage, were recorded if present. For patients who underwent keratoplasty, graft clarity (oedema and lipid), evidence of graft rejection and recurrence of vascularisation were noted. All patients had the ability to access the 24 hours on call emergency eye service and contact the investigators for any queries during the study period.

#### **4.2.4 Outcome measurements**

Primary outcome measures were decreased corneal neovascularisation. Secondary outcome measures were improved/maintained Snellen's visual acuity, decreased corneal opacity related to lipid and reduced episodes of graft rejection (in patients with corneal grafts).

#### **4.2.5 Statistics and data analysis**

Statistical analysis was performed by using GraphPad Prism 8.02 (GraphPad Software La Jolla, CA, USA). Paired t test was used to analyse the data for the clinical scoring of NV.

### **4.3 Results**

We reviewed the notes of 15 patients who fit the criteria. The demographic data and procedures for the recruited patients is listed in table 4.1.

**Table 4.1 Demographic data and procedures done for each case at the end of one year.**

**Keratoconus: KC; Penetrating keratoplasty: PK; Herpes simplex keratitis: HSK; Herpes simplex zoster; Deep anterior lamellar keratoplasty: DALK; Limbal stem cell deficiency: LSCD; HZK; NK: Neurotrophic keratopathy; Left: L, Right: R**

	<b>Age Years (M/F)</b>	<b>Cause of corneal NV</b>	<b>Eye treated</b>	<b>Treatment type</b>	<b>NV stage</b>	<b>Lipid k</b>	<b>Graft performed and type</b>	<b>NV score Before treatment</b>	<b>NV score after treatment</b>	<b>VA before</b>	<b>VA after</b>	<b>Graft Survived</b>
<b>1</b>	26 (M)	KC with PK graft	L	FND	Active Old	No	No	3	0	0.3	0.06	N/A
<b>2</b>	50 (F)	HSK on a graft	L	FND+ Avastin	Active Old	No	No	12	4	0.04	0.04	N/A
<b>3</b>	70 (F)	HZK	R	2 ×FND+ Avastin	Active old	No	Yes (DALK)	12	4	CF	CF	Yes
<b>4</b>	31 (M)	Chemical burn with LSCD	L	1×FND 1×FND+ Avastin	Active Old	No	Yes (PK)	14	8	CF	0.24	Yes
<b>5</b>	50 (F)	HSK	L	FND+ Avastin	Active Old	Yes	No	5	0	0.16	0.1	N/A
<b>6</b>	50 (F)	HSK	L	FND	Active Old	Yes (Same)	No	5	5	1.3	0.96	Yes

<b>7</b>	38 (M)	NK stage 3	R	Avastin	Active Old	No	No	10	9	0.3	0.1	N/A
<b>8</b>  <b>Less than 1 year</b>	51 (F)	NK stage 3	R	Avastin	Active old	No	No	9	7	HM	HM	N/A
<b>9</b>	73 (F)	HSK	Left	2×Avastin	Active young	No	No	18	12	CF	0.92	N/A
<b>10</b>	68 (M)	Failed graft with Endothelial Decompensation	R	1×FND 1×FND+Avastin	Active old	No	Yes (PK)	3	0	CF	0.88	Y
<b>11</b>	34 (M)	Chemical burn	L	Avastin	Active Old	No	No	7	3	0.4	0.1	
<b>12</b>	61 (F)	HSK	L	FND+ Avastin	Active young	No	Yes (PK)	15	0	0.9	0.14	Yes
<b>13</b>	22 (M)	Not known(keratitis)	R	FND	Active Old	Yes	No	8	4	0.2	0.2	N/A
<b>14</b>	49 (M)	Infective Keratitis	L	FND+ Avastin	Active Old	No	Yes (PK)	4	0	HM	CF	Yes
<b>15</b>	53 (M)	KC	R	2×FND+ Avastin	Active Old	No	Yes (PK)	12	0	HM	0.2	Yes

Fourteen patients had active old NV while 1 patient had active young NV. Of the 15 patients, 8 were females (50%), and 8 were males (50%). Mean age was 48 years (range was from 22-73 years). Ten patients (67%) had 1 treatment session while 5 (33%) had 2 sessions of treatment. Three patients had FND, 4 patients had bevacizumab injections and 8 patients had combined FND and bevacizumab injections. Six patients had a graft with or after one of the 3 treatment options. Five of these grafts were a penetrating keratoplasty (PK) while one was a deep anterior lamellar keratoplasty (DALK). Five of the patients with a graft had no rejection episodes or failure. Only one patient who had a penetrating graft had an endothelial rejection episode 2 months after combined FND and bevacizumab injection and was aborted after appropriate treatment. Seventy-three% of the patients had improved visual acuity while 27% had stable vision. After treatment, 6 patients had mature NV, 5 patients had regressed NV and 4 patients had partially regressed NV. Three patients had lipid keratopathy. Two of them had remarkable reduction of lipid deposition following treatment while one remained the same. Table 4.2 shows the end stage of the NV in each of the 3 treatment regimens. The data reported is after one year from the start of treatment. Temporal decrease of NV was not analyzed.

*Table 4.2: End stage of NV in each of the 3 treatment regimens.*

<b>End stage</b>	<b>FND</b>	<b>Avastin</b>	<b>FND and Avastin</b>
<b>Regressed</b>	1	0	4
<b>Partially regressed</b>	0	1	3
<b>Matured</b>	2	3	0

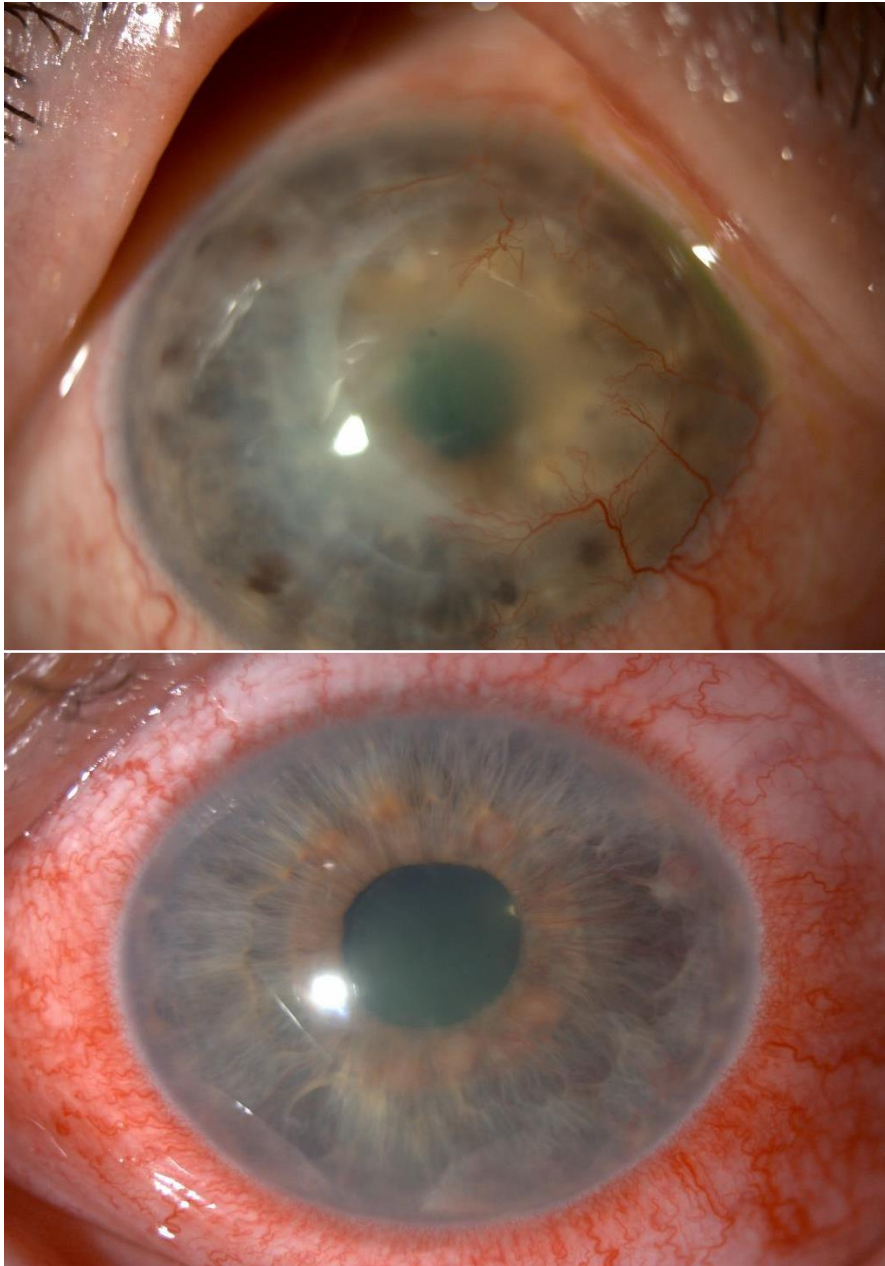
There was a mean reduction of 2.33 +/- 2.08 in the clinical scoring of NV in the FND group (p=0.1917, paired test, 95% confidence interval (CI) = 2.838-7.504), which was not statistically significant. For the Avastin injection group, the mean reduction was 3.25+/- 2.217 (p= 0.0609, paired test., 95% CI= 0.2783-6.778), which was not statistically significant. The mean reduction in the FND and Avastin group was 8.143+/-4.14 (p= 0.0020, paired test, 95% CI= 4.134-11.97), which was statistically significant. None of the patients had adverse events related to the FND or the subconjunctival injections.

That is already mentioned in table 4.1

Patients 2,5,6 gender, age and laterality is just a co-incidence.

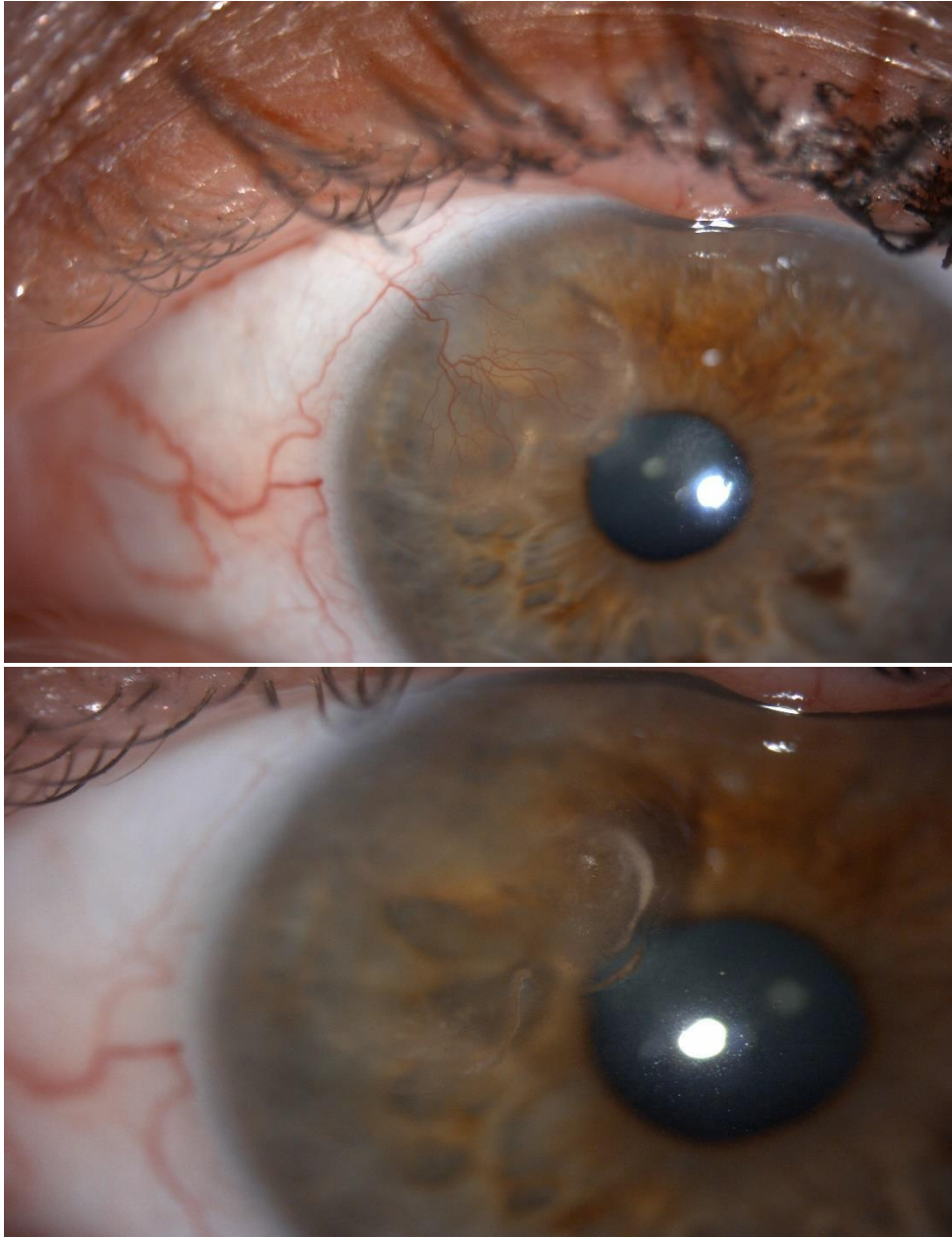


Figures 4.2- 4.4 are for 3 patients before and after treatment with different procedures.



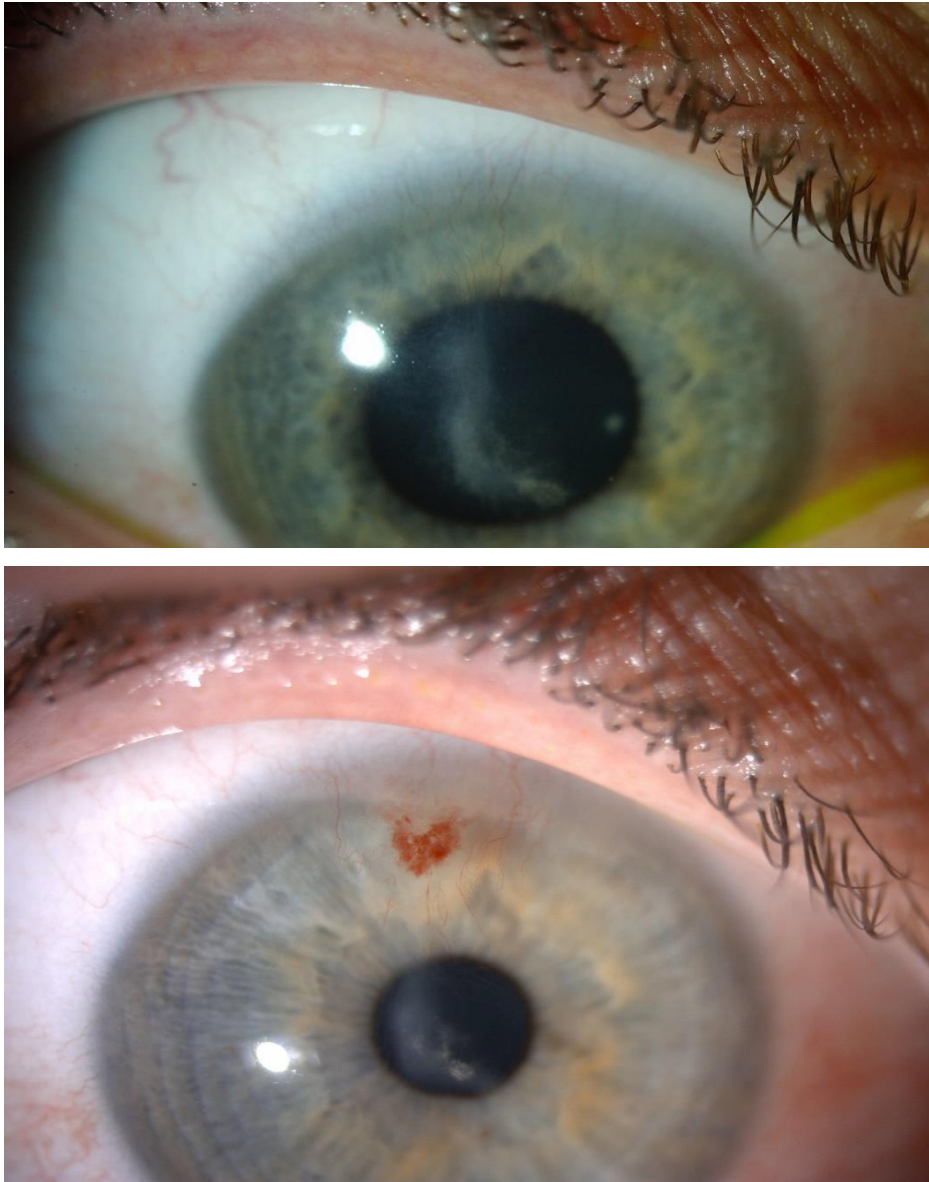
*Figure 4.2: Slit lamp anterior segment photographs of a patient before treatment (top image) and after treatment with FND, Avastin and PK (bottom image).*

**The bottom image shows no NV and a clear cornea.**



*Figure 4.3: Slit lamp anterior segment photographs of a patient before treatment (top image) and after treatment with FND, Avastin (bottom image).*

**There is no NV in the bottom image.**



*Figure 4.4: Slit lamp anterior segment photographs of a patient with lipid keratopathy before treatment (top image) and after treatment with FND (bottom image).*

**Top image shows superficial superior NV and dense lipid keratopathy. The bottom image shows less lipid keratopathy after FND.**

## **4.4 Discussion**

It is well established that corneal stromal vascularisation is both a risk factor and harbinger of rejection in penetrating keratoplasty. Topical steroids have been used to suppress corneal

vascularisation and to decrease corneal scarring. However, long term topical use may lead to cataract, glaucoma, superinfection and reactivation of herpes simplex virus and they are unlikely to cause complete regression of the vessels. There are no current NICE guidelines for established corneal neovascularisation.

The only definitive treatment that is available now is fine needle diathermy which is used as a routine for treatment of corneal NV. However, FND itself induces trauma to the vascular endothelium that might stimulate further vessel formation. It is hypothesised that if an anti-VEGF is combined with FND it will address any surgically induced factor for further vascularisation thus reduce the risk of rejection even further (393).

Several studies were performed where FND was used for corneal NV of different aetiologies (120, 189, 191, 386, 395). They reported that FND was a safe and effective method for both active and established vessels, can be used before PK to reduce rejection episodes and is associated with improvement of vision. However, Thatte et al (191) noted that the deposited lipids did not regress any faster by the occlusion of the corneal vessels. This was contradicted by Faraj et al (120), who reported that NV regression resulted in gradual reduction of lipid keratopathy if present. They also reported that active young vessels were usually a sign of underlying continuous pathology which keeps on inducing more vascularisation and such eyes will require treatment with anti-VEGF subconjunctival injections.

Combined FND and bevacizumab was also used. Koenig et al (192), used FND combined with bevacizumab eye drops as well as bevacizumab injections in some of the eyes. They reported good outcomes in terms of regression of the vascularised area and visual acuity improvement which was however statistically insignificant with some patients needing a second treatment session. They also reported better results in eyes that received injections and drops rather than drops therapy alone reported similar results using FND and

subconjunctival bevacizumab injections with reduction of lipid deposition (394). However, they noted that the management of cases with ongoing inflammatory was much more challenging. Elbaz et al (193), reported similar results in children with NV using combined FND and bevacizumab subconjunctival injections.

Many studies used subconjunctival bevacizumab and eye drops to treat NV. They reported statistically significant reduction of the calibre of vessels, area of NV (166, 167) (207, 390) (387, 396, 397).

Subconjunctival bevacizumab was also used successfully as an adjunctive treatment in vascularized corneas at the time of lamellar and penetrating keratoplasty to reduce the risk of graft rejection (388, 391). Vassileva et al and Symes et al reported that bevacizumab is an efficient and safe additional treatment option for improvement of prognosis in high-risk corneal transplantation with pre- and postoperative corneal NV.

In this retrospective study, there were 3 different treatment regimens. The limitations were the small number of patients in each group. The results show that there was a reduction in the clinical score of NV in all groups but the FND and Avastin injection group is the only group that showed a statistically significant reduction. This is most probably because FND occludes all stages of vessels and the VEGF produced by FND trauma to the vascular endothelium is blocked by the bevacizumab injections leading to effective and prolonged reduction of NV as our patients had a maintained effect for a year after the last treatment. Similar to the previous studies, some of our patients required a second session of treatment. We had no side effects related to the injections and the FND. Gradual reduction of lipid keratopathy was seen in 2 of the 3 patients following treatment. The improvement of visual acuity in 73% of the patients was related to the reduction of NV, reduction of lipid keratopathy and the reduction of corneal opacity in patients who had grafts. None of the patients had worse vision. We noted that patients who did not achieve partial regression or regression of vessels had stable, inactive vessels after the treatment which is considered a success as these patients had no further progression of NV or lipid deposition. Only one patient had an episode of endothelial rejection following treatment with FND and Avastin which was controlled by steroid treatment. Based on the results, a combination of anti VEGF with FND produces the best outcome of eliminating corneal neovascularisation with no reported side effects. Different treatments for HSK patients in this study were given

based on the clinical picture with regards to the NV stage and clinical scoring as treatment option is based on the NV status and not the aetiology of the NV. This is because the mechanism of corneal angiogenesis is the same for any etiology. The main inducer of NV in all etiologies is inflammation. All patients who had HSK in this study were females which was a coincidence as HSK almost affects both genders equally. Avastin was used for patients with NV secondary to NK as the NV stage was active which is usually a sign of underlying continuous pathology which keeps on inducing more vascularisation and such eyes will require treatment with anti-VEGF subconjunctival injections.

The main limitations in this study was the sample and the fact that data collection was retrospective. Future studies with larger sample sizes need to be carried out with longer follow-up to ascertain the effect of combined treatment for corneal NV and rejection rates following corneal grafting.

# **CHAPTER 5: AUTOLOGOUS CULTIVATED LIMBAL STEM CELLS TRANSPLANTATION FOR RESTORATION OF CORNEAL EPITHELIUM IN PATIENTS WITH LIMBAL STEM CELL DEFICIENCY DUE TO OCULAR BURNS (HOLOCORE Study)**

## **5.1 Introduction**

Ex-vivo expansion of limbus derived cells with or without a substrate (collagen, fibrin or amnion) is an essential option in the surgical management of total limbal stem cell deficiency whether unilateral or bilateral. Biopsies are obtained from the unaffected eye or from living related donors and are used to extract limbal epithelial cells or can be directly applied as explants on culture plates to produce stratified sheets to be used for transplantation (398-400). Excellent results were reported with long term follow-up following use of ex-vivo expansion of these stratified sheets (401).

Oral mucosal cells have been used as potential cells in the treatment of LSCD and it was reported that oral mucosal cells can successfully improve vision in patients with LSCD obviating the need for immunosuppression (402). Cultivated oral mucosal epithelial transplantation (COMET) utilizes a transplanted epithelial sheet which contains stem cells that help to reconstruct and sustain the integrity of the corneal surface and is a surgical option for bilateral LSCD (403).

Autologous Cultivated Limbal Stem Cell Transplantation (ACLST) is an advanced treatment for LSCD which utilizes a small limbal-biopsy specimen from the unaffected eye or from a normal limbal zone in case of bilateral burns, followed by in vitro expansion to generate a sheet of corneal epithelial cells including both differentiated and stem cells. The final product is named Hologlar and is a transparent round sheet that consists of 300,000 to 1,200,000 viable autologous human corneal epithelial cells, with an average of 3.5% limbal

stem cells as well as differentiated cells and stem cell derived transient amplifying cells. This epithelial sheet rests on a supportive fibrin layer and is kept in a nutrient transport medium (401,404,405).

This technique has the advantage of being autologous which means that no donor tissue is used and no immunosuppression is required.

Autologous cultivated limbal stem cells (ACLSC) have been obtained using standardized and optimized methods since 1998. Since then, ACLSCT was performed on more than 200 patients with moderate or severe LSCD in several clinical centres in Italy. The acquired experience has been reported in independent published studies (401, 404, 405) and in three Chiesi-sponsored, retrospective, case-series, non-randomised, non-controlled studies (HLSTM01, HLSTM02 and HLSTM04), that gathered all clinical information from all treated patients with available source documentation with a follow-up of up to 10 years. Specific amendments and improvements in quality and manufacturing have been introduced after 2007 to comply with the current legislation and regulations regarding Advanced Therapy Medicinal Products (ATMPs), in particular in respect of the quality of the reagents (recombinant growth factors, pharmacopoeia-grade reagents) and some excipients ( the supporting layer of human fibrin for cell attachment). The results of HLSTM04 study showed that after the introduction of improvements in quality and manufacturing of ACLSCT in 2007, most of the patients with moderate to severe LSCD due to ocular burns, who received cultured limbal stem-cell grafts for corneal transplantation, achieved a positive clinical outcome with a favourable safety profile. Improved visual acuity was achieved despite the majority of study population exhibiting stromal scarring. In addition, clinically- and functionally-beneficial effects from Holoclar were observed among patients who failed a full restoration of corneal epithelium and who are candidates for Holoclar re-treatment and keratoplasty. The data from these retrospective studies demonstrated the efficacy and safety of Holoclar for human use and were included as clinical data into the marketing authorization application for Holoclar which was filed by Chiesi Farmaceutici S.p.A. in March 2013 (application EMEA/H/C/2450).

Holoclar has been approved by the European Medicines Agency EMA only recently (Committee for



Medicinal Products for Human Use (CHMP) meeting 15-18 December 2014). During that meeting, the CHMP recommended Holoclar, the first advanced therapy medicinal product containing stem cells for usage in the European Union. The CHMP considered that Holoclar provided a first treatment option for this eye condition and recommended a conditional marketing authorisation because, although the data supplied by the applicant show that the medicine's benefits outweigh its risks, the data was based on retrospective studies and were not yet comprehensive. This data has been reported in independent published studies (401, 404, 405) and in three Chiesi-sponsored, retrospective, case-series, non-randomised, non-controlled studies (HLSTM01, HLSTM02 and HLSTM04). Therefore, an additional study (Holocore) on the use of Holoclar was conducted and this clinical trial CCD- GPLSCD01-03 has been agreed with the regulatory body in order to satisfy the need of additional and more comprehensive data obtained in a controlled setting.

### **5.2.1 Methods**

#### **5.2.2 Ethical issues**

The study was conducted in accordance to the declaration of Helsinki. All relevant study approvals were present before the actual started trial. Chiesi Farmaceutici S.p.A. (the sponsor of Holocore study) supplied us with all the relevant documents from the regulatory authorities before we started recruiting the patients. (REC reference number: 15/LO/1480).

#### **5.2.3 Patient recruitment**

Holocore is a multinational, multicentre, prospective, open label, uncontrolled clinical trial. Queens Medical Centre (Centre number 82602) was one of the 12 sites in 8 countries across Europe in which the study was carried out. It was conducted in routine specialist cornea clinics under the supervision of Professor Harminder Dua (Consultant Ophthalmologist and principal investigator of Holocore study).

#### **Inclusion Criteria**

Subjects had to meet all of the following inclusion criteria to be eligible for enrolment into the study:

1. Written informed consent prior to any study-related procedures
2. Adult male and female patients ( $\geq 18$  years old).
3. LSCD secondary to unilateral or bilateral physical or chemical ocular burns, with at least 1-2 mm<sup>2</sup> of undamaged limbus to harvest stem cells for expansion in culture. LSCD was considered for inclusion in the presence of superficial neo-vascularization invading at least two corneal quadrants with evidence of central corneal (6mm) involvement (including corneal neovascularisation, corneal opacity or corneal dyschromia).
4. Stability of LSCD, defined by a duration of disease of at least 24 months at the time of the screening visit and the presence of continuous epithelial cover by fluorescein staining scored as none or trace.
5. Presence of severe impairment in visual acuity defined by a score of 1/10th or below 20/200 at the Snellen chart (legal blindness) after best correction (i.e. Best Corrected Visual Acuity).
6. Absence of other clinical contraindications to ACLSC transplantation based upon investigators' judgment.
7. A cooperative attitude to follow up the study procedures (Caregivers in case of minors).

### **Exclusion Criteria**

The presence of any of the following excluded a subject from study enrolment:

1. LSCD of mild degree (i.e. below 2 quadrants of neo-vessel invasion without central corneal), due to a recent burn (less than 24 months before screening), or secondary to medical conditions other than burns (i.e. radiotherapy).
2. Severe ocular inflammation according to the Efron Grading Scale for Contact Lens complications.
3. Presence of eyelids malposition.
4. Conjunctival scarring with fornix shortening.
5. Severe tear secretion deficiency, determined by Schirmer's test type I ( $< 5$  mm/ 5 min).
6. Corneal anaesthesia and conjunctival anaesthesia.

7. Active local or systemic infections at the time of screening.
8. Diagnosis of local or systemic neoplastic disease.
9. Congenital diseases (i.e., Aniridia).
10. Bilateral inflammatory diseases (i.e. Stevens-Johnson syndrome, pemphigoid).
11. A pre-existing blindness precluding a functional recovery.
12. Female subjects: pregnant or lactating women and all women physiologically capable of becoming pregnant (i.e. women of childbearing potential) unless they were willing to use one or more reliable methods of contraception (e.g. oral contraceptives, IUD, tubal ligature). Reliable contraception should be maintained throughout the study.  
  
A urine pregnancy test was performed at the screening visit for all women of childbearing potential and repeated before biopsy and treatment. Any postmenopausal women (physiologic menopause defined as “12 consecutive months of amenorrhea”) or women permanently sterilized (e.g. tubal occlusion, hysterectomy or bilateral salpingectomy) was a potential candidate for enrolment into the study
13. Allergy, sensitivity or intolerance to concomitant drugs or excipients (Hypersensitivity to any of the excipients listed in section 6.1 or to bovine serum and murine 3T3-J2 cells).
14. Contraindications to the local or systemic antibiotics and/ or corticosteroids foreseen by the protocol.
15. Contraindications to the surgical procedure.
16. Clinically significant or unstable concurrent disease or other clinical contraindications to stem cell transplantation based upon investigators’ judgment or other concomitant medical conditions affecting grafting procedure.
17. Patients unlikely to comply with the study protocol or unable to understand the nature and scope of the study or the possible benefits or unwanted effects of the study procedures and treatments.
18. Participation in another clinical trial where investigational drug was received less than 4 weeks prior to the screening visit.

## 5.2.4 Clinical Intervention and follow up

Fourteen clinic visits were performed during the study. The study duration period was 19 months +/- 15 days:

Five to 6 weeks- screening visit up to biopsy.

Six months roll-in period starting from the biopsy and up to autologous limbal stem cells transplant ACLSCT.

Twelve months from the autologous limbal stem cells transplant ACLSCT up to endpoint visit.

Table 5.1 shows the follow up scheme of HOLOCORE.

*Table 5.1: Details of patient's visits during the study course*

<b>Name and code of visit</b>	<b>Interpretation</b>
Visit 0 (V0)	Date of recruitment
Visit 1 (V1)	Two weeks from V0
Visit 2 (V2)	Biopsy day (Four weeks from V1)
Visit 3 (V3)	Two months after the Biopsy
Visit 4 (V4)	Four months after the Biopsy
Visit 5 (V5)	Day -13 +/- 2
Visit 6 (V6)	Transplantation day
Visit 7 (V7)	One day after V6 (done over the phone)
Visit 8 (V8)	Four +/- 1 day after V6
Visit 9 (V9)	Two weeks +/- 3 days after V6
Visit 10 (V10)	Twenty nine days +/- 5 days after V6
Visit 11 (V11)	Three months +/- 14 days after V6
Visit 12 (V12)	Six months +/- 14 days after V6

Visit 13 (V13)	Nine months +/- days after V6
Visit 14 (V14)	End of the study, 1 year +/- 14 days after V6

#### **A) Standard haematology, blood chemistry and infectious assessment**

Standard haematology and biochemistry and infectious assessments were performed at the prescribed visits as in at the phlebotomy clinic at Queen Medical Centre and transferred to a central laboratory in Germany for analysis. The blood samples for standard haematology and blood chemistry were collected in the morning after an overnight fasting (10 hours) at screening visit, visit 5 and visit 10. The blood samples for infectious assessments were collected at visit 1 and visit 2. The collection was always done after vital signs measurements and before any further study assessment.

The following parameters were assessed:

**Haematology:** Red blood cells count, white blood cells count and differential, total haemoglobin, hematocrit , platelets count and prothrombin time.

**Blood Chemistry:** Creatinine, Blood urea nitrogen, fasting serum glucose, Aspartate aminotransferase, Alanine aminotransferase, Gamma-glutamyl transpeptidase, total bilirubin, albumin, Alkaline phosphatase, sodium, potassium, calcium, and chloride electrolytes.

**Infectious Assessment:** HAV-Ag, HAV-IgG, HAV-IgM, HBsAg, HBsAb,

HBcAb, HCVAg, HCVAb, HIV1&HIV2 Ab and Ag, Treponema Pallidum Ab, HTLV – Human T Lymphotropic Virus-Ag and Ab, HWN -Human West Nile virus- Ab measurement.

#### **B) Surgical procedures**

Holocore study includes obtaining a biopsy from the unaffected eye (or from a normal zone in bilateral LSCD cases) then a single administration of Holoclax implant through a dedicated surgical procedure of corneal surface scraping and product application. Both the biopsy and Holoclax implantation were performed at the Ophthalmology theatre at Queens Medical Centre by the same surgeon (Professor Harminder Dua).

## **Biopsy (Visit 2)**

The patients had corneal biopsy taken from the unaffected limbus of the contralateral eye according to the following multi-steps procedure:

- Topical anaesthesia was procured with parabolbar anaesthesia with marcaine without and adrenaline.
- Ocular surface lavage was performed with balanced salt solution (BSS).
  - A horizontal clear-cornea incision, 2 mm long, was made with a disposable scalpel of 15 - 30°, just anterior to the limbal vessels. Lamellar dissection in a "pocket" fashion using a disk lamellar knife or a crescent blade (the depth was about 50 to 100 µm to enable the lifting of the lamella from the corneal limbus) was made from the incision extending posterior to the limbus. The conjunctiva at the limbus was then incised to expose the posterior limit of the lamellar dissection. The sample was obtained from the upper area.
  - Two vertical incisions from each end of the horizontal incision were then made in the limbus and adjacent sclera with a disposable scalpel of 15 - 30°. A posterior horizontal incision was then made to join the posterior end of the vertical incisions to complete the excision of a 2mm piece of limbus. Caution was not used to coagulate bleeding vessels before the tissue sample was removed, in order to avoid damaging the stem cells.
  - Biopsy was inserted in the sterile test tube containing the transport medium.
  - The conjunctiva was sutured (tacked down) with 2 nylon 10/0 sutures.

## **Treatment after biopsy**

Patients received topical antibiotic prophylaxis with single-dose preservative-free levofloxacin, 3-4 drops three times per day for 7 days.

## **Holocalr implantation procedure (Visit 6)**

Surgery was performed according to the following procedure:

- General anaesthesia was done.
- Limbal peritomy was done a few millimetres outside the limbus, with proper coagulation. The bulbar conjunctiva was freed for about 4-5 mm in order to create a pocket into which Holoclar implant was inserted.
- Pannusectomy for removal of corneal fibrovascular layer of conjunctival origin was done, trying to find the cleavage level between the pannus and the cornea for avoiding, when possible, keratectomy.
- Lavage with BSS was done, whilst checking for an absence of consistent blood loss that could form blood collections ('sacks') under the epithelial graft.
- Holoclar implant was transferred from the transport container to a suitable dish. Under the microscope it was possible to recognize the fibrin "nude" side (smooth and translucent) from the cells-seeded side (rough). It is absolutely crucial to place the fibrin sheet with the cultivated cells outside and not upside down.
- Holoclar was allowed to slide onto the recipient's prepared graft area assisting with BSS and slight traction with tweezers at the edge of the graft as necessary.
- The excess fibrin sheet (Holoclar) was trimmed and the edge covered with the conjunctiva applying 2 or 3 stitches (sutures) of Vicryl 8/0.
- Eyelids were kept closed with Steri-strips.

#### **Treatment after administration of Holoclar**

- Systemic antibiotic treatment: Doxycyclin 100 mg tablets twice per day for 2 weeks.
- Systemic corticosteroid treatment: Prednisone P.O. at a daily dose of 0.5 mg/kg for 2 weeks after the implant at a daily dose to a maximum of 25 mg for 2 weeks, then tapered to 0.25 mg/kg (maximum 12.5 mg) per day for 1 week, to 0.125 mg/kg (maximum 5.0 mg) per day for the following week and then stopped. In case of persistent inflammation, the corticosteroid treatment was allowed to be maintained or reintroduced.

- Topical corticosteroid treatment: 2 weeks after surgery, preservative-free dexamethasone (dexafree 1 mg/ml PF B&L) eye drops for a total of 4 weeks: 1 drop TID for 2 weeks followed by 1 drop bid for 1 week and then 1 drop QID for 1 week. Topical corticosteroid can be maintained for longer in case of persistent inflammation according to the judgment of the doctor.

**C) Details of the visits:**

All of the visits and medications received by the patient were recorded in the patient's medical notes as well as in electronic CRF. I was the coordinator of this study. I was responsible for performing all the clinical examination during all the visits and recording the data on the medical notes as well as doing all correspondence with the sponsor of the study. The slit lamp images were taken by the imaging technicians in the department.



*Table 5.2: Details of procedures carried out in each visit during the study course*

VISITS	Pre-Screen.	Screen Roll-in start	Limbal Biopsy	Pre-Transp	Pre-Transp	Confir mation	ACLST	Post-Transp	Post-Transp	Post-Transp	Post-Transp	Post-Transp	Post-Transp	Post-Transp	End of Study
	V0	V1	V2 <sup>(1)</sup>	V3	V4 <sup>(2)</sup>	V5	V6	V7 <sup>(4)</sup>	V8	V9	V10	V11	V12	V13	V14
<i>Date from 1<sup>st</sup> ACLST</i>	Day-225 ± 30	Day-210 ± 30	Day-180 ± 30	Day-120 ± 30	Day -60 ± 30	Day -13 ± 2	Day 1	Day 2	Day 4 ± 1	Day 15 ± 3	Day 29 ± 5	Day 90 ± 14	Day 180 ± 14	Day 270 ± 14	Day 360 ± 14
<b>ACTIVITY/ ASSESSMENT</b>															
Informed Consent	✓														
Demographic Data	✓														
Inclusion/ Exclusion Criteria		✓				✓ <sup>(3)</sup>									
Medical History and concomitant diseases	✓														
Previous and concomitant medications	✓	✓	✓	✓	✓	✓	✓	✓	✓	✓	✓	✓	✓	✓	✓
Adverse Events (AE)	✓	✓	✓	✓	✓	✓	✓	✓	✓	✓	✓	✓	✓	✓	✓
Adverse Event of Special Interest (AESI)	✓	✓	✓	✓	✓	✓	✓	✓	✓	✓	✓	✓	✓	✓	✓
Physical examination <sup>(5)</sup>	✓	✓	✓	✓	✓	✓	✓		✓	✓	✓	✓	✓	✓	✓
Vital signs		✓	✓	✓	✓	✓	✓		✓	✓	✓	✓	✓	✓	✓
Haematology and blood chemistry		✓				✓					✓				
Infectious Assessment		✓	✓												
ECG		✓				✓									
Urine Pregnancy Test		✓	✓			✓	✓								

VISITs	Pre-Screen.	Screen Roll-in start	Limbal Biopsy	Pre-Transp	Pre-Transp	Confirmation	ACLST	Post-Transp	Post-Transp	Post-Transp	Post-Transp	Post-Transp	Post-Transp	Post-Transp	End of Study
	V0	V1	V2 <sup>(1)</sup>	V3	V4 <sup>(2)</sup>	V5	V6	V7 <sup>(4)</sup>	V8	V9	V10	V11	V12	V13	V14
<i>Date from 1<sup>st</sup> ACLST</i>	Day-225 ± 30	Day-210 ± 30	Day-180 ± 30	Day-120 ± 30	Day -60 ± 30	Day -13 ± 2	Day 1	Day 2	Day 4 ± 1	Day 15 ± 3	Day 29 ± 5	Day 90 ± 14	Day 180 ± 14	Day 270 ± 14	Day 360 ± 14
<b>ACTIVITY/ ASSESSMENT</b>															
Corneal epithelial defects by fluorescein staining		✓	✓	✓	✓	✓					✓	✓	✓	✓	✓
Superficial corneal neovascularization		✓	✓	✓	✓	✓					✓	✓	✓	✓	✓
Digital photography		✓	✓		✓	✓					✓	✓	✓	✓	✓
Best-Corrected Visual Acuity		✓		✓	✓	✓					✓	✓	✓	✓	✓
Ocular tonometry		✓	✓	✓	✓	✓					✓	✓	✓	✓	✓
Slit lamp examination: • Corneal endothelium • Anterior chamber		✓	✓	✓	✓	✓			✓	✓	✓	✓	✓	✓	✓
Conjunctival inflammation (limbal and bulbar)		✓	✓	✓	✓	✓			✓	✓	✓	✓	✓	✓	✓
Corneal sensitivity		✓	✓	✓	✓	✓					✓	✓	✓	✓	✓
Corneal involvement		✓	✓	✓	✓	✓					✓	✓	✓	✓	✓
Schirmer's test type I		✓													✓
Symptoms: • Pain • Burning • Photophobia		✓	✓	✓	✓	✓		✓ <sup>(6)</sup>	✓	✓	✓	✓	✓	✓	✓
NEI-VFQ-25 and EQ-5D-3L(Y) QoL questionnaires		✓				✓						✓	✓		✓
Limbal biopsy and shipment			✓												
ACLSC grafting procedure							✓		✓ <sup>(7)</sup>						

VISITs	Pre-Screen.	Screen Roll-in start	Limbal Biopsy	Pre-Transp	Pre-Transp	Confirmation	ACLSCCT	Post-Transp	Post-Transp	Post-Transp	Post-Transp	Post-Transp	Post-Transp	Post-Transp	End of Study
	V0	V1	V2 <sup>(1)</sup>	V3	V4 <sup>(2)</sup>	V5	V6	V7 <sup>(4)</sup>	V8	V9	V10	V11	V12	V13	V14
<i>Date from 1<sup>st</sup> ACLSCCT</i>	Day-225 ± 30	Day-210 ± 30	Day-180 ± 30	Day-120 ± 30	Day -60 ± 30	Day -13 ± 2	Day 1	Day 2	Day 4 ± 1	Day 15 ± 3	Day 29 ± 5	Day 90 ± 14	Day 180 ± 14	Day 270 ± 14	Day 360 ± 14
<b>ACTIVITY/ ASSESSMENT</b>															
Impression cytology							✓								
Systemic corticosteroid treatment							----- ✓ -----			Tapering	Stop				
Systemic antibiotic treatment							----- ✓ -----			Stop					
Topic corticosteroid treatment									✓	Tapering Stop in 2 weeks					
Short course of local antibiotic prophylaxis			✓												
ACLSC graft failure Check															✓ (8)
Investigator's Judgement											✓	✓	✓	✓	✓
Study termination															✓ (9)
Independent Assessors Evaluation		✓ (10)													✓

The study was terminated at this visit 14 for all patients who are judged as a success.

### **5.2.5 Outcome measurements**

Efficacy measurements were made in terms of the degree of superficial corneal neovascularisation and epithelial defects. Safety measurements were specifically investigated with reporting any adverse effects related to the biopsy and Holoclar transplantation. Patients had the ability to access the 24 hour on call emergency eye service, and at the same time were provided with contact numbers for investigators for any queries during the study period.

## **5.3 Results**

### **5.3.1 Recruitment**

We were able to recruit 2 patients to this study as these were the only patients that met all the eligibility criteria at the time of recruitment. The demographic data for the recruited patients is listed in table 5.2. The two recruited patients in this study are reported as individual case reports.

*Table 5.3: Demographic data of HOLOCORE cases.*

**LSCD: Limbal stem cell deficiency.**

	<b>Participant Trial Code</b>	<b>Age Years (M/F)</b>	<b>Cause of LSCD</b>	<b>Date of recruitment</b>	<b>Eye treated</b>	<b>Last follow up visit</b>
1	82602-01	57 (M)	Acid chemical burn	07/02/2017	Right	19/12/2018
2	82602-02	27 (F)	Chemical burn (Unknown)	08/02/2017	Left	19/12/2018

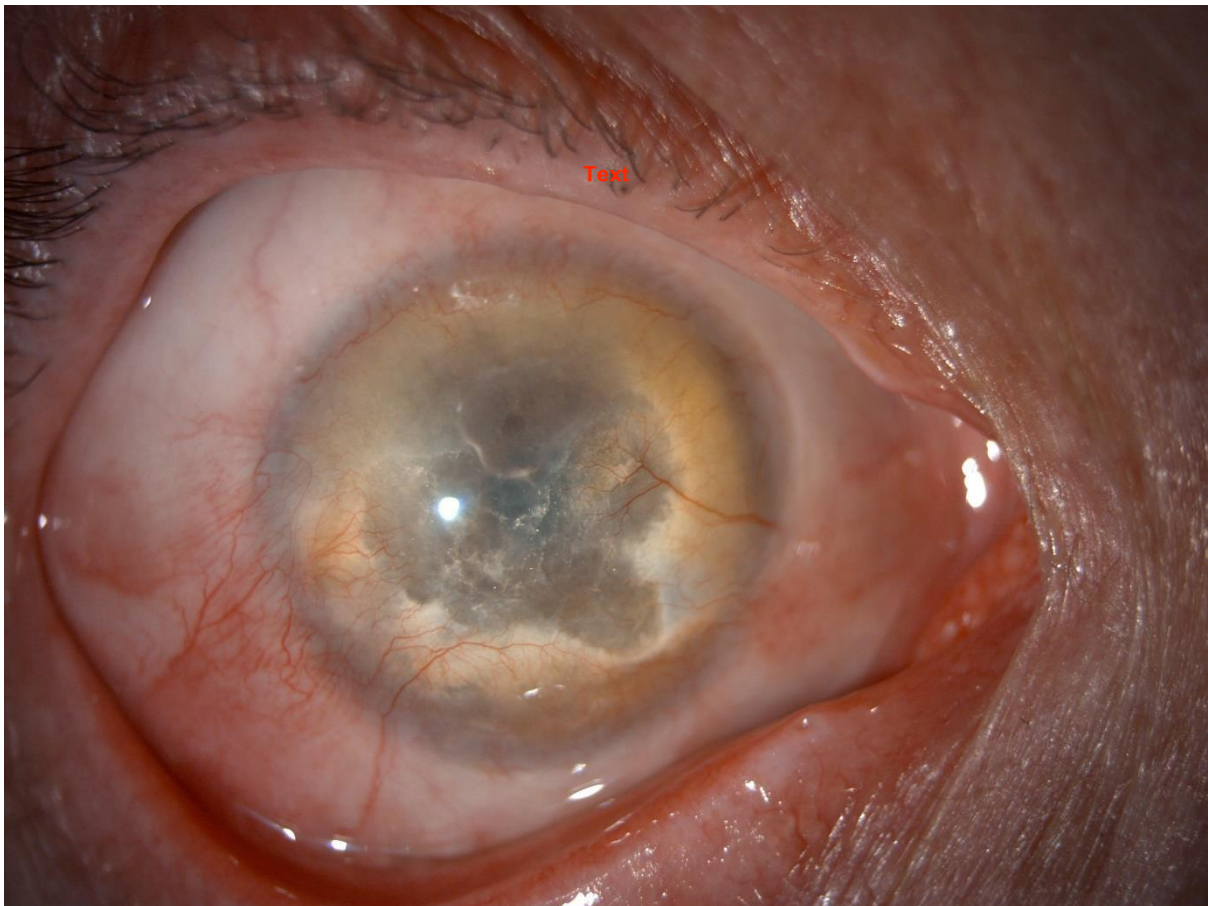
### **5.3.2 Cases**

#### **Case one (82602-01)**

This patient was a 57 year old gentleman who was recruited on the 7<sup>th</sup> of February 2017 for treatment of the right eye. He had a dense fibrovascular membrane involving the central cornea due to an acid chemical burn in 1993. He had severe superficial corneal NV in all 4 quadrants and his vision was hand movement. The 4 quadrants of the cornea were invaded with superficial corneal NV and they extended to the central cornea (Figure 5.1). The visual acuity was hand movement. He had normal intraocular pressure in both eyes throughout the study (range from 8-12). Schirmer test type I was 10 mm on V1. He had normal corneal sensitivity which was assessed by a cotton tip. On V1, the patient had moderate photophobia but no pain or burning sensation. His physical examination and vital signs were always normal. He was started on Citalopram tablets 20 mg once daily (selective serotonin re-uptake inhibitor) because of anxiety related to holocore trial and continued for the whole period of the trial. Otherwise, he had no history of any medical conditions. His infectious assessment was always normal. The biopsy was done on 30<sup>th</sup> of May 2017. The biopsy was taken from the superior limbus and placed in a sterile tube containing the transport

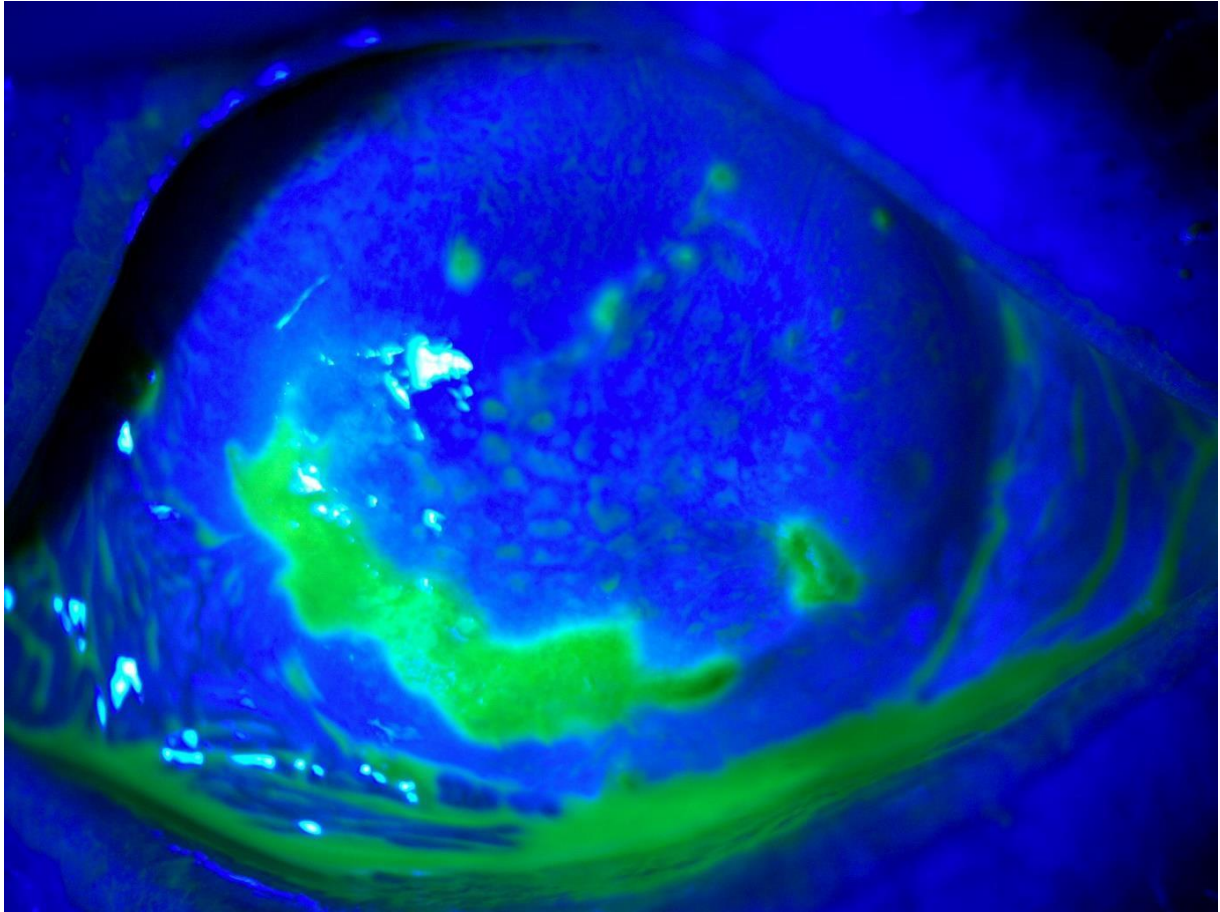
medium. The standard operating procedures were followed carefully and the biopsy was shipped on the same day to Holostem (The site where the biopsy will be processed into Holoclar). The patient was prescribed preservative-free levofloxacin eye drops, three times per day for 1 week. Conjunctiva was closed using 2 sutures. The patient presented to the eye casualty 2 days after the biopsy procedure with pain which was due to a broken suture and was removed. The other suture was removed 2 weeks after the biopsy procedure. The wound was healing well underneath. There were no adverse events. The holoclar implant was performed on the 6<sup>th</sup> of December 2017. Holoclar was delivered on the same day to the hospital inside a sterile, plastic Petri dish which was placed in a secondary container that was only removed in the operating theatre. The surgery was done under general anaesthesia. The surgery was successful and Holoclar was in place. The patient was started on the treatment mentioned before. On V8, the ocular bandage was removed and replaced with new bandage, Steri-strips and shield. He continued on Doxycycline tablets, 25 mgs of prednisolone tablets. On V9, the ocular bandage was removed. The vision was not recorded on that visit. The patient had mild burning sensation and photophobia but no pain. He was asked to stop doxycycline, taper Prednisolone to 12.5 mgs and to start dexafree eye drops TID. There were no adverse events. On V10, the vision was counting fingers. On examination, he had marked limbal and conjunctival hyperaemia with an epithelial defect (> 2mm) (Figure 5.2). He had a deep central corneal opacity. The anterior chamber was deep and quite. He was prescribed levofloxacin 5mg/ml eye drops QID. Dexafree eye drops were tapered by 1 drop every week. He was seen two weeks later. His vision was still counting fingers and he had moderate pain and photophobia. The epithelial defect was much larger and was involving the centre of the cornea (Figure 5.3). A bandage contact lens (BCL) was inserted and Celluvisc 0.5% eye drops QID were prescribed in addition to the levofloxacin eye drops that he was using. It was decided that the patient should be withdrawn from the trial and the epithelial defect was reported to Chiesi as a serious adverse event. He was listed for penetrating keratoplasty with autolimbal stem cell transplant. The patient had a persistent epithelial defect for 5 months despite eyelid taping with Steri-strips so a decision was taken to list him for Omnigen transplant. During these 5 months he was on levofloxacin preservative free eye drops QID, predsol preservative free eye drops 0.5% and VisuXl 6 times per day. The Omnigen was transplanted on 20<sup>th</sup> June 2018 and sutured. A BCL was inserted. Gradually over 3 months, the eye became more comfortable. During that time the patient

was seen frequently and the BCL was replaced until the epithelial defect healed completely (Figure 5.4). The final vision was hand movement and there were superficial NV in all quadrants involving the corneal centre. The patient is currently on the waiting list for penetrating keratoplasty with autolimbic stem cell transplant.



*Figure 5.1: Slit lamp anterior segment photographs of Case 1 on VI.*

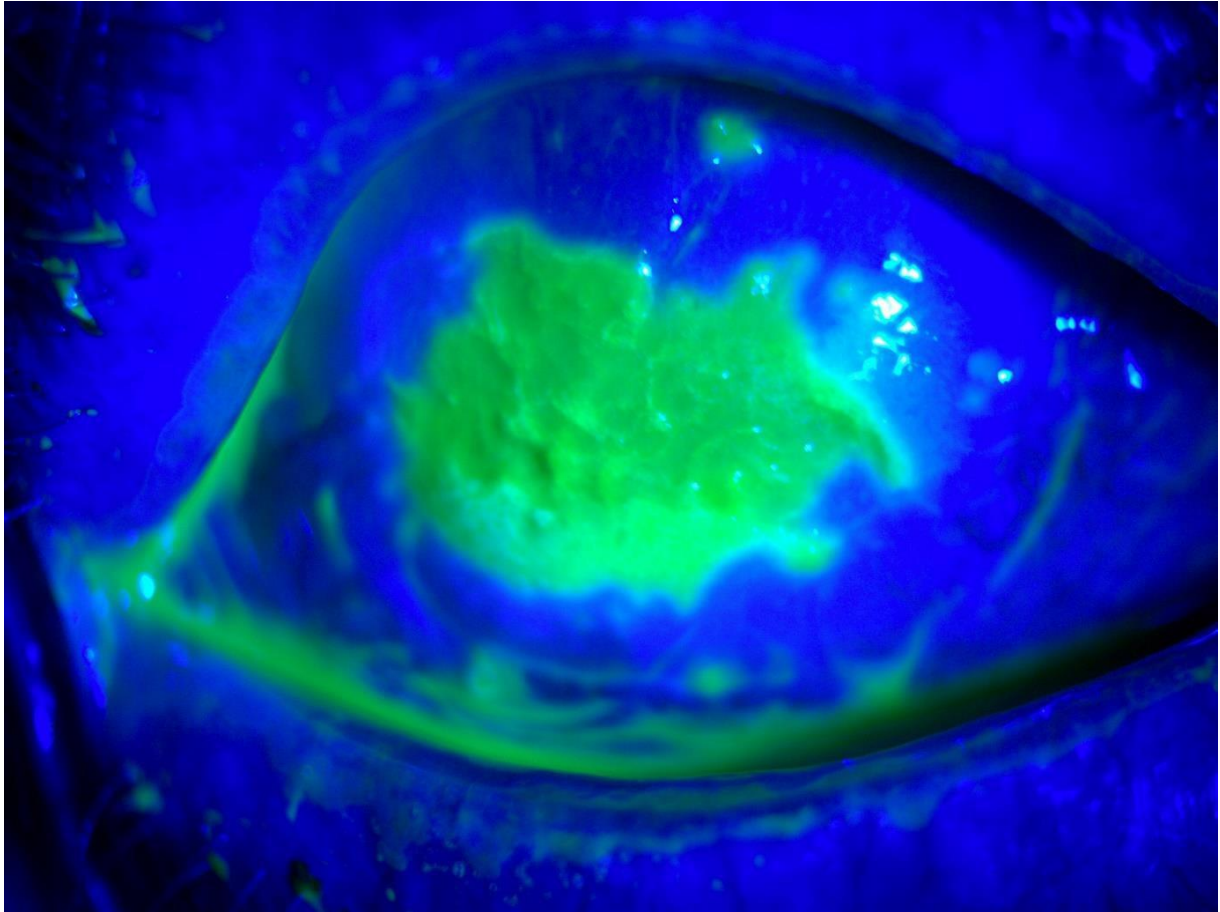
**Dense fibrovascular pannus with central corneal opacity.**



*Figure 5.2: Cobalt blue filter image with fluorescein sodium 2% eye drops of Case 1 on V10.*

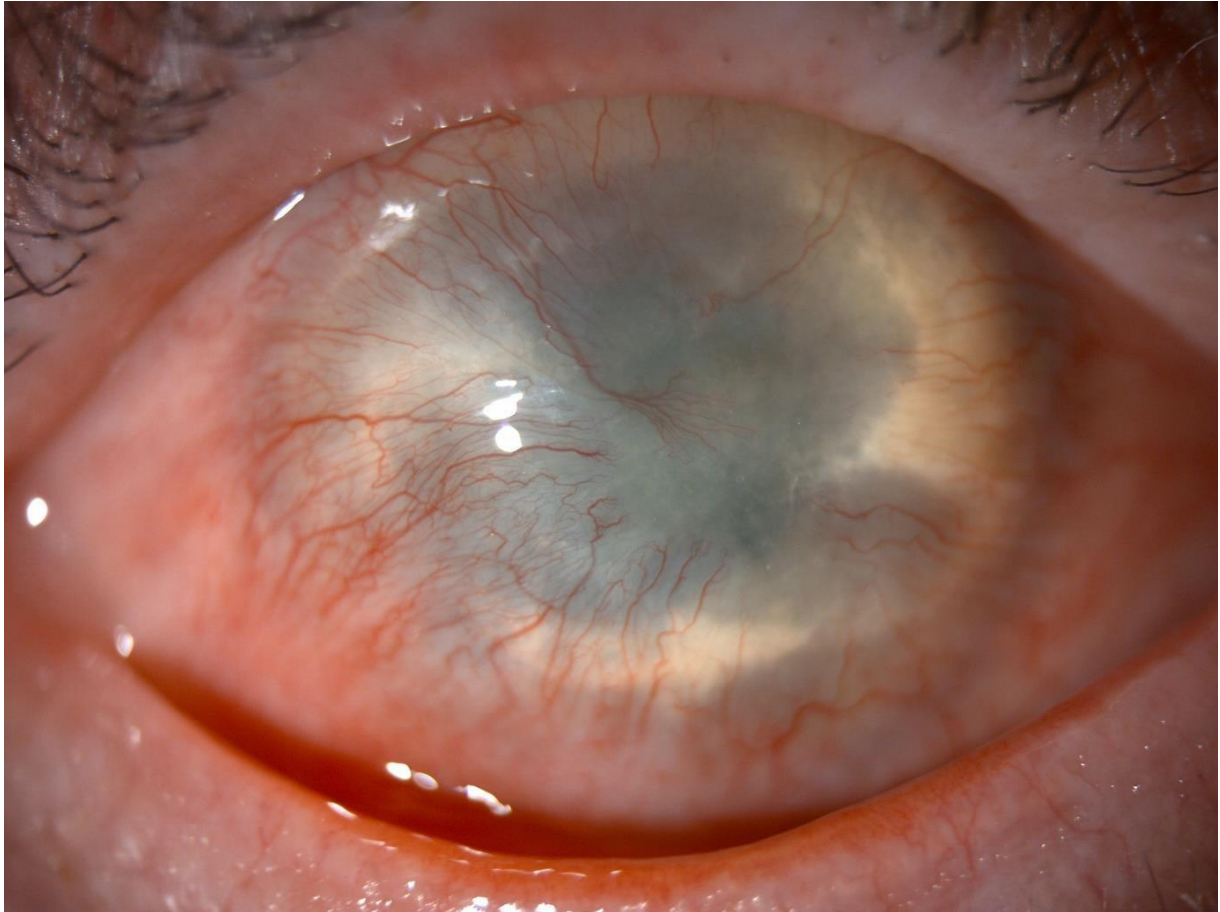**Inferior epithelial defect larger than 2mm.**





*Figure 5.3: Cobalt blue filter image with fluorescein sodium 2% eye drops of Case 1 2 weeks after V10.*

**Enlargement of epithelial defect to involve the central cornea.**



*Figure 5.4: Slit lamp anterior segment photographs of Case 1 9 months on V1.*

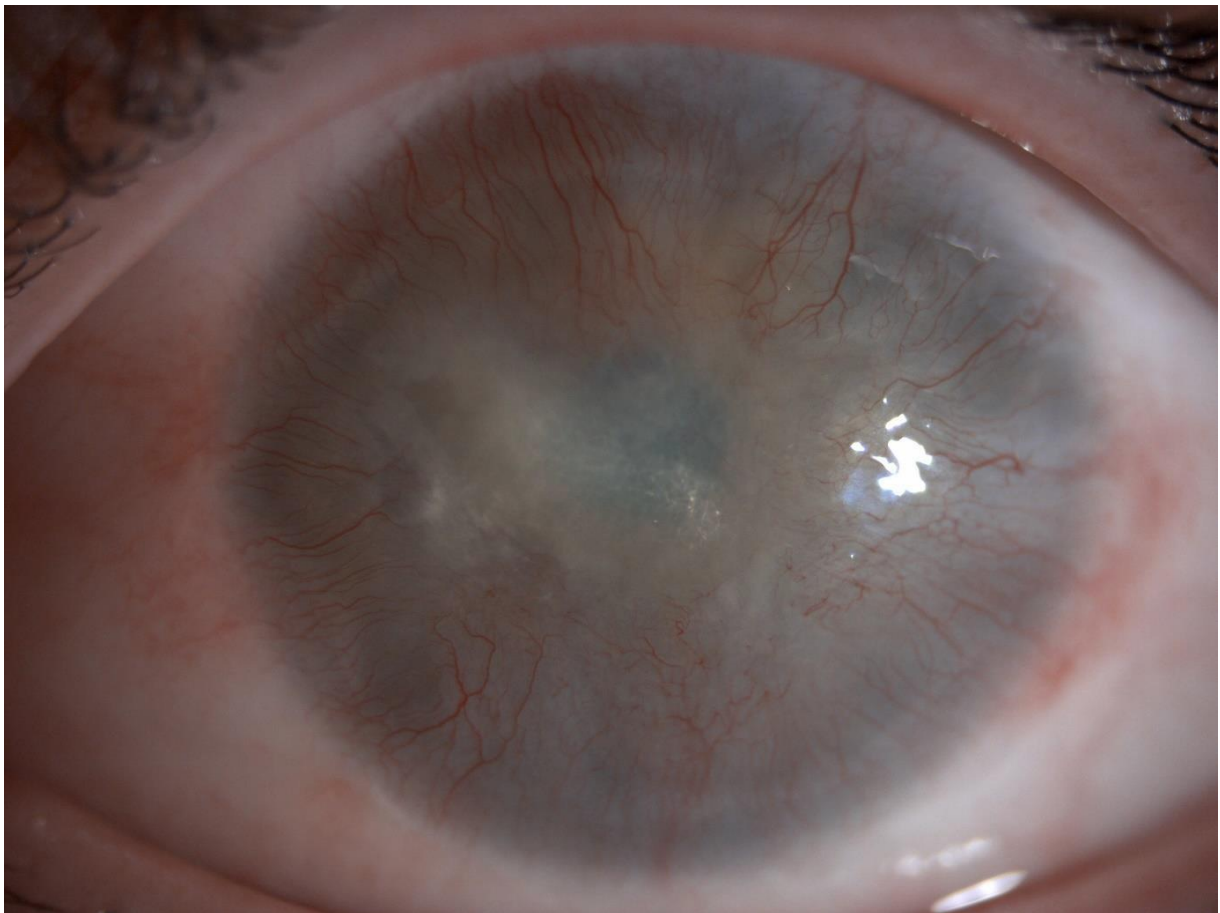
**Dense superficial NV in all quadrants involving the centre of the cornea.**

### **Case two (82602-02)**

This patient was a 27 year old lady who was recruited on the 8<sup>th</sup> of March 2017 for treatment of the left eye. She had dense fibrovascular pannus involving the central cornea due to an assault chemical injury in 2011. The 4 quadrants of the cornea were invaded with superficial corneal NV and they extended to the central cornea (Figure 5.5). The visual acuity was hand movement. She had normal ocular pressure in both eyes throughout the study (range from 12-15 mmHg). The anterior chamber was always visible and it was always deep with no cells or abnormal contents. Schirmer test type I was 10 mm on V1 and dropped to 6mm on V14. She had corneal anaesthesia which was assessed using a cotton tip. On V1, the patient had moderate photophobia but no pain or burning sensation. Her physical examination and vital signs were always normal and she was not on any concomitant medications and had no history of any medical conditions. Her infectious assessment was

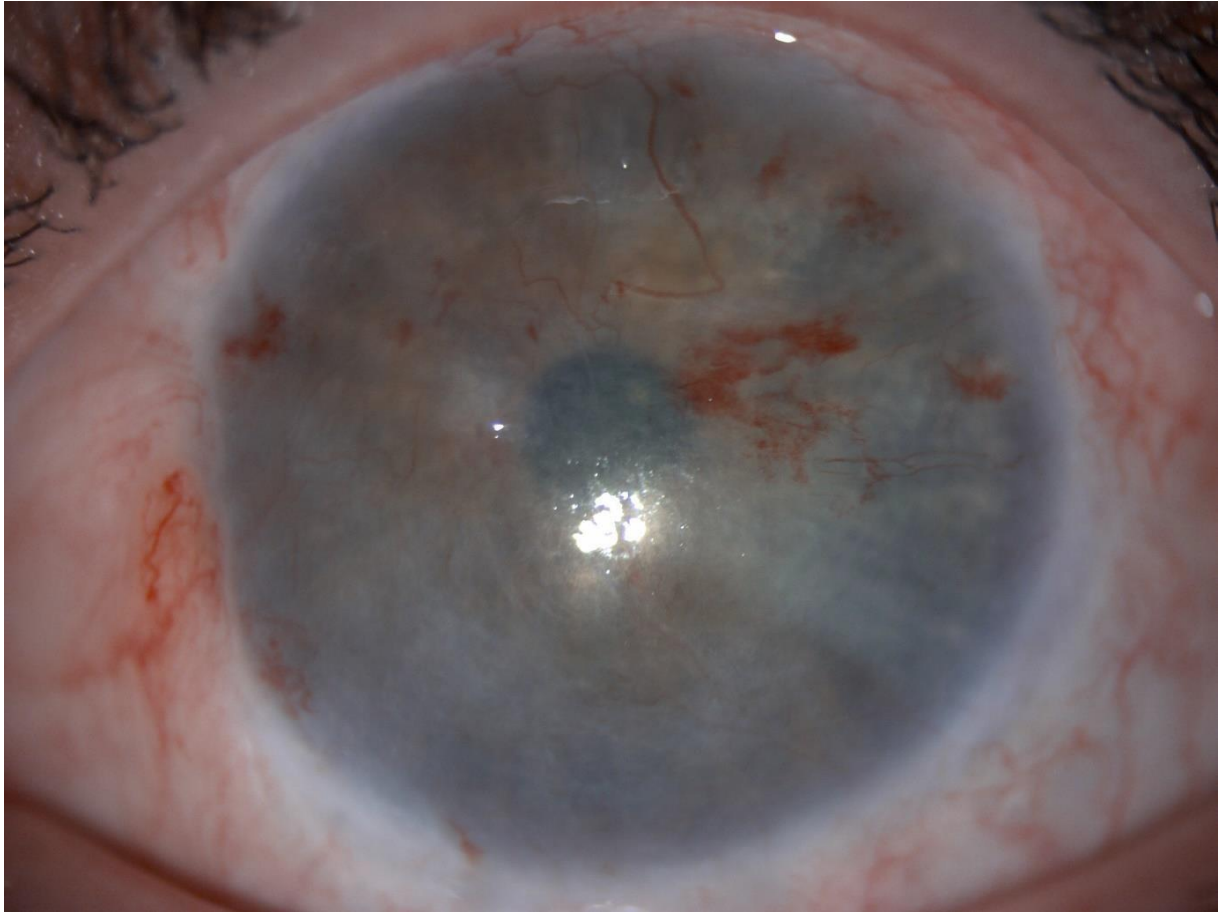
always normal apart from high levels of anti-HBs and positive values for HBc IgG Ab for hepatitis B virus which was due to previous hepatitis B vaccination with booster doses. Her pregnancy test was always negative. The biopsy was done on the 30<sup>th</sup> of May 2017. The biopsy was taken from the superior limbus of the right eye. The biopsy was placed in a sterile tube containing the transport medium. The standard operating procedures were followed carefully and the biopsy was shipped on the same day to Holostem. The patient was prescribed preservative-free levofloxacin eye drops, three times per day for 1 week. Conjunctiva was closed using 2 sutures which were removed after the biopsy procedure. The wound was healing well underneath. There were no adverse events. The holoclar implant was performed on the 7<sup>th</sup> of February 2018. Holoclar was delivered on the same day to the hospital inside a sterile, plastic Petri dish which was placed in a secondary container that was only removed in the operating theatre. The surgery was done under general anaesthesia. The surgery was successful and Holoclar was in place. The patient was started on the treatment as per protocol. On V8, the ocular bandage was removed and replaced with new bandage, Steri-strips and shield. The patient had moderate limbal and bulbar hyperaemia. She continued on Doxycycline tablets, 25 mgs of prednisolone tablets and tapering doses of dexafree eye drops. On V9, the ocular bandage was removed. The patient had no burning, no pain and no photophobia. The vision was hand movement. On examination, there were intra-corneal haemorrhages, congested conjunctiva with chemosis and superficial corneal NV. There were no epithelial defects. She was asked to stop doxycycline, taper Prednisolone to 12.5 mgs and to start dexafree eye drops TID. There were no adverse events. On V10, the patient reported that she has noted a remarkable improvement of vision since she last had the chemical injury. Her vision was 3/60 on Snellen chart (+1.30 logMAR). On examination, there was less limbal and conjunctival hyperaemia compared to V8 and V9. There was also less superficial corneal NV in all 4 quadrants, corneal opacification and less intracorneal haemorrhage (Figure 5.6). There were no epithelial defects. She was asked to stop the Prednisolone tablets and to continue tapering the dexafree eye drops for 2 more weeks. On V11, the patient had marked limbal and bulbar hyperaemia. There were more superficial NV superiorly, temporally and inferiorly and a nasal conjunctival encroachment on the cornea, but no epithelial defects (Figure 5.7). She was prescribed dexafree 1mg/ml eye drops QID. We saw her after 2 weeks. There was remarkable partial regression of the superficial NV in the superior and temporal quadrants

as well as regression of the nasal conjunctival growth. The inferior vessels regressed completely. There was also less bulbar and limbal hyperaemia (Figure 5.8). The dexafree drops were tapered to bid. On V12, there were very fine vessels superiorly and temporally and the nasal vessels were inactive and stable (Figure 5.9). On V13 and V14, the patient had stable inactive NV in 3 quadrants with no epithelial defects. The case was considered a success as she had no epithelial defects at any visits after the implant (V6) and mild degree of superficial NV at the end of the study (V14). She has been added to the waiting list for a left eye penetrating keratoplasty.



*Figure 5.5: Slit-lamp anterior segment photograph of Case 2 at V1.*

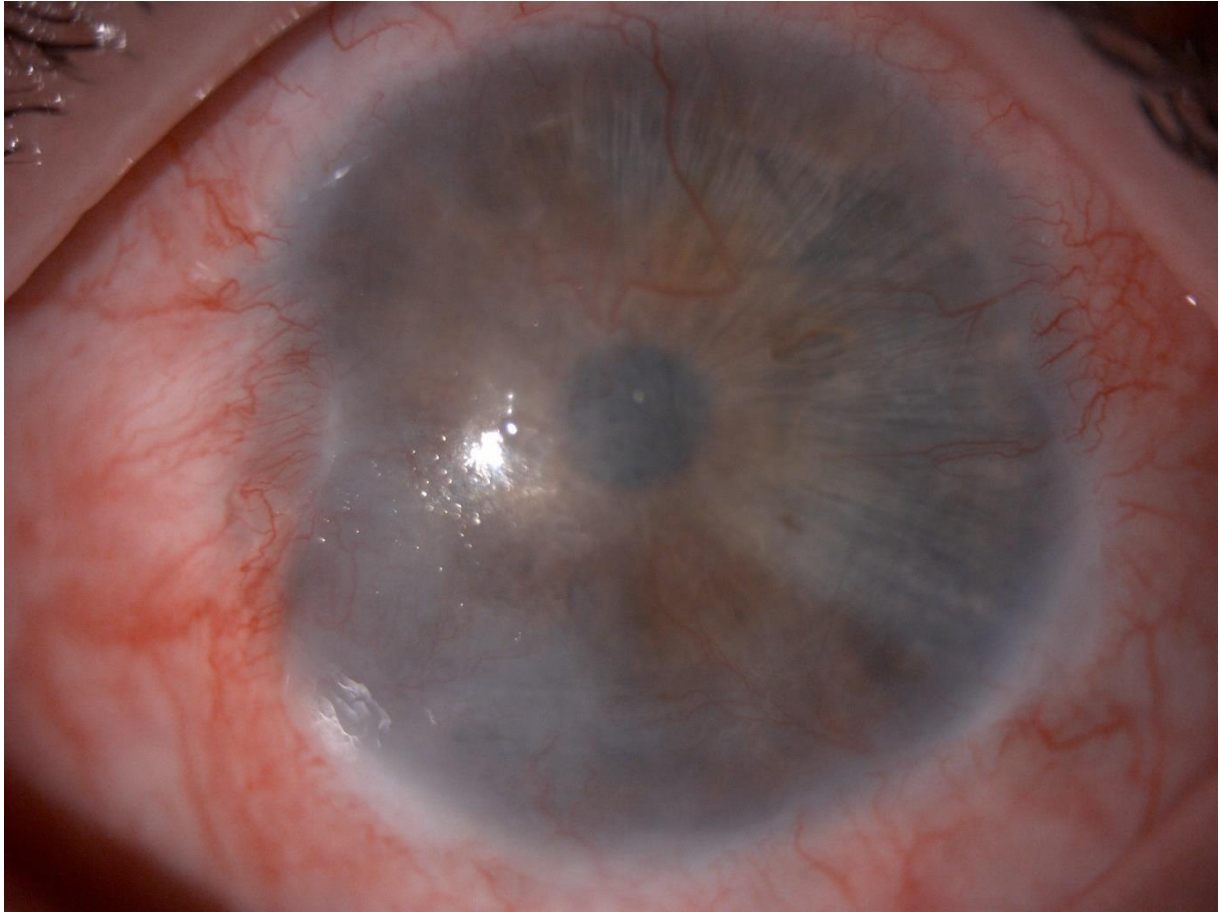
**Fibrovascular pannus with superficial NV in all four quadrants and central corneal opacity.**



*Figure 5.6: Slit-lamp anterior segment photograph of Case 2 at V10.*

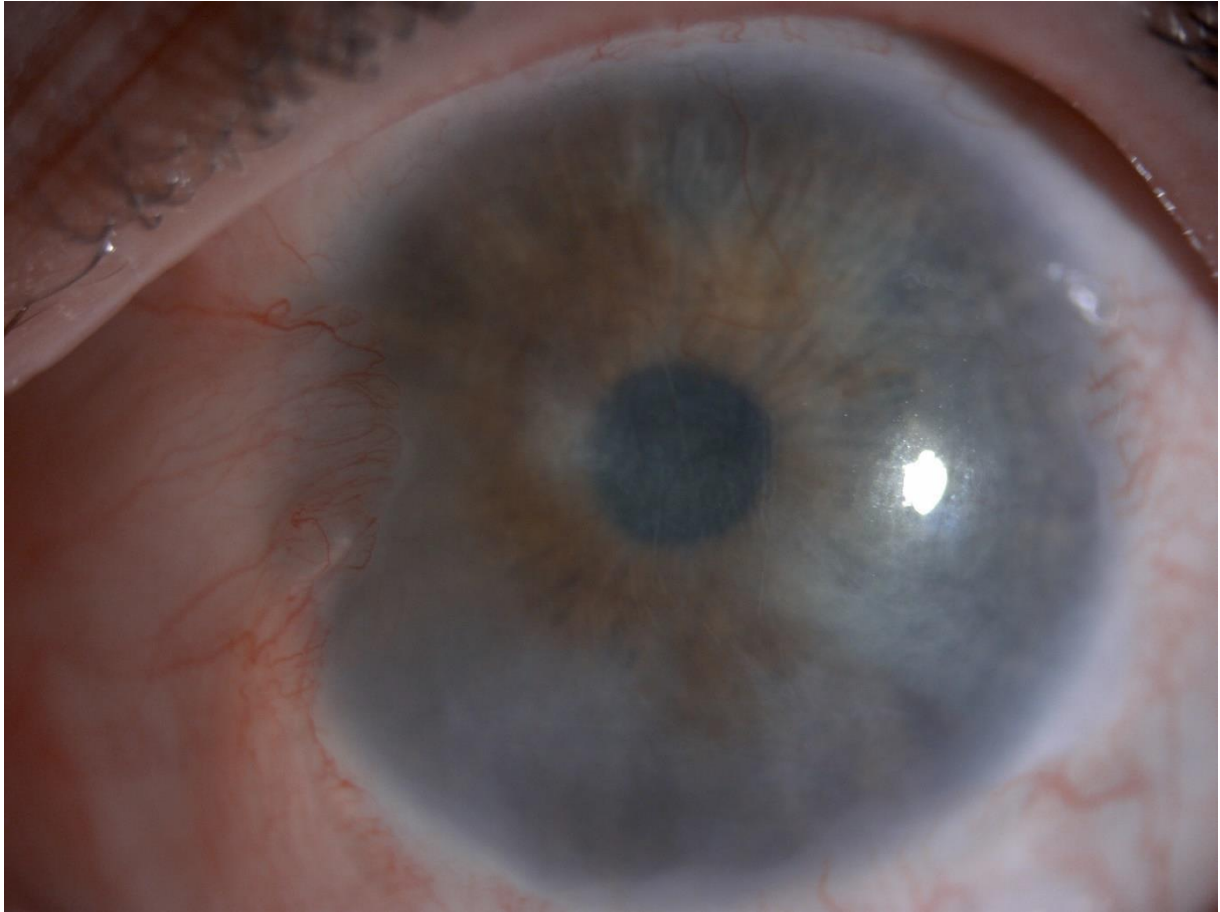
**Intracorneal haemorrhages and superficial NV.**





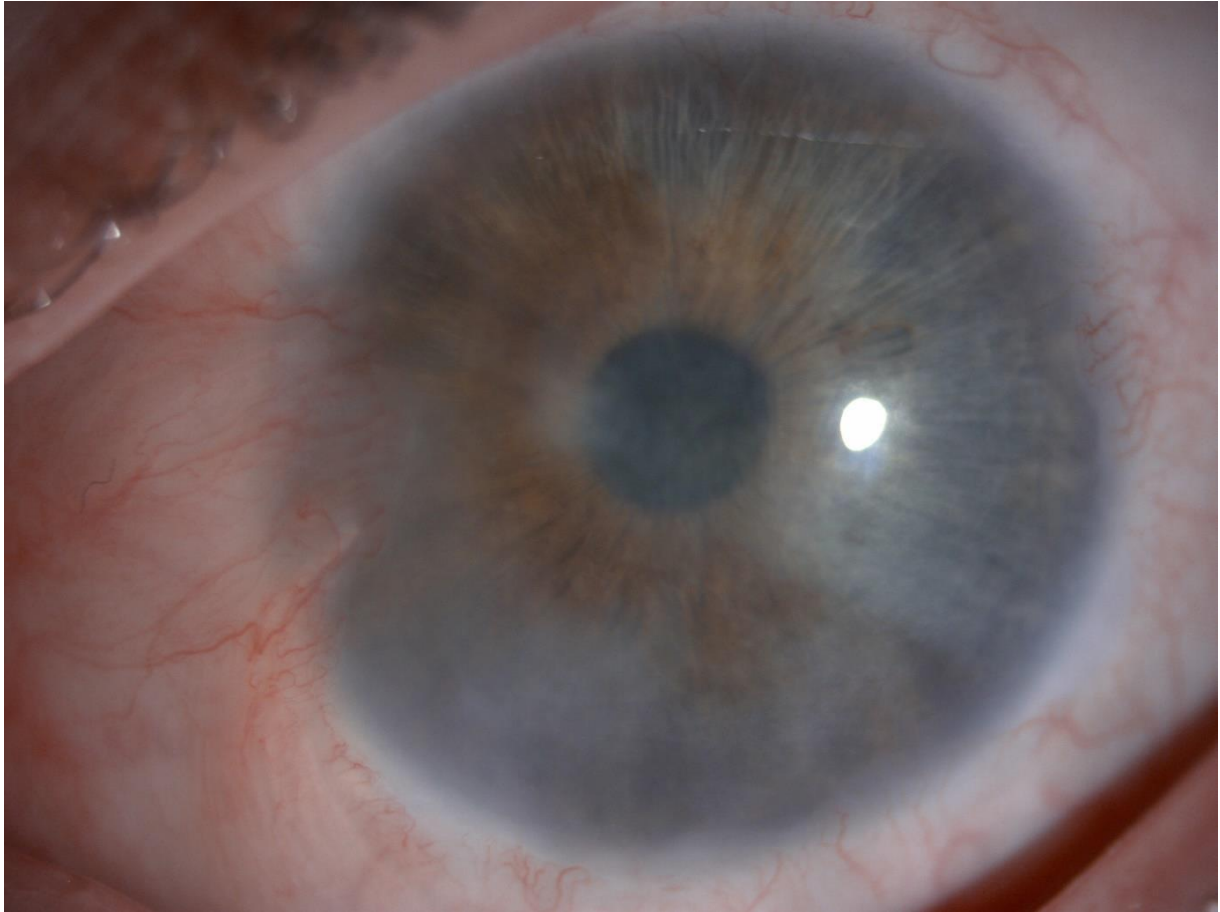
*Figure 5.7: Slit-lamp anterior segment photograph of Case 2 at VII.*

**Limbal and bulbar hyperaemia with marked superficial NV in superior, inferior and temporal quadrants and nasal conjunctival encroachment on the cornea.**



*Figure 5.8: Slit-lamp anterior segment photograph of Case 2 two weeks after V11.*

**Less limbal and conjunctival hyperaemia compared to Figure 5.3 (V11). Less active vessels nasally. Inferior vessels regressed.**



*Figure 5.9: Slit-lamp anterior segment photograph of Case 2 at V12.*

**Very fine vessels superiorly and temporally and the nasal vessels were inactive and stable.**

## **5.4 Discussion**

We recruited 2 patients as part of the Holocore study. Case 2 was a success and case 1 was considered a failure as it did not achieve the outcomes of the study which were the reduction of the degree of superficial corneal neovascularisation and absence of epithelial defects. Case 1 is currently on the waiting list for penetrating keratoplasty and autolimbic stem cell transplant. We could not ascertain the reason for the failure as the patient had no underlying systemic or local causes such as blepharitis, lid malposition, infections, blinking or exposure problems that could explain the failure of the implant. Another study centre reported a similar case where the patient suffered from persistent epithelial defect in addition to corneal melting and the development of a descemetocoele and they attributed this to the Holoclar implant. Case 2 is on the waiting list for penetrating keratoplasty as she



had residual central deep corneal opacity. Recently, NICE has approved Holoclar as an option in people with moderate to severe limbal stem cell deficiency after eye burns, only if it is used to treat 1 eye and people have already had a conjunctival limbal autograft or if there is not enough tissue for a conjunctival limbal autograft.

Scholz et al (406), evaluated the visual acuity and graft success in 34 eyes with LSCD due to chemical and thermal burns using autologous transplantation of ex vivo on human amniotic membrane -cultured and expanded limbus epithelium. They reported stable corneal surface in 75.4% of the eyes. Visual acuity increased significantly in 40 (65.6%) eyes, was stable in 19.7% of the eyes and decreased in 14.8% of the eyes. They considered this method to be safe and successful on the long term. Shimazaki et al (407) transplanted cultivated human limbal epithelium on amniotic membrane for 13 eyes with severe LSCD and achieved corneal epithelialisation in 46.2% of the eyes.

Two long-term studies have been published about simple limbal epithelial transplantation (SLET). A study by Basu et al (408) reported long-term clinical outcomes of autologous SLET on a population of 125 patients suffering from unilateral LSCD. Seventy-six percent of eyes maintained a successful outcome with survival probability of 80% after 1 year. Progressive corneal conjunctivalization was recorded in 18.4% of the eyes in this study.

Another retrospective, multicentre study with 6-month follow-up on 68 eyes showed the success of SLET in 83.8% of the cases with survival probability greater than 80% after 1 year (409).

The main limitation of HOLOCORE is the method of assessment of the severity of LSCD which was based on only the extent of corneal neovascularization and corneal opacity. There was no impression cytology or IVCN performed to assess the quality of epithelium on the corneal surface.

Further trials need to be conducted to compare the results of Holoclar and other ex vivo methods for expansion of limbus derived cells with regards to efficacy and safety.

# CHAPTER 6: CORRELATION BETWEEN DIABETIC CORNEAL NEUROPATHY AND DIFFERENT STAGES OF DIABETIC RETINOPATHY

## 6.1 Introduction

The prevalence of diabetes mellitus (DM) has continued to increase across the world. As at 2013, 382 million people have diabetes worldwide (410). Type 2 DM makes up about 90% of the cases. This equated to 8.3% of the adult population with equal rates in women and men (411). Diabetes can affect any ocular tissue. Diabetic retinopathy (DR) is the commonest complication of diabetes (412) and meets the World Health Organization (WHO) criteria of suitability for screening (413). It is the most significant ocular complication of diabetes and is a major cause of vision loss worldwide (318). Approximately one third of people with diabetes have DR, and a third of the DR patients may have sight-threatening DR, defined as proliferative diabetic retinopathy (PDR) or clinically significant macular oedema (DMO) (318). The natural history of DR is relatively well understood, with recognizable stages. Major risk factors for developing DR include duration of diabetes (414, 415), severity of hyperglycaemia (416, 417), hypertension (418) and dyslipidaemia (419). Once sight-threatening DR is present, progression is the norm and complications are unpredictable. Twenty years after diagnosis, almost all people with Type 1 DM and 60% of people with Type 2 DM will have some degree of diabetic DR (414, 415). Recently, diabetic retinal neurodegeneration (DRN) has been described, where progressive neuronal changes occur in the inner retina before or in the absence of clinically visible microvascular abnormalities (318, 420-422) and may contribute to DR (421, 423-425). OCT studies of diabetic retinal neuropathy (in eyes without DR) have been reported by several investigators (426-430).

Other ocular complications including keratopathy, glaucoma and cataracts may be associated with diabetes (431). The diabetic cornea suffers from cellular dysfunction and dysfunctional repair mechanisms, which manifests as recurrent erosions, delayed wound

healing ulcers, and oedema. In addition and undoubtedly related to epithelial dysfunction, alterations in epithelial basement membrane occur.

More recently, diabetic corneal neuropathy, has been reported as resulting in loss of corneal sensation and innervations (432-435) which may be related to corneal epithelial defects. Progressive reduction in corneal sensitivity and increasing corneal nerve degeneration has been linked with, and may occur before diabetic neuropathy elsewhere in the body (433). In-vivo confocal microscopy (IVCM) (a rapid and non-invasive new tool to examine sub-epithelial and stromal corneal nerves) has demonstrated a decrease in nerve fibre bundles (436), nerve beadings, and nerve branching patterns as well as an increase in nerve fibre tortuosity (437), and abnormal stromal nerves (438) in diabetic patients.

Some studies have shown the involvement of corneal sub-basal nerve plexus in diabetes and their marked reduction with increasing severity of DR and neuropathy using IVCM (436, 439). These studies also showed alterations in basal epithelial cell density in different retinopathy stages, and demonstrated that reduced density in basal epithelial cell is correlated with changes in innervations (436).

A few studies have reported on the effect of laser photocoagulation on sub-basal nerve plexus in patients with diabetic retinopathy (440, 441). Anti-vascular endothelial growth factor (anti-VEGF) drugs have been introduced as treatments for diabetic macular oedema (DMO) (442-444). It is known that VEGF is neuroprotective (445, 446). It is, therefore, theoretically possible that intraocular innervation may be affected by multiple intravitreal injections of anti-VEGFs. In addition, a few studies have reported on the effect of anti-VEGF on corneal nerves in humans and animals (447-450).

However, to date, the author is unaware of any studies that have evaluated corneal innervation following anti-VEGF therapy in a large number of diabetic eyes at different stages of DR. There is a further paucity of data on how the corneal nerve parameters in diabetes correlate with corneal sensitivity.

## **6.2 Methods**

### **6.2.1 Ethical issues**

The study was conducted in accordance to the Declaration of Helsinki (Version 5, 2000).

The study proposal with the relevant forms and documents were approved by the Nottingham Research Ethics Service Committee II, the Health Research Authority HRA and local NHS (Nottingham University Hospitals [NUH] NHS Trust) Research and Innovation authorities (REC reference Number: 15/SW/0186).

The ethical approval application process involved the submission of the project proposal and completed IRAS form to all parties (Research Ethics Committee, NUH NHS trust R&I and HRA), the ethics committee reviewed the application on 6<sup>th</sup> July 2015 and was approved on 11<sup>th</sup> August 2015. One substantial amendment was applied for and was approved. The first patient was recruited on 23<sup>rd</sup> June 2016.

### **6.2.2 Patient recruitment**

This single centre prospective longitudinal study included the identification of 86 patients. The non-diabetic and diabetic patients with type 1 and 2 were recruited from eye clinics at Queen's Medical Centre, NUH Trust, Nottingham.

Participants were recruited from specialist macula clinics, diabetic clinics and diabetic screening clinics at the Queen's Medical Centre, NUH Trust, Nottingham under the supervision of Mr Winfried Amoaku (Consultant Ophthalmologist). Based on the diagnostic criteria and stage classification of DR, the patients were divided into the following 5 groups: Non-diabetic patients (control), diabetic patients with no diabetic retinopathy (DR), Non-proliferative DR (NPDR) and Proliferative DR (PDR) patients including those who have and have not received Anti-VEGF injections and/or retinal laser photocoagulation. Twenty-

three patients were recruited into the control group, 24 patients in the group of diabetic patients with no DR, 27 patients in the NPDR group, and 12 patients in the PDR group.

**Control group inclusion criteria:**

- Patients over the age of 18
- Patients with no diabetes
- Able to consent

**Control group exclusion criteria:**

- Patients under age of 18
- Patients unable or unwilling to provide informed consent
- Any other known cause of neuropathy e.g. herpes keratitis
- History of corneal trauma or surgery
- Contact lens wearers

**Diabetic groups inclusion criteria:**

- Patients over the age of 18
- Patients with type 1 or type 2 diabetes
- Patients who have received retinal laser photocoagulation or intravitreal injections
- Able to consent

**Diabetic group exclusion criteria:**

- Patients under age of 18
- Patients unable or unwilling to provide informed consent
- Any other known cause of neuropathy e.g. herpes keratitis
- History of corneal trauma or surgery
- Contact lens wearers

### 6.2.3 Clinical intervention and follow up

Each participant attended one research session. All participants and groups had identical processes and procedures. A full ophthalmological examination was undertaken for all patients.

Relevant ophthalmic history was obtained. Information was collected on diabetes duration, hypertension state, renal problems and smoking. Visual acuity with glasses and pinhole (best habitual) was measured using ETDRS LogMAR charts (for both literate and illiterate) followed by assessment of pupil reaction. Corneal sensitivity was assessed with Cochet Bonnet esthesiometer (Luneau, Paris, France) was used to assess the sensation of the corneal nerves. A 0.08-mm monofilament was used to gently touch the inferior portion of the cornea in the vertical direction. The filament length was sequentially reduced in 5-mm steps, starting from 60 mm, until a positive response (verbal or a blink) occurred. The length of the monofilament at the time of response was recorded as the corneal sensitivity threshold and graded on a scale from 10 to 60. Anterior segment biomicroscopic examination, intraocular pressure (IOP) measurement with the Goldmann applanation tonometer, and fundal examination after pupil dilatation were performed.

Retinal stereo photographs were obtained in 4 ETDRS fields using the Topcon TRC 50IA camera. DR severity was based on clinical examination and the colour photographic grading by trained ophthalmologists according to the International DR Classification (modified from ETDRS classification). Corneal nerves were examined and quantified by in IVCM in all patients (with the Heidelberg Retina Tomogram II-Rostock Cornea Module; HRTII-RCM; Heidelberg Engineering GmbH, Heidelberg, Germany). This is a laser scanning confocal microscope that uses a class I diode laser (670-nm wavelength) with a 63× water-immersion lens. IVCM was performed under topical anaesthesia with Guttæ Proxymetacaine 0.5% (B&L, UK). A digital camera mounted on a side arm furnished a lateral view of the eye and objective lens to monitor the position of the objective lens on the surface of the eye. A drop of polyacrylic gel (Carbomer 0.2% eye gel, Blumont, UK) was used as coupling medium between the contact cap and objective lens of the microscope.

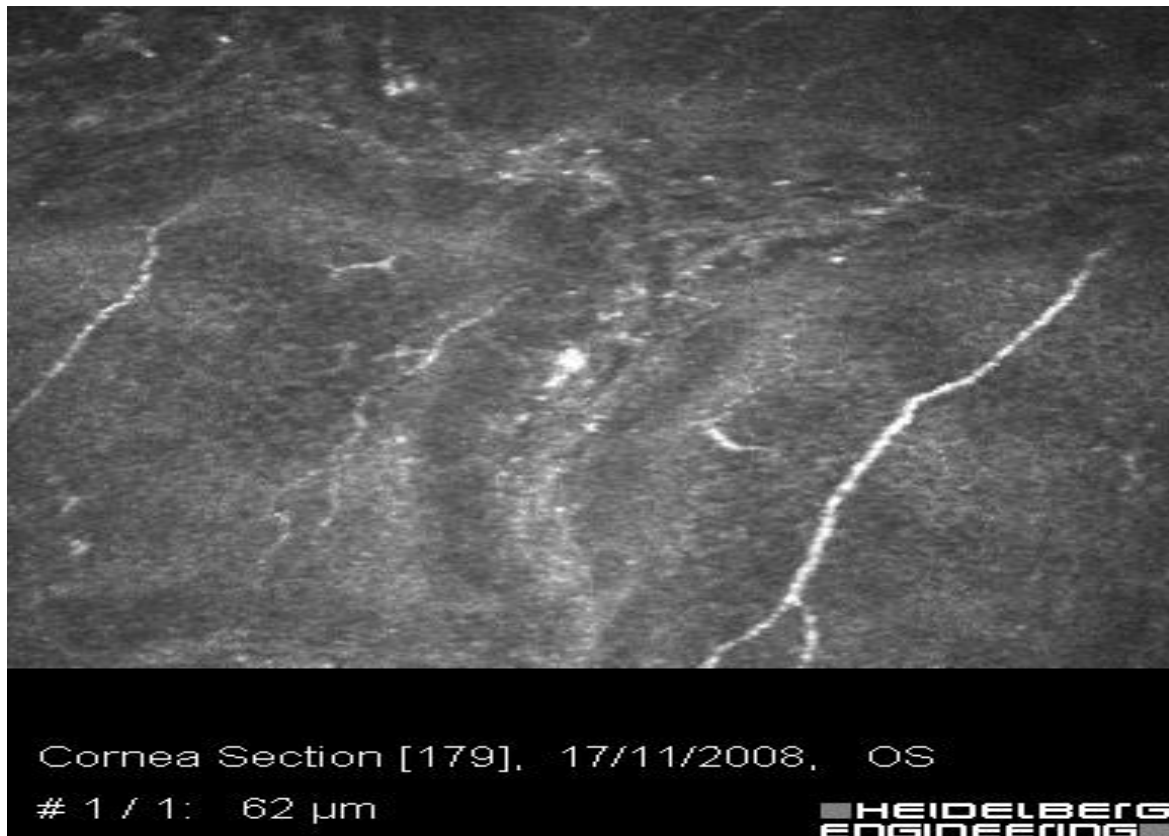The IVCM images were then analyzed on a special software for analyzing corneal nerves (Image J, LOCI, University of Wisconsin). This software measures 4 main parameters for corneal nerves which are nerve fibre density and that is defined as the number of main nerves per frame, the nerve branch density which is the number of main branches per frame, the nerve fibre length which is the total length of all nerves per frame and the nerve fibre tortuosity which is the main nerves per frame.

Three IVCM frames (the clearest images) were selected from among hundreds of scans for each eye. To analyze the image, the parameter that needs to be measure was selected from the metric box on the software. The density and length of the sub-basal nerves in each of the three frames was measured the using the tracing in analysis tool. The average was calculated and so for each eye two values were calculated: the density and length of sub-basal nerves in that eye.

Patients were provided with contact numbers for investigators for any queries, and access the 24 hour on call emergency eye service, during the study period.



*Figure 6.1: IVCM image of a left eye of a patient showing sub-basal corneal nerves (depth 167 microns) of normal length and density.*



*Figure 6.2: IVCM image of a left eye of a patient showing sub-basal corneal nerves (depth 62 microns) of reduced length and density.*

#### **6.2.4 Outcome measurements**

The outcome measure was to detect and grade the changes in corneal nerves in correlation with different stages of diabetic retinopathy.

Data will be captured using Microsoft Office Access and cleaned using Excel. Analysis will be done using statistical package for social sciences (SPSS Version 24.0.). Continuous numerical data will be presented as Mean and Standard deviation (SD) and categorical data as percentages (%).

#### **6.2.5 Statistics and data analysis**

Statistical analysis was performed with SPSS software version 24.0 (SPSS Inc, Chicago, Illinois, USA). The statistical analysis was carried out on corneal nerve parameter (length and density) between the control group, NPDR, PDR and diabetics with no retinopathy groups.



Normality of the data was tested between the different groups using the non-parametric test Kolmogorov-Smirnov as the groups were not age and co-morbidity matched. The non-parametric Mann-Whitney test and Kruskal-Wallis test were subsequently used to determine differences in corneal nerve parameters between the different groups. Significance was set at  $\alpha=0.05$ .

## 6.3 Results

### 6.3.1 Recruitment and Cases

A total of 86 patients were recruited into this study. Of the 86 patients, 35 were females and 51 males. Table 6.1 shows demographics of the study participants.

*Table 6.1 Demographics of study participants*

	<b>Controls</b>	<b>Diabetics with no retinopathy</b>	<b>NPDR</b>	<b>PDR</b>
<b>Age (years)</b>	Mean: 37 Range: 23-64	Mean: 70 Range: 48-95	Mean: 58 Range: 26-83	Mean: 52 Range: 26-80
<b>Sex (F, M)</b>	7, 16	13, 11	10, 17	5, 7
<b>Diabetes Type</b>	N/A	23 type 2 1 type 1	25 type 1 2 type 2	8 type1 4 type 2
<b>Duration of diabetes (years)</b>	N/A	Mean: 14 Range: 1-40	Mean: 17 Range: 4-45	Mean: 25 Range: 12-45
<b>Smoker</b>	0	2	1	0
<b>HTN</b>	0	10	7	4
<b>Renal problems</b>	0	1	2	2

#### **A) Combining both eyes in each group:**

Data from both eyes for each patient were combined for analysis of nerve length and density parameters for the control, NPDR, PDR and diabetics with no diabetic retinopathy as there was no statistically significant difference between nerve length and density between 2 in all of the above mentioned groups. Tables 6.2-6.9 show the significance level of each of the above mentioned groups. Mann-Whitney test was used for all groups.

**Table 6.2: p-value of statistical test for combining nerve length and nerve density for both eyes in in Control, NPDR, PDR and diabetics with no retinopathy groups**

Null Hypothesis	Significance	Decision
Combining both eyes in nerve length of control group (same across all categories of eyes)	.783	Retain the null hypothesis
Combining both eyes in nerve density of control group	.767	Retain the null hypothesis
Combining both eyes in nerve length of NPDR group	.406	Retain the null hypothesis
Combining both eyes in nerve density of NPDR group	.356	Retain the null hypothesis
Combining both eyes in nerve length for PDR group	.321	Retain the null hypothesis
Combining both eyes in nerve density of PDR group	.314	Retain the null hypothesis
Combining both eyes in nerve length of diabetics with no retinopathy group	.918	Retain the null hypothesis
Combining both eyes in nerve density of diabetics with no retinopathy group	.869	Retain the null hypothesis

**Table 6.3: Normality of distribution testing of each group. Non-parametric Kolmogorov Smirnov test was used**

Group	Normal distribution
NPDR group nerve length	Not normally distributed
Control group nerve length	Normally distributed
PDR group nerve length	Normally distributed
Diabetics with no retinopathy group nerve length	Not normally distributed
NPDR group nerve density	Normally distributed
Control group nerve density	Normally distributed
PDR group nerve density	Normally distributed
Diabetics with no retinopathy group nerve density	Not normally distributed

**B) Comparing different groups:**

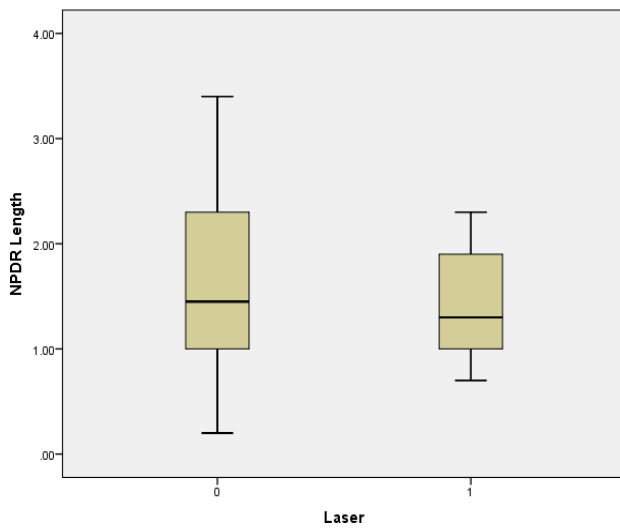
*Table 6.4: p-value of statistical test for comparing nerve length and nerve density in Control, NPDR, PDR and diabetics with no retinopathy groups*

Group	Test used	p-value	Significance
Control vs NPDR nerve length	Mann-Whitney	0.007	Significantly different
Control vs NPDR nerve density	Mann-Whitney	<0.001	Significantly different
Control vs PDR nerve length	Mann-Whitney	<0.0001	Significantly different
Control vs PDR nerve density	Mann-Whitney	<0.0001	Significantly different
NPDR vs diabetics with no retinopathy nerve length	Mann-Whitney	0.84	No significant difference
NPDR vs diabetics with no retinopathy nerve density	Mann-Whitney	0.84	No significant difference
PDR vs diabetics with no retinopathy nerve length	Kruskal-Wallis	0.020	No significant difference
PDR vs diabetics with no retinopathy nerve density	Kruskal-Wallis	0.019	No significant difference
NPDR vs PDR nerve length	Kruskal-Wallis	0.048	No significant difference
NPDR vs PDR nerve density	Kruskal-Wallis	0.018	No significant difference

**C) The effect of laser and intravitreal injection on nerve length and density in NPDR and PDR groups:**

- Focal and macular grid laser has effect on NPDR-length (mm/mm<sup>2</sup>) (No) both eyes considered combined**

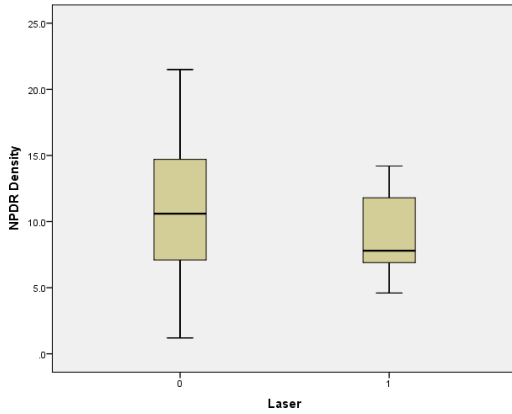
Non-parametric Mann-Whitney test was applied to compare the nerve length of laser/ non-laser NPDR groups. The p-value = 0.41. Therefore, laser treatment had no significant effect on the nerve length in the NPDR group (Figure 6.1).



*Figure 6.3: Box plot showing insignificant difference in nerve length between NPDR eyes that did not receive laser treatment and NPDR eyes that received laser treatment. 0: group that did not receive laser, 1: group that received laser.*

**2. Focal and macular grid laser has effect on NPDR-density (no/mm<sup>2</sup>) (No) both eyes considered combined**

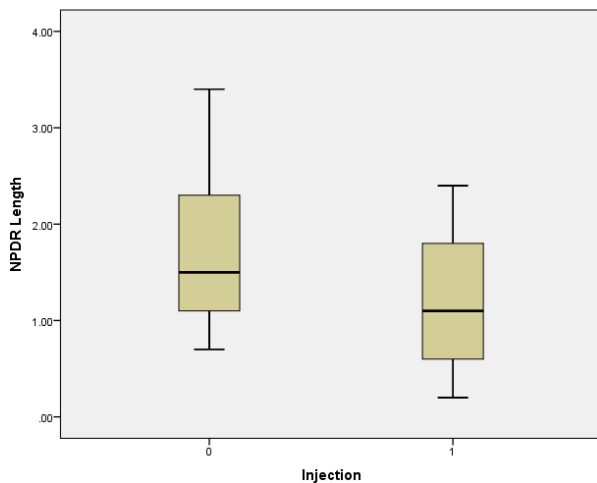
Non-parametric Mann-Whitney test was applied to compare the nerve density of laser/ non-laser NPDR groups. The p-value = 0.36. Therefore, laser treatment had no significant effect on the nerve density in the NPDR group (Figure 6.2).



**Figure 6.4:** Box plot showing insignificant difference in nerve density between NPDR eyes that did not receive laser treatment and NPDR eyes have received laser treatment. 0: group that did not receive laser, 1: group that received laser.

**3. Anti-VEGF Injection has effect on NPDR-length (mm/mm<sup>2</sup>) (yes) both eyes considered combined**

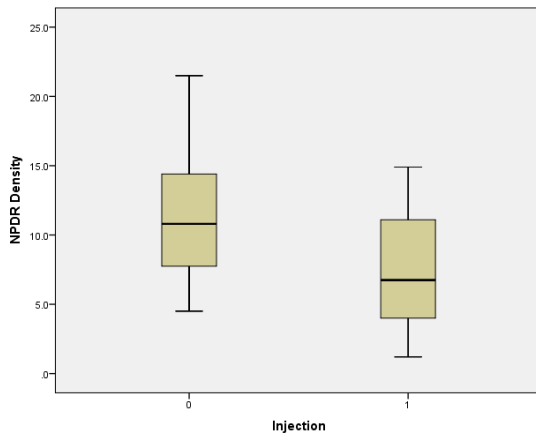
Non-parametric Mann-Whitney test was applied to compare the nerve length of injection/ non-injection NPDR groups. The p-value = 0.046. Therefore, anti-VEGF injections had a significant effect on the nerve length in the NPDR group (Figure 6.3).



**Figure 6.5:** Box plot showing significant difference in nerve length between NPDR eyes that did not receive injections and NPDR eyes that received injections. 0: group that did not receive laser, 1: group that received laser.

**4. Anti-VEGF Injection has effect on NPDR-density (no/mm<sup>2</sup>) (yes) both eyes considered combined**

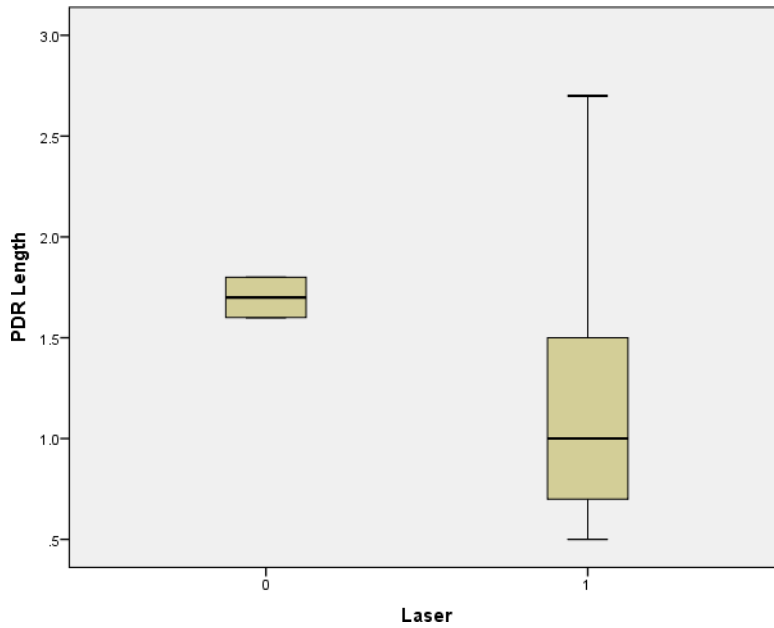
Non-parametric Mann-Whitney test was applied to compare the nerve density of injection/ non-injection NPDR groups. The p-value = 0.016. Therefore, anti-VEGF injections had a significant effect on the nerve density in the NPDR group (Figure 6.4).



*Figure 6.6: Box plot showing significant difference in nerve density between NPDR eyes that did not receive injections and NPDR eyes that received injections. 0: group that did not receive injections, 1: group that received injections.*

**5. PASCAL laser has effect on PDR-length (mm/mm<sup>2</sup>) (No) both eyes considered combined**

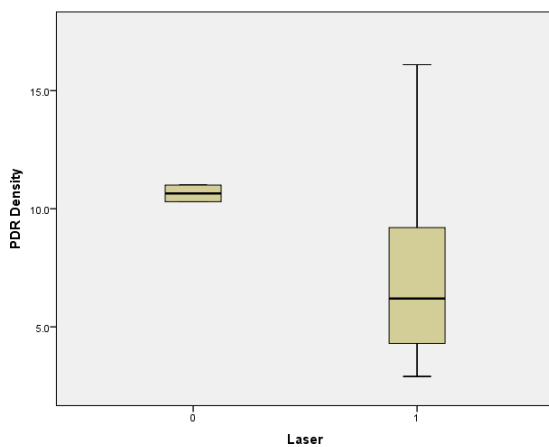
Non-parametric Mann-Whitney test was applied to compare the nerve density of laser/ non-laser PDR groups. The p-value = 0.32. Therefore, laser treatment had no significant effect on the nerve length in the PDR group (Figure 6.5).



**Figure 6.7:** Box plot showing insignificant difference in nerve length between NDR eyes that did not receive laser treatment and NPDR eyes that received laser treatment. 0:group that did not receive laser, 1: group that received laser.

**6. PASCAL laser has effect on PDR-density (no/mm<sup>2</sup>) (No) both eyes considered combined**

Non-parametric Mann-Whitney test was applied to compare the nerve density of laser/ non-laser PDR groups. The p-value = 0.22. Therefore, laser treatment had no significant effect on the nerve density in the PDR group (Figure 6.6).

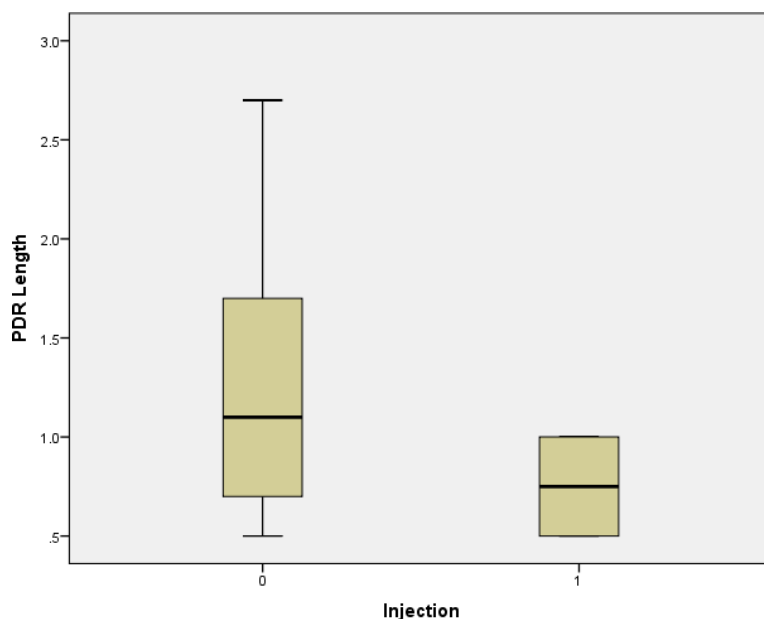


**Figure 6.8:** Box plot showing insignificant difference in nerve density between PDR eyes that did not receive injections and PDR eyes that received injections. 0:group that did not receive laser, 1: group that received laser.



**7. Anti-VEGF Injection has effect on PDR-length (mm/mm<sup>2</sup>) (No) both eyes considered combined**

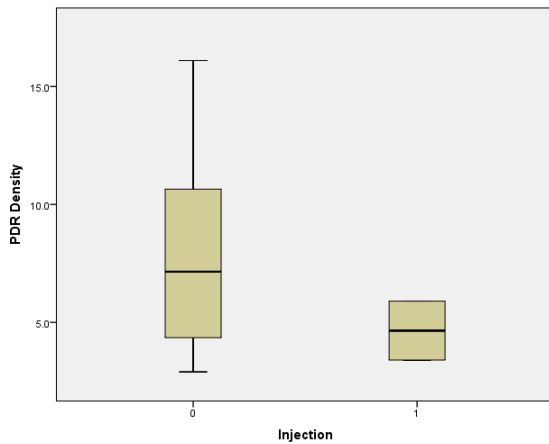
Non-parametric test Mann-Whitney test was applied to compare the nerve length of injection/ non-injection PDR groups. The p-value = 0.26. Therefore, anti-VEGF injections had no significant effect on the nerve length in the PDR group (Figure 6.7).



*Figure 6.9: Box plot showing insignificant difference in nerve length between PDR eyes that did not receive injections and PDR eyes that received injections. 0:group that did not receive injections, 1: group that received injections.*

**8. Anti-VEGF Injection has effect on PDR-density (no/mm<sup>2</sup>) (No) both eyes considered combined**

Non-parametric Mann-Whitney test was applied to compare the nerve length of injection/ non-injection PDR groups. The p-value = 0.22. Therefore, anti-VEGF injections had no significant effect on the nerve density in the PDR group (Figure 6.8).



**Figure 6.10:** Box plot showing insignificant difference in nerve density between PDR eyes that did not receive injections and PDR eyes that received injections. 0: group that did not receive injections, 1: group that received injections.

The results of the study are summarised in Table 6.10. The length and density of fibres of the sub-basal nerve plexus are significantly lower in the NPDR and PDR groups compared to the control group. There was no significant difference between the nerve length and density in the NPDR and diabetic patients with no retinopathy groups. The nerve length and density of the diabetic patients with no retinopathy group are significantly lower than those of the PDR group. The nerve length and density of the NPDR group were significantly lower than those in the PDR group.

The PASCAL laser treatment had no significant effect on the corneal nerve length and density in both the NPDR and PDR groups. Anti-VEGF treatment had a significant reduction of corneal nerve length and density of the NPDR group but not the PDR group.

Aflibercept and ranibizumab were the anti-VEGF drugs used in the current study. The average number of intravitreal injections of anti-VEGF in NPDR group was 4.3, and 2.8 in the PDR eyes group.

*Table 6.4: Features of the sub-basal plexus nerves in the study participants and corneal nerve sensitivity*

Parameters	Length (mm)	Density (mm/mm <sup>2</sup> )	Corneal sensitivity
<b>Control</b>	Mean +/- SD: 2.278+/- 0.89 Range: 0.8- 4.2	Mean: 13.943+/- 5.15 Range: 5-25	Mean: 57 Range: 55-60
<b>NPDR</b>	Mean +/- SD: 1.5802+/-0.71 Range: 0.2- 3.4	Mean: 10.245+/- 4.38 Range: 1.2- 21.5	Mean: 55.4 Range: 25-60
<b>PDR</b>	Mean: 1.241+/-0.65 Range: 0.5- 2.7	Mean: 7.745+/- 3.40 Range: 2.9- 16.1	Mean: 50 Range: 25-60
<b>Diabetics with no retinopathy</b>	Mean: 1.635+/- 0.70 Range: 0.6- 3.1	Mean: 10.185+/- 4.24 Range: 3.8- 19.5	Mean: 55.7 Range: 40-60

## 6.4 Discussion

Confocal microscopy is a non- invasive method for quantifying corneal nerve length and density. Studies have shown that there is a marked reduction of the sub-basal plexus nerve density in patients with DR which increased with the increasing severity of DR as well as decreased corneal sensitivity (435, 436, 439, 451). The results from this study showed a significant difference between the sub-basal plexus nerve length and density in diabetic eyes with different stages of retinopathy compared to control eyes, and support findings from previous studies. Similarly, there were differences in corneal nerve parameters between NPDR eyes when compared to PDR eyes, and PDR eyes when compared to diabetic eyes with no retinopathy. However, there was no significant difference in corneal nerve parameters between the NPDR eyes and eyes of diabetics with no retinopathy. These findings suggest that neuronal changes in the cornea precede the development of clinical DR, and may coincide with development of retinal neuropathy as previously described (318, 420-422).

Nerve branching is one of the parameters measured in some previous studies, but was found to be unpredictable as nerve fibre branches were sometimes difficult to grade, as for example, a single nerve branch could be easily interpreted as two fibres without branches (441). Tortuosity was another measurement used in some studies but the subjective (438,

440) and objective grading methods (452, 453) that have been used for quantification were not repeatable or comparable. For these reasons, the sub-basal nerve length and density were thought to be the most accurate parameters to compare between the different groups in this study.

The results from this study have shown that PASCAL laser treatment, whether focal, macular grid or PRP did not lead to significant changes in the length and density of the sub-basal corneal nerve plexus in NPDR and PDR eyes. Misra et al (441), reported the same as they found no significant difference in nerve density between 19 PDR eyes that had no PRP compared to 19 PDR eyes that had PRP. They did not specify the type of laser equipment that was used. They suggested that the decreased nerve density found in their study was due to diabetes rather than the laser treatment.

De cilla et al (440) recruited 50 patients with DR and 50 normal control subjects. They studied the effect of argon laser PRP on the corneal sub-basal nerve plexus of 14 patients with PDR who had argon laser and compared them to 13 patients who had PDR but did not receive any laser treatment. They used IVCM to quantify the number of nerves, tortuosity and fibre reflectivity. Contrary to results from this study, they reported significant reduction of sub-basal nerve plexus number in the laser treated group compared to the non-treated group. Similar to results from the present study, they reported significant differences between the PDR and NPDR eyes and diabetic eyes (NPDR and PDR) when compared to normal control eyes. The results from the present study might be different from those from De Cilla et. al. as the PASCAL laser was used in the present study (Synthesis 577 nm, Topcon, Essebaan, Netherlands) which is a frequency-doubled (Nd:YAG) solid-state laser rather than argon. The number of laser burns might be another factor of difference. The other possible reason might be that De Cilla et. al. study included patients who had previous cataract surgery which is known to have damaging effect on corneal nerves. Schiodte et al (454) suggested that the argon laser might be causing damage to the short ciliary nerves as they cross the suprachoroidal space having left the ciliary ganglion on their way to the ciliary body and iris. However, corneal innervation is generally derived from the long ciliary nerves, rather than the short ciliaries.

In this study, the corneal sensitivity worsened with the increasing severity of the diabetic retinopathy.

VEGF was reported to be an essential player in nerve growth. VEGF and its receptor are expressed by neurons and they are responsible for promoting neurotrophic and neuroprotective activities (445, 455, 456). These activities include protection of neurons from hypoxia-induced death, expansion of cortical neurones and stimulation of outgrowth of axons in peripheral neurons (457). One study reported that systemic inhibition of VEGF with bevacizumab may cause apoptosis in retinal neurons (458).

Studies were carried out to investigate the influence of VEGF on promoting corneal nerve regeneration and repair. VEGF was found to have established trophic effects on nerve growth including studies of neurite outgrowth of trigeminal ganglion cultures (455, 459-463). Li et al, investigated the contribution of acute inflammation to sensory nerve regeneration in the murine cornea using a model of corneal abrasion that removes the stratified epithelium and sub-basal nerve plexus (464). Their results showed that VEGF is necessary for efficient corneal nerve repair following epithelial abrasion.

Results from this study showed that anti-VEGF injections have an effect on the sub-basal nerve plexus length and density in eyes with NPDR. This effect may be due to the role that VEGF plays in nerve growth. The non-significant corneal nerve changes in eyes with PDR maybe that the decreased nerve density and length are due to the effect of the long-standing diabetes rather than the injections. Another possibility is that the average number of injections in the NPDR was greater than in PDR eyes. Goldhardt et al (450) carried out a retrospective study and compared between eyes in 39 patients who had anti-VEGF in one eye only and the fellow eye. They also compared corneal nerve parameters between 50 eyes of 50 individuals who had anti-VEGF and 80 individuals with no history of injections. That study only included 8 diabetic patients among the 89 patients; the other cases included retinal vein occlusion, wet age-related macular degeneration and other mixed aetiologies and did not specify the degree of retinopathy in the 8 diabetic patients. They reported reduced corneal nerve length and density in all eyes that received injections regardless of the indication for the injection.

Bock et al (447) used bevacizumab eye drops to treat corneal neovascularisation in murine corneas. They measured the corneal nerve density following treatment with the drops. The findings showed that the nerves were not affected by the treatment and this may imply Anti-VEGF drops might be a safer option than injections .

However, a direct comparison in a randomised study will be required for confirmation of the hypothesis.

The current study was prospective, and showed that PASCAL is a safe modality of treatment for patients who need focal, macular grid or PRP laser treatment. It also shows that anti-VEGF injections might be implicated in the damage of corneal nerves seen in diabetic eyes especially at the NPDR stage. In eyes with PDR, it is most probable that the long-standing diabetes rather than the laser treatment or anti-VEGF injections are responsible for reduced corneal nerve parameters. However, higher numbers of anti-VEGF injections might play role in the extent of corneal nerve damage.

## CHAPTER 7: SUMMARY AND CONCLUSIONS

Ocular neovascularisation is an important feature in the pathophysiology of many vision-threatening conditions including corneal vascularisation and diabetic retinopathy.

The cornea is the transparent part of the eye and is responsible for the majority of its refractive power. The cornea is normally an avascular structure, but may vascularize in situations in which a disequilibrium between angiogenic and antiangiogenic stimuli occurs. Such vascularisation leads to oedema, further inflammation and eventually scar formation resulting in severe visual impairment if uncontrolled. Vascularisation is the single most important risk for corneal graft rejection. Treatments for corneal vascularisation have been ineffective to date.

Treatments for corneal vascularisation (NV) have been ineffective to date. As part of this project, fifteen patients with corneal vascularisation resulting from different pathologies who had fine needle diathermy (FND) only, subconjunctival injection of bevacizumab (Avastin, Roche) only, or a combination of both modalities were studied. The corneal vessels were graded using the scoring system published by Faraj et al at Queens Medical Centre, Nottingham University hospitals. The study results showed that the only statistically significant method of reduction of corneal NV was the combined FND and bevacizumab injections. This is most probably due to the fact that FND induces trauma which stimulates the release of vascular endothelial growth factor (VEGF). Anti-VEGF injections are thus required to block these factors and prevent further NV formation following FND. Both FND and bevacizumab injections had no significant complications. A randomised control trial with a larger number of patients is required to establish this combined method of treatment as the number one option for managing corneal NV especially in patients with NV undergoing keratoplasty.

In another study (HOLOCORE), Holoclar - a sheet of autologous cultivated limbal stem cells was used to treat patients with moderate to severe limbal stem cell deficiency complicated by deep and superficial corneal vascularisation. This work was part of a global multi-centre study. Two patients with unilateral chemical burns with moderate corneal vascularisation

were recruited from Nottingham. One patient failed with treatment in HOLOCORE, and had persistent epithelial defect which was managed with amniotic membrane transplant. The reason of the failure was not clear but could have been related to the age of the patient, the condition of the cornea and conjunctiva or the corneal nerves status after the chemical burn. The other chemical burn case successfully treated and was listed for a penetrating keratoplasty due to residual deep central corneal scar. There are other studies which have used autologous transplantation of ex vivo cultivated cells on human amniotic membrane and simple limbal epithelial transplantation (SLET), which reported safe and successful outcomes in the majority of the cases on the long term (406-409). NICE has approved Holoclar as an option but only if it is used to treat 1 eye in a patient who have already had a conjunctival limbal autograft or if there is not enough tissue in the healthy eye for a conjunctival limbal autograft. Further trials need to be conducted to compare the results of Holoclar and other ex vivo methods for expansion of limbus derived cells with regards to efficacy and safety.

Pterygium is a potentially sight threatening condition and is composed of wing shaped fleshy fibrous and vascular tissue that grows towards the cornea. Two studies were carried to investigate the medical management and healing of primary and recurrent pterygium. In the first study (REPEAT), 20 patients with primary and recurrent were recruited and treated with combined subconjunctival injections of 5 fluorouracil (5FU) and Avastin. Tissue was obtained by surgical excision of primary pterygium from 4 eyes who received injections and 3 eyes with primary pterygium who did not receive injections (control) and subjected to immunohistological examination for beta fibroblast growth factor (bFGF), vascular endothelial growth factor (VEGF), epidermal growth factor (EGF), von-Willebrand factor (vWF), lymphatic vessel endothelial hyaluronan receptor (LYVE-1) and collagen-I. All of the patients had arrest of progression of their pterygia, as well as reduction in the clinical grade, thickness and vascularity of the pterygium. This is related to the effect of agents on fibroblasts, collagen, and vascular tissues. There was also a reduction of all the above mentioned molecules on immunohistochemical study in the injected samples compared to the control samples. Fifty six percent of the patients were happy with their eyes being less red and irritated and refrained from further surgery. Four patients subsequently decided to proceed with surgical excision for cosmetic reasons. Astigmatism was found to be increased in 67% of the treated patients which could be related to the retraction of the fibrotic tissue



post-injection exerting a greater force on the cornea inducing further deformation. This is the first time both 5FU and Avastin were combined to treat pterygia. Other studies that used either 5FU or bevacizumab alone (234, 236, 273) concluded that improvements in appearance, colour and surface area of pterygium could be safely achieved with their regimen. However, Avastin on its own was not very effective to halt progression. The results of injecting 5 FU on its own in primary and recurrent pterygia are very similar to the results of REPEAT study (234, 282). As such, 5FU on its own might be used in primary or recurrent pterygium. However, this study found that intraoperative bleeding was much less in eyes treated with the combination regime compared to un-injected eyes. This is most probably related to the use of Avastin which reduced vascularity of the membranes. Combined intralesional injection of Avastin and 5FU was found to be safe and viable option in the management of pterygium on its own or as an adjuvant with surgical excision. Longer follow up is needed to ascertain whether this will reduce the recurrence rate following excision.

In the second study, 32 eyes of 28 patients underwent pterygium surgery for primary and recurrent pterygia. The healing of the conjunctival autografts was temporally studied following the surgery. The changes that occurred in the autoconjunctival grafts were part of the reperfusion injury process which can start as early as 1 day postoperative in the form of haemorrhage and swelling of the graft. These changes were evidenced by fluorescein angiography which was performed in 5 patients in the study. Harvesting of the free conjunctival autograft severs all vascular and lymphatic connections rendering the tissue ischaemic. When the conjunctival autograft vessels establish connections with the episcleral vessels in the new host bed, blood flows into the ischaemic vessels of the conjunctival autograft so they recanalize, swell and leak, giving dramatic clinical features seen in the first few postoperative days. Reconnection between the graft and the bed starts during the first week. All patients having conjunctival autograft will demonstrate patchy or diffuse haemorrhage and swollen grafts due to oedema and/or transudation from the blood vessels in the first week. All the grafts remained in place and the conjunctival autograft epithelium remained intact in all cases at all time-points. At 2 months, most of the swelling and haemorrhage had resolved but the conjunctival autograft demonstrated under-perfused areas where the vascular network was poor or ill-defined. Changes were also seen in the conjunctival bed surrounding the conjunctival autograft in the form of hyperaemia and

scattered haemorrhages. Fibrin glue used to fix the graft, was shown to have an influence on the clinical picture seen both in the conjunctival bed and the conjunctival autograft as it mechanically interfered with epithelial cell migration which proceeds normally once the glue dissolves in 10-14 days. Donor site complications were only seen in 2 eyes in the form of telangiectasia and pyogenic granuloma. This study showed that reperfusion injury occurs in the autoconjunctival graft and is an essential feature of early healing. The changes described in the conjunctival autograft should not be confused with conjunctival recurrence of pterygium. Patients should be assured that the dramatic clinical picture seen in the early post-operative is actually a sign of healing and will steadily decline over time.

Ocular neovascularisation also includes retinal neovascularisation which can occur as a result of diabetic retinopathy (DR). DR is the leading cause of loss of vision in the working age population in the developed world, and is fast gaining importance in the low and middle income countries. Diabetes affects all ocular tissues, although most significant visual loss results from the retinopathy. Clinically, DR is characterized by the formation of microaneurysms, exudates in the outer plexiform layer, retinal haemorrhages, cotton wool spots and retinal vascular calibre changes in the NPDR stage. Recent evidence indicates that diabetic retinal neuropathy is an important consequence of diabetes, which precedes clinical DR. Neovascularisation of the retina (PDR) and iris (iris neovascularisation/rubeosis iridis) occur at the later stages of DR, and are attributed to retinal ischaemia. Retinal neovascularisation may result in bleeding from the fragile vessels leading to pre-retinal and vitreous haemorrhage. Further changes may result in fibrous tissue formation and traction retinal detachment. The effect of anti-VEGF and PASCAL laser treatment whether in the form of panretinal photocoagulation (PRP), focal or macular has not been widely investigated.

This study on diabetics aimed to show the correlation between DR and retinal neuropathy, corneal neuropathy and corneal sensitivity. The study was able to show that the corneal and retinal neuropathy precedes the DR (vascular) changes as there was no significant difference in the corneal nerve parameters between the non-proliferative diabetic retinopathy eyes (NPDR) and eyes of diabetics with no retinopathy, and confirms findings from previous studies (318, 420-422). The study, addition, showed that both corneal sensitivity and corneal neuropathy worsen as the DR becomes more advanced. The study, further, demonstrated that PASCAL laser is a safe option for treating different stages of retinopathy. Anti-VEGF

injections were found to be associated some potentially damaging effect especially in NPDR eyes rather than PDR eyes, as corneal sensitivity was significantly reduced. On the contrary, in eyes with PDR, the corneal neuropathy is most probably due to the long-standing diabetes. The number of injections might be another factor.

The main limitations of this study on diabetic eyes is the inclusion of a small number of eyes within the PDR group and the short follow up visits. Furthermore, information from patient records on the details of the laser sessions for patients in NPDR and PDR groups were incomplete. Further longitudinal studies are needed, with a larger number of PDR eyes and with longer follow up on the same patients before and after PRP and anti-VEGF injections.

This thesis has investigated vascularisation and its modulation in the cornea and retina in different eye diseases. Further studies on the different mechanisms and therapies will be required to optimise treatments.

## BIBLIOGRAPHY

1. Dua HS, Faraj LA, Said DG, Gray T, Lowe J. Human corneal anatomy redefined: a novel pre-Descemet's layer (Dua's layer). *Ophthalmology*. 2013;120(9):1778-85.
2. Gipson IK. The epithelial basement membrane zone of the limbus. *Eye (Lond)*. 1989;3 ( Pt 2):132-40.
3. Krachmer JH, Mannis MJ, Holland EJ. *Cornea*. St. Louis: Mosby; 1997.
4. Alison MR, Poulosom R, Forbes S, Wright NA. An introduction to stem cells. *J Pathol*. 2002;197(4):419-23.
5. Sehic A, Utheim OA, Ommundsen K, Utheim TP. Pre-Clinical Cell-Based Therapy for Limbal Stem Cell Deficiency. *J Funct Biomater*. 2015;6(3):863-88.
6. Dua HS, Miri A, Alomar T, Yeung AM, Said DG. The role of limbal stem cells in corneal epithelial maintenance: testing the dogma. *Ophthalmology*. 2009;116(5):856-63.
7. Majo F, Rochat A, Nicolas M, Jaoude GA, Barrandon Y. Oligopotent stem cells are distributed throughout the mammalian ocular surface. *Nature*. 2008;456(7219):250-4.
8. Higa K, Shimmura S, Miyashita H, Shimazaki J, Tsubota K. Melanocytes in the corneal limbus interact with K19-positive basal epithelial cells. *Experimental eye research*. 2005;81(2):218-23.
9. Chee KY, Kicic A, Wiffen SJ. Limbal stem cells: the search for a marker. *Clin Exp Ophthalmol*. 2006;34(1):64-73.
10. Dziasko MA, Armer HE, Levis HJ, Shortt AJ, Tuft S, Daniels JT. Localisation of epithelial cells capable of holoclone formation in vitro and direct interaction with stromal cells in the native human limbal crypt. *PLoS One*. 2014;9(4):e94283.
11. Shortt AJ, Secker GA, Munro PM, Khaw PT, Tuft SJ, Daniels JT. Characterization of the limbal epithelial stem cell niche: novel imaging techniques permit in vivo observation and targeted biopsy of limbal epithelial stem cells. *Stem Cells*. 2007;25(6):1402-9.
12. Daniels JT, Dart JK, Tuft SJ, Khaw PT. Corneal stem cells in review. *Wound Repair Regen*. 2001;9(6):483-94.
13. Kruse FE, Tseng SC. Growth factors modulate clonal growth and differentiation of cultured rabbit limbal and corneal epithelium. *Investigative ophthalmology & visual science*. 1993;34(6):1963-76.
14. Schofield R. The stem cell system. *Biomed Pharmacother*. 1983;37(8):375-80.
15. Fuchs E, Segre JA. Stem cells: a new lease on life. *Cell*. 2000;100(1):143-55.
16. Janes SM, Lowell S, Hutter C. Epidermal stem cells. *J Pathol*. 2002;197(4):479-91.
17. Dua HS, Azuara-Blanco A. Autologous limbal transplantation in patients with unilateral corneal stem cell deficiency. *The British journal of ophthalmology*. 2000;84(3):273-8.
18. Dua HS, Shanmuganathan VA, Powell-Richards AO, Tighe PJ, Joseph A. Limbal epithelial crypts: a novel anatomical structure and a putative limbal stem cell niche. *The British journal of ophthalmology*. 2005;89(5):529-32.
19. Goldberg MF, Bron AJ. Limbal palisades of Vogt. *Transactions of the American Ophthalmological Society*. 1982;80:155-71.
20. Shanmuganathan VA, Foster T, Kulkarni BB, Hopkinson A, Gray T, Powe DG, et al. Morphological characteristics of the limbal epithelial crypt. *The British journal of ophthalmology*. 2007;91(4):514-9.
21. Dua HS, Forrester JV. Clinical patterns of corneal epithelial wound healing. *American journal of ophthalmology*. 1987;104(5):481-9.

22. Haynes RJ, Tighe PJ, Scott RAH, Dua HS. Human conjunctiva contains high endothelial venules that express lymphocyte homing receptors. *Experimental eye research*. 1999;69(4):397-403.
23. Knop N, Knop E. Conjunctiva-associated lymphoid tissue in the human eye. *Investigative ophthalmology & visual science*. 2000;41(6):1270-9.
24. Dua HS, Gomes JA, Jindal VK, Appa SN, Schwarting R, Eagle RC, Jr., et al. Mucosa specific lymphocytes in the human conjunctiva, corneoscleral limbus and lacrimal gland. *Curr Eye Res*. 1994;13(1):87-93.
25. Maurice DM. The structure and transparency of the cornea. *The Journal of physiology*. 1957;136(2):263-86.
26. Benedek GB. Theory of transparency of the eye. *Applied optics*. 1971;10(3):459-73.
27. Farrell RA, McCally RL, Tatham PE. Wave-length dependencies of light scattering in normal and cold swollen rabbit corneas and their structural implications. *The Journal of physiology*. 1973;233(3):589-612.
28. Fenton BM, Zweifach BW, Worthen DM. Quantitative morphometry of conjunctival microcirculation in diabetes mellitus. *Microvasc Res*. 1979;18(2):153-66.
29. Iwamoto T, Smelser GK. Electron microscope studies on the mast cells and blood and lymphatic capillaries of the human corneal limbus. *Invest Ophthalmol*. 1965;4(5):815-34.
30. Papas EB. The limbal vasculature. *Cont Lens Anterior Eye*. 2003;26(2):71-6.
31. Caplan AI. All MSCs are pericytes? *Cell Stem Cell*. 2008;3(3):229-30.
32. Crisan M, Corselli M, Chen CW, Peault B. Multilineage stem cells in the adult: a perivascular legacy? *Organogenesis*. 2011;7(2):101-4.
33. Bernardo ME, Cometa AM, Pagliara D, Vinti L, Rossi F, Cristantielli R, et al. Ex vivo expansion of mesenchymal stromal cells. *Best Pract Res Clin Haematol*. 2011;24(1):73-81.
34. Corselli M, Chen CW, Crisan M, Lazzari L, Peault B. Perivascular ancestors of adult multipotent stem cells. *Arterioscler Thromb Vasc Biol*. 2010;30(6):1104-9.
35. Stratman AN, Malotte KM, Mahan RD, Davis MJ, Davis GE. Pericyte recruitment during vasculogenic tube assembly stimulates endothelial basement membrane matrix formation. *Blood*. 2009;114(24):5091-101.
36. Dua HS, Azuara-Blanco A. Corneal allograft rejection: risk factors, diagnosis, prevention, and treatment. *Indian J Ophthalmol*. 1999;47(1):3-9.
37. Patel SP, Dana R. Corneal lymphangiogenesis: implications in immunity. *Semin Ophthalmol*. 2009;24(3):135-8.
38. Bonini S, Rama P, Olzi D, Lambiase A. Neurotrophic keratitis. *Eye (Lond)*. 2003;17(8):989-95.
39. Marfurt CF, Cox J, Deek S, Dvorscak L. Anatomy of the human corneal innervation. *Experimental eye research*. 2010;90(4):478-92.
40. Al-Aqaba MA, Fares U, Suleman H, Lowe J, Dua HS. Architecture and distribution of human corneal nerves. *The British journal of ophthalmology*. 2010;94(6):784-9.
41. Stepp MA, Tadvalkar G, Hakh R, Pal-Ghosh S. Corneal Epithelial Cells Function as Surrogate Schwann Cells for Their Sensory Nerves. *Glia*. 2017;65(6):851-63.
42. Beebe DC. Maintaining transparency: a review of the developmental physiology and pathophysiology of two avascular tissues. *Seminars in cell & developmental biology*. 2008;19(2):125-33.
43. Lee P, Wang CC, Adamis AP. Ocular neovascularization: an epidemiologic review. *Surv Ophthalmol*. 1998;43(3):245-69.
44. Bachmann B, Taylor RS, Cursiefen C. Corneal Neovascularization as a Risk Factor for Graft Failure and Rejection after Keratoplasty An Evidence-Based Meta-analysis. *Ophthalmology*. 2010;117(7):1300-U42.
45. Power WJ, Tugal-Tutkun I, Foster CS. Long-term follow-up of patients with atopic keratoconjunctivitis. *Ophthalmology*. 1998;105(4):637-42.
46. Dana MR, Schaumberg DA, Kowal VO, Goren MB, Rapuano CJ, Laibson PR, et al. Corneal neovascularization after penetrating keratoplasty. *Cornea*. 1995;14(6):604-9.

47. Faraj LA, Said DG, Al-Aqaba M, Otri AM, Dua HS. Clinical evaluation and characterisation of corneal vascularisation. *Brit J Ophthalmol.* 2016;100(3):315-22.
48. Centifantofitzgerald YM, Yamaguchi T, Kaufman HE, Tognon M, Roizman B. Ocular Disease Pattern Induced by Herpes-Simplex Virus Is Genetically-Determined by a Specific Region of Viral-DNA. *J Exp Med.* 1982;155(2):475-89.
49. Dana MR, Streilein JW. Loss and restoration of immune privilege in eyes with corneal neovascularization. *Investigative ophthalmology & visual science.* 1996;37(12):2485-94.
50. Azar DT. Corneal angiogenic privilege: angiogenic and antiangiogenic factors in corneal avascularity, vasculogenesis, and wound healing (an American Ophthalmological Society thesis). *Transactions of the American Ophthalmological Society.* 2006;104:264-302.
51. Cursiefen C, Kuchle M, Naumann GO. Angiogenesis in corneal diseases: histopathologic evaluation of 254 human corneal buttons with neovascularization. *Cornea.* 1998;17(6):611-3.
52. Hanahan D, Folkman J. Patterns and emerging mechanisms of the angiogenic switch during tumorigenesis. *Cell.* 1996;86(3):353-64.
53. Folkman J, Shing Y. Angiogenesis. *The Journal of biological chemistry.* 1992;267(16):10931-4.
54. Kato T, Kure T, Chang JH, Gabison EE, Itoh T, Itohara S, et al. Diminished corneal angiogenesis in gelatinase A-deficient mice. *FEBS letters.* 2001;508(2):187-90.
55. Beck L, Jr., D'Amore PA. Vascular development: cellular and molecular regulation. *FASEB journal : official publication of the Federation of American Societies for Experimental Biology.* 1997;11(5):365-73.
56. Ambati BK, Nozaki M, Singh N, Takeda A, Jani PD, Suthar T, et al. Corneal avascularity is due to soluble VEGF receptor-1. *Nature.* 2006;443(7114):993-7.
57. Itoh T, Tanioka M, Yoshida H, Yoshioka T, Nishimoto H, Itohara S. Reduced angiogenesis and tumor progression in gelatinase A-deficient mice. *Cancer research.* 1998;58(5):1048-51.
58. O'Reilly MS, Wiederschain D, Stetler-Stevenson WG, Folkman J, Moses MA. Regulation of angiostatin production by matrix metalloproteinase-2 in a model of concomitant resistance. *The Journal of biological chemistry.* 1999;274(41):29568-71.
59. Ambati BK, Patterson E, Jani P, Jenkins C, Higgins E, Singh N, et al. Soluble vascular endothelial growth factor receptor-1 contributes to the corneal antiangiogenic barrier. *The British journal of ophthalmology.* 2007;91(4):505-8.
60. Cursiefen C, Chen L, Saint-Geniez M, Hamrah P, Jin Y, Rashid S, et al. Nonvascular VEGF receptor 3 expression by corneal epithelium maintains avascularity and vision. *Proceedings of the National Academy of Sciences of the United States of America.* 2006;103(30):11405-10.
61. Chung ES, Chauhan SK, Jin Y, Nakao S, Hafezi-Moghadam A, van Rooijen N, et al. Contribution of macrophages to angiogenesis induced by vascular endothelial growth factor receptor-3-specific ligands. *The American journal of pathology.* 2009;175(5):1984-92.
62. Tombran-Tink J, Chader GG, Johnson LV. PEDF: a pigment epithelium-derived factor with potent neuronal differentiative activity. *Experimental eye research.* 1991;53(3):411-4.
63. Ortego J, Escribano J, Becerra SP, Coca-Prados M. Gene expression of the neurotrophic pigment epithelium-derived factor in the human ciliary epithelium. Synthesis and secretion into the aqueous humor. *Investigative ophthalmology & visual science.* 1996;37(13):2759-67.
64. Karakousis PC, John SK, Behling KC, Surace EM, Smith JE, Hendrickson A, et al. Localization of pigment epithelium derived factor (PEDF) in developing and adult human ocular tissues. *Molecular vision.* 2001;7:154-63.
65. Dawson DW, Volpert OV, Gillis P, Crawford SE, Xu H, Benedict W, et al. Pigment epithelium-derived factor: a potent inhibitor of angiogenesis. *Science.* 1999;285(5425):245-8.
66. Hernandez-Quintela E, Azar DT, O'Reilly MS, Ye HQ, Lu PC, Rachid MD. The role of angiostatin in the cornea after wounding. *Investigative ophthalmology & visual science.* 1999;40(4):S97-S.
67. Tarui T, Miles LA, Takada Y. Specific interaction of angiostatin with integrin alpha(v)beta(3) in endothelial cells. *The Journal of biological chemistry.* 2001;276(43):39562-8.

68. Moser TL, Stack MS, Asplin I, Enghild JJ, Hojrup P, Everitt L, et al. Angiostatin binds ATP synthase on the surface of human endothelial cells. *Proceedings of the National Academy of Sciences of the United States of America*. 1999;96(6):2811-6.
69. Ma G, Molla-Abbassi A, Kritikos M, Ilyukhin A, Jalilehvand F, Kessler V, et al. Structure of the dimethyl sulfoxide solvated thallium(III) ion in solution and in the solid state. *Inorganic chemistry*. 2001;40(25):6432-8.
70. Wajih N, Sane DC. Angiostatin selectively inhibits signaling by hepatocyte growth factor in endothelial and smooth muscle cells. *Blood*. 2003;101(5):1857-63.
71. Coffey PJ, Jin J, Woodgett JR. Protein kinase B (c-Akt): a multifunctional mediator of phosphatidylinositol 3-kinase activation. *The Biochemical journal*. 1998;335 ( Pt 1):1-13.
72. Mirza AM, Kohn AD, Roth RA, McMahon M. Oncogenic transformation of cells by a conditionally active form of the protein kinase Akt/PKB. *Cell Growth Differ*. 2000;11(6):279-92.
73. Patterson BC, Sang QA. Angiostatin-converting enzyme activities of human matrilysin (MMP-7) and gelatinase B/type IV collagenase (MMP-9). *The Journal of biological chemistry*. 1997;272(46):28823-5.
74. Lee SH, Kim KW, Joo K, Kim JC. Angiogenin ameliorates corneal opacity and neovascularization via regulating immune response in corneal fibroblasts. *BMC Ophthalmol*. 2016;16:57.
75. Huo N, Ichikawa Y, Kamiyama M, Ishikawa T, Hamaguchi Y, Hasegawa S, et al. MMP-7 (matrilysin) accelerated growth of human umbilical vein endothelial cells. *Cancer Lett*. 2002;177(1):95-100.
76. Ito TK, Ishii G, Chiba H, Ochiai A. The VEGF angiogenic switch of fibroblasts is regulated by MMP-7 from cancer cells. *Oncogene*. 2007;26(51):7194-203.
77. Lu PC, Ye H, Maeda M, Azar DT. Immunolocalization and gene expression of matrilysin during corneal wound healing. *Investigative ophthalmology & visual science*. 1999;40(1):20-7.
78. Kure T, Chang JH, Kato T, Hernandez-Quintela E, Ye H, Lu PC, et al. Corneal neovascularization after excimer keratectomy wounds in matrilysin-deficient mice. *Investigative ophthalmology & visual science*. 2003;44(1):137-44.
79. Fukai N, Eklund L, Marneros AG, Oh SP, Keene DR, Tamarkin L, et al. Lack of collagen XVIII/endostatin results in eye abnormalities. *EMBO J*. 2002;21(7):1535-44.
80. Yeh SI, Han KY, Sabri A, Rosenblatt MI, Azar DT, Jain S, et al. MMP-7 knock-in corneal fibroblast cell lines secrete MMP-7 with proteolytic activity towards collagen XVIII. *Curr Eye Res*. 2010;35(9):799-805.
81. Ohlmann AV, Ohlmann A, Welge-Lussen U, May CA. Localization of collagen XVIII and endostatin in the human eye. *Curr Eye Res*. 2005;30(1):27-34.
82. O'Reilly MS, Boehm T, Shing Y, Fukai N, Vasios G, Lane WS, et al. Endostatin: an endogenous inhibitor of angiogenesis and tumor growth. *Cell*. 1997;88(2):277-85.
83. Neufeld G, Cohen T, Gengrinovitch S, Poltorak Z. Vascular endothelial growth factor (VEGF) and its receptors. *FASEB journal : official publication of the Federation of American Societies for Experimental Biology*. 1999;13(1):9-22.
84. Stuttfeld E, Ballmer-Hofer K. Structure and function of VEGF receptors. *IUBMB Life*. 2009;61(9):915-22.
85. Amano S, Rohan R, Kuroki M, Tolentino M, Adamis AP. Requirement for vascular endothelial growth factor in wound- and inflammation-related corneal neovascularization. *Investigative ophthalmology & visual science*. 1998;39(1):18-22.
86. Ferrara N, Gerber HP, LeCouter J. The biology of VEGF and its receptors. *Nat Med*. 2003;9(6):669-76.
87. Kvanta A. Ocular angiogenesis: the role of growth factors. *Acta Ophthalmol Scand*. 2006;84(3):282-8.

88. Singh N, Higgins E, Amin S, Jani P, Richter E, Patel A, et al. Unique homologous siRNA blocks hypoxia-induced VEGF upregulation in human corneal cells and inhibits and regresses murine corneal neovascularization. *Cornea*. 2007;26(1):65-72.
89. Stevenson W, Cheng SF, Dastjerdi MH, Ferrari G, Dana R. Corneal neovascularization and the utility of topical VEGF inhibition: ranibizumab (Lucentis) vs bevacizumab (Avastin). *Ocul Surf*. 2012;10(2):67-83.
90. Hiratsuka S, Kataoka Y, Nakao K, Nakamura K, Morikawa S, Tanaka S, et al. Vascular endothelial growth factor A (VEGF-A) is involved in guidance of VEGF receptor-positive cells to the anterior portion of early embryos. *Mol Cell Biol*. 2005;25(1):355-63.
91. Takahashi H, Shibuya M. The vascular endothelial growth factor (VEGF)/VEGF receptor system and its role under physiological and pathological conditions. *Clin Sci*. 2005;109(3):227-41.
92. Campochiaro PA. Ocular neovascularisation and excessive vascular permeability. *Expert Opin Biol Ther*. 2004;4(9):1395-402.
93. Bates DO, Hillman NJ, Williams B, Neal CR, Pocock TM. Regulation of microvascular permeability by vascular endothelial growth factors. *J Anat*. 2002;200(6):581-97.
94. Hood JD, Meininger CJ, Ziche M, Granger HJ. VEGF upregulates eNOS message, protein, and NO production in human endothelial cells. *Am J Physiol-Heart C*. 1998;274(3):H1054-H8.
95. Luttun A, Tjwa M, Moons L, Wu Y, Angelillo-Scherrer A, Liao F, et al. Revascularization of ischemic tissues by PIGF treatment, and inhibition of tumor angiogenesis, arthritis and atherosclerosis by anti-Flt1. *Nat Med*. 2002;8(8):831-40.
96. Joukov V, Pajusola K, Kaipainen A, Chilov D, Lahtinen I, Kukk E, et al. A novel vascular endothelial growth factor, VEGF-C, is a ligand for the Flt4 (VEGFR-3) and KDR (VEGFR-2) receptor tyrosine kinases. *Embo Journal*. 1996;15(2):290-8.
97. Achen MG, Jeltsch M, Kukk E, Makinen T, Vitali A, Wilks AF, et al. Vascular endothelial growth factor D (VEGF-D) is a ligand for the tyrosine kinases VEGF receptor 2 (Flk1) and VEGF receptor 3 (Flt4). *Proceedings of the National Academy of Sciences of the United States of America*. 1998;95(2):548-53.
98. Dana MR. Angiogenesis and lymphangiogenesis-implications for corneal immunity. *Semin Ophthalmol*. 2006;21(1):19-22.
99. Li A, Dubey S, Varney ML, Dave BJ, Singh RK. IL-8 directly enhanced endothelial cell survival, proliferation, and matrix metalloproteinases production and regulated angiogenesis. *J Immunol*. 2003;170(6):3369-76.
100. Chen L, Huq S, Gardner H, de Fougères AR, Barabino S, Dana MR. Very late antigen 1 blockade markedly promotes survival of corneal allografts. *Arch Ophthalmol-Chic*. 2007;125(6):783-8.
101. Li J, Perrella MA, Tsai JC, Yet SF, Hsieh CM, Yoshizumi M, et al. Induction of vascular endothelial growth factor gene expression by interleukin-1 beta in rat aortic smooth muscle cells. *The Journal of biological chemistry*. 1995;270(1):308-12.
102. Cohen T, Nahari D, Cerem LW, Neufeld G, Levi BZ. Interleukin 6 induces the expression of vascular endothelial growth factor. *The Journal of biological chemistry*. 1996;271(2):736-41.
103. Ryuto M, Ono M, Izumi H, Yoshida S, Weich HA, Kohno K, et al. Induction of vascular endothelial growth factor by tumor necrosis factor alpha in human glioma cells. Possible roles of SP-1. *The Journal of biological chemistry*. 1996;271(45):28220-8.
104. Pertovaara L, Kaipainen A, Mustonen T, Orpana A, Ferrara N, Saksela O, et al. Vascular Endothelial Growth-Factor Is Induced in Response to Transforming Growth-Factor-Beta in Fibroblastic and Epithelial-Cells. *Journal of Biological Chemistry*. 1994;269(9):6271-4.
105. Olsen SK, Garbi M, Zampieri N, Eliseenkova AV, Ornitz DM, Goldfarb M, et al. Fibroblast growth factor (FGF) homologous factors share structural but not functional homology with FGFs. *Journal of Biological Chemistry*. 2003;278(36):34226-36.
106. Itoh N, Ornitz DM. Evolution of the Fgf and Fgfr gene families. *Trends Genet*. 2004;20(11):563-9.



107. Beenken A, Mohammadi M. The FGF family: biology, pathophysiology and therapy. *Nat Rev Drug Discov.* 2009;8(3):235-53.
108. Miller DL, Ortega S, Bashayan O, Basch R, Basilico C. Compensation by fibroblast growth factor 1 (FGF1) does not account for the mild phenotypic defects observed in FGF2 null mice. *Mol Cell Biol.* 2000;20(6):2260-8.
109. Adamis AP, Meklir B, Joyce NC. In situ injury-induced release of basic-fibroblast growth factor from corneal epithelial cells. *The American journal of pathology.* 1991;139(5):961-7.
110. Folkman J, Klagsbrun M, Sasse J, Wadzinski M, Ingber D, Vlodavsky I. A Heparin-Binding Angiogenic Protein - Basic Fibroblast Growth-Factor - Is Stored within Basement-Membrane. *American Journal of Pathology.* 1988;130(2):393-400.
111. Soubrane G, Jerdan J, Karpouzas I, Fayein NA, Glaser B, Coscas G, et al. Binding of basic fibroblast growth factor to normal and neovascularized rabbit cornea. *Investigative ophthalmology & visual science.* 1990;31(2):323-33.
112. Ware JA, Simons M. Angiogenesis in ischemic heart disease. *Nat Med.* 1997;3(2):158-64.
113. Yanagisawa-Miwa A, Uchida Y, Nakamura F, Tomaru T, Kido H, Kamijo T, et al. Salvage of infarcted myocardium by angiogenic action of basic fibroblast growth factor. *Science.* 1992;257(5075):1401-3.
114. Munier AI, Doucet D, Perrodou E, Zachary D, Meister M, Hoffmann JA, et al. PVF2, a PDGF/VEGF-like growth factor, induces hemocyte proliferation in *Drosophila* larvae. *Embo Rep.* 2002;3(12):1195-200.
115. Fredriksson L, Li H, Eriksson U. The PDGF family: four gene products form five dimeric isoforms. *Cytokine Growth F R.* 2004;15(4):197-204.
116. Kim WJ, Mohan RR, Mohan RR, Wilson SE. Effect of PDGF, IL-1alpha, and BMP2/4 on corneal fibroblast chemotaxis: expression of the platelet-derived growth factor system in the cornea. *Investigative ophthalmology & visual science.* 1999;40(7):1364-72.
117. Hoppenreijns VP, Pels E, Vrensen GF, Felten PC, Treffers WF. Platelet-derived growth factor: receptor expression in corneas and effects on corneal cells. *Investigative ophthalmology & visual science.* 1993;34(3):637-49.
118. Valenzuela DM, Griffiths JA, Rojas J, Aldrich TH, Jones PF, Zhou H, et al. Angiopoietins 3 and 4: diverging gene counterparts in mice and humans. *Proceedings of the National Academy of Sciences of the United States of America.* 1999;96(5):1904-9.
119. Lobov IB, Brooks PC, Lang RA. Angiopoietin-2 displays VEGF-dependent modulation of capillary structure and endothelial cell survival in vivo. *Proceedings of the National Academy of Sciences of the United States of America.* 2002;99(17):11205-10.
120. Faraj LA, Elalfy MS, Said DG, Dua HS. Fine needle diathermy occlusion of corneal vessels. *The British journal of ophthalmology.* 2014;98(9):1287-90.
121. Murata M, Shimizu S, Horiuchi S, Taira M. Inhibitory effect of triamcinolone acetate on corneal neovascularization. *Graefes' archive for clinical and experimental ophthalmology = Albrecht von Graefes Archiv fur klinische und experimentelle Ophthalmologie.* 2006;244(2):205-9.
122. BenEzra D, Griffin BW, Maftzir G, Sharif NA, Clark AF. Topical formulations of novel angiostatic steroids inhibit rabbit corneal neovascularization. *Investigative ophthalmology & visual science.* 1997;38(10):1954-62.
123. Boneham GC, Collin HB. Steroid inhibition of limbal blood and lymphatic vascular cell growth. *Curr Eye Res.* 1995;14(1):1-10.
124. McNatt LG, Weimer L, Yanni J, Clark AF. Angiostatic activity of steroids in the chick embryo CAM and rabbit cornea models of neovascularization. *J Ocul Pharmacol Ther.* 1999;15(5):413-23.
125. Ashton N, Cook C, Langham M. Effect of cortisone on vascularization and opacification of the cornea induced by alloxan. *The British journal of ophthalmology.* 1951;35(11):718-24.
126. Chang CT, Chen YL, Lee SH, Lue CM, Lin MT. The inhibition of prostaglandin E1-induced corneal neovascularization by steroid eye drops. *Taiwan yi xue hui za zhi Journal of the Formosan Medical Association.* 1989;88(7):707-11.

127. Dinning WJ. Steroids and the eye--indications and complications. *Postgraduate medical journal*. 1976;52(612):634-8.
128. Steinbrook R. The price of sight--ranibizumab, bevacizumab, and the treatment of macular degeneration. *The New England journal of medicine*. 2006;355(14):1409-12.
129. Kaiser PK. Antivascular endothelial growth factor agents and their development: therapeutic implications in ocular diseases. *American journal of ophthalmology*. 2006;142(4):660-8.
130. Liarakos VS, Papaconstantinou D, Vergados I, Douvali M, Theodossiadis PG. The effect of subconjunctival ranibizumab on corneal and anterior segment neovascularization: study on an animal model. *Eur J Ophthalmol*. 2014;24(3):299-308.
131. Ferrari G, Dastjerdi MH, Okanobo A, Cheng SF, Amparo F, Nallasamy N, et al. Topical Ranibizumab as a Treatment of Corneal Neovascularization. *Cornea*. 2013;32(7):992-7.
132. Kim JH, Seo HW, Han HC, Lee JH, Choi SK, Lee D. The effect of bevacizumab versus ranibizumab in the treatment of corneal neovascularization: a preliminary study. *Korean J Ophthalmol*. 2013;27(4):235-42.
133. Ahn YJ, Hwang HB, Chung SK. Ranibizumab injection for corneal neovascularization refractory to bevacizumab treatment. *Korean J Ophthalmol*. 2014;28(2):177-80.
134. Grisanti S, Ziemssen F. Bevacizumab: off-label use in ophthalmology. *Indian J Ophthalmol*. 2007;55(6):417-20.
135. Gordon MS, Margolin K, Talpaz M, Sledge GW, Jr., Holmgren E, Benjamin R, et al. Phase I safety and pharmacokinetic study of recombinant human anti-vascular endothelial growth factor in patients with advanced cancer. *J Clin Oncol*. 2001;19(3):843-50.
136. Kabbinavar F, Hurwitz HI, Fehrenbacher L, Meropol NJ, Novotny WF, Lieberman G, et al. Phase II, randomized trial comparing bevacizumab plus fluorouracil (FU)/leucovorin (LV) with FU/LV alone in patients with metastatic colorectal cancer. *J Clin Oncol*. 2003;21(1):60-5.
137. Hurwitz H. Integrating the anti-VEGF-A humanized monoclonal antibody bevacizumab with chemotherapy in advanced colorectal cancer. *Clin Colorectal Cancer*. 2004;4 Suppl 2:S62-8.
138. Avery RL, Pieramici DJ, Rabena MD, Castellarin AA, Nasir MA, Giust MJ. Intravitreal bevacizumab (Avastin) for neovascular age-related macular degeneration. *Ophthalmology*. 2006;113(3):363-72 e5.
139. Avery RL, Pearlman J, Pieramici DJ, Rabena MD, Castellarin AA, Nasir MA, et al. Intravitreal bevacizumab (Avastin) in the treatment of proliferative diabetic retinopathy. *Ophthalmology*. 2006;113(10):1695 e1-15.
140. Rosenfeld PJ, Fung AE, Puliafito CA. Optical coherence tomography findings after an intravitreal injection of bevacizumab (avastin) for macular edema from central retinal vein occlusion. *Ophthalmic Surg Lasers Imaging*. 2005;36(4):336-9.
141. Shahar J, Avery RL, Heilweil G, Barak A, Zemel E, Lewis GP, et al. Electrophysiologic and retinal penetration studies following intravitreal injection of bevacizumab (Avastin). *Retina*. 2006;26(3):262-9.
142. Heiduschka P, Fietz H, Hofmeister S, Schultheiss S, Mack AF, Peters S, et al. Penetration of bevacizumab through the retina after intravitreal injection in the monkey. *Investigative ophthalmology & visual science*. 2007;48(6):2814-23.
143. Jorge R, Costa RA, Calucci D, Scott IU. Intravitreal bevacizumab (Avastin) associated with the regression of subretinal neovascularization in idiopathic juxtafoveal retinal telangiectasis. *Graefes archive for clinical and experimental ophthalmology = Albrecht von Graefes Archiv fur klinische und experimentelle Ophthalmologie*. 2007;245(7):1045-8.
144. Mandal S, Venkatesh P, Abbas Z, Vohra R, Garg S. Intravitreal bevacizumab (Avastin) for subretinal neovascularization secondary to type 2A idiopathic juxtafoveal telangiectasia. *Graefes archive for clinical and experimental ophthalmology = Albrecht von Graefes Archiv fur klinische und experimentelle Ophthalmologie*. 2007;245(12):1825-9.
145. Laud K, Spaide RF, Freund KB, Slakter J, Klancnik JM, Jr. Treatment of choroidal neovascularization in pathologic myopia with intravitreal bevacizumab. *Retina*. 2006;26(8):960-3.

146. Tewari A, Dhalla MS, Apte RS. Intravitreal bevacizumab for treatment of choroidal neovascularization in pathologic myopia. *Retina*. 2006;26(9):1093-4.
147. Lommatzsch A, Spital G, Trieschmann M, Pauleikhoff D. [Intraocular application of bevacizumab for the treatment of choroidal neovascularization secondary to angioid streaks]. *Ophthalmologie*. 2007;104(4):325-8.
148. Teixeira A, Moraes N, Farah ME, Bonomo PP. Choroidal neovascularization treated with intravitreal injection of bevacizumab (Avastin) in angioid streaks. *Acta Ophthalmol Scand*. 2006;84(6):835-6.
149. Azad R, Chandra P. Intravitreal bevacizumab in aggressive posterior retinopathy of prematurity. *Indian J Ophthalmol*. 2007;55(4):319; author reply 20.
150. Comparison of Age-related Macular Degeneration Treatments Trials Research G, Martin DF, Maguire MG, Fine SL, Ying GS, Jaffe GJ, et al. Ranibizumab and bevacizumab for treatment of neovascular age-related macular degeneration: two-year results. *Ophthalmology*. 2012;119(7):1388-98.
151. Ma N, He XG. [Efficacy and safety in treatment of ocular neovascularization by Bevacizumab versus Ranibizumab: a meta-analysis]. *Zhonghua Yan Ke Za Zhi*. 2010;46(3):263-7.
152. Zheng M, Deshpande S, Lee S, Ferrara N, Rouse BT. Contribution of vascular endothelial growth factor in the neovascularization process during the pathogenesis of herpetic stromal keratitis. *J Virol*. 2001;75(20):9828-35.
153. Hosseini H, Nejabat M. A potential therapeutic strategy for inhibition of corneal neovascularization with new anti-VEGF agents. *Med Hypotheses*. 2007;68(4):799-801.
154. Petsoglou C, Dart J, Balaggan K, Bunce C, Xing W, Tuft S. Pilot Randomized Placebo-Controlled Double-Masked Clinical Trial of Subconjunctival Bevacizumab on Eyes with Recent Onset of Corneal Neovascularization. *Clin Exp Ophthalmol*. 2011;39:24-.
155. Chu HS, Hu FR, Yang CM, Yeh PT, Chen YM, Hou YC, et al. Subconjunctival injection of bevacizumab in the treatment of corneal neovascularization associated with lipid deposition. *Cornea*. 2011;30(1):60-6.
156. Doctor PP, Bhat PV, Foster CS. Subconjunctival bevacizumab for corneal neovascularization. *Cornea*. 2008;27(9):992-5.
157. You IC, Kang IS, Lee SH, Yoon KC. Therapeutic effect of subconjunctival injection of bevacizumab in the treatment of corneal neovascularization. *Acta Ophthalmol*. 2009;87(6):653-8.
158. Gueudry J, Richez F, Tougeron-Brousseau B, Genevois O, Muraine M. [Subconjunctival bevacizumab for corneal neovascularization]. *J Fr Ophthalmol*. 2010;33(9):630-6.
159. Kim TI, Chung JL, Hong JP, Min K, Seo KY, Kim EK. Bevacizumab Application Delays Epithelial Healing in Rabbit Cornea. *Investigative ophthalmology & visual science*. 2009;50(10):4653-9.
160. Jacobs DS, Lim M, Carrasquillo KG, Rosenthal P. Bevacizumab for corneal neovascularization. *Ophthalmology*. 2009;116(3):592-3; author reply 3-4.
161. Krizova D, Vokrojova M, Liehneova K, Studeny P. Treatment of Corneal Neovascularization Using Anti-VEGF Bevacizumab. *J Ophthalmol*. 2014;2014:178132.
162. Dastjerdi MH, Saban DR, Okanobo A, Nallasamy N, Sadrai Z, Chauhan SK, et al. Effects of topical and subconjunctival bevacizumab in high-risk corneal transplant survival. *Investigative ophthalmology & visual science*. 2010;51(5):2411-7.
163. Awadein A. Subconjunctival bevacizumab for vascularized rejected corneal grafts. *J Cataract Refract Surg*. 2007;33(11):1991-3.
164. Zaki AA, Farid SF. Subconjunctival bevacizumab for corneal neovascularization. *Acta Ophthalmol*. 2010;88(8):868-71.
165. DeStafeno JJ, Kim T. Topical bevacizumab therapy for corneal neovascularization. *Arch Ophthalmol*. 2007;125(6):834-6.
166. Koenig Y, Bock F, Horn F, Kruse F, Straub K, Cursiefen C. Short- and long-term safety profile and efficacy of topical bevacizumab (Avastin) eye drops against corneal neovascularization. *Graefes's*

- archive for clinical and experimental ophthalmology = Albrecht von Graefes Archiv fur klinische und experimentelle Ophthalmologie. 2009;247(10):1375-82.
167. Dastjerdi MH, Al-Arfaj KM, Nallasamy N, Hamrah P, Jurkunas UV, Pineda R, 2nd, et al. Topical bevacizumab in the treatment of corneal neovascularization: results of a prospective, open-label, noncomparative study. *Arch Ophthalmol*. 2009;127(4):381-9.
  168. Bakunowicz-Lazarczyk A, Urban B. Assessment of therapeutic options for reducing alkali burn-induced corneal neovascularization and inflammation. *Adv Med Sci*. 2016;61(1):101-12.
  169. Atiba A, Wasfy T, Abdo W, Ghoneim A, Kamal T, Shukry M. Aloe vera gel facilitates re-epithelialization of corneal alkali burn in normal and diabetic rats. *Clin Ophthalmol*. 2015;9:2019-26.
  170. Rho CR, Choi JS, Seo M, Lee SK, Joo CK. Inhibition of Lymphangiogenesis and Hemangiogenesis in Corneal Inflammation by Subconjunctival Prox1 siRNA Injection in Rats. *Investigative ophthalmology & visual science*. 2015;56(10):5871-9.
  171. Sijnave D, Van Bergen T, Castermans K, Kindt N, Vandewalle E, Stassen JM, et al. Inhibition of Rho-Associated Kinase Prevents Pathological Wound Healing and Neovascularization After Corneal Trauma. *Cornea*. 2015;34(9):1120-9.
  172. Lima TB, Ribeiro AP, Conceicao LF, Bandarra M, Manrique WG, Laus JL. Ketorolac eye drops reduce inflammation and delay re-epithelization in response to corneal alkali burn in rabbits, without affecting iNOS or MMP-9. *Arq Bras Oftalmol*. 2015;78(2):67-72.
  173. Cai J, Dou G, Zheng L, Yang T, Jia X, Tang L, et al. Pharmacokinetics of topically applied recombinant human keratinocyte growth factor-2 in alkali-burned and intact rabbit eye. *Experimental eye research*. 2015;136:93-9.
  174. Shadmani A, Kazemi K, Khalili MR, Eghtedari M. Omental transposition in treatment of severe ocular surface alkaline burn: an experimental study. *Med Hypothesis Discov Innov Ophthalmol*. 2014;3(2):57-61.
  175. Dvashi Z, Sar Shalom H, Shohat M, Ben-Meir D, Ferber S, Satchi-Fainaro R, et al. Protein phosphatase magnesium dependent 1A governs the wound healing-inflammation-angiogenesis cross talk on injury. *The American journal of pathology*. 2014;184(11):2936-50.
  176. Crooke A, Guzman-Aranguez A, Mediero A, Alarma-Estrany P, Carracedo G, Pelaez T, et al. Effect of melatonin and analogues on corneal wound healing: involvement of Mt2 melatonin receptor. *Curr Eye Res*. 2015;40(1):56-65.
  177. Cherry PM, Faulkner JD, Shaver RP, Wise JB, Witter SL. Argon laser treatment of corneal neovascularization. *Annals of ophthalmology*. 1973;5(8):911-20.
  178. Cherry PM, Garner A. Corneal neovascularization treated with argon laser. *The British journal of ophthalmology*. 1976;60(6):464-72.
  179. Marsh RJ, Marshall J. Treatment of lipid keratopathy with the argon laser. *The British journal of ophthalmology*. 1982;66(2):127-35.
  180. Baer JC, Foster CS. Corneal laser photocoagulation for treatment of neovascularization. Efficacy of 577 nm yellow dye laser. *Ophthalmology*. 1992;99(2):173-9.
  181. Epstein RJ, Stulting RD, Hendricks RL, Harris DM. Corneal neovascularization. Pathogenesis and inhibition. *Cornea*. 1987;6(4):250-7.
  182. Epstein RJ, Hendricks RL, Harris DM. Photodynamic therapy for corneal neovascularization. *Cornea*. 1991;10(5):424-32.
  183. Schmidt-Erfurth U, Hasan T, Schomacker K, Flotte T, Birngruber R. In vivo uptake of liposomal benzoporphyrin derivative and photothrombosis in experimental corneal neovascularization. *Lasers Surg Med*. 1995;17(2):178-88.
  184. Gohto Y, Obana A, Kaneda K, Nakajima S, Takemura T, Miki T. Accumulation of photosensitizer ATX-S10 (Na) in experimental corneal neovascularization. *Jpn J Ophthalmol*. 2000;44(4):348-53.
  185. Holzer MP, Solomon KD, Vroman DT, Sandoval HP, Margaron P, Kasper TJ, et al. Photodynamic therapy with verteporfin in a rabbit model of corneal neovascularization. *Investigative ophthalmology & visual science*. 2003;44(7):2954-8.

186. Diaz-Davalos CD, Carrasco-Quiroz A, Rivera-Diez D. [Neovascularization corneal regression in patients treated with photodynamic therapy with verteporfin]. *Rev Med Inst Mex Seguro Soc.* 2016;54(2):164-9.
187. Hamdan J, Boulze M, Aziz A, Alessi G, Hoffart L. [Corneal neovascularisation treatments compared: Subconjunctival bevacizumab injections and/or photodynamic therapy]. *J Fr Ophtalmol.* 2015;38(10):924-33.
188. Yoon HJ, Kim MK, Seo KY, Ueta M, Yoon KC. Effectiveness of photodynamic therapy with verteporfin combined with intrastromal bevacizumab for corneal neovascularization in Stevens-Johnson syndrome. *Int Ophthalmol.* 2019;39(1):55-62.
189. Pillai CT, Dua HS, Hossain P. Fine needle diathermy occlusion of corneal vessels. *Investigative ophthalmology & visual science.* 2000;41(8):2148-53.
190. Cursiefen C, Colin J, Dana R, Diaz-Llopis M, Faraj LA, Garcia-Delpech S, et al. Consensus statement on indications for anti-angiogenic therapy in the management of corneal diseases associated with neovascularisation: outcome of an expert roundtable. *The British journal of ophthalmology.* 2012;96(1):3-9.
191. Thatte S. Fine needle diathermy - a choice for managing corneal vascularization. *Nepal J Ophthalmol.* 2011;3(1):23-6.
192. Koenig Y, Bock F, Kruse FE, Stock K, Cursiefen C. Angioregressive Pretreatment of Mature Corneal Blood Vessels Before Keratoplasty: Fine-Needle Vessel Coagulation Combined With Anti-VEGFs. *Cornea.* 2012;31(8):887-92.
193. Elbaz U, Mireskandari K, Shen C, Ali A. Corneal Fine Needle Diathermy With Adjuvant Bevacizumab to Treat Corneal Neovascularization in Children. *Cornea.* 2015;34(7):773-7.
194. Conn H, Berman M, Kenyon K, Langer R, Gage J. Stromal vascularization prevents corneal ulceration. *Investigative ophthalmology & visual science.* 1980;19(4):362-70.
195. Spiteri N, Romano V, Zheng Y, Yadav S, Dwivedi R, Chen J, et al. Corneal angiography for guiding and evaluating fine-needle diathermy treatment of corneal neovascularization. *Ophthalmology.* 2015;122(6):1079-84.
196. Gupta D, Illingworth C. Treatments for corneal neovascularization: a review. *Cornea.* 2011;30(8):927-38.
197. Forsius H. Lipid keratopathy. A clinical and serum lipid chemical study of sixteen cases. *Acta Ophthalmol (Copenh).* 1961;39:273-83.
198. Gaynor PM, Zhang WY, Salehizadeh B, Pettiford B, Kruth HS. Cholesterol accumulation in human cornea: Evidence that extracellular cholesteryl ester-rich lipid particles deposit independently of foam cells. *J Lipid Res.* 1996;37(9):1849-61.
199. Koay PY, Lee WH, Figueiredo FC. Opinions on risk factors and management of corneal graft rejection in the United kingdom. *Cornea.* 2005;24(3):292-6.
200. Chong EM, Dana MR. Graft failure IV. Immunologic mechanisms of corneal transplant rejection. *Int Ophthalmol.* 2008;28(3):209-22.
201. Cursiefen C, Schlotzer-Schrehardt U, Kuchle M, Sorokin L, Breiteneder-Geleff S, Alitalo K, et al. Lymphatic vessels in vascularized human corneas: Immunohistochemical investigation using LYVE-1 and podoplanin. *Investigative ophthalmology & visual science.* 2002;43(7):2127-35.
202. Cursiefen C. Immune privilege and angiogenic privilege of the cornea. *Chem Immunol Allergy.* 2007;92:50-7.
203. Chen L, Cursiefen C, Barabino S, Zhang Q, Dana MR. Novel expression and characterization of lymphatic vessel endothelial hyaluronate receptor 1 (LYVE-1) by conjunctival cells. *Investigative ophthalmology & visual science.* 2005;46(12):4536-40.
204. Detorakis ET, Spandidos DA. Pathogenetic mechanisms and treatment options for ophthalmic pterygium: trends and perspectives (Review). *Int J Mol Med.* 2009;23(4):439-47.
205. Tong L, Lan WW, Sim HS, Hou AH. Conjunctivochalasis is the precursor to pterygium. *Medical Hypotheses.* 2013;81(5):927-30.

206. Clearfield E, Muthappan V, Wang X, Kuo IC. Conjunctival autograft for pterygium. *Cochrane Database Syst Rev*. 2016;2:CD011349.
207. Bahar I, Kaiserman I, McAllum P, Rootman D, Slomovic A. Subconjunctival bevacizumab injection for corneal neovascularization in recurrent pterygium. *Curr Eye Res*. 2008;33(1):23-8.
208. Mansour AM. Treatment of inflamed pterygia or residual pterygial bed. *The British journal of ophthalmology*. 2009;93(7):864-5.
209. Teng CC, Patel NN, Jacobson L. Effect of subconjunctival bevacizumab on primary pterygium. *Cornea*. 2009;28(4):468-70.
210. Hosseini H, Nejabat M, Khaliti MR. Bevacizumab (Avastin) as a potential novel adjunct in the management of pterygia. *Medical Hypotheses*. 2007;69(4):925-7.
211. Mauro J, Foster CS. Pterygia: pathogenesis and the role of subconjunctival bevacizumab in treatment. *Semin Ophthalmol*. 2009;24(3):130-4.
212. Xu YX, Zhang LY, Zou DL, Liu ZS, Shang XM, Wu HP, et al. Differential expression and function of survivin during the progress of pterygium. *Investigative ophthalmology & visual science*. 2014;55(12):8480-7.
213. Coroneo MT, Di Girolamo N, Wakefield D. The pathogenesis of pterygia. *Curr Opin Ophthalmol*. 1999;10(4):282-8.
214. Kria L, Ohira A, Amemiya T. Growth factors in cultured pterygium fibroblasts: immunohistochemical and ELISA analysis. *Graefe's archive for clinical and experimental ophthalmology = Albrecht von Graefes Archiv fur klinische und experimentelle Ophthalmologie*. 1998;236(9):702-8.
215. Lee JK, Song YS, Ha HS, Park JH, Kim MK, Park AJ, et al. Endothelial progenitor cells in pterygium pathogenesis. *Eye (Lond)*. 2007;21(9):1186-93.
216. Jin J, Guan M, Sima J, Gao G, Zhang M, Liu Z, et al. Decreased pigment epithelium-derived factor and increased vascular endothelial growth factor levels in pterygia. *Cornea*. 2003;22(5):473-7.
217. Marcovich AL, Morad Y, Sandbank J, Huszar M, Rosner M, Pollack A, et al. Angiogenesis in pterygium: morphometric and immunohistochemical study. *Curr Eye Res*. 2002;25(1):17-22.
218. Aspiotis M, Tsanou E, Gorezis S, Ioachim E, Skyrilas A, Stefaniotou M, et al. Angiogenesis in pterygium: study of microvessel density, vascular endothelial growth factor, and thrombospondin-1. *Eye (Lond)*. 2007;21(8):1095-101.
219. Gebhardt M, Mentlein R, Schaudig U, Pufe T, Recker K, Nolle B, et al. Differential expression of vascular endothelial growth factor implies the limbal origin of pterygia. *Ophthalmology*. 2005;112(6):1023-30.
220. O'Neill EC, Qin Q, Van Bergen NJ, Connell PP, Vasudevan S, Coote MA, et al. Antifibrotic activity of bevacizumab on human Tenon's fibroblasts in vitro. *Investigative ophthalmology & visual science*. 2010;51(12):6524-32.
221. Park YM, Kim CD, Lee JS. Effect of Bevacizumab on Human Tenon's Fibroblasts Cultured from Primary and Recurrent Pterygium. *Korean J Physiol Pharmacol*. 2015;19(4):357-63.
222. Busin M, Halliday BL, Arffa RC, McDonald MB, Kaufman HE. Precarved lyophilized tissue for lamellar keratoplasty in recurrent pterygium. *American journal of ophthalmology*. 1986;102(2):222-7.
223. Tan DT, Chee SP, Dear KB, Lim AS. Effect of pterygium morphology on pterygium recurrence in a controlled trial comparing conjunctival autografting with bare sclera excision. *Arch Ophthalmol*. 1997;115(10):1235-40.
224. Kim KW, Kim JC. Current approaches and future directions in the management of pterygium. *Int J Ophthalmol*. 2018;11(5):709-11.
225. Campagna G, Adams M, Wang L, Khandelwal S, Al-Mohtaseb Z. Comparison of Pterygium Recurrence Rates Among Different Races and Ethnicities After Primary Pterygium Excision by Surgeons in Training. *Cornea*. 2018;37(2):199-204.
226. Hirst LW, Sebban A, Chant D. Pterygium recurrence time. *Ophthalmology*. 1994;101(4):755-8.

227. Alpay A, Ugurbas SH, Erdogan B. Comparing techniques for pterygium surgery. *Clin Ophthalmol.* 2009;3:69-74.
228. Ozer A, Yildirim N, Erol N, Yurdakul S. Long-term results of bare sclera, limbal-conjunctival autograft and amniotic membrane graft techniques in primary pterygium excisions. *Ophthalmologica.* 2009;223(4):269-73.
229. Kaufman SC, Jacobs DS, Lee WB, Deng SX, Rosenblatt MI, Shtein RM. Options and adjuvants in surgery for pterygium: a report by the American Academy of Ophthalmology. *Ophthalmology.* 2013;120(1):201-8.
230. Luanratanakorn P, Ratanapakorn T, Suwan-Apichon O, Chuck RS. Randomised controlled study of conjunctival autograft versus amniotic membrane graft in pterygium excision. *The British journal of ophthalmology.* 2006;90(12):1476-80.
231. Prabhasawat P, Tesavibul N, Leelapatranura K, Phonjan T. Efficacy of subconjunctival 5-fluorouracil and triamcinolone injection in impending recurrent pterygium. *Ophthalmology.* 2006;113(7):1102-9.
232. Tsai YY, Lin JM, Shy JD. Acute scleral thinning after pterygium excision with intraoperative mitomycin C: a case report of scleral dellen after bare sclera technique and review of the literature. *Cornea.* 2002;21(2):227-9.
233. Safianik B, Ben-Zion I, Garzozzi HJ. Serious corneoscleral complications after pterygium excision with mitomycin C. *The British journal of ophthalmology.* 2002;86(3):357-8.
234. Khan MS, Malik S, Basit I. Effect of intralesional 5 fluorouracil injection in primary pterygium. *Pak J Med Sci.* 2016;32(1):130-3.
235. Malik S, Khan MS, Basit I. Comparison of primary versus recurrent pterygium after intralesional 5-Fluorouracil. *J Pak Med Assoc.* 2016;66(5):559-62.
236. Besharati MR, Manaviat MR, Souzani A. Subconjunctival bevacizumab injection in treatment of pterygium. *Acta Med Iran.* 2011;49(3):179-83.
237. Sarac O, Demirel S, Oltulu R. Efficacy of intralesional bevacizumab administration in primary pterygium: a quantitative analysis. *Eye Contact Lens.* 2014;40(1):46-50.
238. Nakasato H, Uemoto R, Mizuki N. Treatment of pterygium by ligation and bevacizumab injection. *Cornea.* 2012;31(11):1339-41.
239. Fallah MR, Khosravi K, Hashemian MN, Beheshtnezhad AH, Rajabi MT, Gohari M. Efficacy of topical bevacizumab for inhibiting growth of impending recurrent pterygium. *Curr Eye Res.* 2010;35(1):17-22.
240. Mandalos A, Tsakpinis D, Karayannopoulou G, Tsinopoulos I, Karkavelas G, Chalvatzis N, et al. The effect of subconjunctival ranibizumab on primary pterygium: a pilot study. *Cornea.* 2010;29(12):1373-9.
241. Motarjemzadeh Q, Aidenloo NS, Sepehri S. A comparative study of different concentrations of topical bevacizumab on the recurrence rate of excised primary pterygium: a short-term follow-up study. *Int Ophthalmol.* 2016;36(1):63-71.
242. Johnson RD, Pai VC, Hoft RH. Historical Approaches to Pterygium Surgery, Including Bare Sclera and Adjunctive Beta Radiation Techniques. *Pterygium: Techniques and Technologies for Surgical Success.* 2012:27-36.
243. Ang LP, Chua JL, Tan DT. Current concepts and techniques in pterygium treatment. *Curr Opin Ophthalmol.* 2007;18(4):308-13.
244. Segev F, Jaeger-Roshu S, Gefen-Carmi N, Assia EI. Combined mitomycin C application and free flap conjunctival autograft in pterygium surgery. *Cornea.* 2003;22(7):598-603.
245. Tseng SC, Li DQ, Ma X. Suppression of transforming growth factor-beta isoforms, TGF-beta receptor type II, and myofibroblast differentiation in cultured human corneal and limbal fibroblasts by amniotic membrane matrix. *J Cell Physiol.* 1999;179(3):325-35.
246. Katircioglu YA, Altiparmak U, Engur Goktas S, Cakir B, Singar E, Ornek F. Comparison of Two Techniques for the Treatment of Recurrent Pterygium: Amniotic Membrane vs Conjunctival Autograft Combined with Mitomycin C. *Semin Ophthalmol.* 2015;30(5-6):321-7.

247. Tananuvat N, Martin T. The results of amniotic membrane transplantation for primary pterygium compared with conjunctival autograft. *Cornea*. 2004;23(5):458-63.
248. Prabhasawat P, Barton K, Burkett G, Tseng SC. Comparison of conjunctival autografts, amniotic membrane grafts, and primary closure for pterygium excision. *Ophthalmology*. 1997;104(6):974-85.
249. Ma DH, See LC, Hwang YS, Wang SF. Comparison of amniotic membrane graft alone or combined with intraoperative mitomycin C to prevent recurrence after excision of recurrent pterygia. *Cornea*. 2005;24(2):141-50.
250. Cho H, Chuck RS. Pterygium Excision and Placement of Amniotic Membrane Grafts. *Pterygium: Techniques and Technologies for Surgical Success*. 2012:91-100.
251. Kenyon KR, Wagoner MD, Hettinger ME. Conjunctival autograft transplantation for advanced and recurrent pterygium. *Ophthalmology*. 1985;92(11):1461-70.
252. Fernandes M, Sangwan VS, Bansal AK, Gangopadhyay N, Sridhar MS, Garg P, et al. Outcome of pterygium surgery: analysis over 14 years. *Eye (Lond)*. 2005;19(11):1182-90.
253. Bilge AD. Comparison of conjunctival autograft and conjunctival transposition flap techniques in primary pterygium surgery. *Saudi J Ophthalmol*. 2018;32(2):110-3.
254. Koranyi G, Seregard S, Kopp ED. The cut-and-paste method for primary pterygium surgery: long-term follow-up. *Acta Ophthalmol Scand*. 2005;83(3):298-301.
255. Al Fayez MF. Limbal versus conjunctival autograft transplantation for advanced and recurrent pterygium. *Ophthalmology*. 2002;109(9):1752-5.
256. Nuzzi R, Tridico F. How to minimize pterygium recurrence rates: clinical perspectives. *Clinical Ophthalmology*. 2018;12:2347-62.
257. Kumar S, Singh R. Pterygium excision and conjunctival autograft: A comparative study of techniques. *Oman journal of ophthalmology*. 2018;11(2):124-8.
258. Koranyi G, Seregard S, Kopp ED. Cut and paste: a no suture, small incision approach to pterygium surgery. *Brit J Ophthalmol*. 2004;88(7):911-4.
259. McCoombes JA, Hirst LW, Isbell GP. Sliding conjunctival flap for the treatment of primary pterygium. *Ophthalmology*. 1994;101(1):169-73.
260. Bamdad S, Kooshki AS, Yasemi M. Surgical outcome of conjunctival rotational autograft-mitomycin C (MMC) versus free conjunctival autograft-MMC for pterygium removal: A randomized clinical trial. *Electron Physician*. 2017;9(12):5877-84.
261. Bekibele CO, Ashaye A, Olusanya B, Baiyeroju A, Fasina O, Ibrahim AO, et al. 5-Fluorouracil versus mitomycin C as adjuncts to conjunctival autograft in preventing pterygium recurrence. *Int Ophthalmol*. 2012;32(1):3-8.
262. Frucht-Pery J, Ilsar M, Hemo I. Single dosage of mitomycin C for prevention of recurrent pterygium: preliminary report. *Cornea*. 1994;13(5):411-3.
263. Mahar PS. Conjunctival autograft versus topical mitomycin C in treatment of pterygium. *Eye*. 1997;11:790-2.
264. Manning CA, Kloess PM, Diaz MD, Yee RW. Intraoperative mitomycin in primary pterygium excision - A prospective, randomized trial. *Ophthalmology*. 1997;104(5):844-8.
265. Sharma A, Gupta A, Ram J, Gupta A. Low-dose intraoperative mitomycin-C versus conjunctival autograft in primary pterygium surgery: long term follow-up. *Ophthalmic Surg Lasers*. 2000;31(4):301-7.
266. Ari S, Caca I, Yildiz ZO, Sakalar YB, Dogan E. Comparison of mitomycin C and limbal-conjunctival autograft in the prevention of pterygial recurrence in Turkish patients: A one-year, randomized, assessor-masked, controlled trial. *Curr Ther Res Clin Exp*. 2009;70(4):274-81.
267. Biswas MC, Shaw C, Mandal R, Islam MN, Chakroborty M. Treatment of pterygium with conjunctival limbal autograft and mitomycin C--a comparative study. *J Indian Med Assoc*. 2007;105(4):200, 2, 4.



268. Keklikci U, Celik Y, Cakmak SS, Unlu MK, Bilek B. Conjunctival-limbal autograft, amniotic membrane transplantation, and intraoperative mitomycin C for primary pterygium. *Ann Ophthalmol (Skokie)*. 2007;39(4):296-301.
269. Frucht-Pery J, Raiskup F, Ilsar M, Landau D, Orucov F, Solomon A. Conjunctival autografting combined with low-dose mitomycin C for prevention of primary pterygium recurrence. *American journal of ophthalmology*. 2006;141(6):1044-50.
270. Koranyi G, Artzen D, Seregard S, Kopp ED. Intraoperative mitomycin C versus autologous conjunctival autograft in surgery of primary pterygium with four-year follow-up. *Acta Ophthalmol*. 2012;90(3):266-70.
271. Cardillo JA, Alves MR, Ambrosio LE, Poterio MB, Jose NK. Single intraoperative application versus postoperative mitomycin C eye drops in pterygium surgery. *Ophthalmology*. 1995;102(12):1949-52.
272. Nuzzi R, Tridico F. Efficacy of Subconjunctival Bevacizumab Injections before and after Surgical Excision in Preventing Pterygium Recurrence. *J Ophthalmol*. 2017;2017:6824670.
273. Singh P, Sarkar L, Sethi HS, Gupta VS. A randomized controlled prospective study to assess the role of subconjunctival bevacizumab in primary pterygium surgery in Indian patients. *Indian J Ophthalmol*. 2015;63(10):779-84.
274. Bekibele CO, Sarimiye TF, Ogundipe A, Olaniyan S. 5-Fluorouracil vs avastin as adjunct to conjunctival autograft in the surgical treatment of pterygium. *Eye (Lond)*. 2016;30(4):515-21.
275. Nava-Castaneda A, Ulloa-Orozco I, Garnica-Hayashi L, Hernandez-Orgaz J, Jimenez-Martinez MC, Garfias Y. Triple subconjunctival bevacizumab injection for early corneal recurrent pterygium: one-year follow-up. *J Ocul Pharmacol Ther*. 2015;31(2):106-13.
276. Karalezli A, Kucukerdonmez C, Akova YA, Koktekir BE. Does topical bevacizumab prevent postoperative recurrence after pterygium surgery with conjunctival autografting? *Int J Ophthalmol*. 2014;7(3):512-6.
277. Kasetsuwan N, Reinprayoon U, Satitpitakul V. Prevention of recurrent pterygium with topical bevacizumab 0.05% eye drops: a randomized controlled trial. *Clin Ther*. 2015;37(10):2347-51.
278. Bradley JC. Management of Recurrent Pterygium. *Pterygium: Techniques and Technologies for Surgical Success*. 2012:121-34.
279. Khaw PT, Ward S, Porter A, Grierson I, Hitchings RA, Rice NS. The long-term effects of 5-fluorouracil and sodium butyrate on human Tenon's fibroblasts. *Investigative ophthalmology & visual science*. 1992;33(6):2043-52.
280. Blumenkranz MS, Ophir A, Claflin AJ, Hajek A. Fluorouracil for the treatment of massive periretinal proliferation. *American journal of ophthalmology*. 1982;94(4):458-67.
281. Pherwani A, Vakil V, Eatamadi H, Singh R, Dua HS. Postoperative subconjunctival 5-fluorouracil in the management of recurring pterygium. *The British journal of ophthalmology*. 2007;91(3):398-9.
282. Said DG, Faraj LA, Elalfy MS, Yeung A, Miri A, Fares U, et al. Intra-lesional 5 fluorouracil for the management of recurrent pterygium. *Eye (Lond)*. 2013;27(10):1123-9.
283. Pikkell J, Porges Y, Ophir A. Halting pterygium recurrence by postoperative 5-fluorouracil. *Cornea*. 2001;20(2):168-71.
284. Hosseini H, Nejabat M, Khalili MR. Bevacizumab (Avastin) as a potential novel adjunct in the management of pterygia. *Med Hypotheses*. 2007;69(4):925-7.
285. Stival LR, Lago AM, Figueiredo MN, Bittar RH, Machado ML, Nassaralla Junior JJ. Efficacy and safety of subconjunctival bevacizumab for recurrent pterygium. *Arq Bras Oftalmol*. 2014;77(1):4-7.
286. Mutlu FM, Sobaci G, Tatar T, Yildirim E. A comparative study of recurrent pterygium surgery: limbal conjunctival autograft transplantation versus mitomycin C with conjunctival flap. *Ophthalmology*. 1999;106(4):817-21.
287. Ozgurhan EB, Agca A, Kara N, Yuksel K, Demircan A, Demirok A. Topical Application of Bevacizumab as an Adjunct to Recurrent Pterygium Surgery. *Cornea*. 2013;32(6):835-8.

288. Dua HS, Saini JS, Azuara-Blanco A, Gupta P. Limbal stem cell deficiency: concept, aetiology, clinical presentation, diagnosis and management. *Indian J Ophthalmol.* 2000;48(2):83-92.
289. Dua HS, Joseph A, Shanmuganathan VA, Jones RE. Stem cell differentiation and the effects of deficiency. *Eye (Lond).* 2003;17(8):877-85.
290. Dua HS, Azuara-Blanco A. Limbal stem cells of the corneal epithelium. *Surv Ophthalmol.* 2000;44(5):415-25.
291. De Nicola R, Labbe A, Amar N, Dupas B, Baudouin C. In vivo confocal microscopy and ocular surface diseases: anatomical-clinical correlations. *J Fr Ophtalmol.* 2005;28(7):691-8.
292. Dua HS. The conjunctiva in corneal epithelial wound healing. *The British journal of ophthalmology.* 1998;82(12):1407-11.
293. Dua HS, Miri A, Said DG. Contemporary limbal stem cell transplantation - a review. *Clin Exp Ophthalmol.* 2010;38(2):104-17.
294. Holland EJ, Schwartz GS. The evolution of epithelial transplantation for severe ocular surface disease and a proposed classification system. *Cornea.* 1996;15(6):549-56.
295. Dua HS, Azuara-Blanco A. Allo-limbal transplantation in patients with limbal stem cell deficiency. *Brit J Ophthalmol.* 1999;83(4):414-9.
296. Tsubota K, Toda I, Saito H, Shinozaki N, Shimazaki J. Reconstruction of the corneal epithelium by limbal allograft transplantation for severe ocular surface disorders. *Ophthalmology.* 1995;102(10):1486-96.
297. Djalilian AR, Mahesh SP, Koch CA, Nussenblatt RB, Shen D, Zhuang Z, et al. Survival of donor epithelial cells after limbal stem cell transplantation. *Investigative ophthalmology & visual science.* 2005;46(3):803-7.
298. Tsubota K, Satake Y, Kaido M, Shinozaki N, Shimmura S, Bissen-Miyajima H, et al. Treatment of severe ocular-surface disorders with corneal epithelial stem-cell transplantation. *The New England journal of medicine.* 1999;340(22):1697-703.
299. Joseph A, Raj D, Shanmuganathan V, Powell RJ, Dua HS. Tacrolimus immunosuppression in high-risk corneal grafts. *The British journal of ophthalmology.* 2007;91(1):51-5.
300. Dua HS, Forrester JV. The corneoscleral limbus in human corneal epithelial wound healing. *American journal of ophthalmology.* 1990;110(6):646-56.
301. Dua HS, Miri A, Elalfy MS, Lencova A, Said DG. Amnion-assisted conjunctival epithelial redirection in limbal stem cell grafting. *The British journal of ophthalmology.* 2017;101(7):913-9.
302. Curcio CA, Sloan KR, Kalina RE, Hendrickson AE. Human photoreceptor topography. *J Comp Neurol.* 1990;292(4):497-523.
303. Sharma R, Whinger B. Development and structure of the retina. In: Kaufman BA, A., editor. *Adler's physiology of the eye.* 12 ed. St Louis: Mosby; 2003.
304. Panda-Jonas S, Jonas JB, Jakobczyk-Zmija M. Retinal pigment epithelial cell count, distribution, and correlations in normal human eyes. *American journal of ophthalmology.* 1996;121(2):181-9.
305. Levin LA. Optic nerve. In: Kaufman PLA, A., editor. *Adler's Physiology of the Eye.* 10 ed. St Louis: Mosby; 2003. p. 603-38.
306. Tessier-Lavigne M. Visual processing by the retina. In: Kandel ERS, J.H.; Jessell, T.M., editor. *Principles of Neural Science.* 4 ed. New York: McGraw-Hill; 2000. p. 507-22.
307. Wurtz RH, Kandel ERS, J.H.; Jessell, T.M. Central visual pathways. In: Kandel ERS, J.H.; Jessell, T.M., editor. *Principles of Neural Science.* 4 ed. New York: McGraw-Hill; 2000. p. 523-47.
308. Roof DJ, Makino CL. The structure and function of retinal photoreceptors. In: Albert DAJ, F.A., editor. *Principles and Practice of Ophthalmology.* 2 ed. Philadelphia: Saunders; 2000. p. 1624-73.
309. Alm A, Bill A. Ocular and Optic-Nerve Blood-Flow at Normal and Increased Intraocular Pressures in Monkeys (*Macaca-Irus*) - Study with Radioactively Labeled Microspheres Including Flow Determinations in Brain and Some Some Other Tissues. *Experimental eye research.* 1973;15(1):15-29.

310. Alm A, Bill A, Young FA. The effects of pilocarpine and neostigmine on the blood flow through the anterior uvea in monkeys. A study with radioactively labelled microspheres. *Experimental eye research*. 1973;15(1):31-6.
311. Ogden TE. Nerve fiber layer of the macaque retina: retinotopic organization. *Investigative ophthalmology & visual science*. 1983;24(1):85-98.
312. Newman EA. Muller cells and the retinal pigment epithelium In: Albert DAJ, F.A., editor. *Principles and Practice of Ophthalmology*. 2 ed. Philadelphia: Saunders; 2000. p. 1763-85.
313. Zhu MD, Madigan MC, Van Driel D, Maslim J, Billson FA, Provis JM, et al. The human hyaloid system: Cell death and vascular regression. *Experimental eye research*. 2000;70(6):767-76.
314. Radius RL, Anderson DR. The histology of retinal nerve fiber layer bundles and bundle defects. *Arch Ophthalmol*. 1979;97(5):948-50.
315. Hogan MJ, Alvarado JA, Weddell JE. *Histology of the Human Eye. Retina*. Philadelphia: Saunders; 1971. p. 393-521.
316. Cioffi G, Granstream E, Alm A. Ocular circulation. In: Kaufman BA, A., editor. *Adler's physiology of the eye*. 12 ed. St Louis: Mosby; 2003.
317. Campochiaro PA. Molecular pathogenesis of retinal and choroidal vascular diseases. *Prog Retin Eye Res*. 2015;49:67-81.
318. Yau JW, Rogers SL, Kawasaki R, Lamoureux EL, Kowalski JW, Bek T, et al. Global prevalence and major risk factors of diabetic retinopathy. *Diabetes Care*. 2012;35(3):556-64.
319. Wong TY, Sun J, Kawasaki R, Ruamviboonsuk P, Gupta N, Lansingh VC, et al. Guidelines on Diabetic Eye Care: The International Council of Ophthalmology Recommendations for Screening, Follow-up, Referral, and Treatment Based on Resource Settings. *Ophthalmology*. 2018;125(10):1608-22.
320. Solomon SD, Chew E, Duh EJ, Sobrin L, Sun JK, VanderBeek BL, et al. Diabetic Retinopathy: A Position Statement by the American Diabetes Association. *Diabetes Care*. 2017;40(3):412-8.
321. Robinson R, Barathi VA, Chaurasia SS, Wong TY, Kern TS. Update on animal models of diabetic retinopathy: from molecular approaches to mice and higher mammals. *Dis Model Mech*. 2012;5(4):444-56.
322. Nakao S, Arita R, Nakama T, Yoshikawa H, Yoshida S, Enaida H, et al. Wide-field laser ophthalmoscopy for mice: a novel evaluation system for retinal/choroidal angiogenesis in mice. *Investigative ophthalmology & visual science*. 2013;54(8):5288-93.
323. Park JR, Choi W, Hong HK, Kim Y, Park SJ, Hwang Y, et al. Imaging Laser-Induced Choroidal Neovascularization in the Rodent Retina Using Optical Coherence Tomography Angiography. *Investigative ophthalmology & visual science*. 2016;57(9):Oct331-Oct40.
324. Ikeda W, Nakatani T, Uemura A. Cataract-preventing contact lens for in vivo imaging of mouse retina. *Biotechniques*. 2018;65(2):101-4.
325. Giacco F, Brownlee M. Oxidative stress and diabetic complications. *Circ Res*. 2010;107(9):1058-70.
326. Reddy MA, Natarajan R. Epigenetic mechanisms in diabetic vascular complications. *Cardiovasc Res*. 2011;90(3):421-9.
327. El-Osta A, Brasacchio D, Yao D, Poci A, Jones PL, Roeder RG, et al. Transient high glucose causes persistent epigenetic changes and altered gene expression during subsequent normoglycemia. *J Exp Med*. 2008;205(10):2409-17.
328. Rubsam A, Parikh S, Fort PE. Role of Inflammation in Diabetic Retinopathy. *Int J Mol Sci*. 2018;19(4).
329. Miyamoto K, Khosrof S, Bursell SE, Rohan R, Murata T, Clermont AC, et al. Prevention of leukostasis and vascular leakage in streptozotocin-induced diabetic retinopathy via intercellular adhesion molecule-1 inhibition. *Proceedings of the National Academy of Sciences of the United States of America*. 1999;96(19):10836-41.
330. Sohn EH, van Dijk HW, Jiao CH, Kok PHB, Jeong W, Demirkaya N, et al. Retinal neurodegeneration may precede microvascular changes characteristic of diabetic retinopathy in

- diabetes mellitus. *Proceedings of the National Academy of Sciences of the United States of America*. 2016;113(19):E2655-E64.
331. van Dijk HW, Kok PH, Garvin M, Sonka M, Devries JH, Michels RP, et al. Selective loss of inner retinal layer thickness in type 1 diabetic patients with minimal diabetic retinopathy. *Investigative ophthalmology & visual science*. 2009;50(7):3404-9.
332. Frydkjaer-Olsen U, Hansen RS, Simo R, Cunha-Vaz J, Peto T, Grauslund J, et al. Correlation between Retinal Vessel Calibre and Neurodegeneration in Patients with Type 2 Diabetes Mellitus in the European Consortium for the Early Treatment of Diabetic Retinopathy (EUROCONDOR). *Ophthalmic Research*. 2016;56(1):10-6.
333. Barber AJ, Lieth E, Khin SA, Antonetti DA, Buchanan AG, Gardner TW. Neural apoptosis in the retina during experimental and human diabetes. Early onset and effect of insulin. *J Clin Invest*. 1998;102(4):783-91.
334. Senger DR, Galli SJ, Dvorak AM, Perruzzi CA, Harvey VS, Dvorak HF. Tumor cells secrete a vascular permeability factor that promotes accumulation of ascites fluid. *Science*. 1983;219(4587):983-5.
335. Leung DW, Cachianes G, Kuang WJ, Goeddel DV, Ferrara N. Vascular Endothelial Growth-Factor Is a Secreted Angiogenic Mitogen. *Science*. 1989;246(4935):1306-9.
336. Aiello LP, Avery RL, Arrigg PG, Keyt BA, Jampel HD, Shah ST, et al. Vascular endothelial growth factor in ocular fluid of patients with diabetic retinopathy and other retinal disorders. *The New England journal of medicine*. 1994;331(22):1480-7.
337. Tolentino MJ, Miller JW, Gragoudas ES, Jakobiec FA, Flynn E, Chatzistefanou K, et al. Intravitreal injections of vascular endothelial growth factor produce retinal ischemia and microangiopathy in an adult primate. *Ophthalmology*. 1996;103(11):1820-8.
338. Simons M, Gordon E, Claesson-Welsh L. Mechanisms and regulation of endothelial VEGF receptor signalling. *Nat Rev Mol Cell Biol*. 2016;17(10):611-25.
339. Koch S, Claesson-Welsh L. Signal transduction by vascular endothelial growth factor receptors. *Cold Spring Harb Perspect Med*. 2012;2(7):a006502.
340. Miller JW, Le Couter J, Strauss EC, Ferrara N. Vascular Endothelial Growth Factor A in Intraocular Vascular Disease. *Ophthalmology*. 2013;120(1):106-14.
341. Campochiaro PA, Aiello LP, Rosenfeld PJ. Anti-Vascular Endothelial Growth Factor Agents in the Treatment of Retinal Disease: From Bench to Bedside. *Ophthalmology*. 2016;123(10S):S78-S88.
342. Augustin HG, Koh GY, Thurston G, Alitalo K. Control of vascular morphogenesis and homeostasis through the angiopoietin-Tie system. *Nat Rev Mol Cell Biol*. 2009;10(3):165-77.
343. Regula JT, Lundh von Leithner P, Foxton R, Barathi VA, Cheung CM, Bo Tun SB, et al. Targeting key angiogenic pathways with a bispecific CrossMAb optimized for neovascular eye diseases. *EMBO Mol Med*. 2016;8(11):1265-88.
344. Cheung N, Mitchell P, Wong TY. Diabetic retinopathy. *Lancet*. 2010;376(9735):124-36.
345. Shu DY, Lovicu FJ. Myofibroblast transdifferentiation: The dark force in ocular wound healing and fibrosis. *Progress in Retinal and Eye Research*. 2017;60:44-65.
346. Di Girolamo N, Chui J, Coroneo MT, Wakefield D. Pathogenesis of pterygia: role of cytokines, growth factors, and matrix metalloproteinases. *Prog Retin Eye Res*. 2004;23(2):195-228.
347. Gumus K, Karakucuk S, Mirza GE, Akgun H, Arda H, Oner AO. Overexpression of vascular endothelial growth factor receptor 2 in pterygia may have a predictive value for a higher postoperative recurrence rate. *Brit J Ophthalmol*. 2014;98(6):796-800.
348. Ling S, Li Q, Lin H, Li W, Wang T, Ye H, et al. Comparative evaluation of lymphatic vessels in primary versus recurrent pterygium. *Eye (Lond)*. 2012;26(11):1451-8.
349. Bornstein P, Sage EH. Matricellular proteins: extracellular modulators of cell function. *Curr Opin Cell Biol*. 2002;14(5):608-16.
350. Riordan-Eva P, Kielhorn I, Ficker LA, Steele AD, Kirkness CM. Conjunctival autografting in the surgical management of pterygium. *Eye (Lond)*. 1993;7 ( Pt 5):634-8.

351. Kheirkhah A, Hashemi H, Adelpour M, Nikdel M, Rajabi MB, Behrouz MJ. Randomized Trial of Pterygium Surgery with Mitomycin C Application Using Conjunctival Autograft versus Conjunctival-Limbal Autograft. *Ophthalmology*. 2012;119(2):227-32.
352. Bayar SA, Kucukerdonmez C, Oner O, Akova YA. Subconjunctival bevacizumab in the impending recurrent pterygia. *Int Ophthalmol*. 2014;34(3):541-7.
353. Mohamed TA, Soliman W, Fathalla AM, El Refaie A. Effect of single subconjunctival injection of bevacizumab on primary pterygium: clinical, histopathological and immunohistochemical study. *Int J Ophthalmol*. 2018;11(5):797-801.
354. Naib-Majani W, Eltohami I, Wernert N, Watts W, Tschesche H, Pleyer U, et al. Distribution of extracellular matrix proteins in pterygia: an immunohistochemical study. *Graefe's archive for clinical and experimental ophthalmology = Albrecht von Graefes Archiv fur klinische und experimentelle Ophthalmologie*. 2004;242(4):332-8.
355. Schlereth SL, Neuser B, Caramoy A, Grajewski RS, Koch KR, SchrodL F, et al. Enrichment of lymphatic vessel endothelial hyaluronan receptor 1 (LYVE1)-positive macrophages around blood vessels in the normal human sclera. *Investigative ophthalmology & visual science*. 2014;55(2):865-72.
356. Detorakis ET, Zaravinos A, Spandidos DA. Growth factor expression in ophthalmic pterygia and normal conjunctiva. *Int J Mol Med*. 2010;25(4):513-6.
357. Dake Y, Mukae R, Soda Y, Kaneko M, Amemiya T. Immunohistochemical localization of collagen types I, II, III, and IV in pterygium tissues. *Acta Histochem*. 1989;87(1):71-4.
358. Kase S, Osaki M, Sato I, Takahashi S, Nakanishi K, Yoshida K, et al. Immunolocalisation of E-cadherin and beta-catenin in human pterygium. *The British journal of ophthalmology*. 2007;91(9):1209-12.
359. Kim KW, Park SH, Kim JC. Fibroblast biology in pterygia. *Experimental eye research*. 2016;142:32-9.
360. Lin A, Stern G. Correlation between pterygium size and induced corneal astigmatism. *Cornea*. 1998;17(1):28-30.
361. Gazzard G, Saw SM, Farook M, Koh D, Widjaja D, Chia SE, et al. Pterygium in Indonesia: prevalence, severity and risk factors. *The British journal of ophthalmology*. 2002;86(12):1341-6.
362. Fotouhi A, Hashemi H, Khabazkhoob M, Mohammad K. Prevalence and risk factors of pterygium and pinguecula: the Tehran Eye Study. *Eye (Lond)*. 2009;23(5):1125-9.
363. Li Z, Cui H. Prevalence and associated factors for pterygium in a rural adult population (the Southern Harbin Eye Study). *Cornea*. 2013;32(6):806-9.
364. Pan HW, Zhong JX, Jing CX. Comparison of fibrin glue versus suture for conjunctival autografting in pterygium surgery: a meta-analysis. *Ophthalmology*. 2011;118(6):1049-54.
365. Boucher S, Conlon R, Teja S, Teichman JC, Yeung S, Ziai S, et al. Fibrin glue versus autologous blood for conjunctival autograft fixation in pterygium surgery. *Can J Ophthalmol*. 2015;50(4):269-72.
366. Kurian A, Reghunadhan I, Nair KG. Autologous blood versus fibrin glue for conjunctival autograft adherence in sutureless pterygium surgery: a randomised controlled trial. *The British journal of ophthalmology*. 2015;99(4):464-70.
367. Gris O, Guell JL, del Campo Z. Limbal-conjunctival autograft transplantation for the treatment of recurrent pterygium. *Ophthalmology*. 2000;107(2):270-3.
368. Yuksel B, Unsal SK, Onat S. Comparison of fibrin glue and suture technique in pterygium surgery performed with limbal autograft. *Int J Ophthalmol*. 2010;3(4):316-20.
369. Mak RK, Chan TCY, Marcet MM, Choy BNK, Shum JWH, Shih KC, et al. Use of anti-vascular endothelial growth factor in the management of pterygium. *Acta Ophthalmologica*. 2017;95(1):20-7.
370. Kampitak K, Leelawongtawun W, Leeamornsiri S, Suphachearaphan W. Role of artificial tears in reducing the recurrence of pterygium after surgery: a prospective randomized controlled trial. *Acta Ophthalmol*. 2017;95(3):e227-e9.
371. Koranyi G, Artzen D, Wijk T. Learning curve in the Cut and Paste method for surgery of primary pterygium. *Acta Ophthalmol*. 2013;91(5):463-8.

372. Ayala M. Results of pterygium surgery using a biologic adhesive. *Cornea*. 2008;27(6):663-7.
373. Karalezli A, Kucukerdonmez C, Akova YA, Altan-Yaycioglu R, Borazan M. Fibrin glue versus sutures for conjunctival autografting in pterygium surgery: a prospective comparative study. *The British journal of ophthalmology*. 2008;92(9):1206-10.
374. Por YM, Tan DT. Assessment of fibrin glue in pterygium surgery. *Cornea*. 2010;29(1):1-4.
375. Ratnalingam V, Eu ALK, Ng GL, Taharin R, John E. Fibrin Adhesive Is Better Than Sutures in Pterygium Surgery. *Cornea*. 2010;29(5):485-9.
376. Nieuwendaal CP, van der Meulen IJE, Mourits M, Lapid-Gortzak R. Long-Term Follow-Up of Pterygium Surgery Using a Conjunctival Autograft and Tissucol. *Cornea*. 2011;30(1):34-6.
377. Cha DM, Kim KH, Choi HJ, Kim MK, Wee WR. A comparative study of the effect of fibrin glue versus sutures on clinical outcome in patients undergoing pterygium excision and conjunctival autografts. *Korean J Ophthalmol*. 2012;26(6):407-13.
378. Welder JD, Pandya HK, Nassiri N, Djalilian AR. Conjunctival Limbal Autograft and Allograft Transplantation Using Fibrin Glue. *Ophthalm Surg Las Im*. 2012;43(4):323-7.
379. Sandra S, Zeljka J, Zeljka VA, Kristian S, Ivana A. The influence of pterygium morphology on fibrin glue conjunctival autografting pterygium surgery. *Int Ophthalmol*. 2014;34(1):75-9.
380. Eltzhig HK, Eckle T. Ischemia and reperfusion--from mechanism to translation. *Nat Med*. 2011;17(11):1391-401.
381. Duehrkop C, Rieben R. Ischemia/reperfusion injury: effect of simultaneous inhibition of plasma cascade systems versus specific complement inhibition. *Biochem Pharmacol*. 2014;88(1):12-22.
382. Rousou JA. Use of Fibrin Sealants in Cardiovascular Surgery: A Systematic Review. *J Cardiac Surg*. 2013;28(3):238-47.
383. Yeung AM, Faraj LA, McIntosh OD, Dhillon VK, Dua HS. Fibrin glue inhibits migration of ocular surface epithelial cells. *Eye (Lond)*. 2016;30(10):1389-94.
384. Mazhdrakova I, Demerdjieva Z. [Neovascularisation of the cornea]. *Klin Monbl Augenheilkd*. 2005;222(8):623-9.
385. Maguire MG, Stark WJ, Gottsch JD, Stulting RD, Sugar A, Fink NE, et al. Risk factors for corneal graft failure and rejection in the collaborative corneal transplantation studies. Collaborative Corneal Transplantation Studies Research Group. *Ophthalmology*. 1994;101(9):1536-47.
386. Trikha S, Parikh S, Osmond C, Anderson DF, Hossain PN. Long-term outcomes of Fine Needle Diathermy for established corneal neovascularisation. *The British journal of ophthalmology*. 2014;98(4):454-8.
387. Benayoun Y, Petellat F, Leclerc O, Dost L, Dallaudiere B, Reddy C, et al. [Current treatments for corneal neovascularization]. *J Fr Ophtalmol*. 2015;38(10):996-1008.
388. Vassileva PI, Hergeldzhieva TG. Avastin use in high risk corneal transplantation. *Graef Arch Clin Exp*. 2009;247(12):1701-6.
389. Erdurmus M, Totan Y. Subconjunctival bevacizumab for corneal neovascularization. *Graefe's archive for clinical and experimental ophthalmology = Albrecht von Graefes Archiv fur klinische und experimentelle Ophthalmologie*. 2007;245(10):1577-9.
390. Carrasco MA. Subconjunctival bevacizumab for corneal neovascularization in herpetic stromal keratitis. *Cornea*. 2008;27(6):743-5.
391. Symes RJ, Poole TR. Corneal graft surgery combined with subconjunctival bevacizumab (avastin). *Cornea*. 2010;29(6):691-3.
392. Fasciani R, Mosca L, Giannico MI, Ambrogio SA, Balestrazzi E. Subconjunctival and/or intrastromal bevacizumab injections as preconditioning therapy to promote corneal graft survival. *International Ophthalmology*. 2015;35(2):221-7.
393. Romano V, Steger B, Kaye SB. Fine-Needle Diathermy Guided by Angiography. *Cornea*. 2015;34(9):e29-30.
394. Hussain R, Savant V. Fine-Needle Diathermy with Simultaneous Subconjunctival Bevacizumab. *Semin Ophthalmol*. 2017;32(5):550-2.

395. Romano V, Steger B, Brunner M, Ahmad S, Willoughby CE, Kaye SB. Method for Angiographically Guided Fine-Needle Diathermy in the Treatment of Corneal Neovascularization. *Cornea*. 2016;35(7):1029-32.
396. Cheng SF, Dastjerdi MH, Ferrari G, Okanobo A, Bower KS, Ryan DS, et al. Short-term topical bevacizumab in the treatment of stable corneal neovascularization. *American journal of ophthalmology*. 2012;154(6):940-8 e1.
397. Agarwal S, Angayarkanni N, Iyer G, Srinivasan B, Natarajan R, Charola S, et al. Clinico-biochemical correlation of the effect of subconjunctival bevacizumab for corneal neovascularization. *Cornea*. 2014;33(10):1016-21.
398. Daya SM, Watson A, Sharpe JR, Giledi O, Rowe A, Martin R, et al. Outcomes and DNA analysis of ex vivo expanded stem cell allograft for ocular surface reconstruction. *Ophthalmology*. 2005;112(3):470-7.
399. Meller D, Pires RTF, Tseng SCG. Ex vivo expansion of human limbal epithelial stem cells on amniotic membrane. *Investigative ophthalmology & visual science*. 2000;41(4):S454-S.
400. Shortt AJ, Secker GA, Lomas RJ, Wilshaw SP, Kearney JN, Tuft SJ, et al. The effect of amniotic membrane preparation method on its ability to serve as a substrate for the ex-vivo expansion of limbal epithelial cells. *Biomaterials*. 2009;30(6):1056-65.
401. Rama P, Matuska S, Paganoni G, Spinelli A, De Luca M, Pellegrini G. Limbal stem-cell therapy and long-term corneal regeneration. *The New England journal of medicine*. 2010;363(2):147-55.
402. Sotozono C, Inatomi T, Nakamura T, Koizumi N, Yokoi N, Ueta M, et al. Visual improvement after cultivated oral mucosal epithelial transplantation. *Ophthalmology*. 2013;120(1):193-200.
403. Takeda K, Nakamura T, Inatomi T, Sotozono C, Watanabe A, Kinoshita S. Ocular Surface Reconstruction Using the Combination of Autologous Cultivated Oral Mucosal Epithelial Transplantation and Eyelid Surgery for Severe Ocular Surface Disease. *American journal of ophthalmology*. 2011;152(2):195-201.
404. Pellegrini G, Traverso CE, Franzi AT, Zingirian M, Cancedda R, De Luca M. Long-term restoration of damaged corneal surfaces with autologous cultivated corneal epithelium. *Lancet*. 1997;349(9057):990-3.
405. Rama P, Bonini S, Lambiase A, Golisano O, Paterna P, De Luca M, et al. Autologous fibrin-cultured limbal stem cells permanently restore the corneal surface of patients with total limbal stem cell deficiency. *Transplantation*. 2001;72(9):1478-85.
406. Scholz SL, Thomasen H, Hestermann K, Dekowski D, Steuhl KP, Meller D. [Long-term results of autologous transplantation of limbal epithelium cultivated ex vivo for limbal stem cell deficiency]. *Ophthalmologie*. 2016;113(4):321-9.
407. Shimazaki J, Aiba M, Goto E, Kato N, Shimmura S, Tsubota K. Transplantation of human limbal epithelium cultivated on amniotic membrane for the treatment of severe ocular surface disorders. *Ophthalmology*. 2002;109(7):1285-90.
408. Basu S, Sureka SP, Shanbhag SS, Kethiri AR, Singh V, Sangwan VS. Simple Limbal Epithelial Transplantation: Long-Term Clinical Outcomes in 125 Cases of Unilateral Chronic Ocular Surface Burns. *Ophthalmology*. 2016;123(5):1000-10.
409. Vazirani J, Ali MH, Sharma N, Gupta N, Mittal V, Atallah M, et al. Autologous simple limbal epithelial transplantation for unilateral limbal stem cell deficiency: multicentre results. *The British journal of ophthalmology*. 2016;100(10):1416-20.
410. Shi Y, Hu FB. The global implications of diabetes and cancer. *Lancet*. 2014;383(9933):1947-8.
411. Vos T, Flaxman AD, Naghavi M, Lozano R, Michaud C, Ezzati M, et al. Years lived with disability (YLDs) for 1160 sequelae of 289 diseases and injuries 1990-2010: a systematic analysis for the Global Burden of Disease Study 2010. *Lancet*. 2012;380(9859):2163-96.
412. Yau JWY, Rogers SL, Kawasaki R, Lamoureux EL, Kowalski JW, Bek T, et al. Global Prevalence and Major Risk Factors of Diabetic Retinopathy. *Diabetes Care*. 2012;35(3):556-64.
413. Wilson JMG, Jungner G. Principles and practice of screening for disease. Geneva,: World Health Organization; 1968. 164 p. p.

414. Klein R, Klein BE, Moss SE, Davis MD, DeMets DL. The Wisconsin Epidemiologic Study of Diabetic Retinopathy. IX. Four-year incidence and progression of diabetic retinopathy when age at diagnosis is less than 30 years. *Arch Ophthalmol*. 1989;107(2):237-43.
415. Klein R, Klein BE, Moss SE, Davis MD, DeMets DL. The Wisconsin epidemiologic study of diabetic retinopathy. III. Prevalence and risk of diabetic retinopathy when age at diagnosis is 30 or more years. *Arch Ophthalmol*. 1984;102(4):527-32.
416. Stratton IM, Kohner EM, Aldington SJ, Turner RC, Holman RR, Manley SE, et al. UKPDS 50: risk factors for incidence and progression of retinopathy in Type II diabetes over 6 years from diagnosis. *Diabetologia*. 2001;44(2):156-63.
417. Intensive blood-glucose control with sulphonylureas or insulin compared with conventional treatment and risk of complications in patients with type 2 diabetes (UKPDS 33). UK Prospective Diabetes Study (UKPDS) Group. *Lancet*. 1998;352(9131):837-53.
418. Tight blood pressure control and risk of macrovascular and microvascular complications in type 2 diabetes: UKPDS 38. UK Prospective Diabetes Study Group. *BMJ*. 1998;317(7160):703-13.
419. Klein R, Sharrett AR, Klein BEK, Moss SE, Folsom AR, Wong TY, et al. The association of atherosclerosis, vascular risk factors, and retinopathy in adult's with diabetes - The atherosclerosis risk in communities study. *Ophthalmology*. 2002;109(7):1225-34.
420. Simo R, Hernandez C, European Consortium for the Early Treatment of Diabetic R. Neurodegeneration in the diabetic eye: new insights and therapeutic perspectives. *Trends Endocrinol Metab*. 2014;25(1):23-33.
421. Barber AJ. Diabetic retinopathy: recent advances towards understanding neurodegeneration and vision loss. *Sci China Life Sci*. 2015;58(6):541-9.
422. Stem MS, Gardner TW. Neurodegeneration in the pathogenesis of diabetic retinopathy: molecular mechanisms and therapeutic implications. *Curr Med Chem*. 2013;20(26):3241-50.
423. Abcouwer SF, Gardner TW. Diabetic retinopathy: loss of neuroretinal adaptation to the diabetic metabolic environment. *Ann N Y Acad Sci*. 2014;1311:174-90.
424. Jindal V. Neurodegeneration as a Primary Change and Role of Neuroprotection in Diabetic Retinopathy. *Mol Neurobiol*. 2015;51(3):878-84.
425. Simo R, Hernandez C. Novel approaches for treating diabetic retinopathy based on recent pathogenic evidence. *Prog Retin Eye Res*. 2015;48:160-80.
426. Santos AR, Ribeiro L, Bandello F, Lattanzio R, Egan C, Frydkjaer-Olsen U, et al. Functional and Structural Findings of Neurodegeneration in Early Stages of Diabetic Retinopathy: Cross-sectional Analyses of Baseline Data of the EUROCONDOR Project. *Diabetes*. 2017;66(9):2503-10.
427. Debut DC, Somfai GM. Early detection of retinal thickness changes in diabetes using Optical Coherence Tomography. *Med Sci Monitor*. 2010;16(3):Mt15-Mt21.
428. Park HY, Kim IT, Park CK. Early diabetic changes in the nerve fibre layer at the macula detected by spectral domain optical coherence tomography. *The British journal of ophthalmology*. 2011;95(9):1223-8.
429. Vujosevic S, Midena E. Retinal layers changes in human preclinical and early clinical diabetic retinopathy support early retinal neuronal and Muller cells alterations. *J Diabetes Res*. 2013;2013:905058.
430. Chhablani J, Sharma A, Goud A, Peguda HK, Rao HL, Begum VU, et al. Neurodegeneration in Type 2 Diabetes: Evidence From Spectral-Domain Optical Coherence Tomography. *Investigative ophthalmology & visual science*. 2015;56(11):6333-8.
431. Fong DS, Aiello LP, Ferris FL, 3rd, Klein R. Diabetic retinopathy. *Diabetes Care*. 2004;27(10):2540-53.
432. Tavakoli M, Malik RA. Corneal confocal microscopy: a novel non-invasive technique to quantify small fibre pathology in peripheral neuropathies. *J Vis Exp*. 2011(47).
433. Tavakoli M, Petropoulos IN, Malik RA. Assessing corneal nerve structure and function in diabetic neuropathy. *Clin Exp Optom*. 2012;95(3):338-47.



434. Zhivov A, Winter K, Hovakimyan M, Peschel S, Harder V, Schober HC, et al. Imaging and Quantification of Subbasal Nerve Plexus in Healthy Volunteers and Diabetic Patients with or without Retinopathy. *Plos One*. 2013;8(1).
435. Malik RA, Kallinikos P, Abbott CA, van Schie CH, Morgan P, Efron N, et al. Corneal confocal microscopy: a non-invasive surrogate of nerve fibre damage and repair in diabetic patients. *Diabetologia*. 2003;46(5):683-8.
436. Chang PY, Carrel H, Huang JS, Wang IJ, Hou YC, Chen WL, et al. Decreased density of corneal basal epithelium and subbasal corneal nerve bundle changes in patients with diabetic retinopathy. *American journal of ophthalmology*. 2006;142(3):488-90.
437. Midea E, Brugin E, Ghirlando A, Somavilla M, Avogaro A. Corneal diabetic neuropathy: a confocal microscopy study. *J Refract Surg*. 2006;22(9 Suppl):S1047-52.
438. Mocan MC, Durukan I, Irkeç M, Orhan M. Morphologic alterations of both the stromal and subbasal nerves in the corneas of patients with diabetes. *Cornea*. 2006;25(7):769-73.
439. Rosenberg ME, Tervo TM, Immonen IJ, Muller LJ, Gronhagen-Riska C, Vesaluoma MH. Corneal structure and sensitivity in type 1 diabetes mellitus. *Investigative ophthalmology & visual science*. 2000;41(10):2915-21.
440. De Cilla S, Ranno S, Carini E, Fogagnolo P, Ceresara G, Orzalesi N, et al. Corneal subbasal nerves changes in patients with diabetic retinopathy: an in vivo confocal study. *Investigative ophthalmology & visual science*. 2009;50(11):5155-8.
441. Misra S, Ahn HN, Craig JP, Pradhan M, Patel DV, McGhee CN. Effect of panretinal photocoagulation on corneal sensation and the corneal subbasal nerve plexus in diabetes mellitus. *Investigative ophthalmology & visual science*. 2013;54(7):4485-90.
442. Bressler SB, Qin H, Melia M, Bressler NM, Beck RW, Chan CK, et al. Exploratory analysis of the effect of intravitreal ranibizumab or triamcinolone on worsening of diabetic retinopathy in a randomized clinical trial. *JAMA Ophthalmol*. 2013;131(8):1033-40.
443. Mitchell P, Bressler N, Tolley K, Gallagher M, Petrillo J, Ferreira A, et al. Patient-Reported Visual Function Outcomes Improve After Ranibizumab Treatment in Patients With Vision Impairment Due to Diabetic Macular Edema Randomized Clinical Trial. *Jama Ophthalmology*. 2013;131(10):1339-47.
444. Mitchell P. Patient-Reported Visual Function Outcomes Improve After Ranibizumab Treatment in Patients With Vision Impairment Due to Diabetic Macular Edema: Randomized Clinical Trial (vol 131, pg 1339, 2013). *Jama Ophthalmology*. 2013;131(12):1652-.
445. Nishijima K, Ng YS, Zhong LC, Bradley J, Schubert W, Jo N, et al. Vascular endothelial growth factor-A is a survival factor for retinal neurons and a critical neuroprotectant during the adaptive response to ischemic injury. *American Journal of Pathology*. 2007;171(1):53-67.
446. D'Amore PA. Vascular endothelial cell growth factor-A - Not just for endothelial cells anymore. *American Journal of Pathology*. 2007;171(1):14-8.
447. Bock F, Onderka J, Rummelt C, Dietrich T, Bachmann B, Kruse FE, et al. Safety Profile of Topical VEGF Neutralization at the Cornea. *Investigative ophthalmology & visual science*. 2009;50(5):2095-102.
448. Lopes GJA, Casella AMB, Oguido AP, Matsuo T. Effects of topical and subconjunctival use of bevacizumab on corneal neovascularization in rabbits' eyes. *Arquivos Brasileiros De Oftalmologia*. 2017;80(4):252-6.
449. Dong M, Di G, Zhang X, Zhou Q, Shi W. Subconjunctival Bevacizumab Injection Impairs Corneal Innervations and Epithelial Wound Healing in Mice. *Investigative ophthalmology & visual science*. 2017;58(3):1469-77.
450. Goldhardt R, Batawi HIM, Rosenblatt M, Lollett IV, Park JJ, Galor A. Effect of Anti-Vascular Endothelial Growth Factor Therapy on Corneal Nerves. *Cornea*. 2019;38(5):559-64.
451. Neira-Zalentein W, Holopainen JM, Tervo TM, Borrás F, Acosta MC, Belmonte C, et al. Corneal sensitivity in diabetic patients subjected to retinal laser photocoagulation. *Investigative ophthalmology & visual science*. 2011;52(8):6043-9.

452. Tavakoli M, Kallinikos P, Iqbal A, Herbert A, Fadavi H, Efron N, et al. Corneal confocal microscopy detects improvement in corneal nerve morphology with an improvement in risk factors for diabetic neuropathy. *Diabet Med*. 2011;28(10):1261-7.
453. Hertz P, Bril V, Orszag A, Ahmed A, Ng E, Nwe P, et al. Reproducibility of in vivo corneal confocal microscopy as a novel screening test for early diabetic sensorimotor polyneuropathy. *Diabetic Med*. 2011;28(10):1253-60.
454. Schiodte SN. Effects on choroidal nerves after panretinal xenon arc and argon laser photocoagulation. *Acta Ophthalmol (Copenh)*. 1984;62(2):244-55.
455. Sondell M, Lundborg G, Kanje M. Vascular endothelial growth factor has neurotrophic activity and stimulates axonal outgrowth, enhancing cell survival and Schwann cell proliferation in the peripheral nervous system. *J Neurosci*. 1999;19(14):5731-40.
456. Bocker-Meffert S, Rosenstiel P, Rohl C, Warneke N, Held-Feindt J, Sievers J, et al. Erythropoietin and VEGF promote neural outgrowth from retinal explants in postnatal rats. *Investigative ophthalmology & visual science*. 2002;43(6):2021-6.
457. Sun Y, Jin K, Xie L, Childs J, Mao XO, Logvinova A, et al. VEGF-induced neuroprotection, neurogenesis, and angiogenesis after focal cerebral ischemia. *J Clin Invest*. 2003;111(12):1843-51.
458. Inan UU, Avci B, Kusbeci T, Kaderli B, Avci R, Temel SG. Preclinical safety evaluation of intravitreal injection of full-length humanized vascular endothelial growth factor antibody in rabbit eyes. *Investigative ophthalmology & visual science*. 2007;48(4):1773-81.
459. Zhu Y, Jin K, Mao XO, Greenberg DA. Vascular endothelial growth factor promotes proliferation of cortical neuron precursors by regulating E2F expression. *FASEB journal : official publication of the Federation of American Societies for Experimental Biology*. 2003;17(2):186-93.
460. Liu Y, Figley S, Spratt SK, Lee G, Ando D, Surosky R, et al. An engineered transcription factor which activates VEGF-A enhances recovery after spinal cord injury. *Neurobiol Dis*. 2010;37(2):384-93.
461. Jin K, Zhu Y, Sun Y, Mao XO, Xie L, Greenberg DA. Vascular endothelial growth factor (VEGF) stimulates neurogenesis in vitro and in vivo. *Proceedings of the National Academy of Sciences of the United States of America*. 2002;99(18):11946-50.
462. Sondell M, Sundler F, Kanje M. Vascular endothelial growth factor is a neurotrophic factor which stimulates axonal outgrowth through the flk-1 receptor. *Eur J Neurosci*. 2000;12(12):4243-54.
463. Yu CQ, Zhang M, Matis KI, Kim C, Rosenblatt MI. Vascular endothelial growth factor mediates corneal nerve repair. *Investigative ophthalmology & visual science*. 2008;49(9):3870-8.
464. Li Z, Burns AR, Han L, Rumbaut RE, Smith CW. IL-17 and VEGF are necessary for efficient corneal nerve regeneration. *The American journal of pathology*. 2011;178(3):1106-16.