

Necrotising fasciitis: a case report

RACHEL VELLA CRITIEN

Abstract

Necrotising fasciitis is a rapidly progressive and potentially life-threatening bacterial infection involving the subcutaneous tissues and fascia which can result in extensive tissue necrosis and severe sepsis. Key factors affecting survival include an early diagnosis, surgical debridement and the appropriate use of antimicrobials. We present a case in a diabetic patient with necrotizing fasciitis of the abdominal wall secondary to a subcutaneous saline infusion, describing the presentation, diagnosis and the successful treatment of this patient.

Introduction

Necrotising fasciitis leads to the development of thrombosis of skin microcirculation, resulting in necrosis of skin and soft tissue, destruction of muscles, and liquefaction of fats. Mortality in several studies has ranged from 22% to 44%, with the truncal region having a higher mortality (44%) than the perineal region (28%) and the extremities (22%).¹

The case report highlights the importance of a high index of suspicion. In the early stages, the signs can be non-specific and can mimic other non-severe soft tissue infections. Severe pain at onset, out of proportion to the clinical findings, can be an important pointer towards the diagnosis. It shows how the commonly used subcutaneous injections can be a cause of necrotizing fasciitis.

Case presentation

A 69 year old male was noted to have an elevated temperature of 39°C during routine parameters. His past medical history included cerebrovascular accident, type 2 diabetes mellitus, hypertension, atrial fibrillation, hypothyroidism and congestive heart failure.

On initial examination, he was tachypnoeic and hypertensive. Other physical parameters were normal.

Left-sided basal crackles were identified on chest auscultation. The values of laboratory parameters were as follows: leucocytes $18.10 \times 10^9/L$ and C-reactive protein (CRP) 187mg/L. All other laboratory values were within normal range. The first clinical impression was one of hypostatic pneumonia. He was thus started on antibiotics and on a subcutaneous saline infusion.

The clinical status of the patient deteriorated further despite the treatment. The patient started complaining of severe abdominal pain; on palpation, there was generalized tenderness over the right hypochondrium with associated rigidity. There was also a well demarcated area of erythema and induration of the skin localized to the region of insertion of the subcutaneous infusion.

The patient was transferred to a surgical ward for further investigations and management. A computed tomography scan of the abdomen showed inflammatory changes (indicative of an infection) with free gas in the abdominal wall on the right of the mesogastrium (figure 1).

A diagnosis of necrotising fasciitis of the abdominal wall secondary to the subcutaneous infusion

was formulated. The patient was transferred to the operating theatre where the abdominal wall was incised and surgical debridement of the infected tissues was performed under local anaesthetic (figure 2). The wound was packed with alginate and left to heal by secondary intention.

Postoperatively the patient was started on intravenous metronidazole and piperacillin/tazobactam. The clinical course of the infection was closely observed by monitoring the patient's vitals including temperature, physiological functions and laboratory parameters. Eventually the leukocyte and C-reactive protein values decreased significantly and the patient's clinical status improved.

Discussion

The hypothesis is that the subcutaneous injection for the saline infusion resulted in a loss of skin integrity with a subsequent bacterial inoculation into the subcutaneous space resulting in damage to the overlying skin. One can suspect that skin contamination contributed to the aetiology.

Several reports link intramuscular injections and intravenous drug abuse to the development of necrotising fasciitis.² Other reported aetiologies

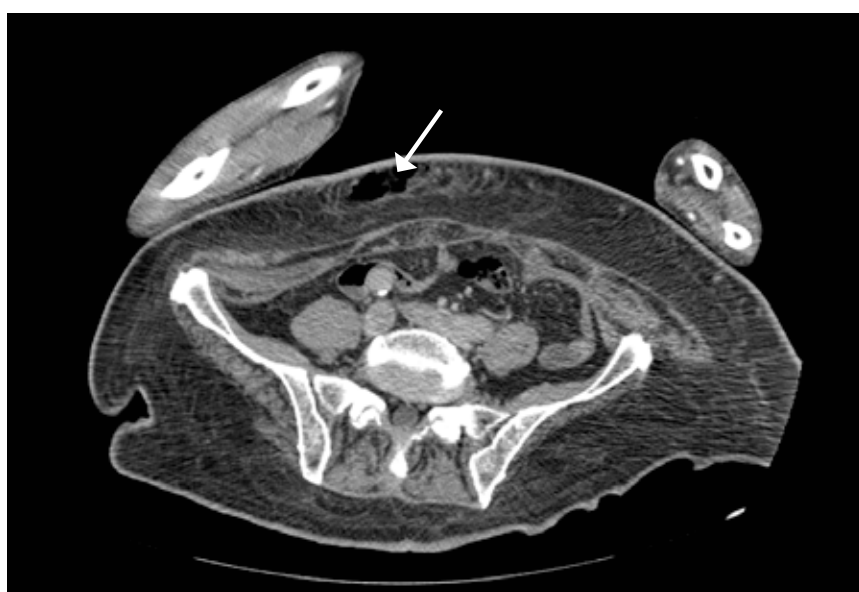


Figure 1. The CT scan of the abdomen showing gases in the abdominal wall (arrow).

include blunt or penetrating trauma and haematogenous spread from a distant site. No literature was found linking subcutaneous saline injections to the development of necrotizing fasciitis.

The patient was a known case of diabetes. His uncontrolled diabetes, as monitored by his glycosylated haemoglobin, resulted in an increased susceptibility to the development of necrotizing fasciitis. Increasing age is another consistent risk factor across several case studies; although the condition can affect any age group.¹ Other recognized risk factors for this condition include immunosuppression and chronic systemic diseases (for example atherosclerosis and renal failure).³

This patient presented with the typical early symptoms of necrotizing fasciitis: fever, erythema and out-of-proportion pain on physical examination. Such pain preceded any skin changes. This occurs in the majority of patients (>97.8%) with necrotizing fasciitis.¹ The intensity of the local signs could have also been weakened by the previous antibiotic therapy.

The CT scan was an important tool in this case, allowing the detection of gas tracking along the fascial planes. The radiological data was correlated to the clinical and laboratory results in order to establish the diagnosis of necrotising fasciitis. Despite this, CT scans sometimes do not adequately differentiate between severe cellulitis and necrotizing fasciitis. Magnetic resonance imaging has been reported as having the highest sensitivity (93-100%) for diagnosing necrotizing fasciitis, exhibiting high signal intensity on T2-weighted images.⁴

Other diagnostic procedures for necrotising fasciitis include the LRINEC (Laboratory Risk Indicator for Necrotising Fasciitis) which is a scoring system developed by Wong et al.⁵ The C-reactive protein, creatinine, haemoglobin, leukocyte count, serum sodium and glucose are used in this score. A score of 6 'raises the suspicion' and a score of 8 is 'strongly predictive' (table 1). A score of 7

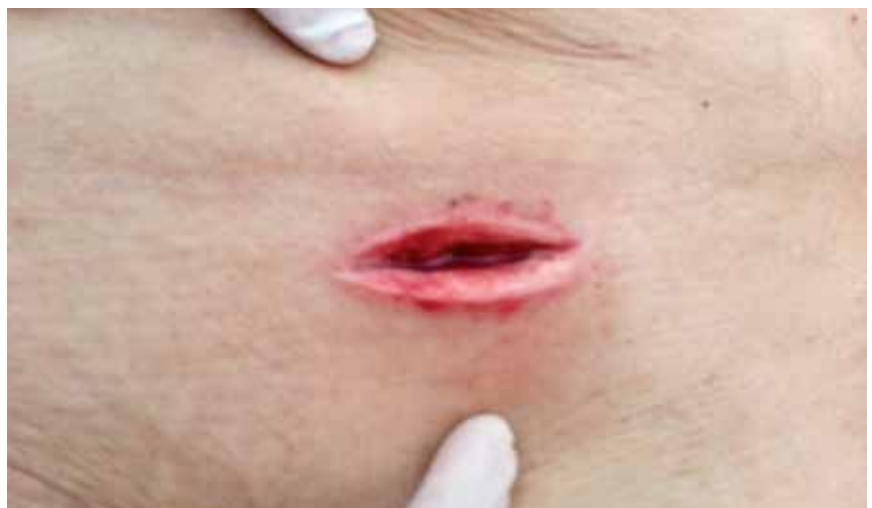

Figure 2. The incision in the lower abdominal wall following surgical debridement

VARIABLES	SCORE
HAEMOGLOBIN	
>13.5	0
11-13.5	1
<11	2
TOTAL WHITE CELL COUNT	
<15	0
15-25	1
>25	2
GLUCOSE	
<10	0
>10	1
C-REACTIVE PROTEIN (mg/dl)	
<150	0
>150	4
SODIUM (mmol/L)	
>135	0
<135	2
CREATININE (µmol/L)	
<141	0
>141	2

Table 1. Laboratory Indicator Necrotising Fasciitis Scoring System (LRINEC)⁵

was retrospectively calculated for this patient.

Conclusion

Subcutaneous injections can represent a local portal of entry for infection that can progress to serious skin infections such as necrotising fasciitis. Necrotising fasciitis should be suspected in every skin infection with fever, signs of systemic toxicity and severe pain. S

References

1. Machado NO. Necrotising fasciitis: The importance of early diagnosis, prompt surgical debridement and adjuvant therapy. *North American Journal of Medical Sciences* 2011; 3:107-118.
2. Espandar R, Sibdari S, Rafiee E, Yazdani S. Necrotising Fasciitis of the extremities: a prospective study. *Strat Traum Limb Recon* 2011; 6(3): 121-5.
3. Chang VC, Chen C, Wu H. Necrotising Fasciitis. *J Med Sci* 2008; 28 (4):175-8.
4. Smeets L, Bous A, Heymans O. Necrotising Fasciitis: Case Report and Review of Literature. *Acta chir belg* 2007; 107:29-36.
5. Morgan MS. Diagnosis and management of necrotising fasciitis: a multiparametric approach. *J Hosp Infect* 2010; 75(4): 249-57.