

Case Number 9

Posterior fossa craniectomy and C1/C2 laminectomy for Arnold-Chiari II decompression of syrinx

Daniela Zammit & Kelly Iles

Reviewed by: Mr. Antoine Zrinzo

Case summary:

Demographic details:

Mr. CC, Male.

Referred from: Home.

Presenting complaint:

Patient had a three-week history of gait disturbance, balance problems, paraesthesia in his right arm and pain in his right shoulder, together with urine frequency and urgency.

History of presenting complaint:

This patient was diagnosed shortly after birth with right-sided facial palsy as a result of lower motor neuron facial nerve involvement, together with spinal abnormalities and hearing impairment (patient currently uses hearing aids). He also has 13 ribs on his left side and 11 ribs on the right, hemi-vertebra at T2/T3 and T8/T9 and fused vertebral bodies at C2/C3 and C6/C7. As a result, clinically he has a short neck with restriction of all neck movements, particularly rotation. Patient is also known to have situs inversus.

From the MRI, it showed he had an Arnold-Chiari malformation. Therefore, the cerebellar tonsils herniated through the foramen magnum which resulted in disruption of the CSF flow. This led to the formation of a syrinx within the spinal cord, the condition being known as Syringomyelia. The syrinx can expand and elongate over time, destroying part of the spinal cord so that the damage will cause the symptoms felt by the patient. Symptoms vary between patients and also depending on the location of the syrinx; in this case, the patient experienced the gait disturbances, balance problems, paraesthesia, pain and bowel control issues. His symptoms suggest a cape-like distribution of paraesthesia and sensory disturbance attributable to syringomyelia.

Past medical and surgical history:

Past medical history:

Sinusitis

Irritable Bowel Syndrome (IBS)

Shortness of breath at times, especially on lying down (Orthopnoea)

Past surgical history:

Inguinal Hernia repair

Drug history:

Drug	Dosage	Frequency	Type	Reason
Desloratadine (NeoClarityn)	1 tablet	BD	Anti-histamine	Relief for nasal congestion
Triamcinolone (Nasacort)			Nasal spray containing adrenocortical steroid	To treat nasal allergies
Alfuzosin (Xatral)	5mg	BD	α 1- Receptor antagonist	Relaxes bladder and prostate neck to ease urination
Ambroxol (Muciclar)	10ml	TDS	Mucolytic agent	Reduces the viscosity of the mucus by stimulating production of surfactant

Family history:

The patient's mother is diabetic but no similar congenital malformations were observed in his family.

Social history:

Patient lives with his parents. He is a university student in his final year. Does not smoke and drinks alcohol socially.

Systemic inquiry:

- General Health: the patient appeared well and afebrile. He was not suffering from headaches or visual disturbances. However, he requires bilateral hearing aids.
- Cardiovascular System: no chest pain or palpitations.
- Respiratory System: complained of shortness of breath on lying down (orthopnoea) and gross sinusitis. Patient was producing yellowish-green sputum up to a week before the surgery. However, both right and left lungs were clear on chest examination.
- Gastrointestinal System: no abdominal pain, bleeding or melaena. Opens bowels around three times per day (small bouts). Abdomen is soft but not tender.
- Genitourinary System: one month history of urinary frequency and urgency. No dysuria.
- Central Nervous System: right sided facial palsy; Bilateral hearing impairment; Horizontal Nystagmus.
- Musculoskeletal System: marked restriction of neck movements.
- Endocrine System: nil to note.

Current therapy:

Patient was undergoing physiotherapy before being admitted.

Discussion of results of general and specific examinations:

Physical examination: Blood pressure recorded 141/51. Chest auscultation is clear both on the right and left sides.

Neurological examination: Patient has right sided facial palsy, bilateral hearing aids and horizontal nystagmus.

Musculoskeletal examination:

UPPER LIMBS:

	Right	Left
Tone	Normal	Normal
Power: Shoulder Flexion	5/5	5/5
Extension	5/5	5/5
Elbow Flexion	5/5	5/5
Extension	5/5	5/5
Finger Flexion	5/5	5/5
Extension	5/5	5/5
Abduction	5/5	5/5
Adduction	5/5	5/5
Thumb Flexion	5/5	5/5
Extension	5/5	5/5
Sensation	Normal	Normal
Reflexes: Biceps	++	++
Triceps	++	++
Hoffmann's	-ve	-ve

LOWER LIMB:

	Right	Left
Tone:	Normal	Normal
Power: Straight Leg Raising	5/5	5/5
Knee Flexion	4/5	4/5
Extension	4/5	4/5
Ankle Flexion	5/5	5/5
Extension	5/5	5/5
Toe flexion	5/5	5/5
Sensation:	Reduced at lower outer leg	Normal
Reflexes: Knee	++	++
Ankle	++	++
Gait: Ataxic	++	
Cannot walk on tiptoes		
Cannot walk on heels		

Diagnostic procedures:

Instrumental exams:

Test: MR Head

Justification for test: To assess for spinal pathology.

Result: The cerebellar tonsils are herniated 1.8 cm below the Foramen of Magnum secondary to a shallow posterior fossa. No vermian agenesis is demonstrated. There are no midline anomalies or space occupying lesions. Ventricles are not dilated.

Conclusion: Malformations compatible with Arnold-Chiari were present.

Test: MR Whole spine - Cervical Spine, Lumbar/sacral and Thoracic

Justification for test: To assess the presence of syrinx.

Result: Tonsillar herniation and large syrinx within the spinal cord of cervical spine extending till cervico-thoracic junction. There is bone abnormality in which the C5 - C6 and C7-Th1 vertebral bodies are fused. The thoraco-lumbar spine shows normal alignment. The disk spaces are maintained

and no cord or thecal compression seen.

Conclusion: Presence of syrinx and cerebellar tonsillar herniation confirmed. X-ray of cervical spine recommended for better evaluation of the bones.

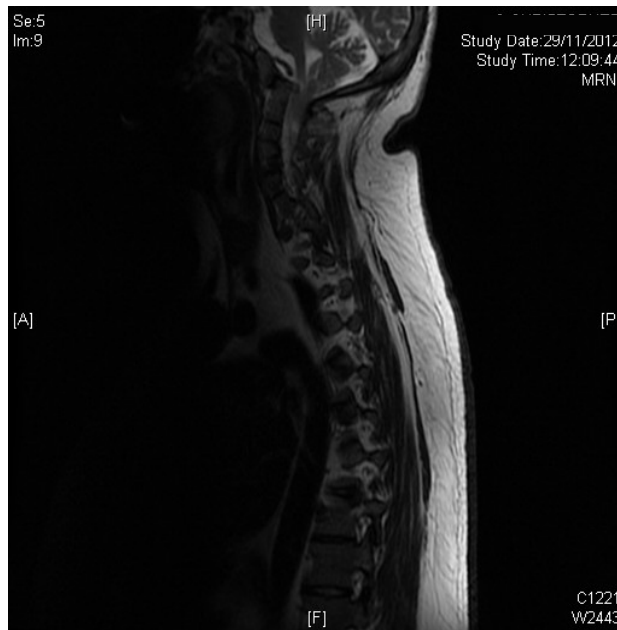


Figure 1: MRI scan showing the cerebellar herniation through the foramen magnum and vertebral fusion.

Test: Chest X-Ray

Justification for test: X-ray of cervical spine for better evaluation of the bones.

Result: There is probably situs inversus (known) together with scoliosis which is probably a consequence of congenital abnormality of Th7-Th8 vertebrae. No pulmonary lesions observed. No cardiomegaly.

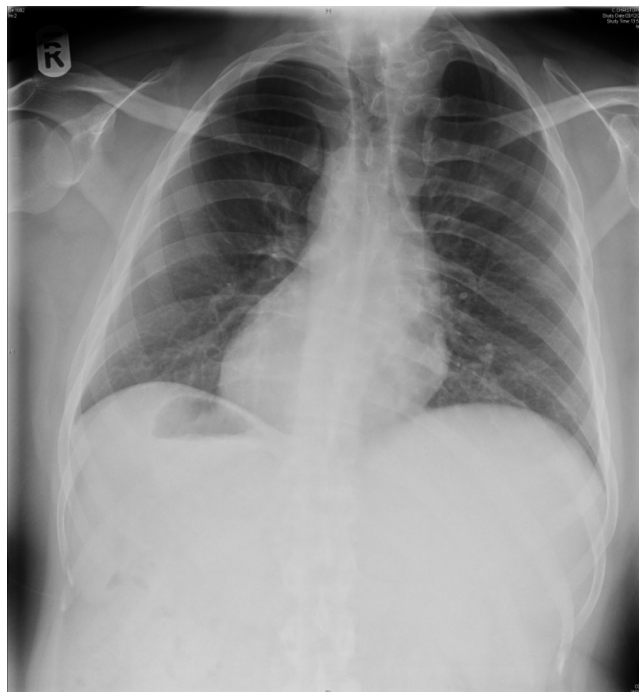


Figure 2: Chest X-Ray showing Situs Inversus in the patient.

Test: US Bladder and Kidneys.

Justification for test: Urinary urgency and frequency was one of the presenting complaints.

Result: Kidneys appeared normal in both size and shape. No stones or hydronephrotic changes seen.

Residual volume of the rest urine is ca. 157mls.

Conclusion: Source of pathology is not of nephrotic or genitourinary origin.

Therapy:

Drugs:

Drug	Dosage	Frequency	Type	Reason
Paracetamol	1g	QDS	Analgesic & Antipyretic	To treat pyrexia
Enoxaparin (Clexane)	20mg	DLY	Anticoagulant (LMW Heparin)	To prevent formation of blood clots post-op
Rocephin (Ceftriaxone)	2mg	DLY	3rd generation Cephalosporin antibiotic	Wide-spectrum activity against Gram negative and Gram positive bacteria
Metoclopramide (Maxolon)	10mg	TDS	Antiemetic	To treat or prevent nausea and vomiting
Pethidine	75mg	QDS	Opioid analgesic	To diminish pain
Codeine	30mg	TDS	Opiate	To treat mild/moderate pain and/ or IBS
Xylometazoline (Otrivin)	2 drops	TDS	Decongestant	Used as a topical nasal decongestant
Oxybutynin (Ditropan)	2.5mg	TDS	Anti-cholinergic	Relieves his urinary frequency and urgency

Surgical therapy:

Pre-operative: The patient was admitted on 3rd December 2012 and prepared for the operation to take place the following day on the 4th of December. The pre-op plan consisted of taking a cross-match and an ECG, undergoing an ENT review, consent form signed, to take CXR and blood samples for the following tests:

- Thyroid Function Test
- Full Blood Count
- Renal Profile (serum)
- Erythrocyte Sedimentation Rate
- Lipid Profile (Serum)
- Calcium and Phosphate (Serum)
- Glucose – Random (Plasma)
- C-Reactive Protein (Serum)
- Liver Profile (Serum)
- Estimated GFR
- Urine Mid Stream Specimen for MCS
- Urinalysis
- Nose and Throat Swab for MRSA
- Coagulation Screen
- Blood type and Screen
- Antibody Screen

Operation: Patient is in a prone position on frame with head fixed in a Mayfield. 2gm ceftriaxone were

given I.V. pre-operatively. Following disinfection of the skin with alcoholic betadine and subsequently with alcoholic solution, the skin was marked and infiltrated with xylocaine 2% with adrenaline. A 12cm incision extending caudally from the external occipital protuberance was made. The scalp was elevated off the periosteum. Subcutaneous tissue and paraspinal muscles were dissected off the first 2 spinous processes. 3 burr holes were created using a craniotome. Double-action and Kerrison's upcut were used to extend the burrholes into a posterior fossa craniectomy (about 7x5cm) and a laminectomy of the first 2 vertebrae. The dura was marsupialised to expose cerebellum and tonsils thus relieving any pressure. Dura was sutured to fascia and Spongistan was applied over the cerebellum.

The wound was closed in layers (Vicryl 1/0 to muscle and fascia and dermal Vicryl 2/0 and Monocryl 3/0 to subcutis).

Post-operative: The patient returned back to the ward at 4pm, conscious but drowsy. He was moving all 4 limbs without difficulty and both hand grips were present and equal. I.V.I was in progress, administering N/Saline alternating 2x5% Dextrose 500cc 6-hourly. Catheter in-situ draining well into bag. PCA pump was in progress as well with the treatment being given as prescribed. Neurological and vital signs were checked and charted as per post-op regime.

The patient had a good first night's sleep post-operatively. Neurologically stable, oriented, moving all limbs well and his grip was present in upper limbs too. All the neurological signs and parameters were checked and charted and treatment continued as per chart. Sips were started and well-tolerated.

Post-operative, the patient developed recurrent spikes of fever. Three sets of blood cultures showed no growth and the fever subsided. The patient was passing large volumes of urine post-op as well. He was seen by Mr. K German who started him on Ditropol 2.5mg tds. He will be reviewed in two months' time from the urology point of view.

Diagnosis:

Syringomyelia refers to a fluid-filled cavity within the spinal cord. In this patient, the syrinx was a result of Arnold-Chiari malformation, meaning that the cerebellar tonsils herniate through the foramen magnum into the cervical spinal canal and cause the disruption of CSF flow; resulting in the formation of a syrinx. Infantile hydrocephalus is sometimes also associated with the Chiari malformations, as well as Spina Bifida². The onset of Chiari syndrome symptoms usually occur in the second or third decade, as exemplified in this patient during his adolescence¹.

There is high clinical variability among patients, ranging from asymptomatic patients to patients with severe neurological deficits¹. The pain the patient experienced in his right arm can be merited to syringomyelia, since such patients often suffer from upper limb pain exacerbated by exertion or coughing, together with spastic lower limb partial paralysis. Cerebellar lesions as a result of Chiari malformations were clinically demonstrated as nystagmus². Urine frequency and urgency were the result of compression of the cervical spinal cord by the syrinx³.

The diagnosis of Chiari malformation in patients with or without symptoms is established with neuro-imaging techniques, preferably with Magnetic Resonance Imaging (MRI). The most effective therapy is surgical decompression of the foramen magnum. Other methods include non-surgical therapy, used to relieve the symptoms caused by neuropathic pain. Next, rehabilitation therapy is commonly prescribed, including medical, such as the use of analgesics or anti-inflammatory agents to reduce the pain and occupational therapy, to continue relieving the pain and optimise articular movements in order to continue improving the patient's quality of life and work activities¹.

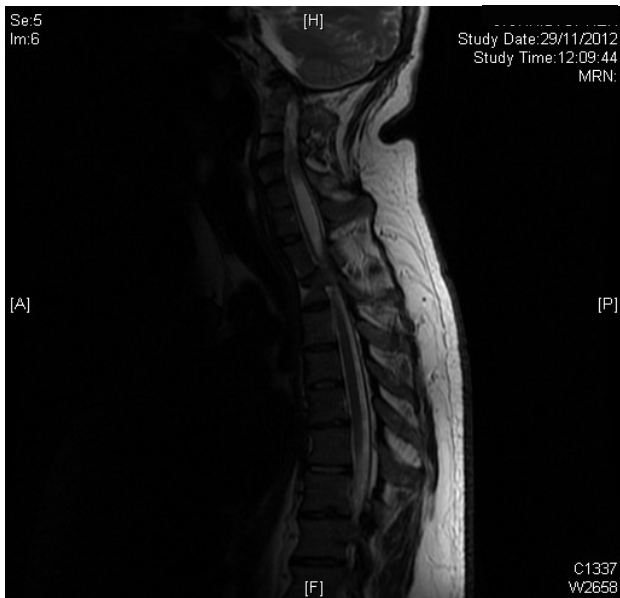

Figure 3: MRI scan showing the syrinx within the cervical spinal canal and vertebral fusion

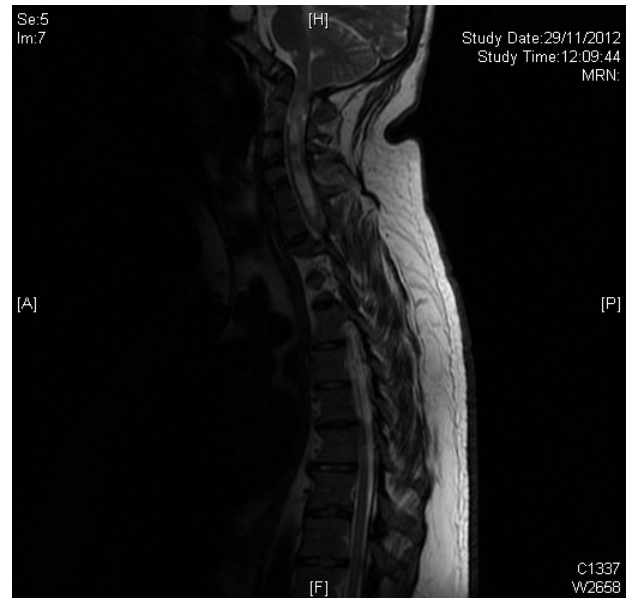

Figure 4: MRI scan showing the syrinx within the cervical spinal canal and vertebral fusion

Final treatment and follow ups:

He was discharged home on 19th December 2012 and will be reviewed at Surgical Out-Patients (SOP) in four weeks' time.

Treatment on Discharge:

Drug	Dosage	Frequency	Type	Period
Oxybutynin (Ditropan)	2.5mg	TDS	anticholinergic	Indefinite
Alfuzosin HCl (Xatral SR)	5mg	BD	α 1- Receptor antagonist	Indefinite

Fact Box 9:

Title: Syringomyelia (Syrinx)

Short description of condition: Syringomyelia refers to the formation of a cyst in the spinal cord which progressively expands and elongates destroying nerve fibers which conduct information from the brain to the extremities as it does so.

Symptoms and signs:

- Progressive weakness in the arms and legs
- Back stiffness as well as stiffness in the shoulders arms or legs and chronic severe pain
- ‘Cape sign’ which is a loss of sensation that spreads over the shoulders and back is evident in some but not all patients

Symptoms may also include:

- Headache and a loss of ability to feel extremes of hot and cold most notably in the hands,
- Difficulty articulating words
- Dizziness
- Hoarseness
- Impaired unilateral or bilateral sensation in the face
- Rapid involuntary rolling of the eyeballs
- Loss of or deficiency in the power to use or understand language
- Loss of bladder and bowel function may also occur

Symptoms vary amongst individuals depending on the location and size of the syrinx.

Causes and Risk Factors:

- Abnormalities of the spine or skull base that are present from birth account for up to 50% of cases.
- Expansion of the syrinx during teen and young adult years is observed for unknown reasons.
- Syrinx may also develop with tumors or after a spinal injury.

Prevention: There is no way of predicting who will develop syringomyelia, however, certain injuries and infections are known to contribute to the condition. Avoiding such injuries and infections may prevent syringomyelia from developing. Rather than preventing the development of the disease, prevention of disease complications such as irreversible damage to the spinal cord and life-long neurological sequelae is more effective. In this case report, the surgeon opted for a craniotomy in an attempt to avoid further neurological deficit by the syrinx.

References:

1. Fernandez A.A., Guerrero A.I., Martinez M.I., Vazquez M.E.A., Fernandez J.B., Octavio E.C., Labrado J.D.C., Silva M.E., Fernandez de Araoz M.F., Garcia-Ramos R., Ribes M.G., Gomez C., Valdivia J.I., Valbuena R.N. and Ramon, J.R. (2009). Malformations of the craniocervical junction (chiari type I and syringomyelia: classification, diagnosis and treatment). BMC Musculoskelet Disord 10 (Suppl 1), S1.
2. Parveen Kumar, Michael Klark. Kumar and Clark’s Clinical Medicine, 2012; 22: 1137.
3. Robert J. Schwartzman. Differential Diagnosis in Neurology, 2006; 6: 209.