

## **Case Number 6**

### **Pancreatic Ductal Adenocarcinoma**

*Daniel Debattista & Sarah Bezzina*

*Reviewed by: Mr N. Spiteri & Mr A. Attard*

#### **Case summary:**

##### *Demographic details:*

Mr. SS, male, Tarxien

Referred from: Polyclinic

A 61-year-old gentleman who lives with his wife and 20-year-old son, presented to the polyclinic with a four week history of pruritus. On examination he was found to be jaundiced and his LFTs were high. Consequently he was referred to Mater Dei Hospital where, following ERCP and MRCP, he was found to have a tumour of the head of the pancreas, causing a stricture of the common bile duct, with consequent obstructive jaundice. The patient was planned for Whipple's operation (pancreatico-duodenectomy), which was extended to total pancreatectomy, splenectomy and cholecystectomy. The operation was successful and the patient is recovering.

#### **Presenting complaint:**

Pruritus: 4 weeks

#### **History of presenting complaint:**

The patient reported generalised itching for four weeks. The itching woke him up at night and disturbed his sleep. The patient was jaundiced and reported passing dark urine and pale stools which were difficult to flush. Recent weight loss and decreased appetite were also reported. The patient denied any back pain or abdominal pain. Moreover, he did not experience any chills or rigors. He reported reflux and dyspepsia following a meal. He did not complain of any nausea, vomiting or haematemesis.

#### **Past medical and surgical history:**

##### *Past medical history:*

- Hypertension
- No history of diabetes, ischaemic heart disease, asthma, chronic heart failure or epilepsy.
- No previous history of jaundice.

#### **Drug history:<sup>1</sup>**

<b>Drug</b>	<b>Dosage</b>	<b>Frequency</b>	<b>Type</b>	<b>Reason</b>
Amlodipine	5mg PO	Dly	Calcium Channel Blocker	Hypertension
Enalapril	20mg PO	Dly	ACE-Inhibitor	Hypertension
Burinex	2mg PO	Dly	Loop Diuretic	Hypertension

## **Family history:**

Father died of a myocardial infarction at the age of 66.

Mother died of pulmonary embolism.

Siblings and children do not suffer from any medical condition.

No family history of cancer.

## **Social history:**

The patient is a married pensioner, father of three, who lives with his wife and youngest son. He used to do clerical work. He is a non-smoker and drinks socially. He does not abuse of drugs.

## **Systemic inquiry:**

- General Health: looks well in general; reported recent weight loss and decreased appetite
- Cardiovascular System: nil to note
- Respiratory System: nil to note
- Gastrointestinal System: GORD and bloating after a meal; pale stools which are difficult to flush
- Genitourinary System: dark urine (though occasionally it is clear)
- Central Nervous System: nil to note
- Musculoskeletal System: nil to note
- Endocrine System: nil to note

## **Pre-operative therapy:**

- Vitamin K supplements (10mg/Dly, IV) were given in view of the fact that the coagulation cascade may be deficient in such patients<sup>1</sup>.
- Prophylactic Clexane® (enoxaparin) therapy was given pre-operatively in view of increased risk of deep vein thrombosis in patients undergoing surgery<sup>1</sup>.
- Phenergan® (promethazine hydrochloride) was given for symptomatic treatment of pruritus<sup>1</sup>.

## **Discussion of results of general and specific examinations:**

<b>Feature</b>	<b>Discussion</b>
Jaundice, pruritus, pale stools and dark urine	Indicative of an obstructive lesion in the biliary tree. The conjugated hyperbilirubinaemia causes the itchiness in the skin and yellow discolouration in the skin and sclera. Since no bile is secreted from the common bile duct, the stools are pale. Conjugated hyperbilirubinaemia is water soluble and thus is excreted in greater amounts in the urine, turning it dark.
Steatorrhoea	Indicates that lipid absorption is impaired because of an obstruction to the biliary tree, thus inhibiting pancreatic enzymes (including lipase) from being secreted into the small intestine. Lipids are not digested and are passed with the stool, making it difficult to flush.
Weight loss and anorexia	May indicate a chronic illness such as a tumour.
No abdominal pain	Shows that the condition is unlikely to be inflammatory.
Soft abdomen	Excludes peritonitis.
No chills or rigors	Absence of pyrexia makes infective cause unlikely.

## **Differential diagnosis:**<sup>3,4</sup>

Differential diagnosis is from other causes of painless obstructive jaundice<sup>3</sup>, such as:

<b>Differential Diagnosis</b>	<b>Features</b>
Tumour of the head of pancreas, periampullary malignant tumours	Biliary ducts appear dilated on ultrasound. This is characterised by painless jaundice, weight loss, and obstruction within head of pancreas, which is confirmed via ERCP and MRCP.
Common bile duct stones	Characterised by tenderness in the right upper quadrant, and dilatation of biliary ducts on ultrasound. However, abdominal pain may be absent.
Benign strictures of the common bile duct	May be due to surgical damage or inflammation caused by a previous stone. Obstructive features are similar to carcinoma of the head of pancreas.
Intrahepatic cholestasis	Mainly caused by viral hepatitis. Low grade jaundice is due to systemic sepsis.
Primary biliary cirrhosis	Hepatomegaly and possible splenomegaly, xanthomas and arthralgia. This disease is characterised by a positive test for anti-mitochondrial antibody and serum IgM. Cirrhosis is confirmed via liver biopsy.
Drugs, such as phenothiazines, anabolic steroids and erythromycin	Discontinuing such drugs will relieve symptoms of obstructive jaundice.
Alcoholic hepatitis	A history of excessive alcohol intake is needed. Presents with features of chronic liver disease, such as spider naevi.
Sclerosing cholangitis	Presence of beading in intra- and extra-hepatic bile ducts on ERCP
Dubin-Johnson syndrome	Characterised by decreased excretion of conjugated bilirubin, intermittent jaundice and pain in the right hypochondrium. Increased urinary bilirubin and pigment granules on liver biopsy.

## **Diagnostic procedures:**

### *Instrumental exams:*

Test: Ultrasound Abdomen (Figure 1)

Justification for test: Patient with pruritus and abnormal LFTs; suspecting stone in biliary tree

Result: Dilated biliary tree and pancreatic duct

Conclusion: Further investigation recommended – referred for CT scan

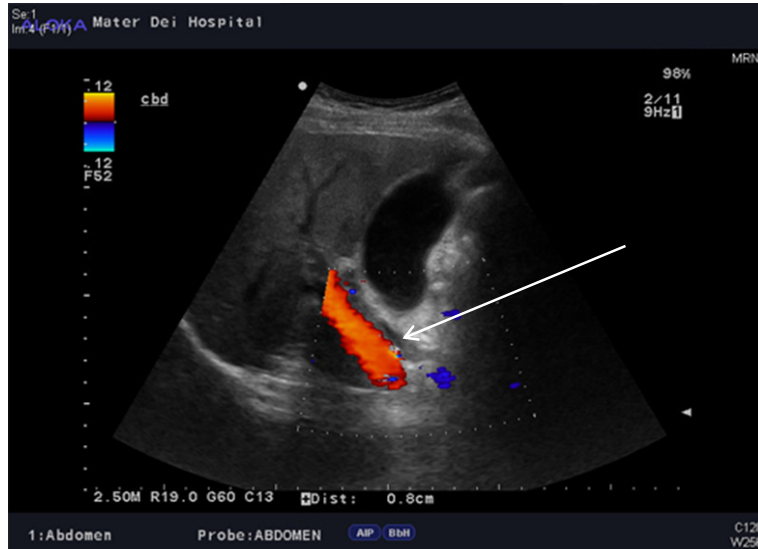


Figure 1: Ultrasound Image, showing the dilated (0.8cm) common bile duct (arrow)

Test: CT Abdomen (Figure 2)

Justification for test: Patient with painless jaundice and dark urine; post ultrasound abdomen findings, suspecting gall stone

Result: Pancreatic duct dilatation and evidence of distal biliary obstruction; no calculi or significant mass lesion

Conclusion: Suspecting vater papilla process and ampullary tumour; ERCP recommended

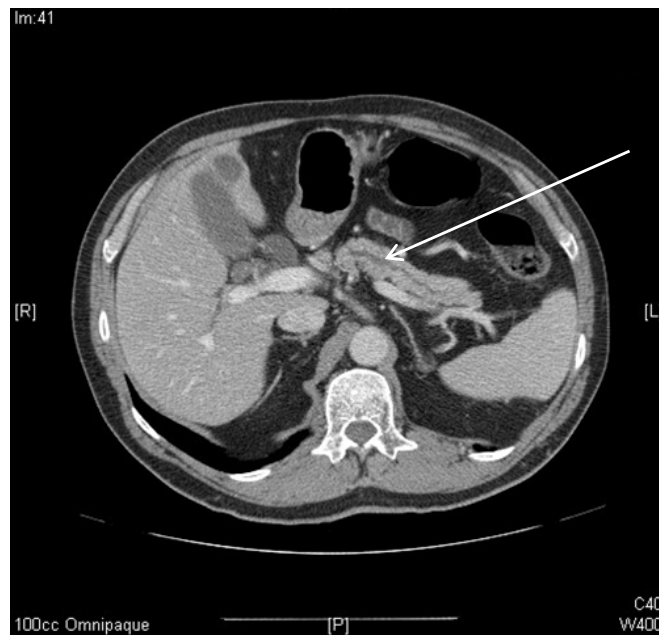


Figure 2: Preoperative CT Abdomen - showing the dilated pancreatic duct (arrow)

Test: ERCP (Endoscopic Retrograde Cholangiopancreatography) (Figure 3)

Justification for test: To rule out pancreatic head pathology

Result: Ampulla appeared flat and normal; suspected common bile duct stricture

Conclusion: Result inconclusive – patient referred for MRCP

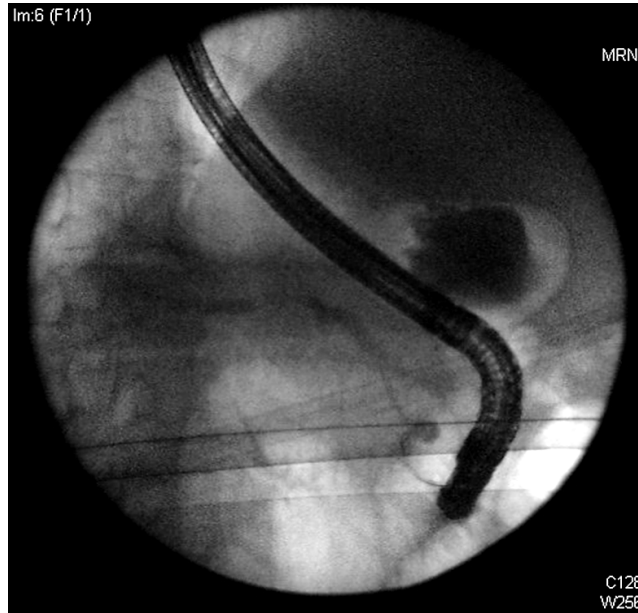


Figure 3: ERCP, showing the biliary tree

Test: MRCP (Magnetic Resonance Cholangiopancreatography) (Figure 4)

Justification for test: Confirm ERCP findings

Result: Common bile duct stricture, noted to be possibly malignant

Conclusion: Suspicion of obstruction of the common bile duct within the head of pancreas confirmed.  
Surgery needed to resect pancreatic head pathology

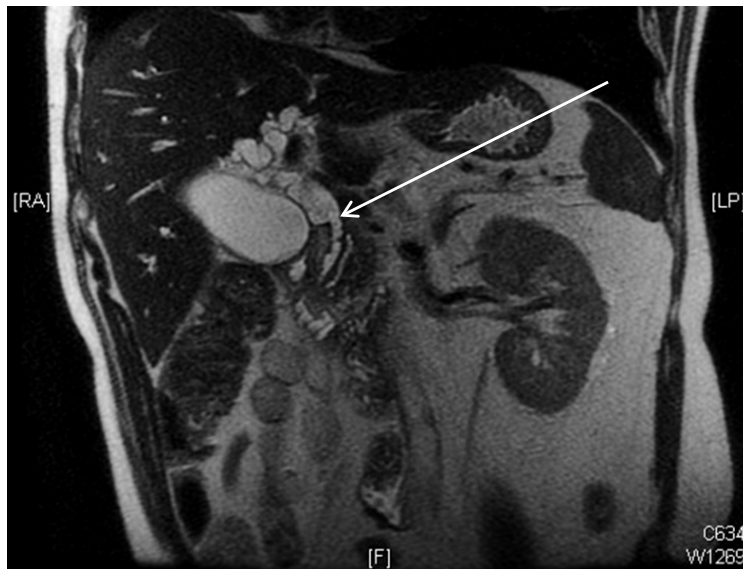

Figure 4: MRCP showing stricture at common bile duct (arrow), with proximal dilatation

**Therapy:**

Drugs:<sup>1</sup>

Drug	Dosage	Frequency	Type	Reason
Promethazine Hydrochloride (Phenergan®)	50mg PO	TDS	Antihistamine	Symptomatic relief treatment of pruritus
Bumetanide	1mg PO	Dly	Loop Diuretic	Hypertension

Enalapril	20mg PO	Dly	ACE-Inhibitor	Hypertension
Amlodipine	5mg PO	Dly	Calcium Channel Blocker	Hypertension
Vitamin K	10mg IV	Dly	Vitamin supplements	Aids the clotting cascade as this may be deficient in such patients
Enoxaparin Sodium (Clexane®)	40mg SC	Dly	Parenteral anticoagulant	Prophylaxis of deep-vein thrombosis in surgical patients
Actrapid	Continuous Infusion according to blood glucose level	Continuous Infusion according to blood glucose level	Soluble Insulin	Insulin deficiency due to pancreatectomy
Cefuroxime (Zinacef®)	750mg IV	TDS	Cephalosporin	Prophylaxis post-splenectomy and post-laparotomy
Metronidazole	500mg IV	TDS	Antimicrobial	Post distal gastrectomy and roux-en-Y anastomosis
Paracetamol	1g PO	6hrly	Analgesic	Pain Relief
Octreotide	25mcg infusion	Hrly	Somatostatic analogue	Prevent complications of pancreatic surgery

Surgical therapy:

Pre-operative: Admitted two days early due to episode of vomiting. Was given IVI N saline and 10cc 20% KCl 1L 8-hourly, in order to compensate for fluid loss and low sodium concentration in the blood. In addition, promethazine hydrochloride was given. All hypertensive drugs were continued, except for burinex. On the day prior to surgery, the patient started fasting, BP was monitored and bloods were sent for crossmatch.

Operation: A total pancreatectomy, duodenectomy, splenectomy, cholecystectomy, distal gastrectomy and roux-en-Y anastomosis were performed. On operating, a tumour of the head of pancreas was identified. There was no evidence of metastasis.

The duodenum was mobilised and the common bile duct, the common hepatic duct and the portal vein were dissected. An enlarged lymph node was found at the porta hepatis and sent to frozen section. Fortunately this was found to be benign. The gall bladder was dissected fundus first and the cystic artery was divided using sutures.

The neck of the pancreas was dissected off the portal vein and divided. The common bile duct was divided and the biliary stent removed. The duodeno-jejunal flexure was mobilised and divided. The head of pancreas was removed together with the duodenum, gall bladder and distal third of the stomach.

Completion of pancreatectomy and splenectomy were performed. Roux-en-Y anastomosis was performed using a loop of jejunum. Choledochojejunostomy (anastomosis between common bile duct and jejunum) was performed using stapling device. Jejuno-jejunostomy was performed using side to side anastomosis with stapling device. Mesenteric defects were then closed, a drain was inserted and the wound was closed.



The following specimens were sent to histology:

- Head of pancreas and distal stomach
- Distal pancreas and spleen
- Gall bladder

**Post-operation:** The patient was transferred to ITU and was administered the drug treatment listed in the table above. IVI and analgesia were given as required. In view of total pancreatectomy, the patient was to be given continuous actrapid infusion even if glucose levels were to be normal initially. Vaccines were planned post-splenectomy – these include prophylactic immunisation with pneumococcal, meningococcal and H. influenza type B vaccines<sup>2</sup>. In addition, cefuroxime (prophylaxis active against haemophilus influenzae) was given post-splenectomy. Metronidazole (effective Helicobacter pylori eradication) was given in view of partial gastrectomy and roux-en-Y anastomosis.

**Laboratory findings postoperatively:**

- A frozen section taken from a possible metastatic lesion was found to be benign.
- Mild fibrous cholecystitis was found at the fundus of the gall bladder.
- No evidence of tumour infiltration at the pancreatic tail.
- Spleen and splenic hilum were found to be normal.
- A well differentiated invasive pancreatic ductal carcinoma was found at the head of pancreas and encroaching the ampulla. The invasive tumour was associated with widespread pancreatic intraepithelial neoplasia and intraductal carcinoma. Extensive perineural and lymphovascular invasion was found. Foci of intraductal carcinoma extend to less than 1mm from both the superior mesenteric vessel margin and the posterior margin. The anterior margin is clear of tumour.
- Three out of eleven regional pancreatic lymph nodes show metastatic adenocarcinoma. Two greater curve lymph nodes were sampled and were found to be free of tumour. A single focus of malignant cells was found at the perineurium of a large nerve.

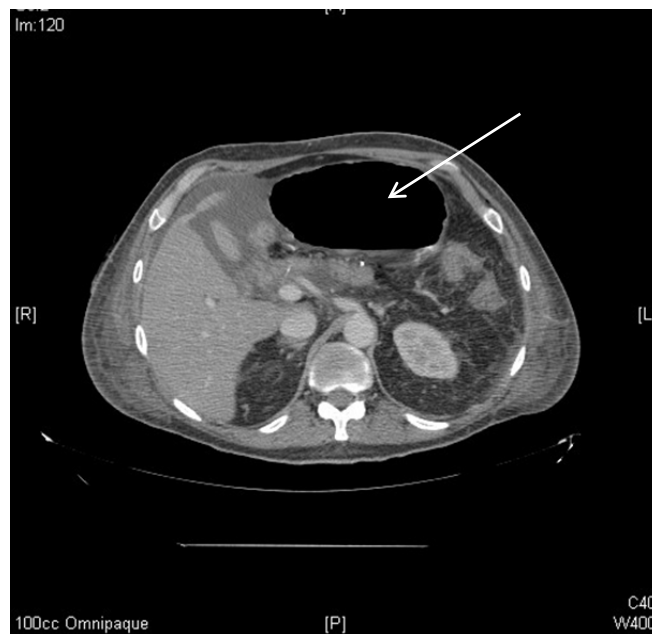

Figure 5: Post op CT Abdomen, showing extensive ascites in the subhepatic region (arrow)

**Diagnosis:**

Based on laboratory findings from specimen of excised organs, the following diagnosis was elicited: Grade 1 pancreatic ductal adenocarcinoma. The tumour at the pancreatic duct traversing the head of

pancreas resulted in compression of the common bile duct, with consequent features of obstructive jaundice. Pancreatic cancer is renowned for its rapid progression and poor prognosis. Often treatment is palliative due to extensive metastasis. However, in rare cases such as this one, early presentation with the lesion confined to the head of the pancreas, curative surgical resection is possible.

### **Final treatment and follow ups:**

In the days that followed the operation, the patient passed altered blood PR (malaena), experienced nausea and brought up coffee ground vomit. These were managed by administering omeprazole (proton pump inhibitor) and ranitidine (H2-receptor blocker); and antiemetic therapy - metoclopramide hydrochloride (maxolon®). In addition, an OGD was performed, with findings of slight erythema, without active bleeding in the body of the stomach and normal post-operative appearance of the gastro-jejunostomy, without any signs of bleeding.

A diabetologist was consulted in order to manage the insulin regimen.

A CT scan of the thorax, abdomen and pelvis was performed 9 days post-operatively in order to investigate confusion post-total pancreatectomy. Findings included extensive bilateral pleural effusion, atelectatic changes in the lower lobes of the lungs and extensive ascites, mainly in the subhepatic region (Figure 5). However, no lymphadenopathy was noted and the liver was homogenous in structure.

Furthermore, a CT scan of the brain was carried out, in which no focal lesions were found and midline structures were not displaced.



## **Fact Box 6:**

*Title:* Pancreatic Ductal Adenocarcinoma

Pancreatic ductal adenocarcinoma is a highly malignant tumour which arises from the cells lining the pancreatic duct. It is the fifth commonest tumour worldwide. It has a high mortality and is often diagnosed late.

*Risk factors:*

- Family history of tumour
- Smoking

*Signs and Symptoms:*

- Jaundice
- Dull epigastric pain which may radiate to the back
- Itching
- Recent onset diabetes
- Thrombophlebitis
- Migraines
- Anorexia
- Weight loss

*Treatment:* In most cases this is palliative, either via a surgical bypass or insertion of a stent through the common bile duct. A curable surgical resection involves Whipple's pancreaticoduodenectomy.

*Prognosis:* Poor, most cases are not operable. In the case of those which are operable, surgery is associated with a high mortality and few survive for more than 5 years.

### **References:**

1. Joint Formulary Committee (2012). British National Formulary. 64th edition. London: British Medical Association and Royal Pharmaceutical Society of Great Britain.
2. Ellis H, Calne RY, Watson CJE (2011). General Surgery Lecture Notes. 12th edition. West Sussex: Wiley-Blackwell.
3. Llewelyn H, Ang HA, Lewis K, Al-Abdullah A (2011). Oxford Handbook of Clinical Diagnosis. 2nd edition. New York: Oxford University Press.
4. Burkitt HG, Quick CRG, Reed JB (2009). Essential Surgery Problems, Diagnosis & Management. 4th edition. Churchill Livingstone Elsevier.