

## **Case Number 10**

### **Hirschsprung's Disease**

*Sarah Ellul & Kay Vanhear*

*Reviewed by: Prof. Simon Attard Montalto*

#### **Case summary:**

##### Demographic details:

Mr. ST, male, B'Kara

Admitted to NPICU from Obstetric Ward, 48 hours after delivery.

A 28-year-old, primigravida woman, gave birth to a boy at 40 gestational weeks. On delivery, the baby was found to have blood stained liquor. This was followed by non-bilious vomiting after feeds and a distended abdomen. He was transferred to NPICU at 36 hours of age due to persistent vomiting and failure to open his bowels.

An initial diagnosis of septic shock necessitated the following management plan: nurse in an incubator, establish intravenous access and perform a septic screen. Nevertheless, at 50 hours of age, persistent bilious vomiting and abdominal distension persisted.

An upper GI contrast study excluded a malrotation. Hirschsprung's Disease was then suspected and confirmed on punch rectal biopsies. A surgical operation was carried out, which included a mapping laparotomy and a colostomy. Three days after the operation was performed, he developed wound dehiscence and required re-repair in theatre. The small and large intestine were cleaned and replaced in the abdomen and the stoma site secured. Swabs taken from the wound grew *Enterococcus faecalis* and *Pseudomonas aeruginosa*.

#### **Presenting complaint:**

Persistent non-bilious vomiting after feeds: within the first 48 hours after delivery

No bowel opening: within the first 48 hours of delivery

Distended abdomen: within the first 48 hours of delivery

Vomiting altered to bilious vomiting: 2 days later once transferred to NPICU

#### **History of presenting complaint:**

A 28-year-old primigravida woman had a normal uncomplicated pregnancy, where no medications or drugs were needed. On abdominal examination, the foetus had a cephalic presentation. After 40 weeks of gestation, there was a spontaneous rupture of membranes and a baby boy was born via normal vaginal delivery. He weighed 3.7kg and was not noted to have any dysmorphic features. The placenta seemed normal.

No meconium was passed in the first 48 hours after birth and the newborn started to pass non-bilious, non-bloody vomitus soon after birth. Due to the persistent vomiting, he was transferred to NPICU, but both the vomiting and abdominal distension persisted at 50 hours from birth.

#### **Past medical and surgical history:**

Nil to note

## **Drug history:**

The drugs listed below were administered to the mother during labour:

<b>Drug</b>	<b>Dosage</b>	<b>Frequency</b>	<b>Type</b>	<b>Reason</b>
Nitrous oxide + Oxygen (Entonox)		TDS	Analgesic	Pain relief during contractions
Pethidine	25mg/ml	once	Analgesic	Pain relief during contractions
Metoclopramide Hydrochloride (Maxalon)	10mg	TDS	Antiemetic	To decrease symptoms of nausea and vomiting

## **Family history:**

No relevant family history from either maternal or paternal side.

## **Social history:**

The mother was a 28-year-old and did not smoke or drink.

## **Systemic inquiry:**

- General Health: persisting bilious vomiting with peri-umbilical erythema and a distended abdomen.
- Cardiovascular System: nil to note.
- Respiratory System: tachypnoeic (60 breaths per minute).
- Gastrointestinal System: persisting bilious vomiting, distended abdomen, did not pass meconium in the first 48 hours.
- Genitourinary System: nil to note.
- Central Nervous System: normal.
- Musculoskeletal System: nil to note.
- Endocrine System: nil to note.

## **Initial Management:**

Closed incubator care: The infant needed close observation because of an increased risk of abnormal heat loss. He was also at risk to develop sepsis, and close monitoring with further tests needed to be done so as to exclude this possibility.

Given intravenous fluids (120ml/kg/day): As the infant had been persistently vomiting, he needed continuous monitoring and adequate hydration so as to prevent dehydration and electrolyte imbalance.

Nil orally: Total parental nutrition was administered as the infant was not getting any form of oral nutrition since there was a strong indication that part of his digestive system was not functioning.

Given antibiotics: amoxicillin and clavulanic acid (Augmentin) and ciprofloxacin hydrochloride (Cifran) as prophylaxis against infection.

Frequent surgical review (to monitor progress).

Cross-matched blood prepared in reserve.

## **Discussion of results of general and specific examinations:**

On general examination, he was found to be tachypnoeic with a capillary refill time of 2-3 seconds. He was found to have a normal positive tone and movement of his upper and lower limbs. His fontanelles were soft. His anus was patent.

On abdominal examination, the infant was found to be slightly jaundiced and had a distended abdomen. He also had an erythematous rash peri-umbilically.

The main presenting feature of concern was the delayed passage of meconium in the newborn period and bilious vomiting, both potentially indicative of intestinal obstruction due to (very uncommon at this age), atresia, malrotation and a strangulated inguinal hernia. Assessment and exclusion of dehydration and shock were also important at this stage.

## **Differential diagnosis:**

- Constipation
- Hypothyroidism
- Intestinal obstruction e.g. malrotation, atresia
- Hirschsprung's Disease

## **Diagnostic procedures:**

### Laboratory exams:

Test: Complete Blood Count.

Justification for test: To check for any signs of infection (high white blood cell count) or anaemia (low haemoglobin levels).

Result: Normal.

Conclusion: No underlying blood disorders or signs of infection.

Test: Thyroid Function Tests.

Justification for test: To exclude hypothyroidism.

Result: Normal.

Conclusion: Hypothyroidism was not present.

Test: Urea and Electrolytes.

Justification for test: To check for any electrolyte imbalance and aim for appropriate fluid management.

Result: Normal.

Conclusion: No underlying dehydration.

Test: Clotting Screen.

Justification for test: To ensure that clotting disorders are corrected before surgery.

Result: Normal.

Conclusion: No underlying clotting disorder was present.

Test: Blood Culture and an MRSA swab.

Justification for test: To exclude septicaemia and MRSA.

Result: Negative.

Conclusion: No underlying MRSA infection.

Test: CRP/ESR.

Justification for test: To check for any underlying inflammation from an infection.

Result: Raised.

Conclusion: Possibility of an ongoing inflammatory process.

Test: Septic Screen.

Justification for test: To exclude a bacterial bloodstream infection, meningitis, pneumonia etc.

Result: Normal.

Conclusion: No underlying infection.

Test: Swab from the post-operative wound.

Justification for test: To detect the causative organisms for the wound dehiscence and treat appropriately.

Result: Positive for *Enterococcus faecalis* and *Pseudomonas spp.*

Conclusion: Treat appropriately with antibiotics to cover for these organisms.

Imaging:

Test: Plain Abdominal X-Ray.

Justification for test: Routine test for abdominal distension and its possible causes.

Result: Distended bowel loops.

Conclusion: Abdominal distension was confirmed.

Test: Upper Gastrointestinal Contrast Study.

Justification for test: To exclude malrotation.

Result: Normal.

Conclusion: Malrotation was not present.

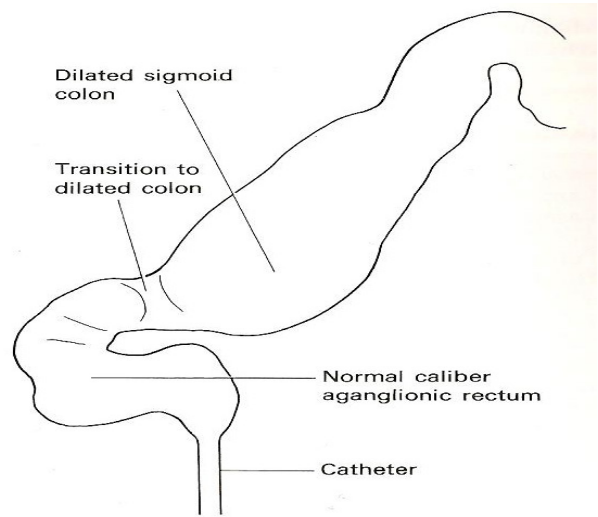
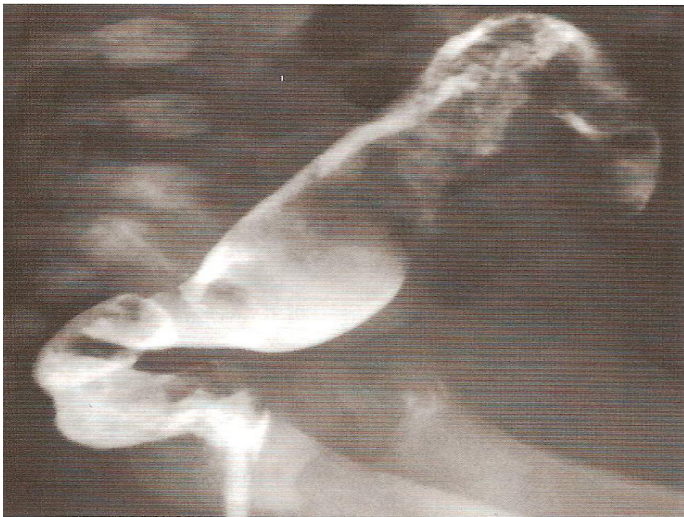

Figure 1. Hirschsprung's Disease on barium enema. Note the transition between the normal caliber aganglionic rectum and the dilated sigmoid colon<sup>1</sup>.

Test: Rectal Biopsy.

Result: Ganglionic Cells were found in the transverse and in the Sigmoid Colon but an aganglionic segment was noted distally, starting from the rectum.

Conclusion: Hirschsprung's Disease.

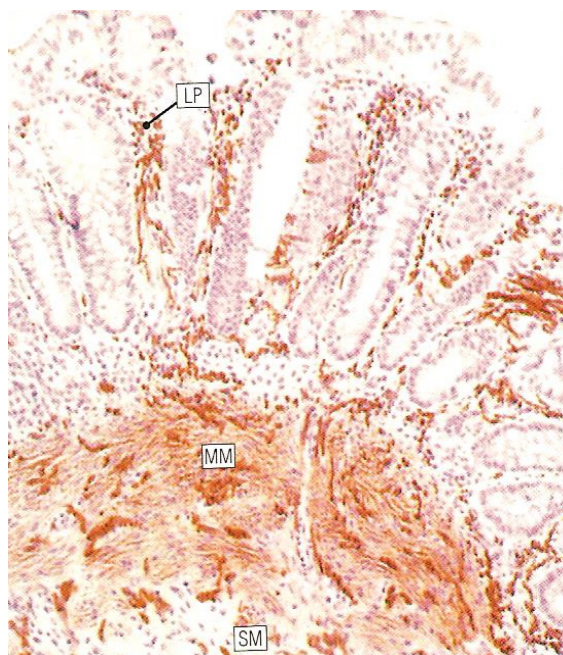


Figure 2. Hirschsprung's Disease. Rectal Biopsy. Micrograph showing prominent nerve twigs in the lamina propria (LP), muscularis mucosae (MM) and submucosa (SM)<sup>2</sup>.

## **Therapy:**

### Drugs:

Drug	Dosage	Frequency	Type	Reason
Meropenem	10mg/kg	8 hourly	I.V.	Broad-spectrum antibiotic to cover gram-positive and gram-negative (including <i>Pseudomonas</i> ) organisms
Teicoplanin	10mg/kg/12hours	Daily	I.V.	Antibiotic which covers gram-positive organisms such as MRSA and <i>Enterococcus faecalis</i>
Ranitidine	1-2mg/kg/dose	2-3 times daily	Suspension	To prevent gastro-oesophageal reflux and erosive oesophagitis
Morphine	0.05mg/kg	Every 4-8 hours	I.V.	Pain relief
Amoxicillin and clavulanic acid (Augmentin)	20mg/5mg/kg/day	Given in 3 doses	Suspension	Prophylactic broad-spectrum antibiotic

### Surgical therapy:

Pre-operatively abdomen was found to be distended but the anus was patent.

Operation: Mapping laparotomy and colostomy.

Post-operatively: Wound dehiscence developed a few days later and the infant was returned to theatre to repair the stoma and clean the bowel whilst reconstructing the wound. The wound layers were closed using individual stitches and not with continuous stitching.



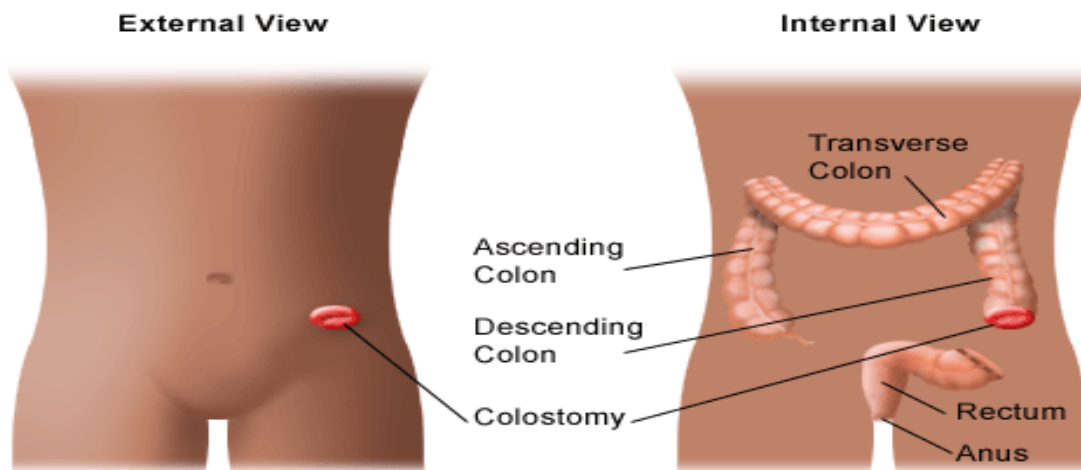
## **Diagnosis:**

The rectal biopsies confirmed that the infant had Hirschsprung's Disease.

On full thickness rectal biopsy, pathophysiology shows absence of both the myenteric (Auerbach) plexus and the submucosal (Meissner) plexus which are responsible in the reduced bowel peristalsis and function<sup>3</sup>.

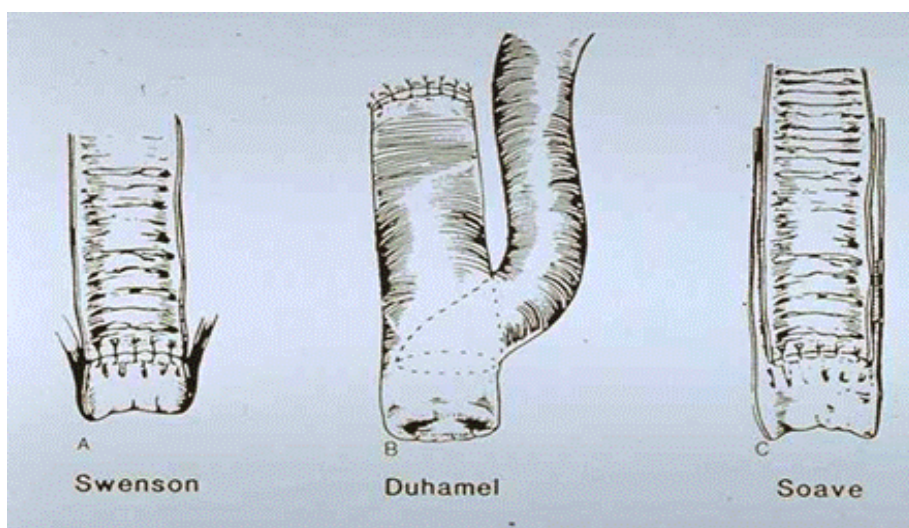
The treatment of this condition is by surgical management. However, initial medical management is needed in order to stabilise the patient before any surgical treatment is undertaken. Medical management includes the correction of any fluid or electrolyte imbalances, antibiotic therapy if enterocolitis is found and rectal decompression using rectal irrigations and tubes till the surgery is undertaken.

The basic aim for the definitive surgical treatment of this disease is the resection of any aganglionic segment, which is followed by a pull-through of any ganglionic bowel down to the anus.



*Figure 3. Bowel resection and colostomy in Hirschsprung's disease<sup>4</sup>*

There are quite a variety of procedures which have been used, but the most commonly used are the following: Swenson pull-through (rectosigmoidectomy), Duhamel pull-through (retrorectal transanal pull-through) and Soave pull-through (endorectal pull-through)<sup>5</sup>.



*Figure 4. Types of surgical procedures for the pull-through of the ganglionic bowel down to the anus in Hirschsprung's disease<sup>6</sup>*

### **Final treatment and follow-up:**

On performing a microscopy and culture of the wound swabs, *Enterococcus faecalis* and *Pseudomonas aeruginosa* were cultivated. Therefore it was advised to stop Augmentin and start the infant on Teicoplanin and Metronidazole.

He was managed nil by mouth, given morphine and started on the above-mentioned antibiotics. He was also put on total parenteral nutrition at 160mls/kg/day at 26ml/hour.

After three days following the operation, he was stabilised although still intubated. All his parameters were noted to be improving and the wound had started to heal.

After six days his condition was significantly better and he was allowed to start feeding, whilst still continuing on the prescribed antibiotics.

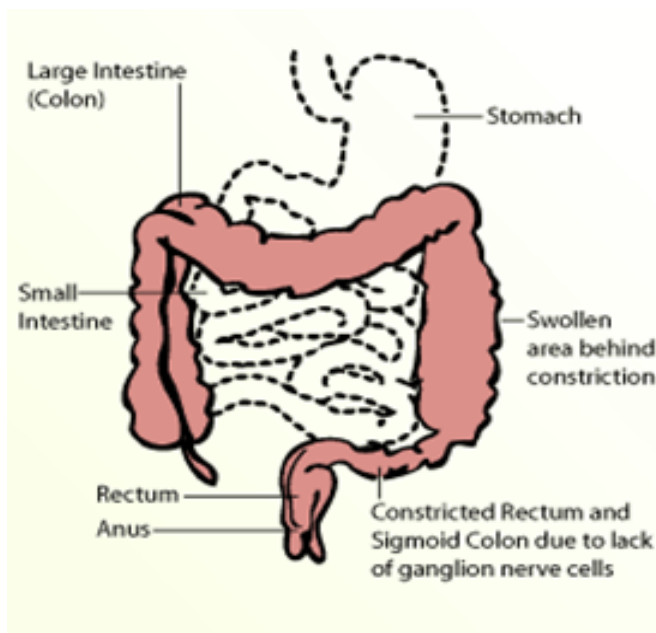
## **Fact Box 10:**

### Title: Hirschsprung's Disease

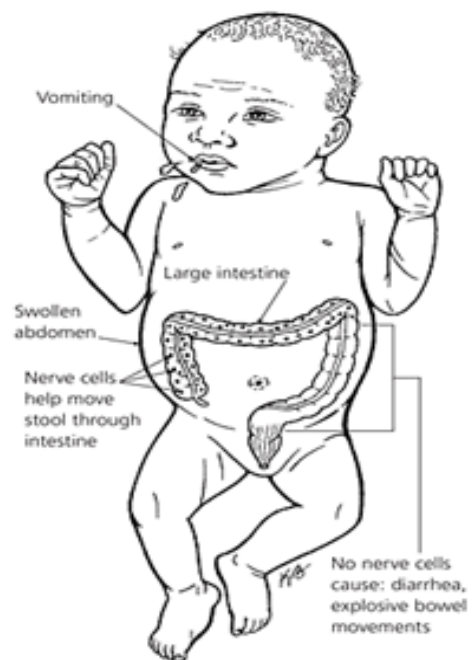
Description: Hirschsprung's disease (HSCR) is a congenital disorder arising in 1 per 5000 newborns worldwide. It is characterised by an absence of enteric ganglia along a variable part of the intestine giving a functional obstruction where the aganglionic zone remains tonically constricted, preventing the passage of faecal material<sup>1</sup>. The HSCR phenotype is highly variable with respect to:

- Gender, with a 4:1 male-to-female incidence ratio.
- Length of agangliosis, where HSCR is subdivided into short-segment (S-HSCR: aganglioneurosis up to the upper sigmoid colon), long-segment (L-HSCR: aganglioneurosis up to the splenic flexure and beyond) and total colonic aganglioneurosis (TCA) forms.
- Familiality
- The presence of additional anomalies, such as Down's syndrome, multiple endocrine neoplasia type II, neurocristopathy syndromes and many more<sup>3</sup>.

Currently, research is mainly focused on RET proto-oncogene on 10q11.2. This makes up 50% of familial and 20% of all the sporadic cases regarding this disease. It is especially noted in those patients presenting with long segment disease. This proto-oncogene is linked with multiple endocrine neoplasia, type IIA<sup>4</sup>. Eight genomes are associated with this disorder and Down's syndrome is the most common chromosomal abnormality linked with the Hirschsprung's disease<sup>5</sup>.



*Figure 1: Functional obstruction in Hirschsprung's disease<sup>2</sup>*



*Figure 2: Signs and symptoms in an infant with Hirschsprung's disease<sup>6</sup>*

### Symptoms:

- Inability to pass meconium in the first 24 hours after birth.
- Poor feeding, generally associated with failure to thrive.
- Bilious vomiting.
- Progressive abdominal distension, with significant constipation<sup>5</sup>.



### Signs:

- Anemia
- The abdomen can be distended due to retention of faeces
- Rectal examination will demonstrate tight anal sphincter which is usually followed by an explosive discharge of foul-smelling faeces and gas<sup>5</sup>

The main presenting feature which should raise a red flag for the possibility of Hirschsprung's disease is delayed passage of meconium in any newborn, or a history of chronic constipation in any child since birth. Although a study shows that if the age at onset of constipation is after the neonatal period, a rectal biopsy is unnecessary as the child would be unlikely to have HRSC<sup>7</sup>.

Treatment: The treatment of this condition is by surgical management. However, initial medical management is needed in order to stabilize the patient before any surgical treatment is undertaken.

Medical management includes the correction of any fluid or electrolyte imbalances, antibiotic therapy if enterocolitis is found, and rectal decompression using rectal irrigations and tubes till the surgery is undertaken.

The basic aim for the definitive surgical treatment of this disease is the resection of any aganglionic segment, which is followed by a pull-through of any ganglionic bowel down to the anus.

There are quite a variety of procedures which have been used, but the most commonly used are: Swenson pull-through<sup>5</sup> (rectosigmoidectomy), Duhamel pull-through (retrorectal transanal pullthrough) and Soave pullthrough (endorectal pull-through)<sup>8</sup>.

### References:

#### Case Report:

1. Armstrong P, Wastie M and Rockall A. (2009) Diagnostic Imaging. Sixth Edition. Wiley-Blackwell.
2. Stevens A and Lowe J. (2005) Human Histology. Third Edition. Elsevier Limited.
3. <http://emedicine.medscape.com/article/178493-overview#a0104> – accessed on 15/01/2013
4. <http://www.chop.edu/healthinfo/hirschsprungs-disease.html> - accessed on 15/01/2013
5. S. Nurko, "HIRSCHSPRUNG'S DISEASE," [Online]. <http://www.motilitysociety.org/pdf/Hirschsprung's%20disease%208.28a.2006.pdf>. - accessed on 05/01/2013.
6. <http://www.ptolemy.ca/members/archives/2011/Hirschsprung%20Disease/index.html> - accessed on 15/01/2013.

#### Fact Box:

1. Wallace A S and Anderson R B. Genetic interactions and modifier genes in Hirschsprung's disease. World J Gastroenterol. 2011; 17(45): 4937-4944.
2. <http://pedsurg.ucsf.edu/conditions--procedures/hirschsprung's-disease.aspx> - accessed on 15/01/2013
3. Jiang Q, Ho Y Y, Hao L et al. Copy number variants in candidate genes are genetic modifiers of Hirschsprung's disease. PLoS ONE 2011; 6(6): e21219.
4. Amiel J and Lyonnet S. Hirschsprung disease, associated syndromes, and genetics: a review. J Med Genet 2001; 38: 729-739.
5. Pasumarthy L and Srour J W. Hirschsprung's Disease. Practical Gastroenterology. June 2008; 42-46.
6. <http://www.aafp.org/afp/2006/1015/p1327.html> - accessed on 15/01/2013
7. Ghosh A and Griffiths D M. Rectal biopsy in the investigation of constipation. Arch Dis Child. 1998; 79: 266-268.
8. S Nurko, "HIRSCHSPRUNG'S DISEASE," [Online]. <http://www.motilitysociety.org/pdf/Hirschsprung's%20disease%208.28a.2006.pdf>. - accessed on 05/01/2013.