

## **Case Number 8**

### **Congenital Neuroblastoma**

*Dillon Mintoff & Christine Mizzi*

*Reviewed by: Dr. J. Mizzi MD, MRCP, MRCPC*

#### **Case summary:**

##### Demographic details:

Baby D, female, Swieqi

Baby D is a 3-day-old baby girl who was noted to have abnormal posture and paucity of movement of the left foot. Examination revealed flaccid weakness of the left lower limb. The rest of the neurological examination was normal. MRI revealed an extramedullary extradural intracanalicular lesion extending from caudal to the 10th thoracic vertebral body to L4 and a paraspinal mass from level of L1 to L4 vertebral bodies which was in continuity with the intracanalicular mass through the right L1/L2 neural foramen. This was diagnosed as congenital dumbbell neuroblastoma.

#### **Presenting Complaint:**

Left foot flaccid paralysis and dorsiflexion weakness since birth.

#### **History of Presenting Complaint:**

Baby D is a 3-day-old baby girl. She was born at 38<sup>+2</sup> weeks gestation by normal vaginal delivery. Her birth weight was 3.36kg, which is on the 50th centile. Her weight was appropriate for gestational age. Her parents noted that the baby was not moving her left lower limb. Clinical examination revealed flaccid paralysis of the left lower limb. The rest of the neonatal and neurological examination was normal.

#### **Past medical and surgical history:**

The patient has no previous medical or surgical history.

#### **Drug history:**

Drug	Dosage	Frequency	Type	Reason
Paracetamol	30mg	QID	Analgesic	Pain relief

#### **Family history:**

Mother suffered two miscarriages before giving birth to Baby D.

#### **Systemic inquiry:**

Apart from the left lower limb paralysis, Baby D was completely healthy on neonatal examination.

## **Current therapy:**

Baby D is currently receiving therapy at Great Ormond Street Hospital for Children in London.

## **Discussion of results of general and specific examinations:**

General examination: The patient looked comfortable at rest and did not appear to have any dysmorphic features. The patient weighed 3.10kg. She was noted to be slightly plethoric but not jaundiced. Examination of the cardiovascular system revealed normal heart sounds (S1+S2+0) and a radial pulse rate of 150 beats per minute. The femoral arteries were palpated and there was a normal liver edge. The lungs were clear, with air entry on the left equal to that on the right. Respiratory rate was 40 breaths per minute. The hips were symmetrically abducted. Galiazzi, Barlow and Ortolani tests were negative.

Neurological examination: Upper limbs: Normal tone, power and sensation.

Trunk: Normal tone.

Lower limbs: Right side: normal tone, power and sensation. Left side: flaccid weakness below left knee with foot drop and inversion. The knee jerk was equivocal and the ankle jerk could not be elicited. The left leg seemed to be thinner than the right but had the same length. The anal sphincter was intact. The bladder was not distended and there was no leakage of urine.

## **Differential diagnosis:**

- Birth trauma
- Tumours: Neuroblastoma  
Schwannoma  
Paranglioma  
Ganglioneuroblastoma  
Ganglioneuroma  
Glioblastoma

## **Diagnostic procedures:**

Laboratory exams:

Test: Complete Blood Count

Justification for test: To exclude bone marrow involvement from a possibly malignant lesion

Results: White blood cell count:  $9.10 \times 10^9/L$

Neutrophils:  $7.5 \times 10^9/L$  (High)

Lymphocytes:  $8.49 \times 10^9/L$

Monocytes:  $2.29 \times 10^9/L$  (High)

Eosinophils:  $0.73 \times 10^9/L$

Basophils:  $0.13 \times 10^9/L$  (High)

Red Cell Count:  $5.60 \times 10^9/L$

Haemoglobin: 19.2 g/dL

Haematocrit: 53.6%

Mean Cell Volume: 95.5 fL

Mean Cell Hb: 34.2 pg (High)

Mean Cell Hb concentration: 35.8 g/dL

Red Cell distribution Width: 17.9% (High)

Platelets:  $233 \times 10^9/L$

Mean Platelet volume: 9.2 fL

Reticulocytes: 208.10 x 10<sup>9</sup>/L (Low)

Serum Urea: 8 mmol/L

Serum Creatinine: 79 mmol/L

Serum Sodium: 145 mmol/L

Serum Potassium: 5.45 mmol/L (High)

Serum Chloride: 105.5 mmol/L

Serum Bilirubin: 193.00 umol/L

Conclusion: The blood results were normal overall, with the slight abnormalities being insignificant. Other laboratory tests which could have been included, given this case in particular, are LFTs to show any involvement of the liver in case of metastases, along with urine catecholamine metabolites, neuron specific enolase and LDH as tumour markers.

#### Instrumental exams:

Test: X-ray of left lower limb.

Justification for test: To exclude any trauma or abnormalities in the lower limb, which could possibly explain the paralysis.

Result: No pathology noted.

Conclusion: The paralysis is not due to a lesion in the lower limb itself.

Test: MRI head.

Justification for test: To exclude an upper motor neuron lesion in the right motor cortex, which could possibly give rise to left lower limb paralysis. Although the weakness in the limb was flaccid and the reflexes were absent, suggesting a lower motor neuron problem, this test was still justified as a motor cortical lesion may present with hypotonia and absent reflexes in the acute stages.

Result: The brain and CSF spaces showed normal intensity. No focal lesion was seen.

Conclusion: The lower limb motor defect is not the result of a brain lesion.

Test: MRI whole spine.

Justification of test: To identify any lesion in the spinal cord which could be the cause of left lower limb paralysis.

Result: An extramedullary extradural intracanalicular lesion extending from caudal to the 10th thoracic vertebral body to L4 is noted. This displaced the cord and cauda to the left, taking up most of the intracanalicular space. A dumbbell paraspinal mass, 3.2cm (craniocaudally) by 2cm (anteroposteriorly), extends from the level of L1 to L4 vertebral bodies. This appears to be in continuity with the described intracanalicular mass through the right L1/L2 neural foramen. Fullness is also noted at the left L1/L2 neural foramen with no associated extracanalicular extension. (See figures 1 to 6).

Conclusion: There is a paraspinal tumour which has extended to the spinal canal and caused spinal cord compression, leading to left lower limb paraplegia. Histological confirmation of the tumour was not done locally because Baby D was referred to a tertiary centre for further investigations where a biopsy specimen was taken at laparoscopy.

#### **Therapy:**

Drug	Dosage	Frequency	Type	Reason
Paracetamol	30mg	QID	Analgesic	Pain relief

## **Diagnosis:**

### **Diagnosis:** Congenital Neuroblastoma

Neuroblastoma is the commonest malignant neoplasm in foetuses and neonates and the second commonest solid tumour in children, following brain tumours<sup>5</sup>. It has an incidence of 1 in 7000 live births<sup>11</sup>. 96 % of cases occur before the age of 10 years<sup>2</sup>. More young children die of neuroblastoma than any other cancer<sup>11</sup>.

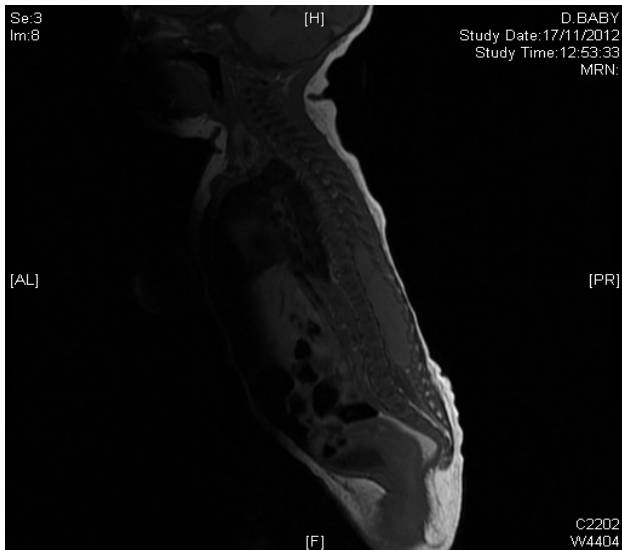


Figure 1

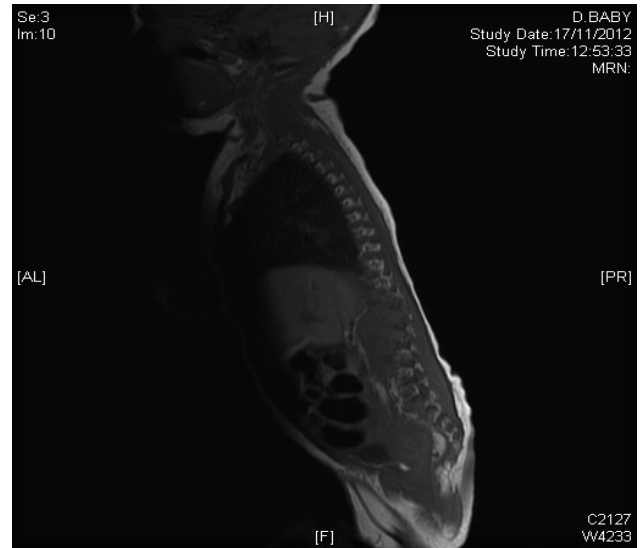


Figure 2

*MRI spine. Fig 1 shows an extramedullary extradural lesion to extend from caudal to the 10th thoracic vertebral body to L4. Figure 2 shows a 3.2cm (craniocaudally) x 2cm (anteroposteriorly) paraspinal mass extending from L1 to L4 vertebral body.*

Neuroblastoma is a malignant embryonic tumour derived from the primordial neural crest cells. These cells eventually inhabit the sympathetic ganglia along the neural tube and the adrenal medulla. Since both of these produce catecholamines they can be used as a biomarker for diagnosis of neuroblastoma. Neuroblastoma can arise anywhere along the migratory path of the neural crest cells. The most common site of primary tumour at presentation is the adrenal gland, followed by the retroperitoneum, paraspinal ganglia, posterior mediastinum and with the least common being the pelvis and cervical region<sup>5</sup>. In this particular case, the tumour evolved from the paravertebral ganglia which link with the spinal cord. As the dumbbell neuroblastoma grew, it infiltrated the intervertebral foramina and compressed the spinal cord and the intraspinal part of the spinal nerves with possible involvement of the vertebral bodies, which eventually gave rise to the paraplegia noted on neonatal examination. The incidence of intraspinal involvement from peripheral neuroblastoma extension is between 6% and 24%<sup>10</sup>. Although in this particular case, the spinal neuroblastoma was in the lumbar area, the thoracic spine is the most frequent level of spinal compression<sup>3</sup>.

The majority of neuroblastoma cases are sporadic. Amplification and overexpression of the MYCN proto-oncogene occurs in approximately 20% of neuroblastomas. MYCN gene codes for N-myc protein which controls the cell cycle and several microRNAs<sup>1</sup>. In such sporadic cases, there may also be alterations in the p53 pathway and amplification and polymorphism of the MDM2 oncogene. Familial tumours represent only 1-2% of cases. They are transmitted in an autosomal dominant fashion with incomplete penetrance, with germline mutation in Phox2b and ALK. ALK is critical in the development of the nervous system and Phox2b is involved in the formation of cells of the sympathoadrenal lineage<sup>11</sup>. Familial cases can present with two or more neuroblastoma tumours in different sites. Most probably, congenital neuroblastoma is

multifactorial, having both an environmental and a genetic input in its aetiology<sup>7</sup>. It is associated with cardiac defects in 20% of cases<sup>4</sup>.

Neuroblastoma consists of undifferentiated small round-shaped sympathetic cells with scanty cytoplasm, hyperchromatic nuclei and indistinct nucleoli. These cells are called neuroblasts and are surrounded by neutopil<sup>12</sup>. Neuroblastoma is one of the small, round, blue cell tumours of childhood (SRBCT)<sup>11</sup>. The neuroblasts may form clusters called Horner–Wright rosettes which are characteristic of neuroblastoma. Calcification and schwannian stroma are also sometimes seen<sup>12</sup>.

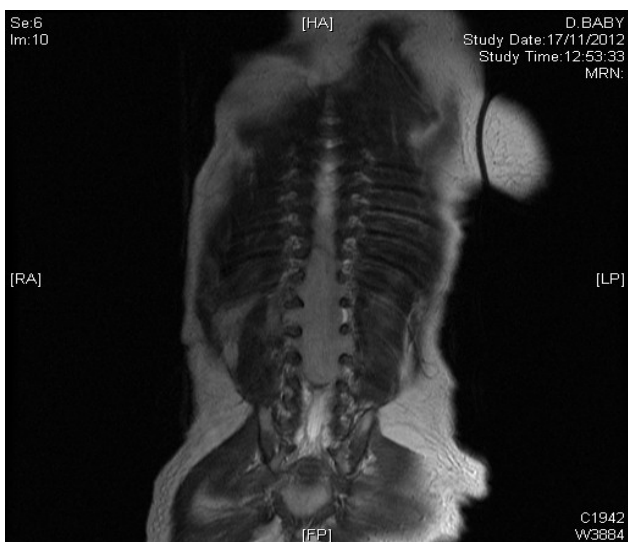

Figure 3

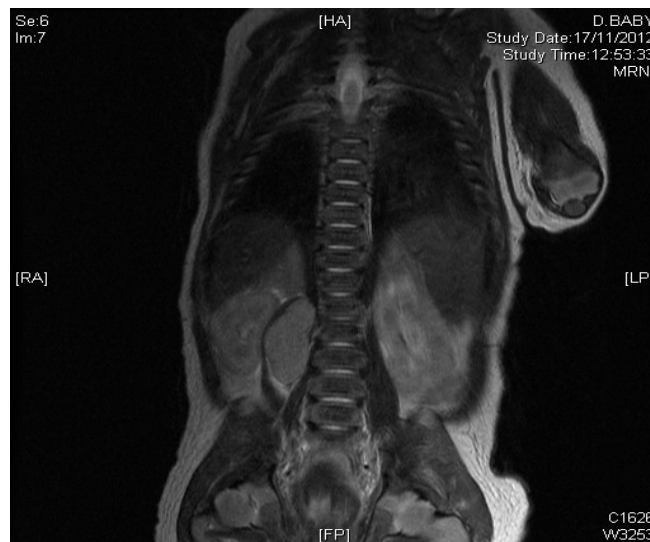

Figure 4

Figure 3 and 4 show the masses described in figure 1 and 2 in coronal section

Neuroblastoma has a range of clinical presentations. It can present as an indolent abdominal or chest mass. If it has infiltrated bone it can present with pallor secondary to anaemia, pain or a limp. The rare cervical neuroblastomas can present with Horner’s syndrome, a neck mass, stridor and dysphagia. Periorbital ecchymosis, proptosis and blindness occur with metastases to the orbital bones<sup>11</sup>. Spinal neuroblastomas give back or radicular pain, sensory deficits, motor deficits and sphincteric dysfunctions<sup>3</sup>. Paraneoplastic syndrome is another presentation of neuroblastoma, specifically opsoclonus-myoclonus ataxia, hypertension, flushing, tachycardia, sweating (in adrenal tumours) or intractable diarrhoea (as a result of VIP secretion), irritability, vomiting and loss of appetite<sup>12</sup>. The main site of metastases is the liver<sup>5</sup>. Sometimes neuroblastoma is asymptomatic and discovered incidentally during imaging for other reasons<sup>12</sup>.

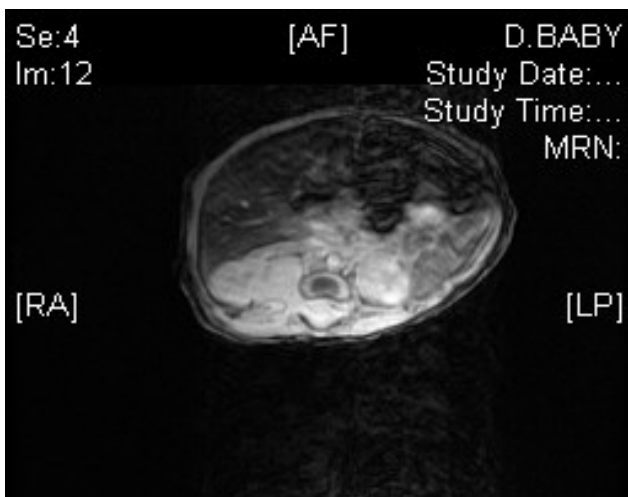


Figure 5

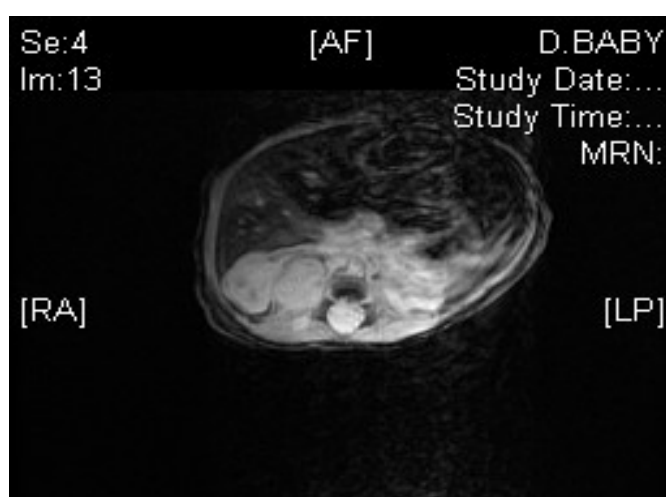


Figure 6

Figures 5 and 6 show the masses described in figure 1 and 2 in transverse section

Poor prognostic factors in neuroblastoma are the presence of MYCN gene, deletion of 11p23, poor differentiation, advanced stage, diploid tumour (rather than hyperploid), noncystic, diagnosis after birth as opposed to antenatal diagnosis, age greater than 18 months, a high mitosis-karyorrhexis index (MKI), poor stromal maturity, high serum levels of lactate dehydrogenase, neuron specific enolase and ferritin and a low ratio of vanillylmandelic acid to homovanillic acid<sup>5,6,12,13</sup>.

The International Neuroblastoma Risk Group Staging System (INRGSS) is used to stage neuroblastoma. It is based on risk factors identified by imaging at diagnosis, biopsies and laboratory tests. Stage L includes a localised tumour that does not involve vital structures and is confined to one body component. Stage L2 refers to a locoregional tumour with the presence of one or more image-defined risk factors. Stage M means that there are distant metastasis<sup>11</sup>. Cytogenetics of neonatal tumours are different to those of older children, which explains their different clinical behaviour and the better prognosis<sup>7</sup>. Taking this into consideration, such cases are classified as stage MS which refers to metastatic disease in children younger than 18 months in whom the secondaries are limited to the skin, liver and bone marrow. Low-risk neuroblastoma patients have a 5-year survival rate of 95%, whereas with high risk groups this falls to 30-50%<sup>11</sup>.

It is thought that foetuses presenting with neuroblastoma have a better outcome than if the disease occurs later on in childhood<sup>4</sup>. This is because children older than 1 year usually turn out to have extensive metastases at presentation which tends to progress despite intensive treatment<sup>2</sup>. On the other hand, if congenital or diagnosed before the age of 1, the tumour is usually localised<sup>8</sup>. Moreover, neuroblastoma in neonates tends to have a normal MYCN copy number and a hyperdiploid DNA index, both of which indicate a good prognosis<sup>5</sup>. However, although survival with dumbbell neuroblastoma appears to be good in many cases, neurological outcome is usually poor<sup>8</sup>. The most common neurological deficit is irreversible flaccid paralysis of lower limbs that does not respond to therapy<sup>5</sup>. When the patient presents with paraplegia, as was the case with this particular baby, it is almost always irreversible<sup>3</sup>.

### **Final treatment and follow ups:**

Although neuroblastoma is the commonest extra-cranial tumour in childhood, it is still a rare disease. The rarity of this disease means that there are few controlled trials researching the management of this condition<sup>6</sup>. It is known that the clinical behaviour varies from spontaneous regression to widespread disseminated disease<sup>11</sup>. Therefore, expectant management is not suggested for neonates with neuroblastoma because the natural history of the disease is unpredictable<sup>4</sup>. Baby D is currently receiving therapy at Great Ormond Street Hospital for Children in London.

Treatment of neuroblastoma is usually a combination of chemotherapy, radiotherapy and surgical resection<sup>9</sup>. The stage of the tumour is one of the most important factors in choosing treatment. As a general rule, resection alone is sufficient for early low-risk tumours. Chemotherapy is added in intermediate-risk tumours, or it may be used before surgery to reduce the size of the tumour and facilitate resection. High-risk tumours are treated with surgery and chemotherapy and bone marrow transplantation if exceedingly resistant<sup>12</sup>.

Dumbbell neuroblastoma with spinal cord compression is, in many cases, unresectable. Decompressive laminectomy is mainly performed in those cases of recent onset neurological dysfunction<sup>10</sup>.

With regards to chemotherapy for unresectable disease, the following drugs may be given:

- Alkylating agents - cyclophosphamide, ifosfamide
- Platinum compounds - cisplatin, carboplatin
- Topoisomerase II inhibitors – etoposide, doxorubicin
- Vincristine
- Busulfan and melphalan are sometimes used during stem cell transplant<sup>12</sup>

Radiotherapy targeting the primary tumour is used for high-risk patients following chemotherapy. It is also useful as palliative therapy for bone metastases and hepatomegaly<sup>12</sup>. There is a lower recurrence rate associated with radiation therapy given before or after bone marrow transplantation<sup>9</sup>. The most common sites of relapse are bone and bone marrow<sup>11</sup>.

In the future, this patient may be given an additional treatment modality which is autologous stem cell transplant for consolidation which helps to re-populate the bone marrow after chemotherapy<sup>13</sup>. Also, immunotherapy and retinoids are used for maintenance<sup>11</sup>. Immunotherapy is the use of a monoclonal antibody ch14.18 which binds to the ganglioside GD2 on the surface of many neuroblastoma cells. This is usually done after a stem cell transplant<sup>13</sup>. Retinoic acid is used as a form of differentiation therapy.

There are several complications associated with treatment for neuroblastoma and for other tumours in general. The kidneys are vulnerable due to toxicity of cisplatin chemotherapy and radiotherapy<sup>9</sup>. In this case, kidney damage due to pressure effects by the paraspinal mass is also possible. If surgery is attempted on this patient, there may be significant spinal damage<sup>8</sup>. Toxic effects of chemotherapy include vomiting, diarrhoea, cardiotoxicity, infertility, deafness, dry desquamation, secondary malignancies, derangements in liver function tests and skeletal abnormalities. Radiation may cause skin reactions, nausea and vomiting, lethargy, infertility and secondary malignancies. The main complication of stem cell transplant is post-transplant shock<sup>9</sup>. All these complications have to be looked out for during the follow-up period.

## **Fact Box 8:**

Title: Congenital Spinal Neuroblastoma

Short description of condition: Congenital Spinal Neuroblastoma is a solid tumor of the spinal cord which arises in utero. Neuroblastoma has an incidence of 1 in 7000 live births, ranking it as the commonest neoplasm in fetuses and neonates.

Risk factors: As the condition arises in utero, pathogenesis of disease is mainly genetic.

Symptoms:

- Pain
- Parasthesia
- Diarrhoea
- Vomiting
- Loss of appetite

Signs:

- Abdominal / chest mass
- Paraplegia
- Hypertension
- Flushing
- Tachycardia
- Sweating

Prevention: There are no specific preventions that can be made, but a diet rich in folate pre-conception is associated with a decreased incidence of neuroblastoma.

NOTE: As you can appreciate, since the condition develops in utero preventive measures are not really adequate (Folate is given to every obstetric patient for the prevention of various NT defects, not neuroblastoma specifically) and the only signs that can be elicited from a newborn are paraplegia and decreased tone. The symptoms above are relevant to those diagnosed at a later stage.

### **References:**

1. Buechner J, Einvik C. N-myc and Noncoding RNAs in Neuroblastoma. *Mol Cancer Res* 2012;10:1243-1253.
2. Cozzi DA, Mele E, Ceccanti S et al. Long-term Follow-up of the “Wait and See” Approach to Localized Perinatal Adrenal Neuroblastoma. *World J Surg* DOI 10.1007/s00268-012-1837-0.
3. De Bernardi B, Pianca C, Pistamiglio P et al. Neuroblastoma With Symptomatic Spinal Cord Compression at Diagnosis: Treatment and Results With 76 Cases. *J Clin Oncol*. 2001 Jan 1;19(1):183-90.
4. Gupta K, Bansal A. Congenital Neuroblastoma: An Autopsy Report. *Fetal and Pediatric Pathology*, Early Online:1–5, 2012.
5. Isaacs H. Fetal And Neonatal Neuroblastoma: Retrospective Review Of 271 Cases. *Fetal And Pediatric Pathology*, 26:177–184, 2007.
6. Lakhoo K, Sowerbutts H. Neonatal tumours. *Pediatr Surg Int* (2010) 26:1159–1168.
7. Moore SW, Satge D, Sasco AJ et al. The epidemiology of neonatal tumours. *Pediatr Surg Int* (2003) 19: 509–519.
8. Munro FD, Carachi R, Fyfe AH. Congenital neuroblastoma presenting with paraplegia. *Arch Dis Child*. 1991 Oct;66(10):1246-7.
9. Nazmy MS, Khafaga Y. Clinical experience in pediatric neuroblastoma intensity modulated radiotherapy. *Journal of the Egyptian National Cancer Institute* (2012) 24, 185–189.
10. Nejat F, Zabihyan S, IzadYar M. Congenital dumbbell neuroblastoma mimicking birth trauma. *J Neurol Neurosurg Psychiatry*. 2005 January; 76(1): 143–144.



11. Owens C, Irwin M. Neuroblastoma: The impact of biology and cooperation leading to personalized treatments. *Critical Reviews in Clinical Laboratory Sciences*, 2012; 49(3): 85–115.
12. Papaioannou G, McHugh K. Neuroblastoma in childhood: review and radiological findings. *Cancer Imaging* (2005) 5, 116–127.
13. Sokol E, Haut PR, Gosiengfiao Y et al. Progression-Free Survival of Two Cases of High-Risk Neuroblastoma With Refractory/Relapsed Disease Following Surgery Alone. *Pediatr Blood Cancer* DOI 10.1002/pbc