

## Case Report

# A Rare Case of an Idiopathic Extraocular Muscle Abscess

Maria de Bono Agius, Mario Vella

**Abstract**

Diplopia has a diverse range of ophthalmological, neurological, autoimmune, neoplastic and infectious causes. However it is very rare for an extraocular muscle abscess to occur. A skeletal muscle abscess usually occurs in the thigh and trunk muscles and is most commonly caused by *Staphylococcus aureus*.<sup>1</sup>

The purpose of this case report is to describe this condition we came across in our eye casualty department in a healthy teenager who presented with painful diplopia and this was due to a lateral rectus muscle abscess.

Complete resolution of the diplopia occurred by 6 weeks from starting treatment. The possible aetiologies and possible complications of such a condition are then discussed.

An idiopathic extraocular muscle abscess is a rare condition which should be included in the differential diagnosis of a patient presenting with painful double vision.

**Keywords**

extraocular muscle abscess; idiopathic; painful diplopia; *Staphylococcus aureus*

**Introduction**

Our 16 year old patient had an idiopathic right lateral rectus muscle abscess. All cardinal signs of an abscess including rubor, calor, dolor, tumor, function laesa and swinging fever were present.

**Case**

A healthy 16 year old female presented to the Ophthalmic Casualty in the evening complaining of a 4 day history of headache and nausea. She also complained of increased swelling of her right eye and painful eye movements. She gave no past ophthalmic history of note.

On examination she had a visual acuity of 6/6 both eyes (OU), normal colour vision OU, normal pupil reaction OU and a normal posterior segment OU.

Diplopia was elicited in right more than in left gaze with generalized painful eye movements. Prism cover test gave readings of 8 prism dioptres (PD) base out (BO) at 1/3m and 12 PD BO at 6m.

On closer examination, there was increased conjunctival hyperemia over the Lateral Rectus area of her right eye as well as a moderate ptosis from a swollen right upper eyelid.

Her vital parameters were checked and all was normal except for a temperature of 102.2°F. She was referred for an Otolaryngology consultation and this proved to be normal.

She was started on the following antimicrobial therapy: intravenous Co-amoxiclav 1g bd and intravenous Metronidazole 500mgs tid. An MRI Orbits was done and this showed the presence of a lateral rectus muscle abscess in the right eye. (See Fig. 1).

Improvement of her symptoms was observed after the first few days of treatment.

She was changed over to oral therapy after 6 days since she was not tolerating adequate food intake and was then discharged home on Ciprofloxacin 250mgs bd x 3 weeks.

A repeat orthoptic test at 6 weeks showed negligible diplopia and a control MRI orbits at 4 months showed complete resolution of the lateral rectus abscess (see Fig. 2). To date, the patient has remained disease free with no residual motility dysfunction.

**Maria de Bono Agius MD, FEBO\***

Mater Dei Hospital

Msida, Malta

dr.maria.agius@gmail.com

**Mario Vella MD, FRCSEd**

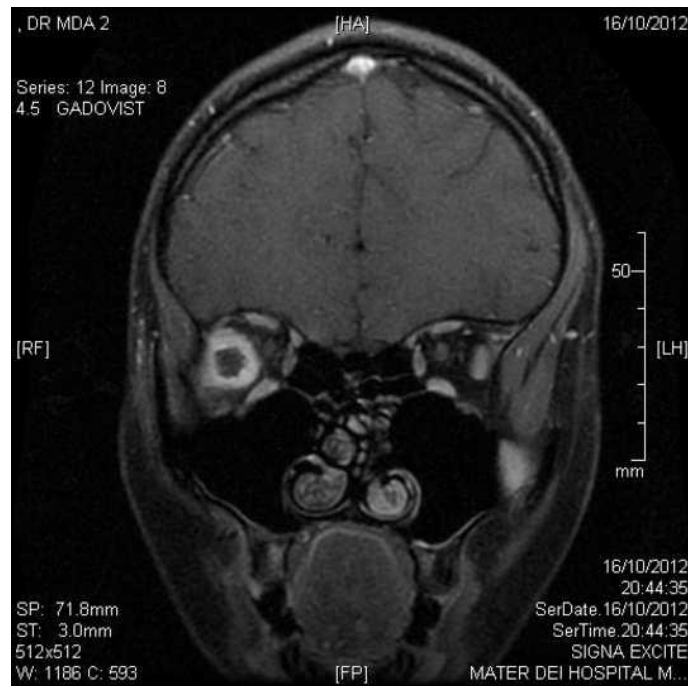
Mater Dei Hospital

Msida, Malta

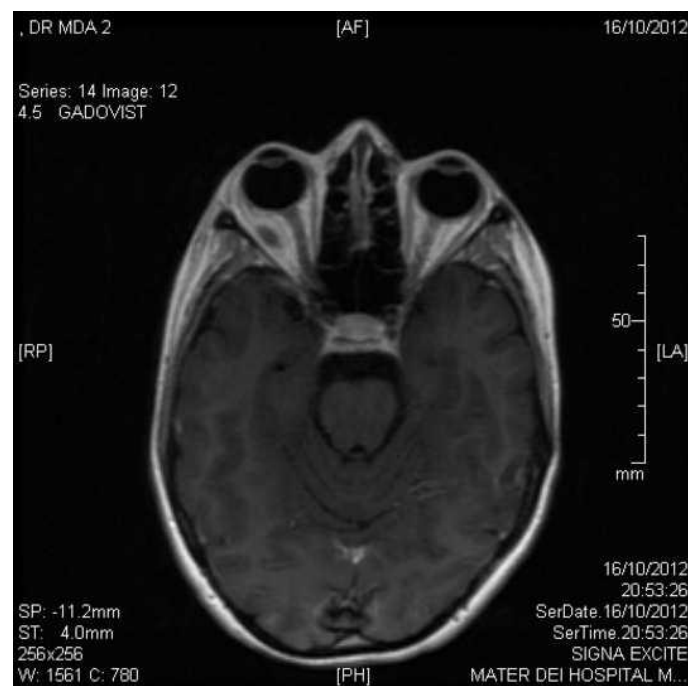\*Corresponding Author

## Case Report

*Figure 1a: MR Orbits; with contrast showing a right lateral rectus muscle abscess*

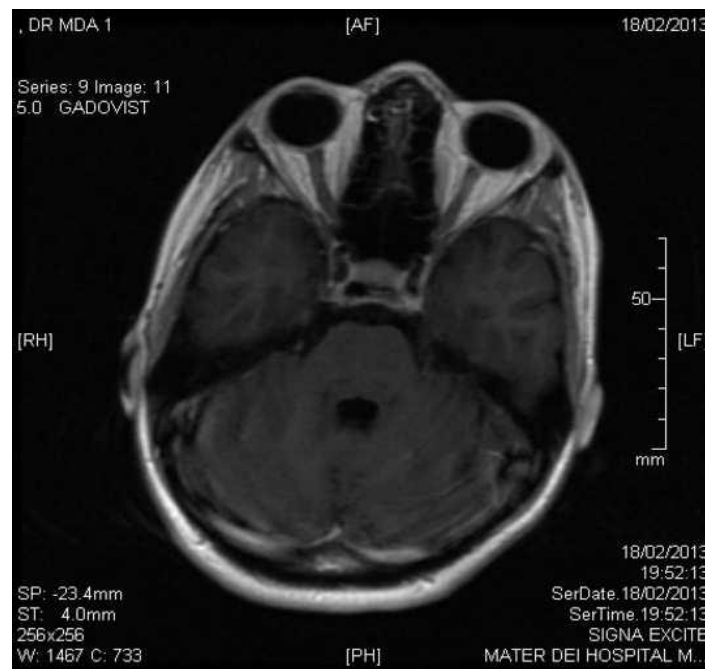


*Figure 1b: MR Orbits; with contrast showing a right lateral rectus muscle abscess*

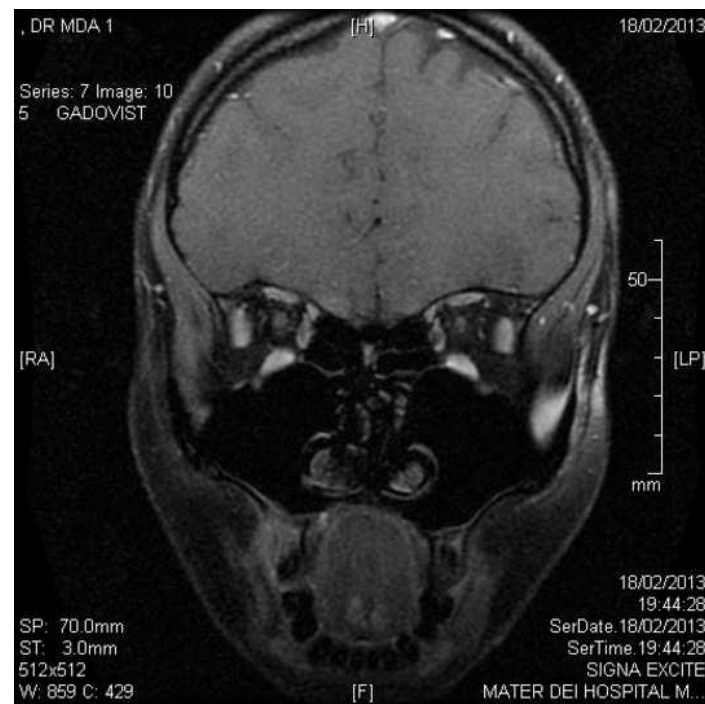


## Case Report

**Figure 2a:** MR Orbits; with contrast showing resolution of the right lateral rectus muscle abscess



**Figure 2b:** MR Orbits; with contrast showing resolution of the right lateral rectus muscle abscess



### Discussion

There have been no case reports of an isolated abscess in an extraocular muscle in Malta. The pathogenesis of an extraocular muscle abscess remains unknown however potential causes are: haematogenous spread from bacteraemia, local spread example from dacryocystitis, midfacial or dental infection, post-trauma or post-surgery.<sup>6</sup> Blood cultures should be taken to help

in the management of the patient. The aetiology of such an abscess is usually *Staphylococcus aureus* followed by parasitic infestation with *Cysticercus cellulosae* which is the encysted larva of the pork tapeworm, *Taenia solium*.<sup>2,4</sup>

In our case, antibiotics were started following a normal Otorhinolaryngology review – however in view of the fever, an infective aetiology was still high on the

## Case Report

cards and this was proven the following morning when the MR Orbits was carried out. Intracranial extension can be rapid from orbital cellulitis and thus it was important for the antibiotics to be started sooner rather than later. Ultrasound-guided drainage was not necessary in our case due to rapid improvement in the patient's symptoms and signs. Should the patient's symptoms have worsened, then this would have been necessary to help both culture the organism as well as provide drainage of the abscess.<sup>5</sup>

Both CT and MRI can be used as investigative tools in this circumstance. However since MRI gives no radiation exposure and is better to study soft tissues, it was the modality of choice. In fact if one had to compare the information gathered on an extraocular muscle abscess between MRI and CT, the former demonstrates a more clear delineation of the extent of inflammatory changes than does CT, and it also demonstrates the abscess as a collection distinct from surrounding structures on at least one repetition rate. With CT, unless an abscess contains air or is of low attenuation, it often blends with the surrounding structures and is difficult to differentiate from them.

Possible differential diagnoses include:

- Inflammation – idiopathic orbital inflammatory disease
- Infections - orbital cellulitis
- Structural lesions (ex. dermoid cyst)
- Vascular neoplastic lesions (ex. capillary haemangioma, lymphangioma)
- Lymphoproliferative diseases (ex. lymphocytic granuloma)
- Neurogenic tumors (ex. neuroblastoma, plexiform neurofibroma)
- Mesenchymal tumors (ex. rhabdomyosarcoma)
- Metastatic carcinoma.<sup>3</sup>

Possible complications from such a condition can be:

- Intraocular Complications:
  - Fibrosis of Lateral Rectus muscle with permanent restriction of movement
  - Optic Neuropathy
  - Central Retinal Artery Occlusion
- Intracranial complications include meningitis, cavernous sinus thrombosis, and intracranial, epidural, or subdural abscess formation.

The role of biopsy is probably limited to atypical cases or those unresponsive to therapy, particularly to exclude neoplasia.

### References

1. Acharya I, Jethani J. Pyomyositis of extraocular muscle: Case series and review of the literature. *Indian Ophthalmol.* 2010;58(6):532–5.

2. Shephard JJ. Tropical myositis: is it an entity and what is its cause? *Lancet* 1983; 26:1240–2.
3. Haufschild T, Weber P, Nuttli I, Hecker B, Flammer J, Kaiser HJ. Idiopathic isolated abscess in an extraocular muscle in a child. *Arch Ophthalmol.* 2004;122:1233–4.
4. Varma A, Sharma K, Rath B, Gupta RK. Isolated abscess of extraocular muscle abscess in two young boys: clinical and imaging features. *Orbit* 2003;22:67–72.
5. Jong Hyuk P, Roo Min J. A Case of an Isolated abscess in an extraocular muscle. *J Korean Ophthalmol Soc.* 2014 Apr;55(4):616-22.
6. Lim WS, Aclimandos W, Pringle E, Shah B. Isolated extraocular muscle abscess presenting 40 years after squint surgery. *BMJ Case Rep.* 2014 Apr 4;2014. Pubmed PMID: 24706710.