

Kahr PC, Gupta SK, Kothari SS, Ramakrishnan S. Classical Supravalvar Aortic Stenosis and Peripheral Pulmonary Stenosis. *Images Paediatr Cardiol* 2014;16(1):1-4.

IMAGES in PAEDIATRIC CARDIOLOGY

Kahr PC¹, Gupta SK², Kothari SS², Ramakrishnan S². Classical Supravalvar Aortic Stenosis and Peripheral Pulmonary Stenosis. *Images Paediatr Cardiol* 2014;16(1):1-4

¹Division of Adult Congenital and Valvular Heart Disease, Department of Cardiovascular Medicine, University Hospital Muenster, Muenster, Germany.

²Department of Cardiology, All India Institute of Medical Sciences, New Delhi, India.

MESH: imaging; pulmonary stenosis; aortic stenosis, supravalvar; catheterization; angiography

Abstract

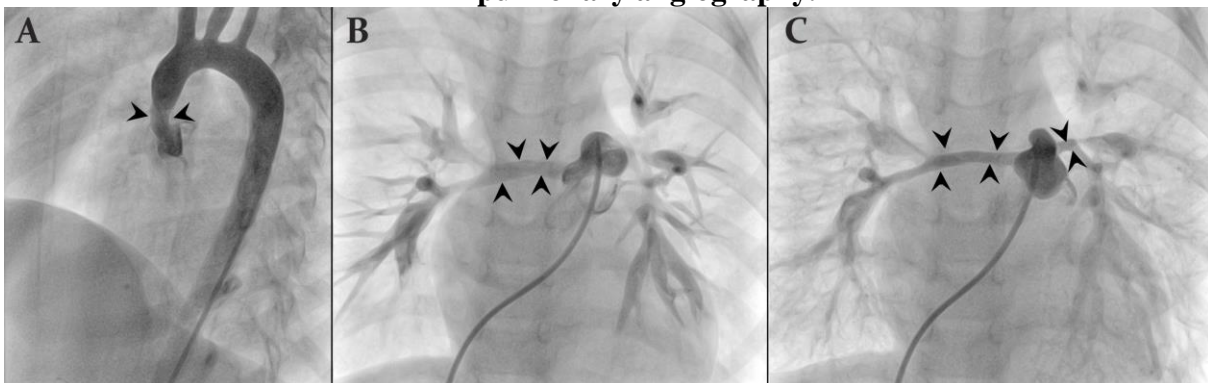
Supravalvar aortic stenosis as well as peripheral pulmonary stenosis are rare forms of congenital heart disease, which occur, however, relatively frequently in association. Here we report and discuss the classical findings of SVAS and PPS upon clinical examination and imaging in a six-year-old girl that presented with repeated respiratory tract infections and failure to thrive.

Case Report

A six-year-old girl presented with repeated episodes of respiratory tract infections and failure to thrive since 3 months of age. On examination, pulse was 100bpm, regular, and palpable at the lower extremities. There was no sign of heart failure or cyanosis. Auscultation revealed a systolic murmur, which was heard loudest over the left side of the chest. ECG showed right axis deviation with large bidirectional forces in the precordial leads, suggestive of bi-ventricular hypertrophy. Chest X-ray showed reduced pulmonary vascular markings, but no cardiomegaly. Initial transthoracic echocardiography revealed significant supravalvar aortic stenosis (SVAS) with a mean gradient of 44mmHg. The stenosis appeared to be tubular, long-segment type with trivial aortic regurgitation. Despite being dilated, left ventricular function was classified as normal (LVed 29mm/m², LVes 19mm/m², EF 65%). Laboratory investigations demonstrated normal serum calcium levels, cognitive function was according to age, and the facial morphology was inconspicuous.

Cardiac catheterization confirmed the diagnosis of supravalvar aortic stenosis with trivial aortic regurgitation (Figure1A). Coronaries were normal. Right ventricular pressures were nearly systemic (114/14 vs. 126/60 mmHg) and angiography revealed a diffuse, extensive narrowing of both branch pulmonary arteries (Figure1B-C).

Figure 1: A 6 year old girl presented with these classical findings of peripheral pulmonary stenosis (PPS) and supravalvar aortic stenosis (SVAS) : A) Depiction of the SVAS upon injection into the coronary sinuses. B-C) Visualization of the diffuse bilateral PPS on pulmonary angiography.



Consecutively, CT angiography was done to better delineate the PPS. Here, the main pulmonary artery (6.5x7.0mm), right (5.0mm) and left branch pulmonary arteries (5.3 mm) were estimated to be of reduced size (Figure2). In addition, significant osteal stenosis was found at the LPA as well as multiple other sites of the peripheral pulmonary arteries. The aorta showed stenosis just above the aortic sinuses with diameters being 17x14mm at the sinuses, 6x6mm at the level of the stenosis and 11x10mm distal to the stenosis. Diameter of the descending thoracic aorta was measured to be 9x7.4mm. The rest of the descending aorta was assessed to be normal with typical branching pattern and without stenosis of the mesenteric or renal arteries. Otherwise, no cardiac malformations were detected.

Figure 2: A-C) CT-angiographic findings in the same patient in different angulations delineating the diffuse aspect of the PPS, but also some osteal stenosis at the LPA and further distal in both branch pulmonary arteries (arrows). D) 3D-reconstruction of the CT-angiographic dataset.

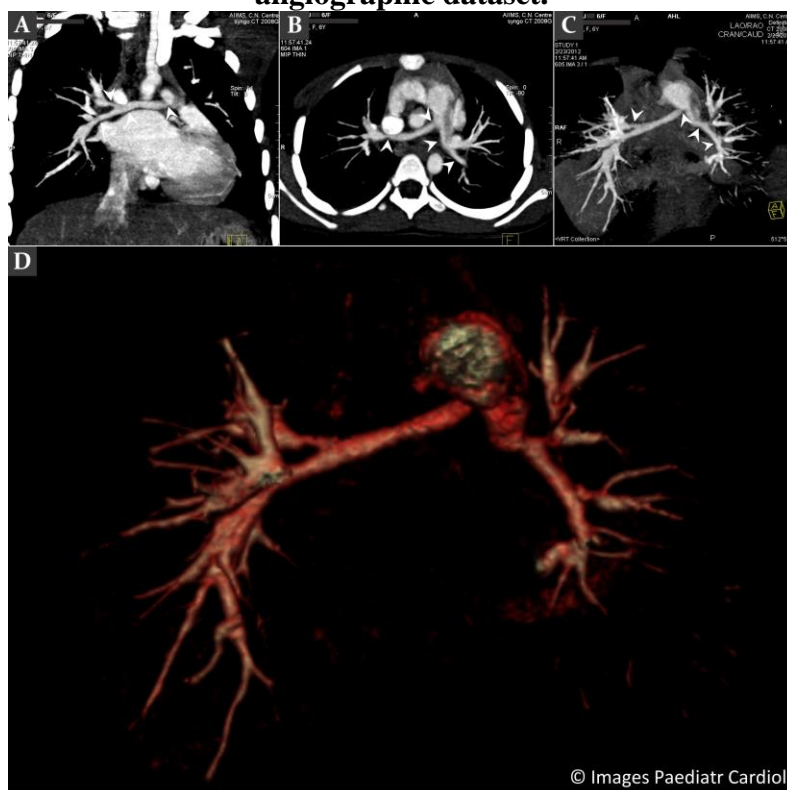


Figure 3: Cine loop of the pulmonary artery contrast injection

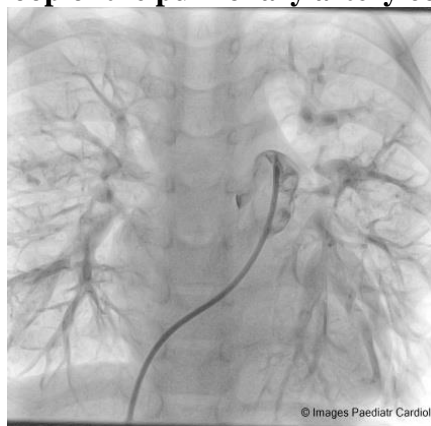
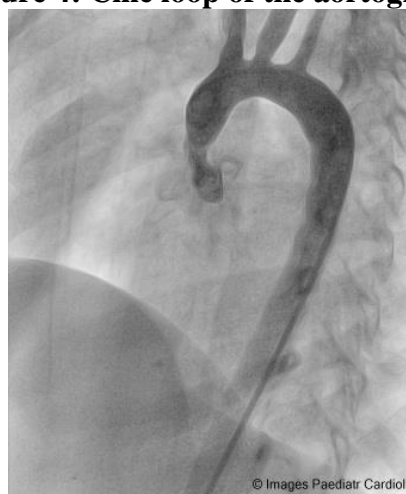
Figure 4: Cine loop of the aortogram.



Discussion

SVAS as well as PPS are rare forms of congenital heart disease, which, however, occur relatively frequently in patients with Williams-Beuren syndrome. Nevertheless, as in this case, non-syndromic forms have been reported.

SVAS is the least common form of left-sided outflow tract obstruction, accounting for around 8% of patients with congenital aortic stenosis. Morphologically, at least two forms can be discriminated: most patients (60-75%) present with an hourglass or tubular formed, discrete constriction of the ascending aorta, while others show a more diffuse narrowing of larger parts of the ascending aorta.¹

In general, echocardiography allows good characterization of the lesion and the trans-stenotic gradient. Therefore, conventional angiography as well as CT angiography are not routinely performed, but may be helpful if further cardiac anomalies are suspected. Because the lesion is progressive in most cases,^{2,3} surgical relief of the obstruction is generally accepted as the only definite treatment option.⁴ However, the indications for surgery are uncertain at present due to limited data. A trans-stenotic gradient of 30mmHg has been suggested, but the threshold may be less when other cardiac anomalies are present. Reports on balloon angioplasty have been mixed. Similar to SVAS, PPS shows marked variability between effected individuals. There can be single or multiple lesions anywhere along the major pulmonary branches, which result in obstructions ranging from localized to extensive. Initially, right heart catheterization was the gold standard to delineate the anatomy of PPS, particularly because echocardiographic visualization is often limited

if lesions are distal. However, non-invasive high-resolution imaging of PPS has become achievable using MR and CT angiography.

In opposition to SVAS, PPS has been suggested to improve spontaneously in many patients.^{2,3} Decreased rigidity of the vessels has been suggested to cause this improvement rather than true increase in the size of the lumen. Thus, peripheral pulmonary stenosis is in most cases not the limiting part of the lesion² and it has been argued that surgical or minimal-invasive intervention is not necessary as long as right ventricular pressures are not increased. Nevertheless, treatment of PPS has become standard as balloon angioplasty has been demonstrated to be a safe and effective method, in particular for distal^{1,5} and isolated⁶ lesions. Reinterventions, however, are required in up to 78% of patients after 5 years.⁶

If a patient shows combined SVAS and PPS, cardiac catheterization may be highly hazardous. This highlights the increased risk of patients with biventricular pressure overload. Nevertheless, a combined approach of pulmonary artery dilatation and surgical resection of the supravalvar aortic stenosis appears to be the best treatment option for patients with severe bilateral outflow tract obstruction.

References

1. McElhinney DB, Petrossian E, Tworetzky W, Silverman NH, Hanley FL. Issues and outcomes in the management of supravalvar aortic stenosis. *The Annals of Thoracic Surgery*. 2000;69:562–7.
2. Wren C, Oslizlok P, Bull C. Natural history of supravalvular aortic stenosis and pulmonary artery stenosis. *J Am Coll Cardiol*. 1990;15:1625–30.
3. Giddins NG, Finley JP, Nanton MA, Roy DL. The natural course of supravalvar aortic stenosis and peripheral pulmonary artery stenosis in Williams's syndrome. *Br Heart J*. 1989;62:315–9.
4. Stamm C, Kreutzer C, Zurakowski D, Nollert G, Friehs I, Mayer JE, et al. Forty-one years of surgical experience with congenital supravalvular aortic stenosis. *J Thorac Cardiovasc Surg*. 1999;118:874–85.
5. Geggel RL, Gauvreau K, Lock JE. Balloon dilation angioplasty of peripheral pulmonary stenosis associated with Williams syndrome. *Circulation*. 2001;103:2165–70.
6. Cunningham JW, McElhinney DB, Gauvreau K, Bergersen L, Lacro RV, Marshall AC, et al. Outcomes after primary transcatheter therapy in infants and young children with severe bilateral peripheral pulmonary artery stenosis. *Circulation: Cardiovascular Interventions*. Lippincott Williams & Wilkins; 2013;6:460–7.

Contact Information

Peter C. Kahr
Division of Adult Congenital and Valvular Heart Disease
Dept. of Cardiovascular Medicine, University Hospital
Münster, Albert-Schweitzer-Str. 33
48149 Münster, Germany
Tel: +49 251 83 46110
Fax: +49 251 83 46109
Email: pckahr@gmail.com

© Images in
Paediatric Cardiology
(1999-2014)

