

Kibar AE, Hallioglu O, Erdem S, Celik I. Prenatal Diagnosis and Postnatal Follow-up of congenitally corrected transposition of the great arteries and recurrent supraventricular tachycardia. *Images Paediatr Cardiol* 2013;15(1):7-11

# IMAGES

## in PAEDIATRIC CARDIOLOGY

### Kibar AE,<sup>1</sup> Hallioglu O,<sup>1</sup> Erdem S,<sup>1</sup> Celik I.<sup>3</sup> Prenatal Diagnosis and Postnatal Follow-up of congenitally corrected transposition of the great arteries and recurrent supraventricular tachycardia. *Images Paediatr Cardiol* 2013;15(1):7-11.

<sup>1</sup>Departments of Pediatric Cardiology, Mersin Maternal and Child Health Hospital, Mersin, Turkey.

<sup>2</sup>Departments of Pediatric Cardiology, Mersin University, Mersin, Turkey

<sup>3</sup>Departments of Neonatology, Neonatal Intensive Care Unit, Mersin Maternal and Child Health Hospital, Mersin, Turkey.

#### Abstract

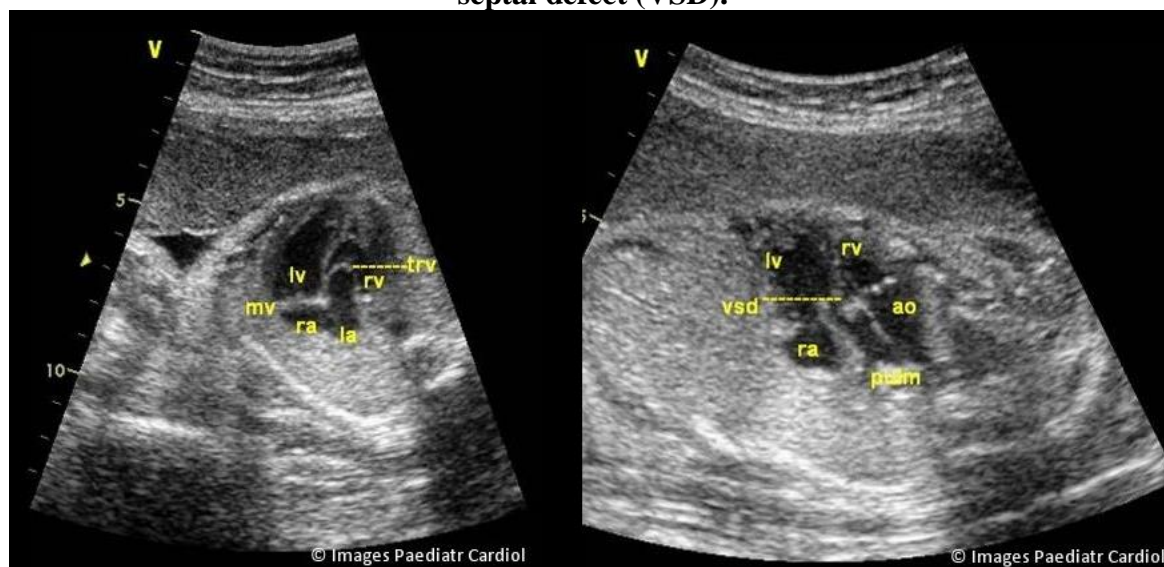
The prenatal sonographic diagnosis of congenitally corrected transposition of the great arteries (ccTGA), a rare form of congenital heart disease is very difficult. A 24-year-old woman was referred to our center at 28 weeks' gestation because of suspected fetal cardiac anomalies. We report a case of ccTGA with supraventricular tachycardia, ventricular septal defect, pulmonary valve stenosis, tricuspid valvar displacement and moderate tricuspid regurgitation during her pregnancy. The combined presence of SVT and ccTGA are occasionally present in the literature.

**Keywords:** Fetal echocardiograph, congenitally corrected transposition, tachycardia,

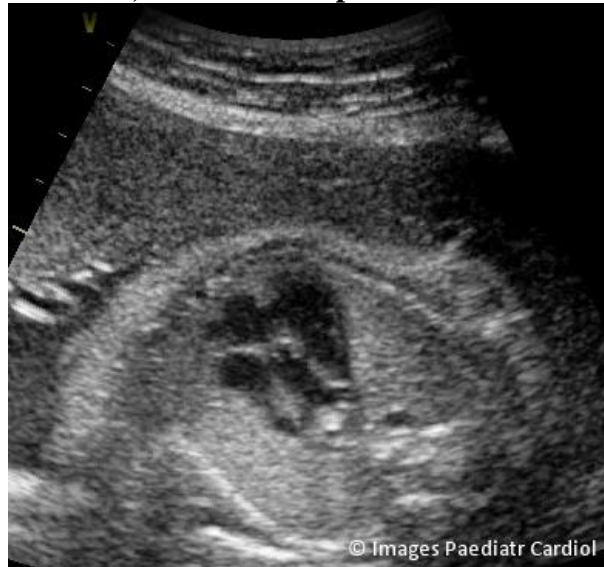#### Case report

A 24-year-old woman was referred to our center at 28 weeks' gestation because of suspected fetal cardiac anomalies. We echocardiographically diagnosed ccTGA and additional cardiac anomalies in utero at 28 weeks' gestation (Gravida: 3 para: 2). Associated cardiac lesions included ventricular septal defect, mild pulmonary valve stenosis, tricuspid valvar displacement and moderate tricuspid regurgitation (Figure 1-3).

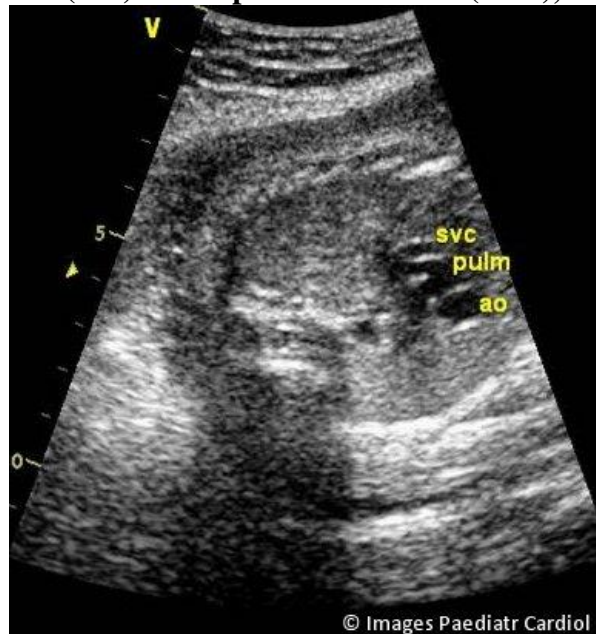
**Fig 1: Four chamber view. Situs solitus with levocardia. A detailed examination of the ventricular morphology helped to confirm that the right-sided right atrium entered, via a morphologic mitral valve (MV), the right-sided left ventricle (LV), which in turn emptied into the posterior, right-sided pulmonary artery (PA) instead the left-sided left atrium was connected, through a morphologic tricuspid valve (TV), to the left-sided right ventricle (RV), which emptied into the anterior, left-sided aorta (AO), ventricular septal defect ventricular septal defect (VSD).**



**Fig 2: Four chamber view. Note the ventriculoarterial discordance: the aorta arises from the left-sided, morphologically right ventricle instead bifurcating pulmonary artery arising from the morphological left ventricle, ventricular septal defect (VSD).**

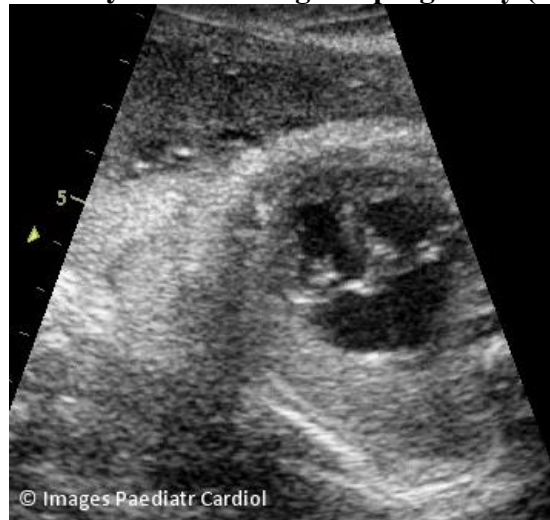


**Fig 3: The 3-vessels view. The pulmonary bifurcating (PULM) is in the middle between ascending aorta (AO) and superior vena cava (SVC), almost aligned.**



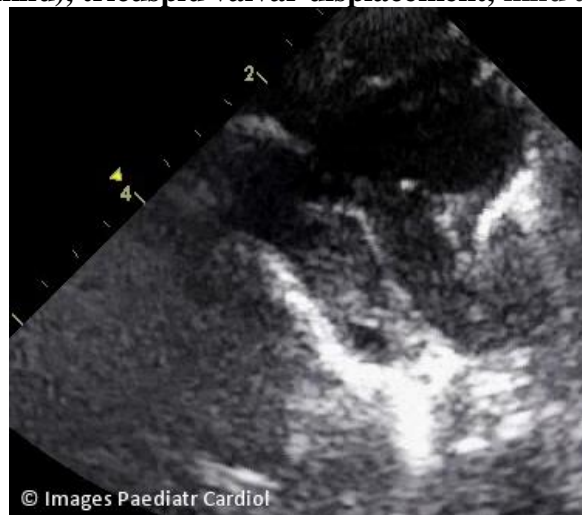This fetus experienced supraventricular tachycardia (SVT) in pregnancy (at 35 weeks' gestation) (fig 4).

**Fig 4: Supraventricular tachycardia during her pregnancy (at 35 weeks' gestation).**



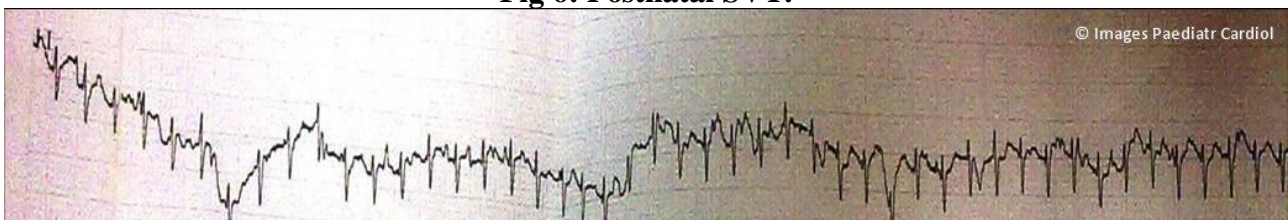
There was no familial history of congenital heart disease. The patient had no known systemic disease. Ultrasonography showed normal fetal growth without any structural anomalies. The diagnosis was confirmed with postnatal echocardiography (fig 5).

**Fig 5: Postnatal echocardiography found visceral situs solitus, visceratrial concordance, and atrioventricular and ventriculoarterial discordance, ventricular septal defect, pulmonary outflow obstruction (mild), tricuspid valvar displacement, mild tricuspid regurgitation.**



Postnatal SVT recurred (Figure 6) electrocardiographic and Holter monitor evidence was confirmed, in which initial treatment with adenosine was ineffective, but amiodarone was effective.

**Fig 6: Postnatal SVT.**



## Discussion

Congenitally corrected transposition is a rare congenital anomaly, with only a few cases diagnosed and reported prenatally even in the largest fetal series.<sup>1,2</sup> Prenatal sonographic diagnosis of CTGA is very difficult because the ventricular outflow tract may appear to arise correctly from the right and left ventricles. The long-term prognosis of ccTGA is dependent on associated other major cardiac anomalies and rhythm disturbances that can influence prognosis.<sup>3</sup>

SVT is reported to account for 47 – 68 % of cases of fetal tachycardia and is associated with a low percentage of structural abnormalities (2 % of cases).<sup>4</sup> Fetal tachycardia of any form that is intermittent, not accompanied by cardiac or valve dysfunction, and present <50% of the time is best not treated, but needs to be monitored closely.

Schnabel reported ccTGA at 20 weeks' gestation with recurrent SVT.<sup>4</sup> Some of these cases may undergo major and unexpected changes, particularly with regard to cardiac rhythm and tricuspid valvar function, with concomitant significant changes in prognosis. Our patient had tricuspid valvar displacement and moderate tricuspid regurgitation.

The diagnosis of these specific types of fetal tachycardia is difficult, if not impossible with the most widely used current technology. The electrophysiologic events are clearly defined in this situation, however, a precise diagnosis is still debatable.<sup>4</sup> In this case, postnatal SVT recurred, electrocardiographic and Holter monitor evidence was confirmed, and the initial treatment with adenosine was ineffective, but amiodarone was effective. The SVT shown in postnatal EKG (Figure 3) for instance, may be AVRT using a concealed accessory pathway. Therefore a detailed electrophysiologic study is eventually planned for our patient.

Anti-arrhythmic therapy are started when arrhythmias were sustained or associated with hemodynamic compromise prior to 34 weeks' gestation. After 34 weeks' gestation, such cases are delivered.<sup>5</sup> Furthermore, some controversy exists in relation to first-line and second-line treatment regimens for fetal supraventricular tachycardia. In general, digoxin is used as first-line treatment in the US, whereas in Europe flecainide is used for this purpose. For second-line treatment of drug-refractory supraventricular tachycardia with hydrops fetalis, maternal intravenous or oral digoxin, alone or in combination with amiodarone can be used without increasing mortality.

For fetuses without ventricular dysfunction, flecainide or sotalol have been used as second line agents, and both have efficacies of 60–80%. However, for fetuses with ventricular dysfunction or severe atrioventricular valve regurgitation, amiodarone is the most effective drug (>93% efficacy alone or in combination), and is associated with a low risk of proarrhythmia.<sup>5-6</sup> Cesarean deliveries is advocated for fetal distress associated with persistent SVT such as in our patient at 35 weeks of gestation.

In conclusion, we think that accurate fetal segmental analysis of the four-chamber and great vessel connections and relations (*l*-transposition) by fetal echocardiography could be highly helpful in improving follow-up of potentially critical neonates (especially irregular heartbeat). The combined presence of SVT and ccTGA are rarely reported in the literature during fetal monitoring.<sup>4</sup>

## References

1. Santoro G, Masiello P, Baldi C, Farina R, Fittipaldi O, Di Benedetto G. Corrected Transposition of the Great Arteries with Isolated Aortic Coarctation: In Utero Echocardiographic Diagnosis. *Pediatr Cardiol* 1997;18: 396–398.
2. Zhang Y, Cai A, Sun W, Guo Y, Zhao Y. Prenatal diagnosis of fetal congenitally corrected transposition of the great arteries. *Fetal Diagn Ther*. 2005;20: 16-9.

3. Shima Y, Nakajima M, Kumasaka S, Migita M. Prenatal diagnosis of isolated congenitally corrected transposition of the great arteries. Arch Gynecol Obstet. 2009;279: 557-9.
4. Schabel JE, Jasiewicz RC. Anesthetic management of a pregnant patient with congenitally corrected transposition of the great arteries for labor and vaginal delivery. J Clin Anesth. 2001 13:517-20.
5. Oudijk MA, Ruskamp JM, Ambachtsheer BE, Ververs TF, Stoutenbeek P, Visser GH, Meijboom EJ. Drug treatment of fetal tachycardias. Pediatr Drugs 2002;4:49-63.
6. Strasburger JF, Cuneo BF, Michon MM, Gotteiner NL, Deal BJ, McGregor SN, Oudijk MA, Meijboom EJ, Feinkind L, Hussey M, Parilla BV. Amiodarone therapy for drug-refractory fetal tachycardia. Circulation 2004;109:375-379.

### Contact Information

Kibar Ayse Esin  
Mersin Maternal and Child  
Health Hospital  
Güneykent/ Mersin  
Turkey.  
[dreseresin@yahoo.com](mailto:dreseresin@yahoo.com)

© Images in  
Paediatric Cardiology  
(1999-2013)

