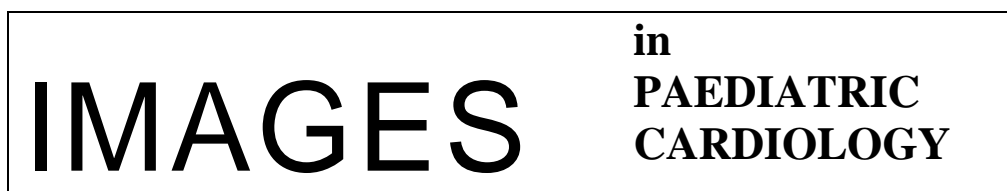

N Datrice, J Milliken, M Kirsh, A Abolhoda, F Saremi, and L Sender. Metastatic Ewing's Sarcoma to the Right Ventricle. *Images Paediatr Cardiol*. 2011 Apr-Jun; 13(2): 4–7.



Images Paediatr Cardiol. 2011 Apr-Jun; 13(2): 4–7.

PMCID: PMC3232596

Metastatic Ewing's Sarcoma to the Right Ventricle

N Datrice, J Milliken, M Kirsh, A Abolhoda, F Saremi, and L Sender
Divisions of Cardiothoracic Surgery, Radiological Sciences, and Hematology-Oncology, University of California Irvine Medical Center, Orange, California

Contact information: Nicole Datrice, Divisions of Cardiothoracic Surgery, University of California Irvine Medical Center, Orange, California ; Email: Nicole.Datrice@nih.gov

MeSH: Ewing's sarcoma, cardiac metastasis

Copyright : © Images in Paediatric Cardiology

This is an open-access article distributed under the terms of the Creative Commons Attribution-Noncommercial-Share Alike 3.0 Unported, which permits unrestricted use, distribution, and reproduction in any medium, provided the original work is properly cited.

Brief Image

Ewing's sarcoma is a round cell neoplasm derived from neural crest cells that is part of the primitive neuroectodermal tumor (PNET) family. It is a rare, aggressive malignancy that affects young people, most commonly in the second decade of life. The treatment of localized disease has improved greatly over the past four decades, but the prognosis for metastatic disease remains poor. Cardiac metastases of Ewing's sarcoma are exceedingly rare, with only a few reported cases.^{1–2}

We present a case of a 22 year old man with a history of Ewing's sarcoma of the bone involving the right knee. The patient required an above knee amputation after a failed salvage procedure, as well as aggressive chemotherapy and radiation. Fourteen months after his amputation, cardiac magnetic resonance imaging (MRI) revealed a 4 x 1.4 cm enhancing pedunculated mass in the right ventricular outflow tract (Fig 1,2), that was first noted on routine follow up chest computed tomography (CT).

Fig 1 Sagittal cardiac MRI identifying intracardiac mass in the right ventricular outflow tract. Smaller hypodense regions represent papillary muscles.

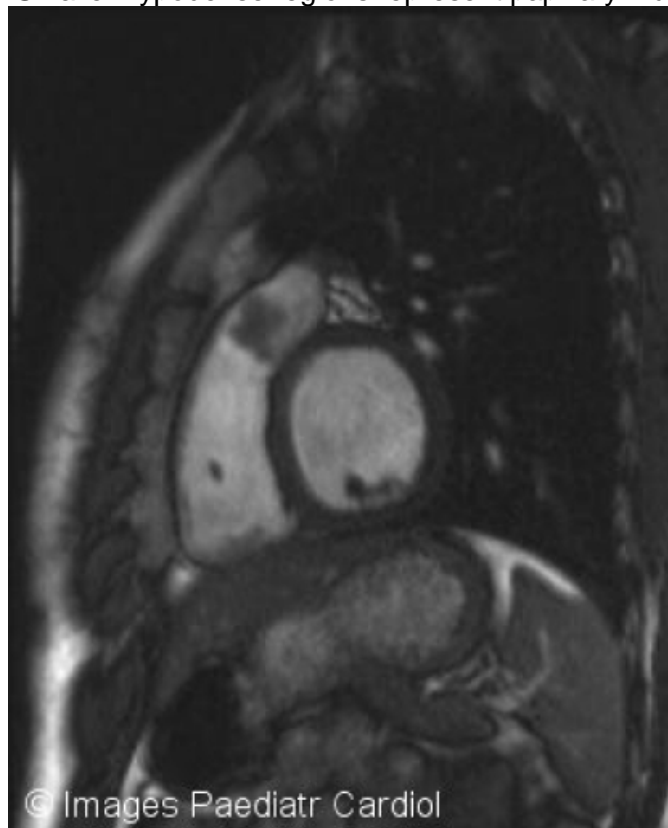
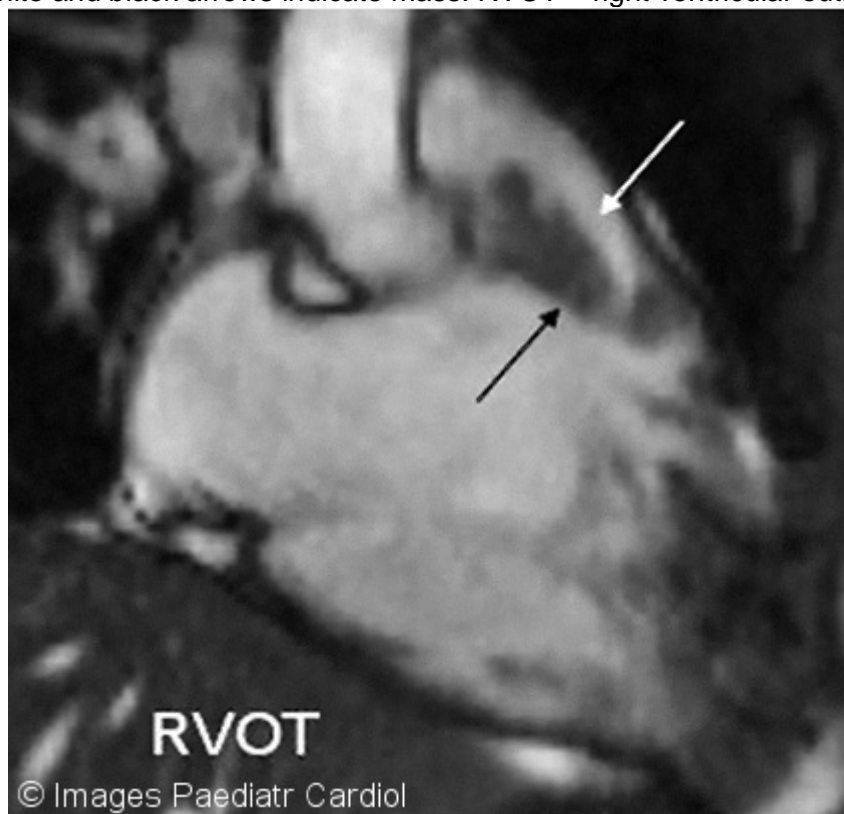

Fig 2 White and black arrows indicate mass. RVOT = right ventricular outflow tract.

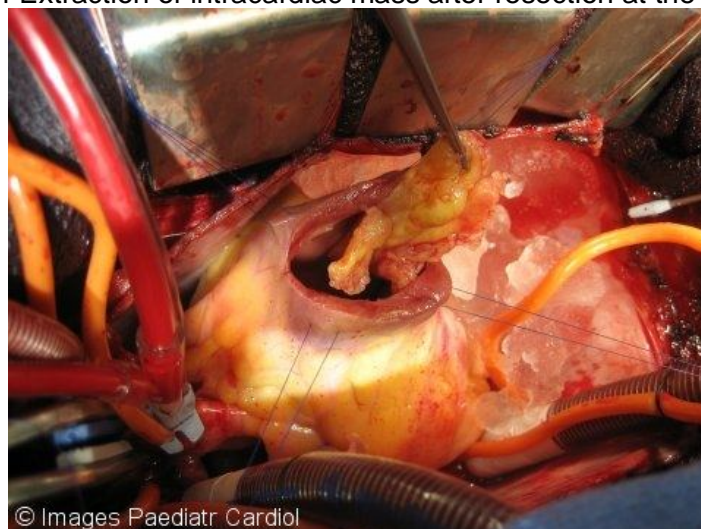


A 1.5 centimeter left upper lung nodule was additionally noted. Echocardiogram further defined a mobile, pedunculated mass within the right ventricle (RV), with the origin of the stalk affixed to the septum of the outflow track of the RV. The patient was asymptomatic. Positron emission tomography (PET) demonstrated that the left lung nodule and the right ventricular outflow tract mass were both metabolically inactive. Through a standard median sternotomy, the left lingular lung nodule was removed with a generous wedge resection. The RV outflow tract was then opened with the patient on full cardiopulmonary bypass. The tumor was noted to be attached to the right ventricular wall near the ventricular septum, and was excised with clear margins (Fig 3 and 4). The ventricle was primarily repaired. Final pathology showed metastatic Ewing's sarcoma for both the right ventricular mass and lingular lung mass. The patient was discharged home on post-operative day four in stable condition, and resumed chemotherapy after his surgical recovery was complete.

Fig 3 Metastatic Ewing's sarcoma attached to the ventricular muscle at the junction of the ventricular septum and right ventricular free wall.

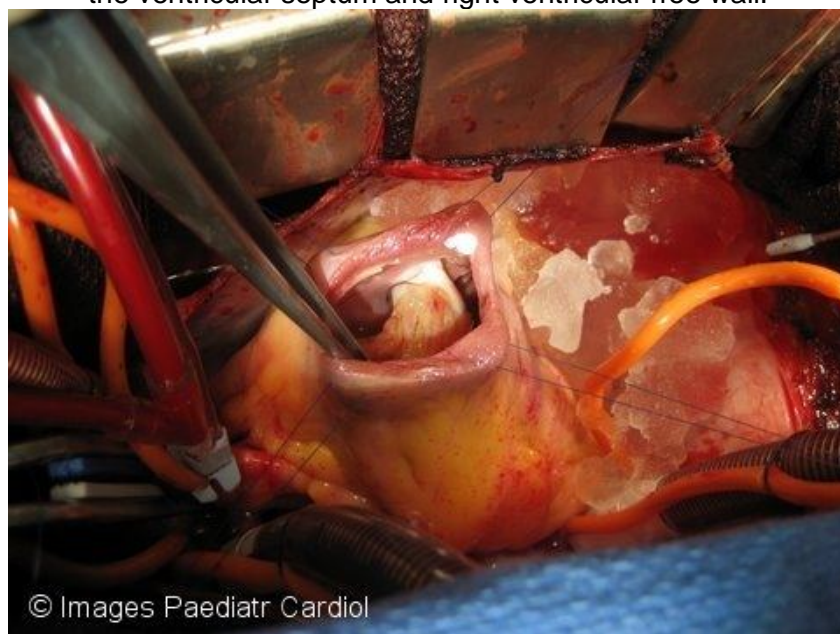

Fig 4 Extraction of intracardiac mass after resection at the stalk.



Discussion

Ewing's sarcoma was first described in 1921, and currently includes soft tissue PNET, classic Ewing's sarcoma of the bone, extraskkeletal Ewing's sarcoma, and Askin's tumor of the thoracopulmonary region. These are linked by their common mesenchymal stem cell, and therefore share immunohistochemical characteristics. Consequently, they also have similar responses to Ewing's-based chemotherapy regimens.

An estimated 20% of patients with Ewing's sarcoma present with distant metastasis.³ One study reviewed 220 patients at St. Jude's Children's Hospital, and found that those with extrapulmonary metastases had worse outcomes than patients with pulmonary metastases.⁴ As a result of chemotherapy as well as multimodality therapy, the 5-year survival rate of localized disease has gone from 10% to over 60% over the past forty years. Yet survival for patients with metastatic disease remains dismally low at less than 25% at 5 years.⁵ The natural history of cardiac metastases is not established, due to the rarity of this finding. Our report demonstrates that metastatic Ewing's sarcoma to the heart can be safely resected at a cardiothoracic institution with good post-operative outcome.

References

1. Alitgan D, Bilge AK, Meric M, Pamukcu B. Metastatic Ewing's sarcoma involving the right ventricle. *Arch Turk Soc Cardiol*. 2008;36:546–548.
2. Paul S, Ramanathan T, Cohen DM, Lebenthal A, Zellos L, Aranki SF, Sugarbaker DJ. Primary Ewing sarcoma invading the heart: Resection and reconstruction. *J Thorac Cardiovasc Surg*. 2007;133:1667–1669.[PubMed: 17532985]
3. Ludwig J. Ewing sarcoma: historical perspectives, current state-of-the-art, and opportunities for targeted therapy in the future. *Curr Opin Oncol*. 2008;20:412–418.[PubMed: 18525337]
4. Paulussen M, Ahrens S, Burdach S, Craft A, Dockhorn-Dworniczal B, Dunst J, Frohlich B, Winkleman W, Zoubek A, Jurgens H. Primary metastatic (stage IV) Ewing tumor; survival analysis of 171 patients from the EICESS studies. *European Intergroup Cooperative Ewing Sarcoma Studies*. *Ann*. 1998;9:275–281.
5. Rodriguez-Galindo C, Liu T, Krasin MJ, Wu J, Billups CA, Daw NC, Spunt SL, Rao BN, Santana VM, Navid F. Analysis of Prognostic Factors in Ewing Sarcoma Family of Tumors: Review of St.Jude Children's Research Hospital Studies. *Cancer*. 2007;110:375–384.[PubMed: 17569105]

