

R Walsh, D Chowdhury, and D Kholwadwala. An unusual vascular ring: Origin of a ductus arteriosus from an aberrant right subclavian artery in a neonate with tetralogy of Fallot. *Images Paediatr Cardiol.* 2010 Apr-Jun; 12(2): 1–4.

IMAGES

in
PAEDIATRIC
CARDIOLOGY

Images Paediatr Cardiol. 2010 Apr-Jun; 12(2): 1–4.

PMCID: PMC3228331

An unusual vascular ring: Origin of a ductus arteriosus from an aberrant right subclavian artery in a neonate with tetralogy of Fallot

R Walsh, D Chowdhury, and D Kholwadwala

Department of Pediatric Cardiology, Schneider Children's Hospital, New Hyde Park, New York 11040, USA

Corresponding author: Rowan Walsh, The Mount Sinai Medical Center, One Gustave L. Levy Place, Box 1201, New York, NY 10029-6574 Tel 212

241 8662 begin_of_the_skype_highlighting FREE 212 241 8662

end_of_the_skype_highlighting Fax 212 534 2659 ; Email:

rowan.walsh@mssm.edu

MeSH: Heart defects, congenital, Aortic Arch

Syndromes/surgery/*ultrasonography

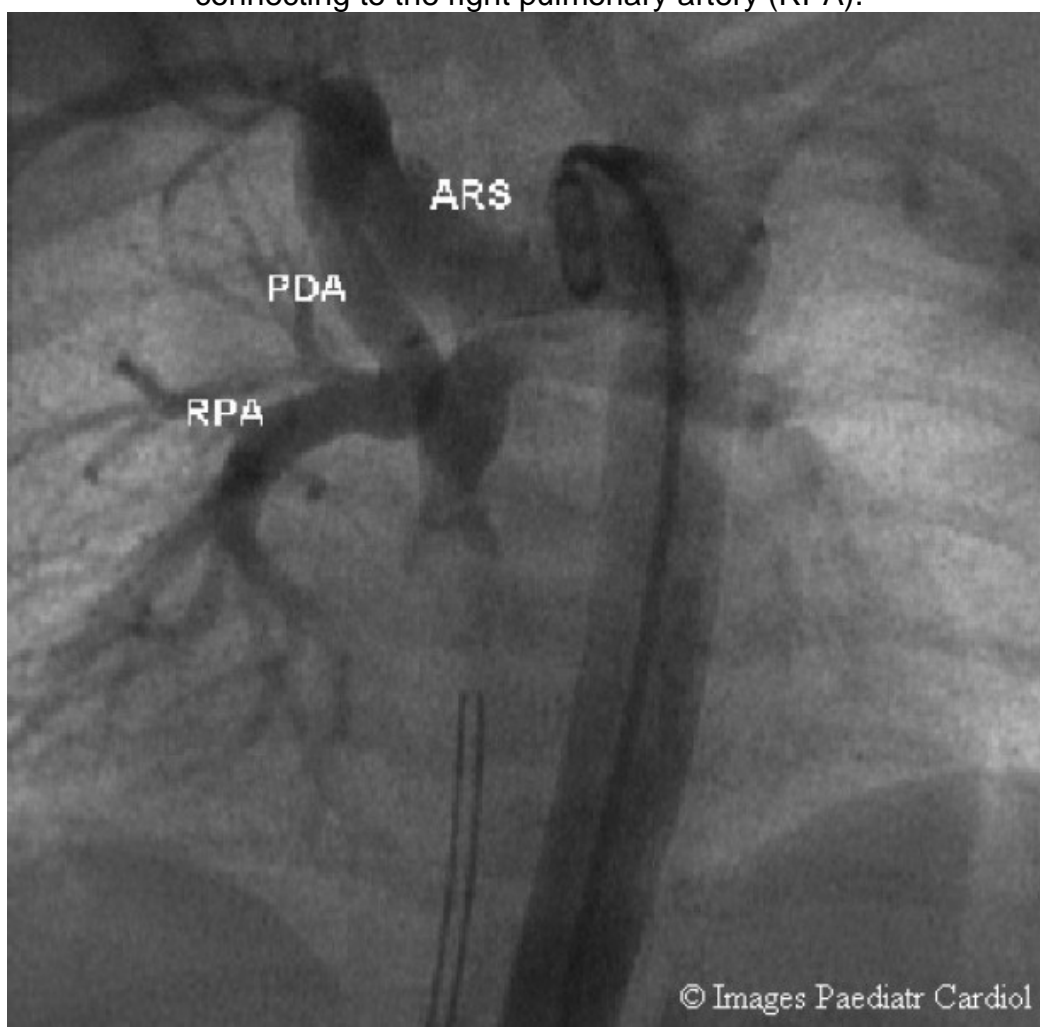
Copyright : © Images in Paediatric Cardiology

This is an open-access article distributed under the terms of the Creative Commons Attribution-Noncommercial-Share Alike 3.0 Unported, which permits unrestricted use, distribution, and reproduction in any medium, provided the original work is properly cited.

Case

A 2.6kg male infant with a prenatal diagnosis of congenital heart disease was delivered via normal vaginal delivery to a 29-year-old mother and subsequently evaluated at our institute. The patient was found to have arterial pre- and post-ductal saturations of 80% and physical examination revealed a holosystolic murmur. The patient did not have stridor. Low ionized calcium was also noted. Echocardiography demonstrated tetralogy of Fallot with an imperforate pulmonary valve and an unusual ductal flow pattern (figure 1). Prostaglandin E₁ infusion was commenced.

Figure 1 Retrograde aortography demonstrating a left aortic arch, an aberrant right subclavian (ARS) giving rise to a patent ductus arteriosus (PDA) connecting to the right pulmonary artery (RPA).



Cardiac catheterization demonstrated a left aortic arch giving rise to an aberrant right subclavian artery. A right patent ductus arteriosus originated from the aberrant right subclavian artery and inserted into the right pulmonary artery, forming a true vascular ring. Mild right pulmonary artery stenosis was noted.

Intraoperative findings confirmed a left aortic arch with a retro-esophageal right subclavian artery giving rise to a right patent ductus arteriosus. The patient underwent a modified left Blalock-Taussig shunt and division of the vascular ring in the operating room. The patient remained stable and did not develop symptoms of upper airway compression.

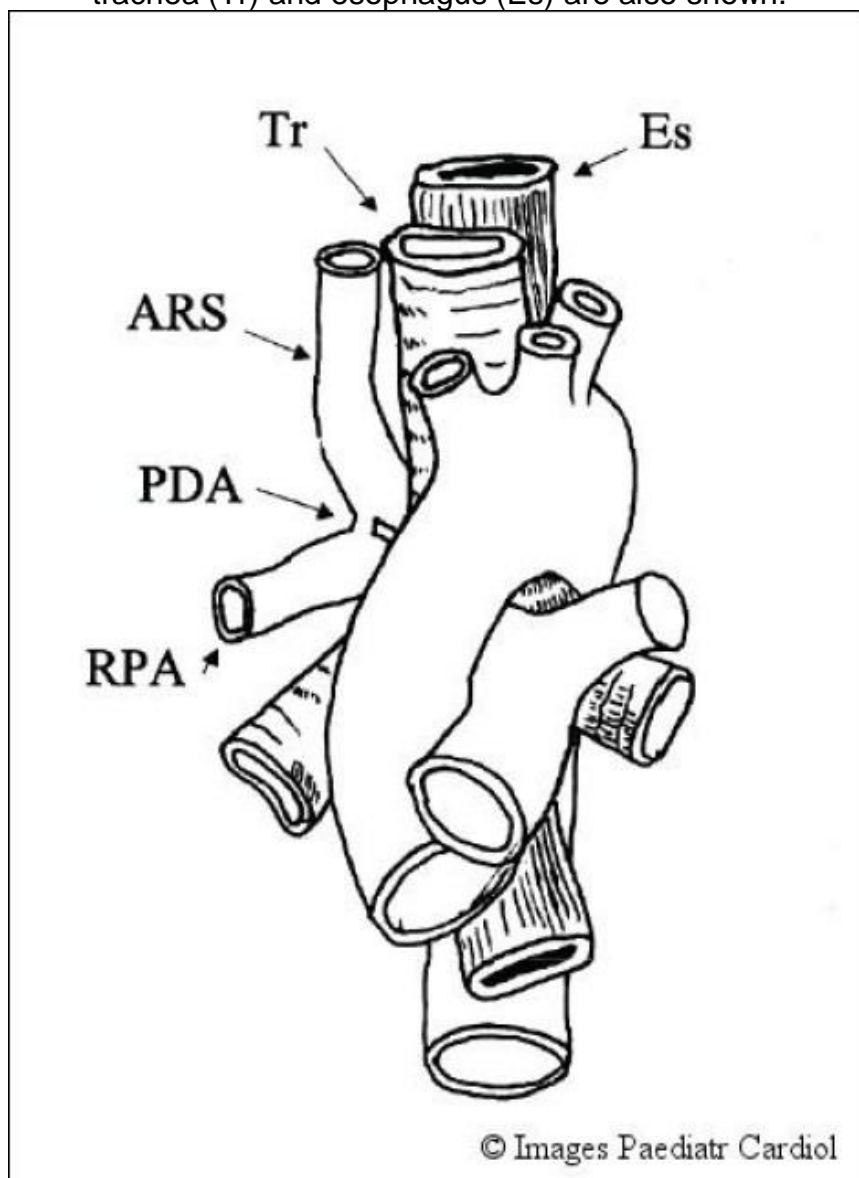
Discussion

This case represents an uncommon type of vascular ring. Most vascular rings and related malformations of the aortic arch result from lack of regression of the eighth segment of the right dorsal aortic root. They may also arise from

R Walsh, D Chowdhury, and D Kholwadwala. An unusual vascular ring: Origin of a ductus arteriosus from an aberrant right subclavian artery in a neonate with tetralogy of Fallot. *Images Paediatr Cardiol.* 2010 Apr-Jun; 12(2): 1-4.

abnormal regression of other segments of the embryonic aortic arch complex (figure 2).^{1,2}

Figure 2 Illustration of a patent ductus arteriosus arising from an aberrant right subclavian artery (ARS) and joining the right pulmonary artery (RPA). The trachea (Tr) and esophagus (Es) are also shown.



The association between aortic arch anomalies and tetralogy of Fallot with an imperforate pulmonary valves has previously been documented in the literature.^{3,4,5} However, in this patient the ductus arteriosus arises from an aberrant right subclavian artery producing an uncommon vascular ring. As the heart migrates caudally during the second month of fetal life, the arrangement and size of the vessels change so that arterial flow is primarily through the left fourth arch and left ductus arteriosus. The seventh intersegmental arteries enlarge to form the proximal portions of the subclavian arteries. With regression of the eighth segment of the right dorsal aortic root

R Walsh, D Chowdhury, and D Kholwadwala. An unusual vascular ring: Origin of a ductus arteriosus from an aberrant right subclavian artery in a neonate with tetralogy of Fallot. *Images Paediatr Cardiol.* 2010 Apr-Jun; 12(2): 1–4.

and the right ductus arteriosus, the general pattern of the normal left aortic arch and its branches is formed.

A left aortic arch with a retro-esophageal right subclavian artery, was initially described by Hunauld in 1735. It is the most common arch anomaly occurring in 0.5% of the population, however there is an increased incidence with tetralogy of Fallot.

Embryologically there is disappearance of the right fourth aortic arch while the distal right dorsal aorta becomes the retroesophageal portion of the proximal right subclavian artery. In most of these cases the right sixth arch disappears. However, in this case the right sixth arch persists as a right-sided ductus arteriosus connecting the aberrant right subclavian artery with the right pulmonary artery, forming a vascular ring. There is regression of the left sixth arch resulting in an absent left ductus arteriosus.

Vascular rings may exist in the presence of complex congenital heart disease. Stridor and difficulty feeding in these patients heightens suspicion for the presence of such anomalies. A right aortic arch is a harbinger of vascular malformations in the presence or absence of congenital heart disease. However, when TOF and an imperforate pulmonary valve exists with a left aortic arch, unusual ductal flow patterns warrants further evaluation for the presence of a vascular malformation.

This patient's congenital heart disease was diagnosed prenatally and the vascular ring component was detected at cardiac catheterization. The presence of such vascular anomalies highlights the importance of detailed anatomical evaluation in every patient with complex heart disease. Cardiac catheterization should be considered when echocardiography detects unanticipated and unusual structures or flow patterns.

References

1. Edwards J. Anomalies of the derivatives of the aortic arch system. *Med Clinic North Am.* 1948;32:925–949.
2. Barry A. Aortic arch derivatives in the Human Adult. *Anat Rec.* 1951;111:221–238.[PubMed: 14894834]
3. D'Cruz IA, Cantez T, Namin EP, Licuta R, Hastreiter AR. Part II: Right aortic arch, right descending aorta, and associated anomalies. *Br Heart J.* 1966;28:722–739. [PMCID: PMC490086][PubMed: 5332779]
4. Hastreiter AR, D'Cruz IA, Cantez T. Right-sided aorta. Part I: Occurrence of right aortic arch in various types of congenital heart disease. *Br Heart J.* 1996;28:722–739. [PMCID: PMC490086][PubMed: 5332779]
5. Nakajima Y, Nishibatake M, Ikeda K, Momma K, Takao A, Terai M. Abnormal development of Fourth Aortic Arch Derivatives in the Pathogenesis of Tetralogy of Fallot. *Pediatr Cardiol.* 1990;11:69–71.[PubMed: 2349144]

© Images in
Paediatric Cardiology
(1999-2012)

