

<h1>IMAGES</h1>	<b>in</b> <b>PAEDIATRIC</b> <b>CARDIOLOGY</b>
-----------------	---

Images Paediatr Cardiol. 2009 Jan-Mar; 11(1): 7–9.

PMCID: PMC3232600

## **The chest x-ray in congenital heart disease 1. Total anomalous pulmonary venous drainage and coarctation of the aorta**

J Somerville and V Grech

Paediatric Department, Mater Dei Hospital, Malta

**Corresponding author:** Victor Grech, Editor-in-Chief, Images Paediatr Cardiol ; Email: victor.e.grech@gov.mt

**MeSH:** Heart defects, congenital, chest x-ray

Copyright : © Images in Paediatric Cardiology

This is an open-access article distributed under the terms of the Creative Commons Attribution-Noncommercial-Share Alike 3.0 Unported, which permits unrestricted use, distribution, and reproduction in any medium, provided the original work is properly cited.

The chest x-ray (CXR) is a useful investigation in congenital heart disease, and has been probably ignored in recent years as echocardiography and other exotic and expensive imaging techniques can show anatomy and physiology. The CXR is a simple, quick and cheap test that yields useful diagnostic information, heart size, lung pathology as well as providing a readily available documentation of these facts for serial comparison. Such information is useful and even vital for the paediatric and the grown up congenital heart population. The echocardiogram gives little or no information on lung pathology or secondary pulmonary effects. The CXR readily demonstrates the classic heart shapes of congenital heart disease and supplies an easily seen record of heart size with low radiation levels. For young clinicians to find teaching about this cheap investigation is hard. This article is the first of a series of articles that highlight the use and the value of the CXR in congenital heart disease.

Figure 1 is a classic picture of the 'snowman' or 'cottage loaf' heart shape due to total anomalous pulmonary venous drainage into a left superior vena cava (SVC). The confluence of pulmonary veins joins behind the heart and enters the ascending limb of the left SVC which appears as a dilated vessel on the right of the upper mediastinal edge. This large venous flow enters the transverse crossing vein or innominate vein making the convex roof of the cottage loaf, and joins the right SVC causing dilatation of the left side of mediastinum. As one looks at this film, there is, beneath these venous shadows, the lower part of the cottage loaf made up of dilated right atrium and ventricular mass which is the right ventricle. There is considerable increase in

the size of pulmonary vessel arteries and veins (pulmonary plethora). This is due to increased pulmonary blood flow shown throughout the lungs.

This is from a young adult and it is unusual to find this in an adult. The picture is pathognomonic. The patient presents with signs of large atrial septal defect with mild cyanosis from the obligatory right to left shunt at atrial level.

Figure 2 is a penetrated view of the posterior ribs on the right side of chest. The notching is on the lower edges due to dilatation of the intercostal arteries. It affects ribs 4, 5, and 6 where it is maximal. This comes from a 30 year old male with coarctation of the aorta and was present bilaterally.

Unilateral rib notching at this site can occur following thoracotomy and failed shunt in cyanotic heart disease. In this patient, the coarctation is at classic site at T4. When it is lower, rib notching will affect lower ribs. It will not be present in abdominal coarctation.

Figure 1 'Snowman' or 'cottage loaf' heart shape due to total anomalous pulmonary venous drainage.

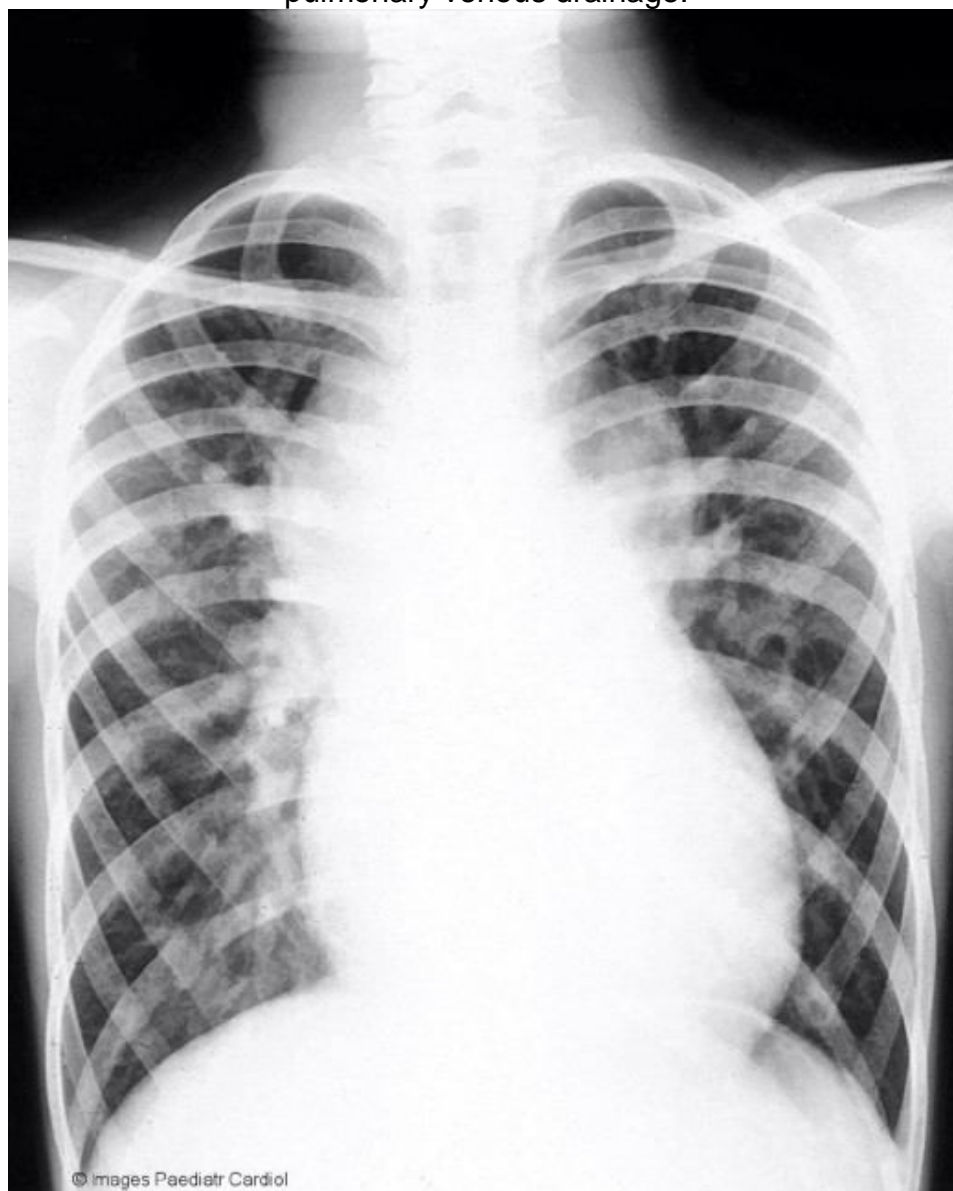
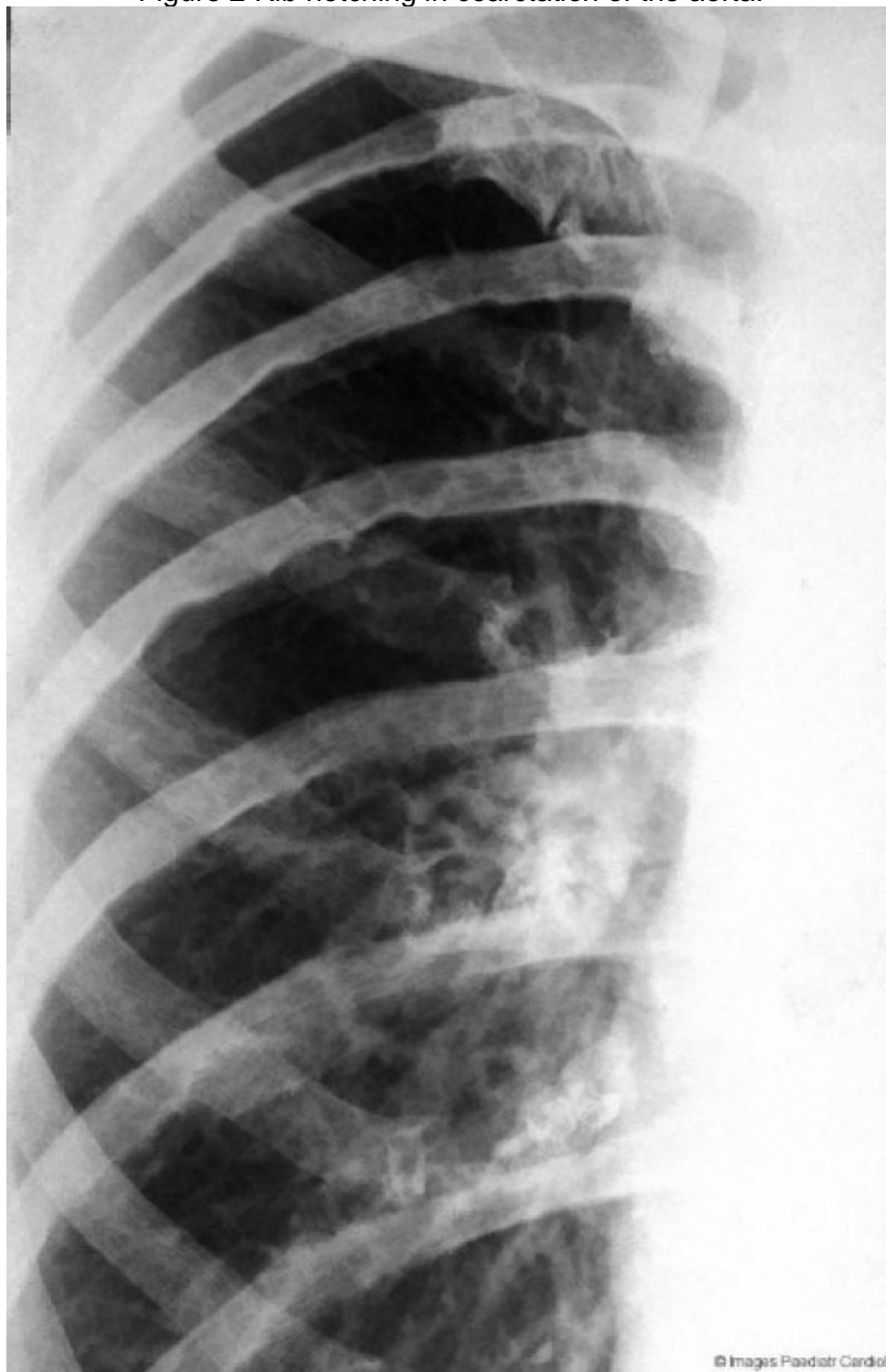


Figure 2 Rib notching in coarctation of the aorta.



© Images in  
Paediatric Cardiology  
(1999-2012)

