

MO Galal, H Turkistani, and A Sultan. Change of size and type of patent ductus arteriosus in a one year old infant during routine echocardiographic study. *Images Paediatr Cardiol.* 2008 Apr-Jun; 10(2): 6–10.

# IMAGES

in  
PAEDIATRIC  
CARDIOLOGY

*Images Paediatr Cardiol.* 2008 Apr-Jun; 10(2): 6–10.

PMCID: PMC3232587

## Change of size and type of patent ductus arteriosus in a one year old infant during routine echocardiographic study

MO Galal,<sup>1,2</sup> H Turkistani,<sup>1</sup> and A Sultan<sup>1</sup>

<sup>1</sup>Prince Salman Heart Center, King Fahad Medical City, Riyadh, KSA.

<sup>2</sup>University Childrens Hospital, Essen, Germany.

**Contact information:** Mohammed Omar Galal, Prince Salman Heart Center, King Fahad Medical City, 11525 Riyadh, PO Box 59046, Saudi Arabia Fax: 00966-1-2889999 ext 1108 ; Email: [ogalal@yahoo.com](mailto:ogalal@yahoo.com)

**MeSH:** Ductus Arteriosus, Patent, Echocardiography, Heart defects, congenital

Copyright : © Images in Paediatric Cardiology

This is an open-access article distributed under the terms of the Creative Commons Attribution-Noncommercial-Share Alike 3.0 Unported, which permits unrestricted use, distribution, and reproduction in any medium, provided the original work is properly cited.

There are only very few publications which document reactivity of patent ductus arteriosus. Dennis et al, reported the intermittent disappearance of a patent ductus arteriosus murmur in a ten year old girl.<sup>1</sup> They noticed that at the time when they published their report, already 12 other patients were known to have intermittent disappearance of their murmur. Seven years before, intermittent functional closure of patent ductus arteriosus in a ten-month-old infant has been documented hemodynamically.<sup>2</sup> A report from Germany had shown that the duct can increase in size during the manipulations at transcatheter procedure.<sup>3</sup> Another case report from India, documented the severe spasm of a large patent duct during an interventional procedure.<sup>4</sup>

In contrast to these reports, we documented the reactivity of a patent arterial duct in a one year old infant, 6.5 kg weight during a routine echocardiographic color Doppler study. Echocardiographic images were obtained during conscious sedation. The boy remained calm and asleep throughout the study. In the previous cases, it was suggested that duct widened or went into spasm either in response to angiography or to the manipulations of the catheter.<sup>3,4</sup> In our case and within a time frame of only 10 minutes, the duct changed its size gradually from a barely seen left to right shunt (Figures 1-3) into a moderate sized (>3.3 mm) duct. (figures 4,5). To our knowledge, this is the first time that the reactivity of a patent arterial duct has been documented echocardiographically.

Figure 1 Ductal view at 11:30, showing a small duct with small ampulla, no shunt.

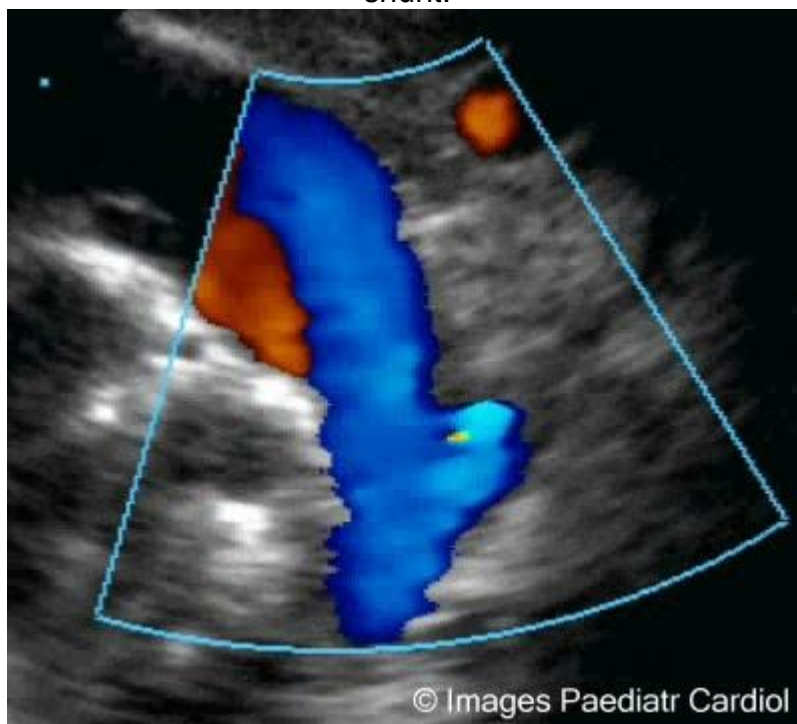
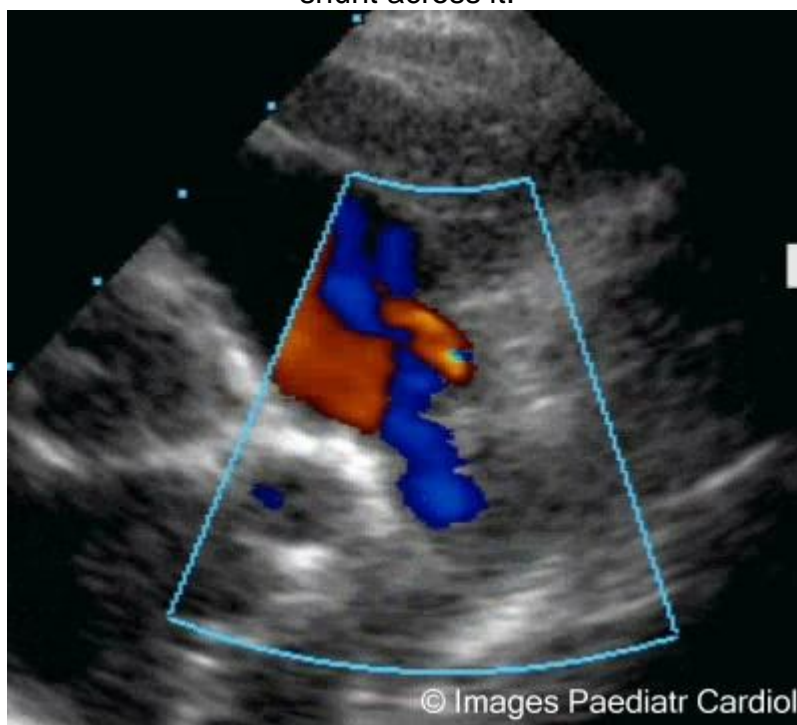


Figure 2 Ductal view at 11:33, showing a small duct with small left to right shunt across it.



MO Galal, H Turkistani, and A Sultan. Change of size and type of patent ductus arteriosus in a one year old infant during routine echocardiographic study. *Images Paediatr Cardiol.* 2008 Apr-Jun; 10(2): 6-10.

Figure 3 Ductal view at 11:38, showing a moderate patent duct with moderate flow across it.

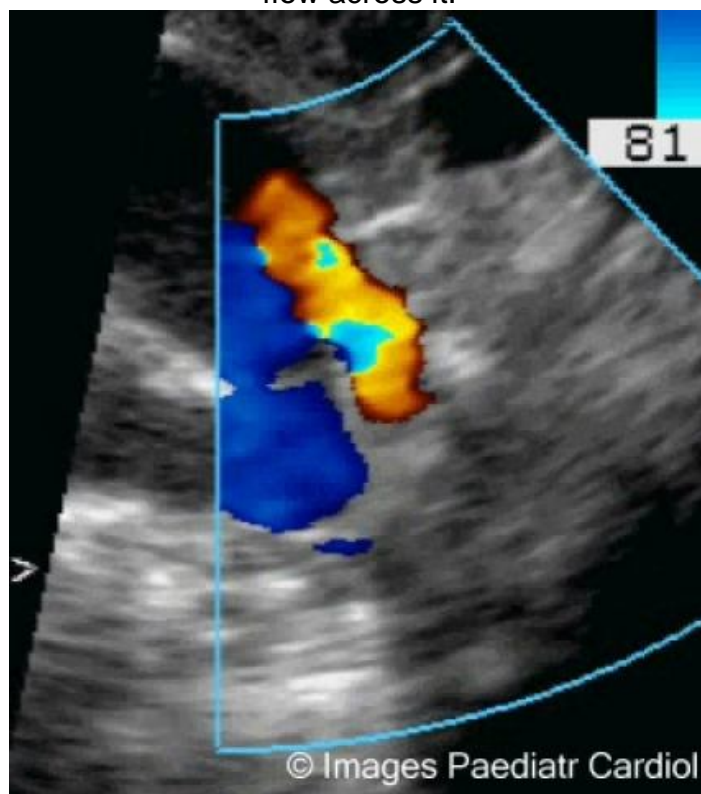
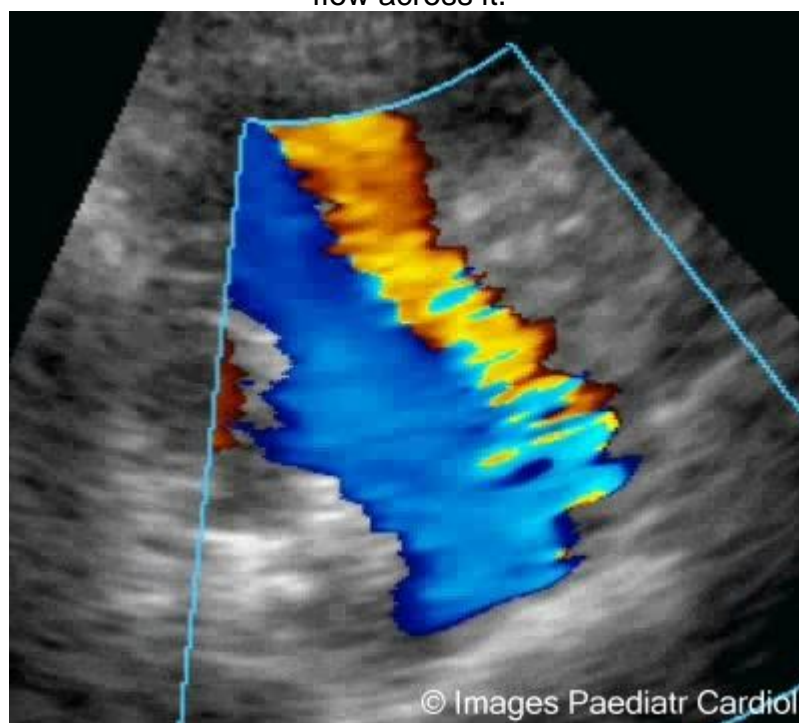
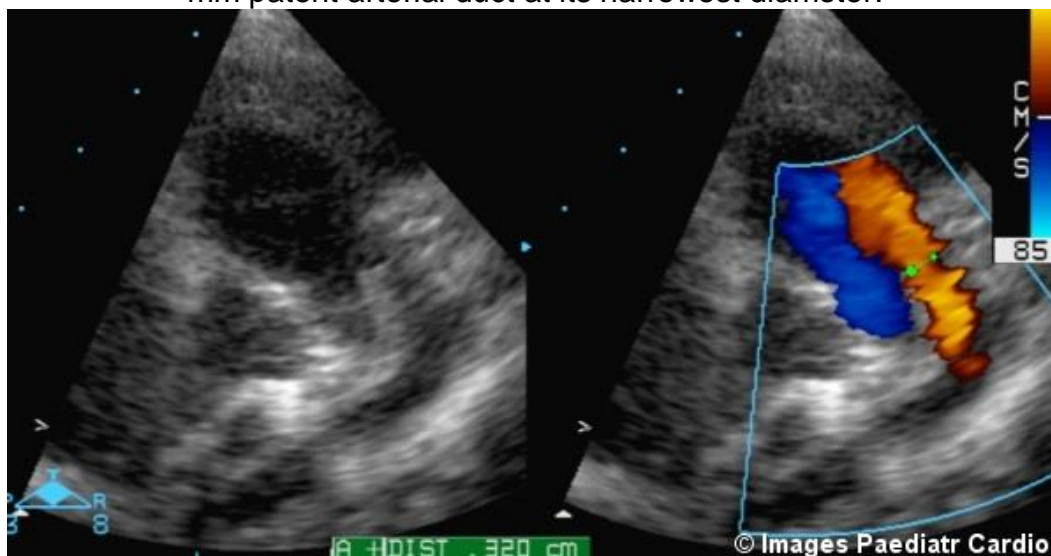

Figure 4 Ductal view at 11:39, showing a larger patent duct with significant flow across it.



MO Galal, H Turkistani, and A Sultan. Change of size and type of patent ductus arteriosus in a one year old infant during routine echocardiographic study. *Images Paediatr Cardiol.* 2008 Apr-Jun; 10(2): 6–10.

Figure 5 Still frame in the ductal view, showing on the left side the left pulmonary artery and the duct, on the right hand side the color across the 3.3 mm patent arterial duct at its narrowest diameter.



Ductal reactivity in late infancy remains an unusual occurrence. Despite the reports of intermittently disappearing murmurs, until recently, it has been doubted that ductal diameter change occurs in absence of any direct or indirect manipulation of the arterial duct. Our report shows that reactivity of the duct can happen without any mechanical reason. This fact should make us more alert during transcatheter closure. Especially in young children less than 2 years of age, multiple angiographic injections should be done during transcatheter closure and especially before releasing the device, to ensure that the duct did not change its size or its shape.

MO Galal, H Turkistani, and A Sultan. Change of size and type of patent ductus arteriosus in a one year old infant during routine echocardiographic study. *Images Paediatr Cardiol.* 2008 Apr-Jun; 10(2): 6–10.

## References

1. Cokkinos DV, Leachman RD, Lufschanowski R. Intermittent disappearance of a patent ductus arteriosus murmur: Case report and review of the literature. *Tex Heart Inst J.* 1982;9:57–60. [PMCID: PMC341473][PubMed: 15226813]
2. DuBrow IW, Fisher E, Hastreiter A. Intermittent functional closure of patent ductus arteriosus in a ten-month-old infant; hemodynamic documentation. *Chest.* 1975;68:110–113.[PubMed: 1149510]
3. Dittrich S, Berger F, Nürnberg JH, Borm B, Lange RE. Reactivity of patent ductus arteriosus : management during transcatheter occlusion. *Monatsschrift fuer Kinderheilkunde.* 1997;145:798–801.
4. Kannan BRJ, Sadhananthan AK, Kumar RK. Severe spasm of a large patent ductus arteriosus. *Ind Heart J.* 2005;57:274–274.

© Images in  
Paediatric Cardiology  
(1999-2012)

